HAL
open science

Primary total knee arthroplasty for acute fracture around the knee

Jean-Noël Argenson, S. Parratte, M. Ollivier

To cite this version:

Jean-Noël Argenson, S. Parratte, M. Ollivier. Primary total knee arthroplasty for acute fracture around the knee. Orthopaedics & Traumatology: Surgery & Research, 2018, 104 (1, S), pp.S71-S80. 10.1016/j.otsr.2017.05.029 . hal-01960517

HAL Id: hal-01960517

https://hal.science/hal-01960517

Submitted on 26 Apr 2019

HAL is a multi-disciplinary open access archive for the deposit and dissemination of scientific research documents, whether they are published or not. The documents may come from teaching and research institutions in France or abroad, or from public or private research centers.

L'archive ouverte pluridisciplinaire **HAL**, est destinée au dépôt et à la diffusion de documents scientifiques de niveau recherche, publiés ou non, émanant des établissements d'enseignement et de recherche français ou étrangers, des laboratoires publics ou privés.

Primary total knee arthroplasty for acute fracture around the knee

S. Parratte[a,b,*], M. Ollivier[a,b], J.-N. Argenson[a,b]

[a] CNRS, ISM UMR 7287, Aix-Marseille université, 13288 Marseille cedex 09, France
[b] Service de chirurgie orthopédique, institut du mouvement et de l'appareil locomoteur, hôpital Sainte-Marguerite, 270, boulevard Sainte-Marguerite, BP 29, 13274 Marseille, France

a b s t r a c t

Relatively poor results have been reported with open reduction and internal fixation of complex fractures around the knee in elderly osteoporotic patients, and primary total knee arthroplasty (TKA) has been proposed as an alternative solution. While limiting the number of procedures, it meets two prerequisites: (1) to save the patient's life, thanks to early weight-bearing, to limit decubitus complications; and (2) to save knee function and patient autonomy, thanks to early knee mobilization. There are 3 main indications: complex articular fractures in elderly patients with symptomatic osteoarthritis prior to fracture; complex articular fractures of the tibial plateau in elderly patients whose bone quality makes internal fixation hazardous; and major destruction of the distal femur in younger patients. Although admitted in emergency, these patients require adequate preoperative management, including a multidisciplinary approach to manage comorbidities, control of anemia and pain, and assessment and management of vascular and cutaneous conditions. Preoperative planning is crucial, to order appropriate implants and materials that may be needed intraoperatively. Surgical technique is based on the basic principles of revision surgery as regards choice of implant, steps of reconstruction, bone defect management and implant fixation. For complex fractures of the distal femur, primary temporary reduction is a useful "trick", to determine the level of the joint line and femoral rotation. Complementary internal fixation may be required in case of diaphyseal extension of the fracture and to prevent inter-prosthetic fractures. In the literature, the results of primary TKA for fracture are encouraging and better than for secondary TKA after failure of non-operative treatment or internal fixation, with lower rates of revision and complications, earlier full weight-bearing and better functional results. Loss of autonomy is, however, frequent, and 1-year mortality is high, especially following complex femoral fractures in the elderly.

1. Introduction

Arthroplasty is commonly used to treat acute fracture of the proximal femur, complex proximal humerus fracture or elbow fracture [1,2], but is less usual in complex knee fracture [3,4]. The main objective of arthroplasty in fractures of the proximal femur is to save the patient's life by limiting the decubitus complications, thanks to immediate resumption of weight-bearing [2,3]. For the shoulder and elbow, the objective is to save joint function, thanks to immediate postoperative mobilization [1,2].

Most complex knee fractures in the elderly are treated by internal fixation or even non-operatively [2–6]. There are, however, good reasons, in the knee as much as for hip or shoulder fractures, for treating certain acute complex fractures using an arthroplasty, such as: significant symptomatic osteoarthritis prior to the fracture, fracture complexity, especially of its articular part, bone fragility making fixation hazardous, and the need for early mobilization and the earliest possible resumption of walking in elderly patients, to avoid the decubitus complications and the risk becoming bedridden [2–6].

The present study hypothesis was therefore that knee arthroplasty could be a solution for acute fractures around the joint in elderly osteoporotic patients, in order to limit decubitus complications and preserve knee function.

We shall therefore seek to answer the following questions:

- what are the fundamental principles of this treatment?
- what are the indications?
- how to prepare for and plan surgery?
- what are the technical specificities?
- what postoperative management is needed?
- what are the expected results?

2. What are the fundamental principles of this treatment?

The indications for first-line arthroplasty in complex epiphyseal shoulder and elbow joint fractures are now well established, with the same rationale as for displaced femoral neck fracture in the elderly [1–6]. What is at issue is the same, with the same contradictory requirements: it is difficult if not impossible to achieve stable bone reconstruction by internal fixation, due to osteoporosis and/or fracture comminution, while rapid recovery of optimal joint function is mandatory [1–6]. In the lower limb, moreover, the prime requirement is to resume full weight-bearing as soon as possible, to avoid decubitus complications, which induce high mortality [2–6].

Thus, in the knee, reconstruction using arthroplasty is sometimes the only surgical option that fulfils the two requirements of saving the patient's life thanks to early resumption of full weight-bearing and saving function thanks to immediate unrestricted joint mobilization [2–6].

Incidence of complex epiphyseal knee fracture is much lower than for fracture of the femoral neck, proximal humerus or elbow, accounting for around 1% of annual emergency admissions [3,4]. The exact incidence of knee joint fracture is hard to determine, as it varies according to demographic and geographical factors. In a series of more than 6,000 fractures, annual incidence of proximal tibia fracture was 13.3 per 100,000 in adults, and 4.5 per 100,000 for distal femoral fracture [7]; there was male predominance for proximal tibia fracture, and female predominance for distal femoral fracture [7].

Internal fixation of complex knee fracture in elderly patients shows loss of reduction in 30–79% of cases for the proximal tibia, with patient age, osteoporosis, comminution and initial displacement as risk factors [3–6]. Due to the limited incidence of these fractures, the number of published series is restricted [3–6]. Although loss of reduction has been studied, its consequences concerning autonomy and mortality are poorly documented [3–6]. Reliable internal fixation is difficult to achieve in diaphyseal, metaphyseal and epiphyseal fracture in severely osteoporotic patients. For these patients, weight-bearing is often proscribed for at least 6 weeks, which greatly limits mobilization, as these patients are unable to use crutches without weight-bearing [3–6]. In case of severe joint comminution with osteoporotic bone and osteoarthritis, the benefit of internal fixation followed by non-weight-bearing is highly questionable [3–6]. Moreover, when progression following internal fixation is not favorable, these patients do not always receive arthroplasty, due to their age and the risks involved in 2-step or 1-step material ablation and implantation [3–6].

To minimize the number of procedures and optimize functional results, Wolfgang [8] was, to our knowledge, the first to report a case of rheumatoid arthritis treated in emergency by total knee arthroplasty (TKA) for an epiphyseal fracture of the distal femur. Subsequently, case reports and small series have been published [9–13]. Two series in particular should be highlighted: Rosen and Strauss [14] reported a large series over a short period; and Nourissat et al. [15] reported the first series for tibial facture in France. Results in these first series were relatively satisfactory; indications were progressively refined and the technique developed [9–15].

To sum up:

- the results of internal fixation are often poor in complex articular fracture around the knee in elderly osteoporotic patients;
- primary arthroplasty can be an interesting solution, fulfilling two treatment requirements while reducing the number of procedures,
  - saving the patient's life thanks to early resumption of weight-bearing, limiting decubitus complications,
  - and saving function, thanks to immediate unrestricted joint mobilization, minimizing loss of autonomy.

3. What are the indications?

There are three major indications: complex articular fracture in elderly patients with symptomatic osteoarthritis prior to the fracture; complex fracture of the tibial plateau in elderly patients where articular involvement makes internal fixation hazardous; and complete femoral metaphysis destruction in younger patients [3–6].

3.1. Elderly osteoporotic patients with osteoarthritis prior to the fracture

This is the most frequent situation [3–6]. These patients present in emergency with a complex comminuted articular fracture of the distal femur or of the proximal tibia. X-ray finds signs of osteoarthritis, and the interview often finds that the patient was already suffering before the fracture. Arthroplasty may in some cases have already been scheduled by another physician before the fracture occurred. Arthroplasty is here a logical solution for both the fracture and the osteoarthritis (Fig. 1) [3–6]. It is important to check that there is no hip arthroplasty stem or other internal fixation material that would hinder knee arthroplasty (Fig. 2).

3.2. Fracture (especially of the tibial plateau) in elderly osteoporotic patients where articular involvement makes internal fixation hazardous

This situation is also quite frequent [3–6]. An elderly patient presents in emergency with complex articular fracture of the proximal tibia, with osteoporotic bone (Fig. 3). The complexity of the fracture, which is often very proximal and with considerable articular step-off, makes internal fixation uncertain. There is a major risk of inadequate reduction of the articular step-off, secondary loss of reduction and material cut-out, and therefore functional prognosis is poor. First-line arthroplasty seems to represent a reasonable attitude, with metaphyseal and epiphyseal tibial reconstruction, allowing immediate weight-bearing (Fig. 4), rather than attempting

Fig. 1. A. The patient presents in emergency with complex comminuted joint fracture of the distal femur. Radiography shows signs of osteoarthritis, and interview usually finds that the patient is already suffering and that TKA had been indicated before the fall. B. Same situation, with tibial fracture.

Fig. 2. A–B. Be careful to check that there is no long hip implant stem or other material liable to hinder implantation.

internal fixation, with a high risk of failure, and subsequent removal of material and arthroplasty with the same need for reconstruction as in first-line arthroplasty [3–6].

3.3. Complete destruction of the distal femur in road accidents in younger patients

This is the most debatable and least frequent indication. To date, no authors have recommended it, although some teams suggest it for extremely complex high-energy fractures sustained in road accidents by young subjects (Fig. 5). The age limit is not well defined, and arthroplasty is indicated only when internal fixation seems unfeasible due to the complexity of the fracture.

Fig. 4. In complex proximal tibial fracture in the elderly, it seems more logical to suggest first-line arthroplasty with metaphyseal and epiphyseal tibial reconstruction, to enable immediate weight-bearing, rather than attempting internal fixation, with its high risk of failure (A), requiring subsequent removal of the hardware followed by implantation (B) with the same reconstruction requirements as in first-line arthroplasty.

This indication is very rare, even in centers treating polytrauma, and first-line arthroplasty can be considered only when a major bone defect might require a so-called tumor-prosthesis implant (as used after tumor resection) or fusion using a modular or customized intramedullary nail.

The integrity of the extensor mechanism should be checked and, in case of open fracture, skin cover and healing must be perfect before considering any arthroplasty.

There is a major risk of infection, and long-term prognosis is not good, which limits indications. Therefore, these cases should

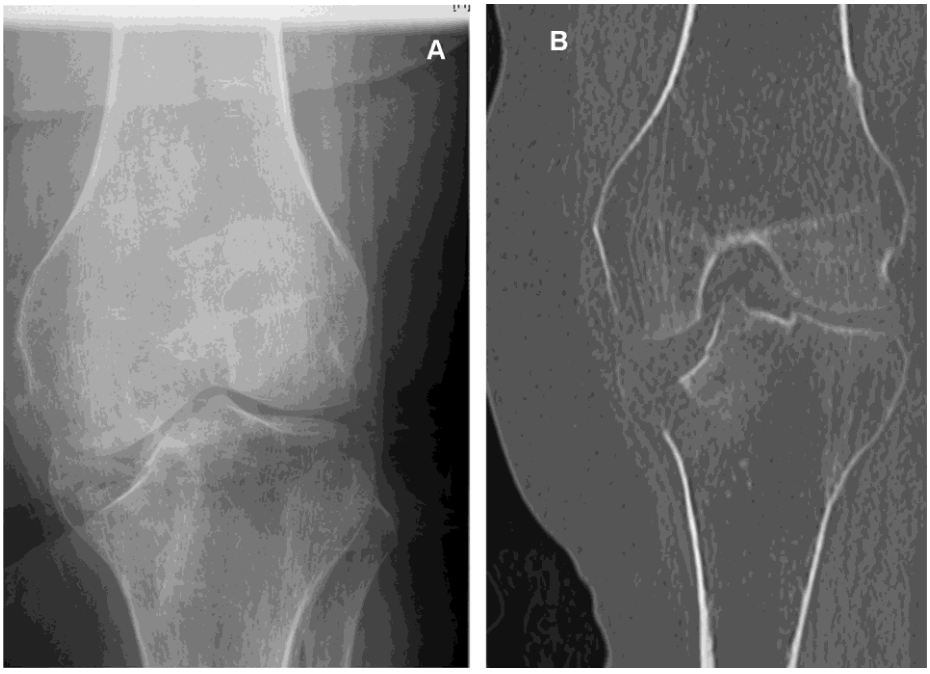

Fig. 3. Elderly patient presents in emergency with complex joint fracture of the proximal tibia, with osteoporotic bone. The complexity of the fracture, which is often very proximal and with considerable step-off of the articular surface, makes internal fixation uncertain.

Fig. 5. Complete destruction of the distal femur in road accidents in younger patients is rarer (A), but may in some cases be a good indication for first-line arthroplasty (B). (With thanks to Pr. Francesco Benazzo).

be discussed on a case-by-case basis; reconstruction by implant should be chosen only if no conservative solution seems available.

3.4. Key-points

There are three main indications:

- complex articular fracture in elderly patients with pre-existing osteoarthritis;
- complex tibial plateau fractures in elderly patients where articular and metaphyseal destruction makes internal fixation hazardous;
- complete destruction of the distal femur in younger patients.

4. How to optimize surgical planning?

These patients are admitted in emergency, but need to be prepared and managed as for scheduled surgery: local and general preparation of the patient. The surgical team itself should also be ready and it is important to order adequate implants and ancillary instrumentation so as not to delay treatment.

4.1. Analysis and management of the patient's general health condition

These patients, admitted in emergency, require rigorous orthogeriatric management, taking full account of comorbidity [16]. Fracture-related anemia should be treated before surgery, and pain should be controlled as of admission. Adhesive traction or cast immobilization may be implemented, to limit fracture site mobility.

4.2. Analysis of skin condition

These elderly patients often have fragile skin, with hematoma and sometimes contusions related to the trauma, for which strict preoperative surveillance is required.

Open fractures are rare in low-energy trauma in elderly patients. Open fracture may, however, be observed in massive distal femur destruction in young poly-trauma patients, and any doubt as to the feasibility of adequate skin coverage contraindicates arthroplasty.

4.3. Analysis of vascular condition

Associated vascular lesions are rare, but should be systematically screened for before surgery.

Fig. 6. Some fractures could be excellent indications (A), but severe venous insufficiency is not unusual (B) and may become a contraindication if there is any doubt regarding the proper healing of the skin due to poor vascular status.

Venous insufficiency, on the other hand, is not unusual and may contraindicate surgery if there is any doubt concerning satisfactory skin healing due to poor vascular condition (Fig. 6).

4.4. Logistics

Surgical planning determines the precise needs for material. Not all centers have permanent access to segmental reconstruction implants (tumoral reconstruction implants), rotating hinged implants or revision implants with metal augmentation systems.

Thus, although these patients are admitted in emergency, surgery has to be accurately planned as quickly as possible, taking account of the time needed to procure equipment.

Key-points:

- despite emergency admission, these patients need strict preoperative planning, including multidisciplinary management of comorbidity, control of anemia, and analysis of skin and vascular condition, and optimal preoperative planning.

5. What are the technical specificities?

These first-line arthroplasties require thorough knowledge of the basic rules of revision surgery [17–19]. Choice of constraint, planning of joint-line restoration and component rotation, bone defect filling and implant fixation are the same as in prosthetic revision or, in the case of major epiphyseal and metaphyseal destruction, the same as in segmental reconstruction following tumor resection [19,20].

To have this experience is mandatory, to keep surgical time as short as possible in these fragile elderly patients [3–6]. Thus, all the above-mentioned choices (implants, level of resection, defect filling, implant fixation, complementary internal fixation, etc.) should be anticipated and made in advance [3–6].

In France, emergency traumatology surgery is usually performed by junior surgeons; first-line TKA for fracture, however, should be performed by or with the help of an experienced surgeon. It is essential to be prepared for this operation, which should be performed as scheduled emergency surgery, to optimize surgical conditions [3–6]. It should never be performed by a duty surgeon with a small team often without any training in TKA revision surgery.

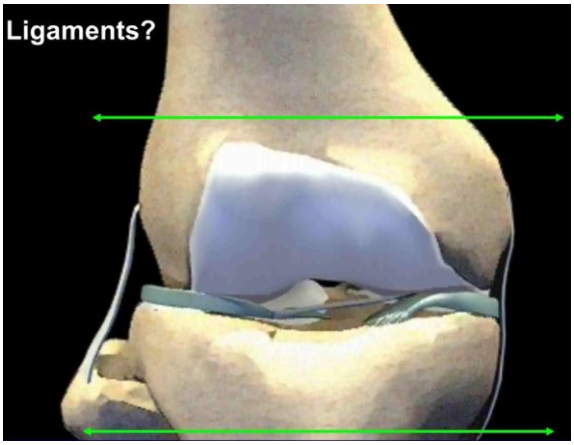

Fig. 7. Schematically, when the fracture involves the tibial or femoral collateral ligament insertions, a rotating-hinge implant should be used.

The three main stages of TKA revision with joint reconstruction described by Vince [21] should be applied here: reconstruction of the tibial base plate, management of the flexion gap, and management of the extension gap. The main goal is to enable the patient to stand up and resume full weight-bearing immediately after surgery. The choice of fixation, modalities of the reconstruction and the entire procedure should therefore be performed with this goal in mind.

5.1. Choice of implant and constraint

The choice of implant and constraint depends on the fracture level and degree of metaphyseal destruction. Schematically, when the fracture involves the tibial or femoral collateral ligament insertions, a rotating-hinge implant should be used (Fig. 7). It is usually impossible to achieve solid internal fixation of the condyles preserving a functional collateral ligament insertion.

In case of severe metaphyseal destruction up to the diaphysis, a segmental mega- prosthesis should be used, especially on the femoral side. In prosthetic revision in younger patients, it is still relevant to seek to minimize constraint, but in complex fractures the essential is to obtain a pain-free, mobile but also and above all stable [3] knee [6,19,20].

Preoperative analysis is thus crucial. Excellent preoperative radiographic views are necessary. CT with 3D reconstruction can be helpful if good-quality X-rays are difficult to obtain due to pain, and/or to improve fracture analysis [3–6]. In these contexts, it is often impossible to obtain good-quality long-leg X-rays including the contralateral limb for length measurement.

5.2. Patient positioning

Patient positioning is as for TKA revision, according to the surgeon's preference. Due to the fracture, it is often difficult to use supports to obtain a stable knee at 90°. We do not use a tourniquet, to be able to release the extensor system and obtain adequate exposure, especially for mega-prostheses. We recommend using tranexamic acid, even in these elderly patients, as contraindications are increasingly rare, and cell-saver [22].

5.3. Approach

The approach should be the one the surgeon adopts for revision TKA. We use the extended sub-vastus approach in revision TKA and also in primary TKA for acute fracture [6,23]. This approach is a quad-sparing solution and has the advantage of being extendable, avoiding the need for anterior tibial tubercle osteotomy or oblique quadriceps tenotomy [6,23].

5.4. Tibial fracture

The main difficulty in tibial fracture is to achieve a stable baseplate, associated to appropriate fixation [3–6]. Joint-line level and tibial rotation are fairly easy to determine. The problem can be solved by following the principles described below (sections 4.6 on defect filling, and 4.7 on implant fixation).

There are, however, a few points worth detailing, according to the type of fracture.

5.4.1. Comminuted lateral condyle fracture

The medial plateau is respected and it is easy to reconstruct the tibial base, maintain joint-line level and determine rotation. Lateral defect filling is important for stability.

5.4.2. Bicondylar tibial fractures

This is the most complex case, due to the instability of the tibial base, requiring temporary reduction (described in detail in section 4.5.1 below, for the femur), to determine joint-line level and tibial rotation and to select the best option to treat tibial bone loss. Use of a cone or other filling device, stabilized by a cemented stem, is essential for early resumption of full weight-bearing.

5.4.3. Management of anterior tibial tubercle fracture

It is important to analyze the X-rays (and CT scans, if any) carefully, so as to include management of the associated anterior tibial tubercle fracture in the preoperative planning.

This fracture may be considered as a contraindication; however, appropriate internal fixation can be considered, by screws and/or cerclages using steel wires passed behind the tibial stem before cementing, as in anterior tibial tubercle fixation during extensor mechanism allografting.

5.4.4. Choice of implant constraint

The choice of constraint is essential. The ligament insertions can usually be spared; however, postoperative stability is more important, and for this an LCCK or a rotating-hinge implant might be a good choice to ensure an adequate postoperative stability.

Megaprosthesis implants are unsuitable for the tibia due to the difficulty of restoring extensor mechanism continuity. This highlights the importance of conserving the epiphysis in proximal tibial fracture.

5.5. Femoral fracture

5.5.1. Principle of primary temporary reduction

As in prosthetic revision or reconstruction after tumor resection, two key issues comprise restoration of the joint-line and femoral rotation [3–6]. In indications for TKA for acute femoral fracture, destruction is often severe and landmarks are unclear [3–6]. We therefore recommend "primary temporary reduction" (Fig. 8), which simply consists in reducing the fracture as well as possible for as long as it takes to mark joint-line level and rotation on the femur [3–6].

5.5.2. Joint-line height

In revision surgery, the joint-line is classically supposed to lie about 25 mm distal to the medial epicondyle and/or 10 mm proximal to the head of the fibula [17]. Primary temporary reduction, as described above, enables the individual native joint-line level to be restored [3–6]. Once this reduction has been achieved and stabilized using reduction clamps, a mark is made on the proximal femur using electric cautery and the distance between the mark

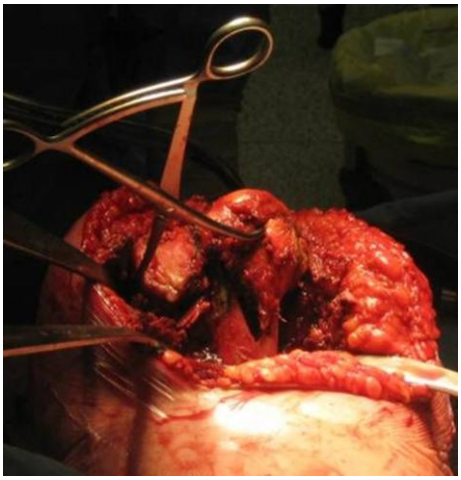

Fig. 8. Principle of primary temporary reduction.

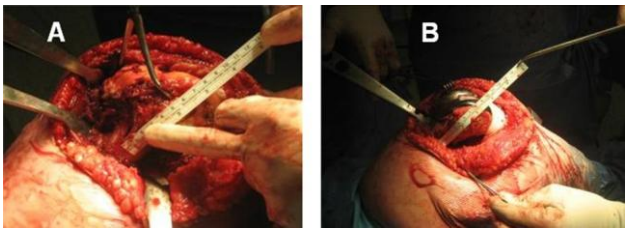

Fig. 9. A. Once this reduction has been achieved and stabilized by reduction clamps, a mark is made on the proximal femur using an electric cautery and a ruler measures the distance between the mark and the native joint-line. B. This distance will then be used for femoral reconstruction.

and the native joint-line is measured using a ruler (Fig. 9) [3–6]. This distance will then be used for femoral reconstruction [3–6].

The level of the tibial cut in the non-fractured epiphysis is easy to determine, as for a primary prosthesis, and this cut can be performed using a classical cutting jig sliding on the intramedullary stem of the conventional ancillary instrumentation [21].

5.5.3. Implant rotation

In complex femoral fracture, the rotation of the future femoral implant can be hard to determine [3–6]. As for determination of joint-line level, we recommend taking the native femoral rotation as reference [3–6]. This can be done after temporary primary reduction, marking the femoral shaft axis with an electric cautery to indicate epiphyseal-metaphyseal rotation (Fig. 10) [3–6]. This mark serves as a landmark for rotation during trials and for the definitive implantation [3–6].

Even in cases of complex fracture of the tibial plateau, tibial rotation should be determined based on the remaining classical bony landmarks, and notably the tibial tubercle, while ensuring congruence with the femoral component in extension.

5.5.4. Femoral component size

In complex femoral fracture, the classical femoral component measurement instruments may be unusable, due to articular comminution [3–6]. In such a case, we recommend using the technique used for hip hemi-arthroplasties: measuring one of the native condyles with a caliper and selecting the corresponding femoral implant (Fig. 11) [3–6].

5.5.5. Bone defect filling, or reconstruction implant?

As in TKA revision and beyond classic classifications, two types of defect can be considered: segmental defects, reconstructed using

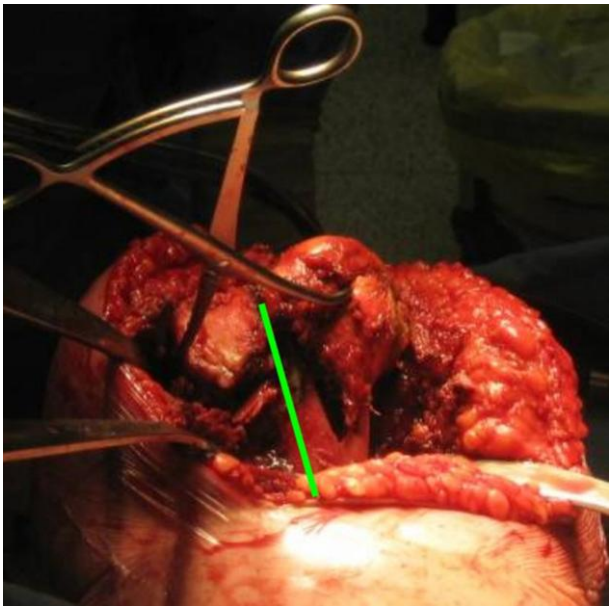

Fig. 10. Like for determining joint-line level, we recommend taking the native femoral rotation as reference. This can be done after temporary primary reduction, marking the femoral shaft with an electric cautery to indicate epiphyseal-metaphyseal rotation (shown in green).

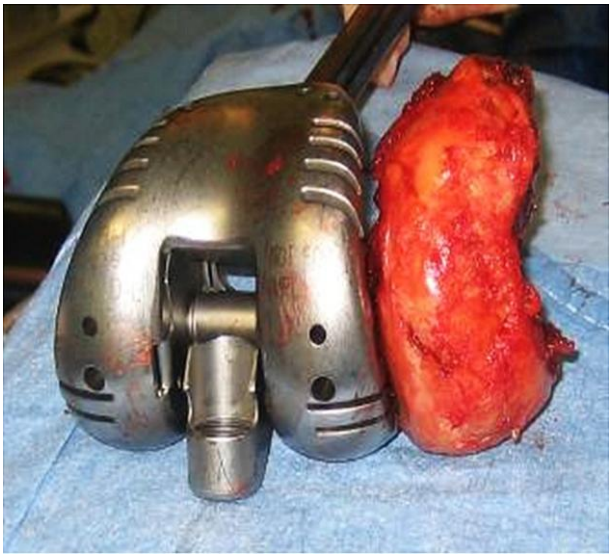

Fig. 11. In complex femoral fracture, the classical femoral component measurement instruments may be unusable, due to joint comminution. In such a case, we recommend the technique used for bipolar implants for femoral neck fractures: measuring one of the native condyles with a caliper and selecting the corresponding femoral implant (A and B).

structural graft [17], and cavitary defects [17], reconstructed using a bone cavity filling method. Various types of graft can be used, depending on the surgeon's habits, and should be included in the preoperative planning.

In our own experience, porous tantalum cones are particularly adapted when a conventional implant is used [17]. In these osteoporotic patients, it is important to find a reliable metaphyseal support, which can be obtained with these cones or other metallic reconstruction systems [17,23,24]. The techniques are those described for prosthetic revision with severe segmental bone defect (Fig. 12) [17,23,24].

The ultimate stage of segmental bone defect is complete metaphyseal and epiphyseal destruction in severely comminuted

Fig. 12. In these osteoporotic patients, it is important to find a reliable metaphyseal support using either tantalum cones and/or metaphyseal sleeves. The techniques are those described for prosthetic revision with severe segmental bone defect, using double cones on the femoral side and tibial cones, as in this example.

Fig. 13. The ultimate stage of segmental bone defect is complete metaphyseal and epiphyseal destruction in severely comminuted fracture, in which case a segmental implant may be needed.

fracture, in which case a tumor prosthesis may be needed (Fig. 13) [20]. In case of major destruction in such fragile elderly patients, reconstruction by a tumor prosthesis is more reasonable and reliable, as it allows immediate weight-bearing, than complex reconstruction using a double cone and complementary internal fixation, which is a long and hemorrhagic procedure with uncertain outcome, as bone fragility precludes immediate postoperative full weight-bearing [3–6,21].

5.6. Principles of implant fixation

The principles are those of prosthetic revision [18]. We recommend applying the principles described by Morgan-Jones et al. [18], with 3 zones of fixation: epiphyseal, metaphyseal, and diaphyseal. To be reliable, fixation should involve at least 2 of the 3 zones (Fig. 14) [18].

The literature reports no superiority between a long uncemented stem with diaphyseal engagement and a shorter cemented stem in revision TKA (Fig. 15) [24]. The current trend, however, favors fully cemented stems, but with a short stem associated to

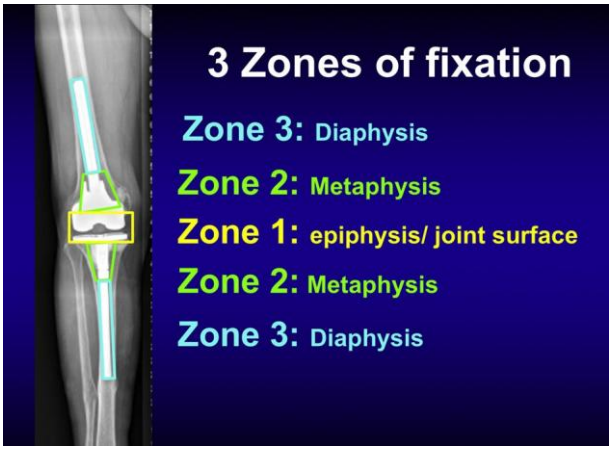

Fig. 14. The principles are those of prosthetic revision [18]. We recommend applying the principles described by Morgan-Jones et al., [18], with 3 zones of fixation: zone 1: epiphyseal; zone 2: metaphyseal; and zone 3: diaphyseal. To be reliable, fixation should involve at least 2 of the 3 zones.

Fig. 15. The literature reports no superiority between a long uncemented stem for diaphyseal fixation and a shorter cemented stem for prosthetic revision. The current trend, however, favors short fully cemented stems associated to metaphyseal reconstruction using a cone or a sleeve, to optimize control of rotational stress and avoid stem tip pain.

metaphyseal reconstruction using a cone or a sleeve to optimize the metaphyseal reconstruction. This concept optimizes the control of rotational stress and avoids pain at the end of the stem [24].

Thus, long stems are used for trials, to control alignment as described by Vince [21], whereas the definitive stem is short and fully cemented [24]. In TKA for acute fracture, the technique should be adapted to osteoporosis and the frequently tubular femoral anatomy of elderly patients, enabling immediate resumption of weight-bearing.

When a tumor prosthesis is used, the stem should be long and fully cemented, to optimize the stability [20].

5.7. Complementary internal fixation

The decision to perform complementary internal fixation is taken at end of procedure and is also important, due to

Fig. 16. In these complex fractures, diaphyseal extension of the metaphyseal fracture is frequent and should not be ignored during underlying metaphyseal reconstruction. Lucky-wire cerclage associated to cemented stem fixation allows immediate resumption of weight-bearing and reduces the risk of periprosthetic fracture.

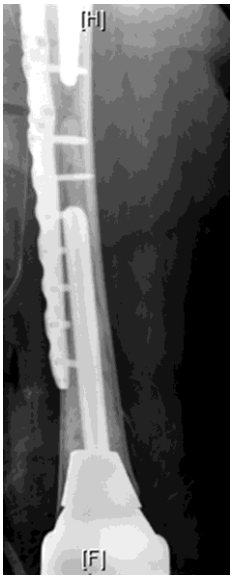

Fig. 17. Ipsilateral hip prostheses lead to a risk of interprosthetic fracture in the bone segment between the two stems, which could become a dramatic complication. Internal fixation using a plate is recommended, to bridge the area between the TKA and THA stems for a length at least twice the diameter of the diaphysis.

sudden changes in bone elasticity caused by prosthetic implants in osteoporotic patients. It allows immediate resumption of full weight-bearing without risk of postoperative periprosthetic fracture [3–6].

5.7.1. Underlying diaphyseal fragility

In these complex fractures, diaphyseal fracture extensions are frequent and should not be ignored during adjacent metaphyseal reconstruction. Metallic cerclages associated to cemented stem fixation allows immediate resumption of weight-bearing and reduces the risk of periprosthetic fracture (Fig. 16).

5.7.2. Limiting risk of interprosthetic fracture

Ipsilateral hip prostheses lead to a risk of interprosthetic fracture in the bone segment between the two stems, which could be a dramatic complication. Internal fixation using a plate is then recommended, to bridge the area between the TKA and THA stems for a length at least twice the diameter of the diaphysis (Fig. 17).

Key-points:

- the surgical technique is based on the basic principles of revision surgery regarding choice of implant, steps of reconstruction, bone defect filling and implant fixation;
- primary temporary reduction is an especially useful "trick" in complex femoral fracture, to determine the level of the joint-line and the femoral rotation.

6. What postoperative management is needed?

The principles of postoperative management of elderly patients apply here: remedying blood loss, preventing decubitus complications, managing anticoagulation and treating the commorbidities [16,25]. The lessons drawn from managing elderly patients undergoing surgery for femoral neck fracture are relevant, especially including teamwork between geriatric and orthopedic surgeons [16].

Pain management should be up-to-date, multimodal, avoiding morphine derivatives so far as possible. A combination of local injection at end of surgery and the use of an adductor canal catheter is particularly effective [25].

The main issue is resumption of full weight-bearing, which should be immediate whenever possible. For this, surgical technique respecting the above reconstruction principles is crucial:

- performing optimized metaphyseal reconstruction using tantalum cones and short cemented stems with complementary internal fixation, as for revision TKA procedures, allows immediate resumption of weight-bearing [3–6,23,24];
- tumor prostheses also allow immediate resumption of full weight-bearing [20].

Key-points:

- the classical principles of multidisciplinary postoperative management, including geriatricians, apply: remedying blood loss, preventing decubitus complications, managing anticoagulation, and treating comorbidities;
- current reconstruction techniques allow immediate resumption of weight-bearing in most cases.

7. What are the expected results?

Results for first-line arthroplasty for fracture are encouraging, and notably better than for arthroplasty secondary to failure of conservative treatment such as internal fixation [3–6]. In both cases, however, studies hade short follow-up and often small series [3–6]. Complications rates of TKAs for recent fractures range between 8% and 42%; revision rates are low, and functional results are usually satisfactory [3–6]. In secondary post-traumatic TKAs, complications rates range between 20% and 48%, implant revision rates range between 8% and 20%, and functional results are satisfactory in only 75% of cases [3–6].

In these often fragile patients, there are also general complications potentially related to 3 successive operations (internal fixation, hardware removal, then TKA implantation) and a period of non-weight-bearing or protected weight-bearing following the internal fixation [3–6].

The French Hip and Knee Society (SFHG)'s multicenter series of TKA for acute fracture is the largest published to date [6], with 26 patients (21 female, 5 male), mean age 80.5 years, and mean ASA score 2.2:

- there were 2 local complications: 1 skin complication, and 1 anterior tibial tubercle avulsion [6], in agreement with previous reports [3–6]. Anterior tibial tubercle avulsion in fracture, sometimes considered as a contraindication for TKA, should be carefully screened for on the preoperative CT. The fracture might extend intraoperatively, resulting in complication [3–6];
- no implant revisions were needed;
- one patient died; 1 showed cardiac complications and 3 showed deep venous thrombosis, including 1 complicated by pulmonary embolism. Thus, general complications were predominant, again in agreement with the literature [3–6], confirming the need for geriatric medical management;
- functional results were satisfactory, with good recovery of range of motion. However, Parker score [26] decreased by a mean 1.7 points, and results were poorer in case of low preoperative Parker score.

The most recent published series is a French retrospective study of 21 TKAs in patients with a mean age of 79 years [5]. Mean time to surgery was 3.9 days [5]. The local complications rate was 9% (1 case of stiffness, 1 infection managed without implant exchange), which is comparable with other reports [3–6]. Functional results were also comparable with the literature, but with a mean 2-point decrease in Parker score, which was greater than in the French multicenter series [3–6]. The authors were the first to report 1-year mortality [5], which was 14% for the series as a whole and 30% in case of femoral fracture, comparable to the rate observed after femoral neck fracture [3–6]; this is a key-point for informing the patient and family, as for fractures of the proximal femur [3–6].

In our series, awaiting publication, of 23 cases with a mean age of 78 years, results were similar in terms of complications and function. A key-point in the present series is the comparison between two techniques in femoral fracture with severe metaphyseal destruction:

- tumor prosthesis;
- rotating-hinge prosthesis with double-cone bone defect reconstruction.

Comparison of surgery time and blood loss was very much in favor of the segmental prosthesis, without increased complications and with systematic resumption of weight-bearing, compared to only 75% of cases after complex metaphyseal reconstruction. The segmental prosthesis procedure was thus technically simpler, quicker and more reliable in case of massive destruction of the distal femur.

Key-points:

- results in first-line arthroplasty for fracture are encouraging, and better than in arthroplasty secondary to failure of conservative treatment, with lower revision and complications rates, earlier resumption of weight-bearing, and better functional results.

8. Conclusion

Reconstruction using TKA in case of complex articular fracture of the knee is an interesting surgical option, limiting the number of surgeries while meeting two imperatives:

- saving the patient's life, thanks to early resumption of weight-bearing, limiting the decubitus complications;
- saving function, thanks to immediate unrestricted joint mobilization, limiting loss of autonomy.

Results in the literature confirm the benefit of this attitude. Multidisciplinary perioperative management is essential in elderly patients.

The surgical technique requires excellent knowledge and experience of the principles of prosthetic revision. It is complex, and should be performed on a delayed emergency basis, to optimize planning and logistic preparation.

Published series are as yet limited, due to the rarity of these fractures and less widespread awareness of this approach; better definition of indications and principles should extend experience and further improve results.

Disclosure of interest

S. Parratte reports personal fees from Medical education and consultant for ZimmerBiomet, personal fees from Consultant for Stryker, personal fees from Medical education and consultant for Arthrex, personal fees from Consultant for Graftys, outside the submitted work. J.N. Argenson and M. Ollivier have no conflict of interest for the current work. J.N. Argenson has royalties from ZimmerBiomet ans Symbios. M. Ollivier reports personal fees for medical education and consultant for Stryker and Arthrex.

References

[1] Obert L, Saadnia R, Tournier C, Bonnevialle N, Saragaglia D, Sirveaux F, La SOFCOT. Four-part fractures treated with a reversed total shoulder prosthesis: prospective and retrospective multicenter study. Results and complications. Orthop Traumatol Surg Res 2016;102:279–85.
[2] Bonnevialle P, Feron JM. Fractures of the over 80 years old. Rev Chir Orthop Reparatrice Appar Mot 2003;89(suppl 5):S129–82.
[3] Bohm ER, Tufescu TV, Marsh JPJ. The operative management of osteoporotic fractures of the knee: to fix or replace? Bone Joint Surg Br 2012;94:1160–9.
[4] Ries MD. Primary arthroplasty for management of osteoporotic fractures about the knee. Curr Osteoporos Rep 2012;10:322–7.
[5] Boureau F, Benad K, Putman S, Dereudre G, Kern G, et al. Does primary total knee arthroplasty for acute knee joint fracture maintain autonomy in the elderly? A retrospective study of 21 cases. Orthop Traumatol Surg Res 2015;101:947–51.
[6] Parratte S, Bonnevialle P, Pietu G, Saragaglia D, Cherrier B, Lafosse JM. Primary total knee arthroplasty in the management of epiphyseal fracture around the knee. Orthop Traumatol Surg Res 2011;97(6 Suppl):S87–94.
[7] Court-Brown CM, Caesar B. Epidemiology of adult fractures: a review. Injury 2006;37:691–7.
[8] Wolfgang GL. Primary total knee arthroplasty for intercondylar fracture of the femur in a rheumatoid arthritic patient. A case report. Clin Orthop Relat Res 1982;171:80–2.
[9] Bell KM, Johnstone AJ, Court-Brown CM, Hugues SP. Primary knee arthroplasty for distal femoral fractures in elderly patients. J Bone Joint Surg Br 1992;74:400.
[10] Rolston LR, Christ DJ, Halpern A, O'Connor PL, Ryan TG, Uggen WM. Treatment of supracondylar fractures of the femur proximal to a total knee arthroplasty. A report of four cases. J Bone Joint Surg Am 1995;77:924–31.
[11] Yoshino N, Takai S, Watanabe Y, Fujiwara H, Ohshima Y, Hirasawa Y. Primary total knee arthroplasty for supra condylar/condylar femoral fracture in osteoarthritic knee. J Arthroplasty 2001;16:471–5.
[12] Nau T, Pflegerl E, Erhart J, Vecsei V. Primary total knee arthroplasty for periarticular fractures. J Arthroplasty 2003;18:968–71.
[13] Killian U. Total knee replacement for primary treatment of intra-articular head fractures in elderly patients. Unfallchirurg 2003;106:1046–50.
[14] Rosen AL, Strauss E. Primary total knee arthroplasty for complex distal femur fractures in elderly patients. Clin Orthop 2004;425:101–5.
[15] Nourissat G, Hoffman E, Hémon C, Rillardon L, Guigui P, Sautet A. Total knee arthroplasty for recent severe fracture of the proximal tibial epiphysis in the elderly subject. Rev Chir Orthop Reparatrice Appar Mot 2006;92:242–7.
[16] Folbert EC, Hegeman JH, Vermeer M, Regtuijt EM, van der Velde D, Ten Duis HJ, et al. Improved 1-year mortality in elderly patients with a hip fracture following integrated orthogeriatric treatment. Osteoporos Int 2017;28:269–77.
[17] Huten D. Femorotibial bone loss during revision total knee arthroplasty. Orthop Traumatol Surg Res 2013;99(1 Suppl):S22–33.
[18] Morgan-Jones R, Oussedik SI, Graichen H, Haddad FS. Zonal fixation in revision total knee arthroplasty. Bone Joint J 2015;97-B(2):147–9.

[19] Appleton P, Moran M, Houshian S, Robinson CM. Distal femoral fractures treated by hinged total knee replacement in elderly patients. J Bone Joint Surg 2006;88B:1065–70.
[20] Pearse EO, Klass B, Bendall SP, Railton GT. Stanmore total knee replacement versus internal fixation for supracondylar fractures of the distal femur in elderly patients. Injury 2005;36:163–8.
[21] Vince KG. A step-wise approach to revision TKA. Orthopedics 2005;28:999–1001.
[22] Irisson E, Hémon Y, Pauly V, Parratte S, Argenson JN, Kerbaul F. Tranexamic acid reduces blood loss and financial cost in primary total hip and knee replacement surgery. Orthop Traumatol Surg Res 2012;98:477–83.
[23] Girerd D, Parratte S, Lunebourg A, Boureau F, Ollivier M, Pasquier G, et al. Total knee arthroplasty revision with trabecular tantalum cones: Preliminary retrospective study of 51 patients from two centres with a minimal 2-year follow-up. Orthop Traumatol Surg Res 2016;102:429–33.
[24] Parratte S, Abdel MP, Lunebourg A, Budhiparama N, Lewallen DG, Hanssen AD, et al. Revision total knee arthroplasty: the end of the allograft era? Eur J Orthop Surg Traumatol 2015;25:621–2.
[25] Canata GL, Casale V, Chiey A. Pain management in total knee arthroplasty: efficacy of a multimodal opiate-free protocol. Joints 2017;4:222–7.
[26] Parker MJ, Palmer CR:. A new mobility score for predicting mortality after hip fracture. J Bone Joint Surg Br 1993;75:797–8.