



HAL
open science

Intrafollicular Steroids and Anti-Müllerian Hormone During Normal and Cystic Ovarian Follicular Development in the Cow1

Danielle Monniaux, Nathalie Di Clemente, Jean-Luc Touze, Corinne Belville, Charlène Rico, Martine Bontoux, Jean-Yves Picard, Stéphane Fabre

► To cite this version:

Danielle Monniaux, Nathalie Di Clemente, Jean-Luc Touze, Corinne Belville, Charlène Rico, et al.. Intrafollicular Steroids and Anti-Müllerian Hormone During Normal and Cystic Ovarian Follicular Development in the Cow1. *Biology of Reproduction*, 2008, 79 (2), pp.387 - 396. <10.1095/biolreprod.107.065847>. <hal-01930567>

HAL Id: hal-01930567

<https://hal.science/hal-01930567v1>

Submitted on 31 May 2020

HAL is a multi-disciplinary open access archive for the deposit and dissemination of scientific research documents, whether they are published or not. The documents may come from teaching and research institutions in France or abroad, or from public or private research centers.

L'archive ouverte pluridisciplinaire **HAL**, est destinée au dépôt et à la diffusion de documents scientifiques de niveau recherche, publiés ou non, émanant des établissements d'enseignement et de recherche français ou étrangers, des laboratoires publics ou privés.



HAL Authorization

Intrafollicular Steroids and Anti-Müllerian Hormone During Normal and Cystic Ovarian Follicular Development in the Cow¹

Danielle Monniaux,^{2,3} Nathalie di Clemente,⁴ Jean-Luc Touzé,³ Corinne Belville,⁴ Charlène Rico,³ Martine Bontoux,³ Jean-Yves Picard,⁴ and Stéphane Fabre³

*Physiologie de la Reproduction et des Comportements,*³ UMR 6175, INRA-CNRS-Université de Tours-Haras Nationaux, 37380 Nouzilly, France

*Endocrinologie et Génétique de la Reproduction et du Développement,*⁴ UMR 782, INSERM-Université Paris Sud, 92 140 Clamart, France

ABSTRACT

Development of follicular cysts is a frequent ovarian dysfunction in cattle. Functional changes that precede cyst formation are unknown, but a role for anti-Müllerian hormone (AMH) in the development of follicular cysts has been suggested in humans. This study aimed to characterize intrafollicular steroids and AMH during follicular growth in a strain of beef cows exhibiting a high incidence of occurrence of follicular cysts. Normal follicular growth and cyst development were assessed by ovarian ultrasonography scanning during the 8 days before slaughtering. Experimental regression of cysts was followed by rapid growth of follicles that reached the size of cysts within 3–5 days. These young cysts exhibited higher intrafollicular concentrations of testosterone, estradiol-17 β , and progesterone than large early dominant follicles did in normal ovaries, but they exhibited similar concentrations of AMH. Later-stage cysts were characterized by hypertrophy of theca interna cells, high intrafollicular progesterone concentration, and high steroidogenic acute regulatory protein mRNA expression in granulosa cells. Progesterone and AMH concentrations in the largest follicles (≥ 10 mm) and cysts were negatively correlated ($r = -0.45$, $P < 0.01$). Smaller follicles (< 10 mm) exhibited higher intrafollicular testosterone and estradiol-17 β concentrations in ovaries with cysts compared to normal ovaries. During follicular growth, AMH concentration dropped in follicles larger than 5 mm in diameter and in a similar way in ovaries with and without cysts. In conclusion, enhanced growth and steroidogenesis in antral follicles < 10 mm preceded cyst formation in cow ovaries. Intrafollicular AMH was not a marker of cystic development in the cow, but low AMH concentrations in cysts were associated with luteinization.

anti-Müllerian hormone, follicle, follicular development, ovary, steroid hormones

INTRODUCTION

In cattle, terminal development of ovarian follicles is characterized by 2 or 3 FSH-induced “waves” of antral follicle

growth that occur at 7- to 10-day intervals during each estrous cycle [1–4]. During each wave, synchronous growth of a cohort of 3- to 5-mm antral follicles is followed by selection and development of a single dominant follicle and concomitant atresia of the remaining follicles in the original cohort [5]. The dominant follicle that has reached an ovulatory size (15–20 mm) will either ovulate in a permissive hormonal environment or regress by atresia in the period of luteal progesterone secretion or during early pregnancy [6, 7]. However in some cases, the dominant follicle fails to ovulate or regress, but continues to grow into an ovarian follicular cyst. Cysts have been defined as large thin-walled follicular structures that do not ovulate but persist for at least 10 days in the absence of a corpus luteum [8]. Waves of follicular growth still occur in cows with cysts, but intervals between waves may be longer or more irregular [9]. Affected cows are generally infertile as long as cysts remain functional. Formation of follicular cysts is a frequent ovarian dysfunction and a major cause of reproductive failure in cattle (for review, see [10]).

The exact pathogenesis of bovine follicular cysts is unclear. It is generally accepted that disruption of the hypothalamo-pituitary-gonadal axis by endogenous and/or exogenous factors, leading to aberrant secretion of LH, causes cyst formation [9, 11, 12]. At the ovarian level, cellular and molecular changes in the growing follicle may contribute to anovulation and cyst formation. Particularly, alterations in follicular steroidogenesis and LH receptor expression have been reported in bovine follicular cysts when compared to dominant follicles [13, 14]. However, studying follicular changes prior to cyst formation remains difficult. In cows with cysts, early functional changes in the growing follicles of the cohort that precede formation of cysts are unknown.

A role for anti-Müllerian hormone (AMH; also called Müllerian-inhibiting substance) in the formation and development of follicular cysts has been recently proposed in women with polycystic ovary syndrome (PCOS). Human follicular cysts exhibit high intrafollicular concentration of AMH [15], and production per granulosa cells is 75 times higher in anovulatory PCOS compared with normal ovaries, suggesting that AMH may contribute to failure of follicle growth and ovulation seen in PCOS [16]. Justified or not, follicular cysts in cow have often been compared to human PCOS. AMH is a member of the transforming growth factor β family, expressed only in the gonads, that exerts inhibitory effects on the development and function of reproductive organs (for review, see [17, 18]). In the ovary of numerous species, AMH expression is restricted to the granulosa cell layers (bovine [19, 20]; sheep [21]; rat [22–24]; human [25, 26]; and mouse [27, 28]). Studies in rodents have established that AMH inhibits differentiation and steroidogenesis of the immature ovary [29,

¹Supported by the special funding “Crédits fléchés” of the INRA PHASE Department and the European contract SABRE C7-2006-001625.

²Correspondence: Danielle Monniaux, Physiologie de la Reproduction et des Comportements, UMR 6175, INRA-CNRS-Université de Tours-Haras Nationaux, Centre INRA de Tours, 37380 Nouzilly, France. FAX: 33 47 42 77 43; e-mail: monniaux@tours.inra.fr

Received: 28 September 2007.
First decision: 5 November 2007.
Accepted: 14 April 2008.

© 2008 by the Society for the Study of Reproduction, Inc.
ISSN: 0006-3363. <http://www.biolreprod.org>

30], primordial follicle recruitment [31, 32], and FSH-stimulated growth of preantral follicles [33]. These observations strongly suggest that AMH is a dominant regulator of early follicular growth. In contrast, the importance of AMH in controlling terminal follicular development is not fully understood. *In vitro* studies have shown clear inhibitory effects of AMH on *CYP19A1* and *LHCGR* expression in FSH-stimulated rat and pig granulosa cells of antral follicles [34], and on progesterone secretion by human luteinized granulosa cells [35]. Limited data are available concerning intrafollicular concentrations of AMH. In humans, follicular fluid from preovulatory follicles contains low levels of AMH [36–39]. This concentration is increased in follicular fluid of women with PCOS [15, 16]. In the bovine species, a role of AMH in controlling terminal follicular development has not been investigated, and there is no data available concerning AMH levels during development of large antral follicles and follicular cysts.

The present study aimed to determine concomitant changes in steroids and AMH in individual follicles studied at different stages of their normal or cystic development, assessed by daily transrectal ultrasonography, in beef cows exhibiting a high incidence of occurrence of ovarian follicular cysts.

MATERIALS AND METHODS

Animals

Experimental animals originated from a strain of Maine-Anjou beef cows that were linebred for twinning (present twinning rate: 27%; present double ovulation rate of cows: 47%). In this strain, the incidence of occurrence of follicular cysts has not been evaluated with accuracy in animals with natural or synchronized cycles, but it was unexpectedly high (>40%) for several months after administration of a standard gonadotropin treatment used to superovulate animals for embryo production. After calf weaning and gonadotropin treatment administration for embryo production, 21 animals from this strain were transported to our local experimental unit. They were then bred without any hormonal treatment for 4–6 mo before study. Animals were housed in free stalls and provided feed and water *ad libitum*. Experiments were conducted during the fall of 2005 and 2006. All procedures were approved by the French Department of Veterinary Services (approval number C37-175-2) and conducted in accordance with the guidelines for Care and Use of Agricultural Animals in Agricultural Research and Teaching.

Experimental Design and Ultrasound Scanning

Animals were treated with two intramuscular injections of 15 mg of prostaglandin PGF₂ α (Prosolvin, Intervet, Angers, France) spaced 11 days apart with the aim of inducing luteolysis in cows with corpora lutea on ovaries (cows without follicular cysts) and synchronizing the occurrence of estrus. From the day of the second injection (D0) to the day of slaughtering (D8), ovarian follicular growth and occurrence of ovulation were followed by daily ultrasound scanning with a sectorial transrectal probe (7.5 MHz transducer; Combison 310A Kretztechnik, Zipf, Austria) that allowed for the detection and measurement of follicles larger than 2 mm diameter. Each ovary was scanned from end to end to identify the positions of the corpora lutea and ≥ 3 mm antral follicles. Video images for different ovarian sections were captured on a computer. The locations of each follicle were drawn on an ovarian map, and approximate diameters were indicated. Images were analyzed subsequently to set up follicular diameters with accuracy and reconstitute individual follicular growth curves between D0 and D8. Mean daily growth rate of each follicle larger than 10 mm at slaughtering was estimated by calculating the slope of the regression line between follicular diameter and time from the moment of its detection to D8.

The diagnosis of follicular cysts on ovaries was based on the presence of follicular structures larger than 15 mm diameter at D0 that did not ovulate or regress spontaneously between D0 and D8. These structures were called cysts (C). Among the 21 studied animals, 11 had follicular cysts on ovaries. Existence of cyst turnover has been shown in cow ovaries, and growth of new follicles in cows with cysts often results in the development of one or several new cysts [9, 14]. In some cows with cysts ($n = 5$), cyst turnover was studied following cyst regression induced at D1 or D2 either by a manual process, i.e., follicular puncture and aspiration of follicular fluid of cysts ($n = 2$ cows), or by hormonal treatment, i.e., an injection of 0.02 mg busereline acetate, a GnRH analogue

(Intervet, France; $n = 3$ cows). Both treatments were followed by growth of new follicular structures that reached a size larger than 15 mm diameter within 3 to 5 days. These follicular structures were called young cysts (YC). No follicular structure larger than 15 mm diameter was present at D8 on the ovaries of the 10 cows diagnosed as normal (without cysts). Follicular growth rates were measured by ultrasonography, and the diameters at slaughtering were compared between large follicles ($n = 18$) on normal ovaries of 9 cows and young cysts ($n = 11$) and cysts ($n = 11$) on ovaries of 8 cows with follicular cysts.

Samples Collection

At slaughtering, all the follicles larger than 3 mm diameter and cysts were dissected, their diameters were measured, and follicular fluids from follicles larger than 5 mm diameter and cysts were recovered individually and stored at -20°C until they were studied. For follicles 3–5 mm in diameter, due to their small size, the recovered follicular fluids for each cow were pooled. Granulosa cells were recovered from small (S, 3–4.5 mm), medium (M, 5–9.5 mm), and large (L, 10–14.5 mm) follicles and cysts (YC and C) of 19 cows, as previously described [40]. Cells were pooled for each cow according to the size of follicles, and then cells from S, M, and L follicles and YC were cultured for 48 h for thymidine incorporation measurements as described below. When possible, the remaining cells not used for *in vitro* culture were immediately centrifuged ($300 \times g$ for 7 min), and the cell pellets were stored at -20°C until RNA extraction. Large follicles ($n = 2$), YC ($n = 2$), and C ($n = 1$) recovered from 4 cows were fixed in Bouin fixative, embedded in paraffin, sectioned at 7 μm , and stained with hematoxylin before microscopic analysis.

Thymidine Incorporation Assay

Granulosa cells were recovered and cultured in McCoy 5A medium (Sigma, L'Isle d'Abeau Chesnes, France) according to a previously described method [41]. Cells were seeded at 100 000 viable cells/well in 48-well plates and cultured at 37°C with 5% CO_2 in the presence of 3% fetal bovine serum, with or without insulin-like growth factor-1 (IGF1, 10 or 100 ng/ml; Ciba-Geigy, Saint-Aubin, Switzerland). Cells were incubated for 24 h with [³H]thymidine (0.1 μCi /well; Dupont De Nemours, Les Ulis, France) added after 24 h of culture. At the end of the incubation, cells were washed twice with culture medium, lysed with 0.1 M NaOH, and the incorporated radioactivity was measured by liquid scintillation counting. Each condition was tested in triplicate in each granulosa cell culture. In additional culture wells, granulosa cells were seeded in duplicate and cultured for 48 h in the different tested conditions for estimation of cell plating. At the end of the culture, cells were detached with Accutase (Sigma, L'Isle d'Abeau Chesnes, France). An aliquot of each suspension was counted using a hemocytometer under a phase-contrast microscope to estimate the total number of cells per well. Thymidine incorporation by granulosa cells was expressed in cpm/50 cells/24 h. In a validation study with S, M, and L follicles from three cows, the labeling index (percent of thymidine-labeled granulosa cells) measured after autoradiography and microscopic analysis [40] was found to be highly correlated with the amount of thymidine incorporated in granulosa cells ($r = 0.91$, $P < 0.0001$, $n = 33$). [³H]Thymidine incorporation by granulosa cells was compared between L follicles ($n = 15$) from the normal ovaries of 8 cows and YC ($n = 7$) from the ovaries of 7 cows with follicular cysts under control and IGF1-stimulated conditions. [³H]Thymidine incorporation by granulosa cells of S and M follicles was also compared between normal ovaries ($n = 8$ cows) and ovaries with follicular cysts ($n = 7$ cows).

Hormonal Assays

Follicular fluids ($n = 180$) were measured for estradiol-17 β , progesterone, testosterone, and AMH. The methods used for follicular steroid assays were adapted from assays of plasma samples with extraction. Thirty microliters of follicular fluid was diluted with 1 ml distilled water, extracted with 3 ml ethyl acetate-cyclohexane (v/v); the dried extracts containing steroids were recovered in 1 ml PBS and then measured by RIA. The percentage of steroid recovery varied between 88% and 92%. Each sample was measured in duplicate. Estradiol-17 β was measured with the estradiol-2 RIA kit following the manufacturer specification (Diasorin SA, Antony, France). The antiserum of the kit cross-reacted slightly with oestrone (0.6%), oestriol (0.6%), and less so with other steroids (<0.1%). The limit of detection of the assay was 0.08 pg per tube. Progesterone and testosterone assays were measured as already described [42, 43]. For the progesterone assay, the antiserum cross-reacted with 20-hydroxyprogesterone (1.7%) and less so with other steroids (<1%). The limit of detection of the assay was 12 pg per tube. For the testosterone assay, the antiserum cross-reacted with 5 α -dihydrotestosterone (65%), 5 β -dihydrotestosterone (49.5%), androstenedione (0.7%), and less so with other steroids (<0.1%). The limit of detection of the assay was 6 pg per tube.

AMH was measured with the Active MIS/AMH ELISA kit (DSL, Cergy-Pontoise, France). This kit is an enzymatically amplified two-site immunoassay, providing materials for the quantitative measurement of AMH in human serum. It has been recently used in other species to study changes in serum AMH during aging in the mouse [44] and the rat [45]. For validation of the assay in bovine species, serial dilutions of different bovine follicular fluids were analysed using the kit. Results showed that the follicular fluid dilution curves were linear and parallel to the standard curve (Fig. 1). Moreover, AMH was undetectable in bovine serum from castrated animals. The limit of detection of the assay was found to be 1 pg per well.

Reverse Transcription and Quantitative Polymerase Chain Reaction

Total RNA were extracted from granulosa cell samples with the RNAsol solution (Eurobio, Les Ulis, France) according to the protocol of the manufacturer and diluted at 0.5 µg/µl in RNase-free water. RNA (2 µg) was then reverse-transcribed using MMLV reverse transcriptase (200 U) in the presence of oligo(dT) (500 ng), dNTP (1 mM), and RNAsin (RNase inhibitor, 20 U) (all products from Promega, Charbonnières, France) at 42°C for 1 h.

Each PCR reaction consisted of 20 µl containing 3 µl of diluted cDNA (between 1/10 and 1/100), 3 pmol of each primer, and 10 µl of 2X IQ SYBR Green Supermix (Bio-Rad, Marnes la Coquette, France) in 96-wells plate. PCR reactions run without cDNA (water blank) on the one hand and with total RNA (non-reverse-transcribed) to check for the absence of genomic DNA contamination on the other hand served as negative controls. The real-time quantitative PCR was run on iCycler iQ Multicolor Detection System (Bio-Rad, Marnes la Coquette, France). The cycling conditions were 1 cycle of denaturation at 95°C/3min, followed by 40 three-segment cycles of amplification (95°C/30 sec, 58°C/30 sec, and 72°C/30 sec). The baseline adjustment method of the iCycler software was used to determine the Ct (cycle threshold) in each reaction. A melting curve was constructed for each primer pair to verify the presence of one gene-specific peak and the absence of primer dimer, further controlled by agarose gel migration of the amplicon. The following specific primer sequences were used for *AMH*: forward 5'-GTGGTCTGCTGCTAAAGATG-3' and reverse 5'-TCGGACAGGCTGATGAGGAG-3'; for *CYP19A1*: forward 5'-TCGTCCTGGTACCCTTCTG-3' and reverse 5'-CGGTCTCTGGTCTCGTCTGG-3'; for *CYP11A1*: forward 5'-CGGACAAGTTTGACCAACCAG-3' and reverse 5'-GGCGGAAGACAA-GGAAGATGG-3'; for *STAR*: forward 5'-ACACCATGTGGAATGTCA-GGCT-3' and reverse 5'-CACACCTTTCAACAAGCAACCC-3'; and for *RPL19*: forward 5'-AATGCCAATGCCAACTC-3' and reverse 5'-CCCTTTCGTACTATACC-3'. For each primer pair, efficiency curves were generated using serial dilutions of cDNA of granulosa cells in the abscissa and the corresponding Ct in the ordinate. The slope of the log-linear phase reflects the amplification efficiency (E) derived from the formula $E = e^{(-1/\text{slope})}$. Amplification efficiency was found to be $E_{AMH} = 1.88$, $E_{CYP19} = 1.95$, $E_{CYP11A1} = 1.95$, $E_{STAR} = 1.95$, and $E_{RPL19} = 1.95$. For quantification analysis, the Ct of target gene (*AMH* or *CYP19A1*) was compared with the internal reference gene *RPL19* encoding an ubiquitous ribosomal protein, according to the ratio $R = [E_{RPL19}]^{Ct(RPL19)} / [E_{target}]^{Ct(target)}$.

Data Analysis

All experimental data are presented as means \pm SEM. Data were analyzed using *t*-test or one-way ANOVA followed by Newman-Keuls multiple comparison tests for comparisons between two or several means, respectively. When variances were heterogeneous, data were log transformed or analysed by the nonparametric Mann-Whitney test (for comparison of two means) or the Kruskal-Wallis test (for comparison of several means). The effects of IGF1 on thymidine incorporation in granulosa cells were analysed using one-way ANOVA for repeated measures. Chi-square test was used to compare percentages in contingency tables. The coefficient of correlation of Pearson was calculated for correlation studies. For all analyses, differences with $P > 0.05$ were considered as not significant.

RESULTS

Follicular Development in Normal Ovaries and Ovaries with Follicular Cysts

In 10 of the 21 cows, the corpora lutea present on ovaries at D0 regressed following prostaglandin injection as expected, 1 or 2 ovulations were detected at D3, and new corpora lutea developed. Emergence of the first wave of follicular growth of

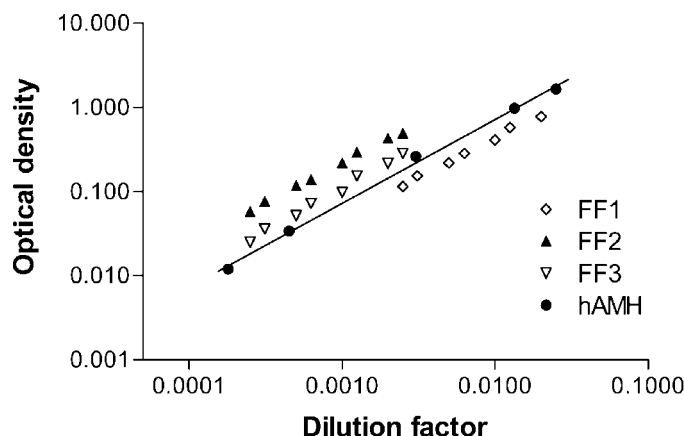


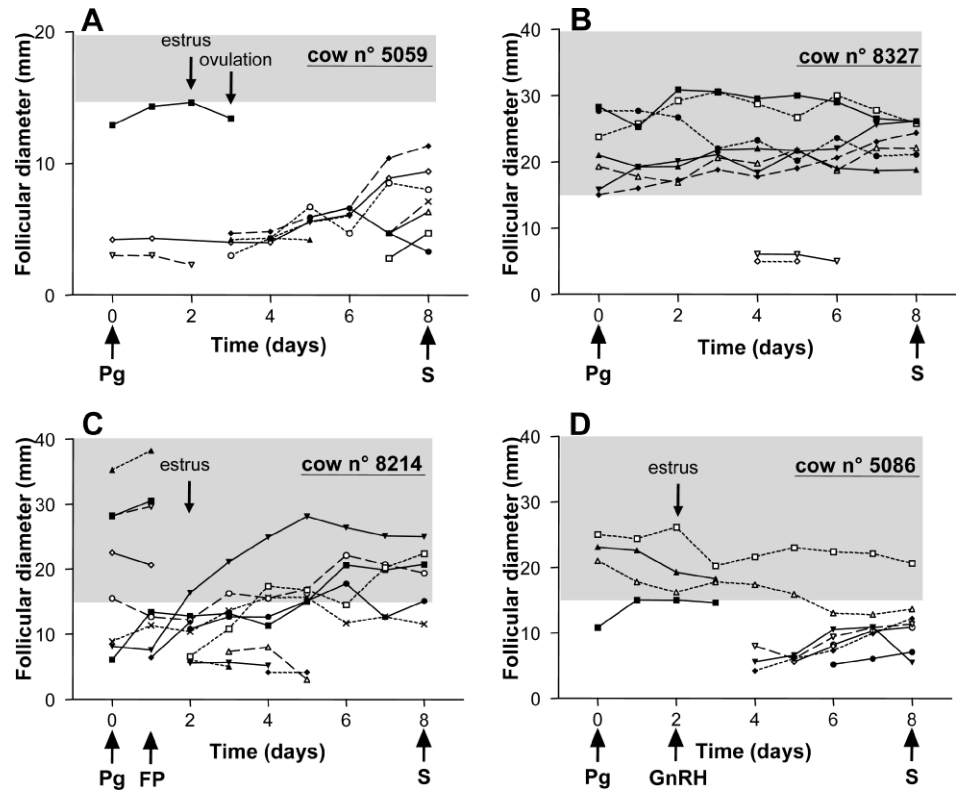
FIG. 1. Dilution curves for bovine follicular fluids and the standard curve of the AMH ELISA. Data are the results of serial dilutions of the human AMH (hAMH) standard and three different follicular fluid (FF1, FF2, and FF3) samples, measured with the Active MIS/AMH ELISA kit.

the cycle was followed by the development of one or two L follicles at D8 (Fig. 2A, cow no. 5059). This pattern of follicular development was in agreement with previous descriptions of development of dominant follicles of the first wave of follicular growth in cows with normal ovaries [46, 47]. In contrast, no corpora lutea but rather ≥ 1 C were present at D0 on the ovaries of the 11 other cows (Fig. 2, B–D). In six of these cows, C remained without ovulating or regressing on ovaries until D8 and no follicular wave clearly emerged (Fig. 2B, cow no. 8327). Experimental regression of the C in four other cows was followed by emergence of a follicular wave and rapid development of one or several YC (Fig. 2C, cow no. 8214). Incomplete regression of the cysts in one cow treated with GnRH allowed emergence of a follicular wave and development of L follicles only (Fig. 2D, cow no. 5086). At D8, after slaughtering, YC and C recovered by ovarian dissection had similar sizes ($P > 0.05$, Table 1). Normal ovaries contained higher numbers of M ($P < 0.05$) and L ($P < 0.001$) follicles than ovaries with follicular cysts (Fig. 3).

Morphological and Functional Characterization of the Largest Follicular Structures in Normal Ovaries and Ovaries with Follicular Cysts

Large follicles from normal ovaries were compared to cysts (YC and C) for their morphological and functional characteristics. Histological analysis showed morphological differences between follicular walls of L follicles, YC, and C. In L follicles from normal ovaries, multilayered granulosa with round nuclei was surrounded by layers of elongated theca interna cells in a parallel alignment with the basement membrane separating granulosa from theca (Fig. 4, A–D). In YC, granulosa cells had a normal appearance, but the basement membrane had disappeared in different places of the follicular wall, the alignment of theca cells was lost, and theca interna cells showed rounded nuclei (Fig. 4, E–H). In C, granulosa cells appeared healthy, but mitosis were rare in the granulosa layers, theca interna cells were clearly hypertrophied, and they exhibited round nuclei (Fig. 4, I–L). The granulosa layers of both L follicles and YC contained numerous cells undergoing mitosis (Fig. 4, B and F), indicative of their proliferative activity. In vitro thymidine incorporation studies showed that the proliferation rate of granulosa cells was higher in YC, compared to L follicles, in both control and IGF1-stimulated conditions (Table 1).

FIG. 2. Follicular growth in different cows with normal ovaries and ovaries with follicular cysts. **A**) Example of a cow with normal ovaries. **B**) Example of a cow with follicular cysts. **C**) Example of a cow with follicular cysts in which cyst regression was induced by follicular puncture (FP) and aspiration of follicular fluid of the cysts at D1. **D**) Example of a cow with follicular cysts in which cyst regression was induced by injection of GnRH agonist at D2. The shaded areas correspond to follicular diameters ≥ 15 mm. Each curve illustrates the growth of a single follicle. The different symbols on the curves correspond to different follicles. The day of prostaglandin injection (Pg) and slaughtering (S) are indicated in each panel and correspond to D0 and D8, respectively.



To further characterize the largest follicular structures in normal ovaries and ovaries with follicular cysts, steroid concentrations were determined in follicular fluid and mRNA levels of the steroidogenic enzymes *CYP11A1* and *CYP19A1* and the steroidogenic acute regulatory protein *STAR* were measured in granulosa cells. Estradiol-17 β ($P < 0.001$), progesterone ($P < 0.001$), and testosterone ($P < 0.05$) intrafollicular concentrations were clearly higher in YC, compared to L follicles (Fig. 5, A–C). Cysts contained the lowest testosterone intrafollicular concentration ($P < 0.01$ vs.

L follicles and $P < 0.001$ vs. YC, Fig. 5A) and lower estradiol-17 β concentration than YC ($P < 0.001$, Fig. 5B); however, they exhibited the highest progesterone concentration compared to both L follicles ($P < 0.001$) and YC ($P < 0.01$) (Fig. 5C). The percentage of follicular structures with high (>200 ng/ml) progesterone concentration was strikingly higher for cysts than for L follicles (0%, 18.2%, and 80% in L follicles, YC, and C, respectively; $P < 0.001$). Daily growth rate of all the L follicles and cysts (L + YC + C, $n = 44$) was positively correlated to estradiol-17 β ($r = 0.41$, $P < 0.01$) and testosterone ($r = 0.43$, $P < 0.01$) and negatively correlated to progesterone ($r = -0.39$, $P < 0.01$) concentration in follicular fluid. *CYP19A1*, *CYP11A1*, and *STAR* mRNA levels were not different between granulosa cells of L follicles and YC (Fig. 6, A–C). In granulosa cells of C, *CYP19A1* and *CYP11A1* mRNA levels were lower than in cells of L follicles ($P < 0.05$ for both genes) and YC ($P < 0.05$ for both genes), whereas *STAR* mRNA levels were clearly higher ($P < 0.001$ vs. L follicles and $P < 0.01$ vs. YC, Fig. 6, A–C).

AMH concentrations in follicular fluid of L follicles, YC, and C were not different ($P > 0.05$, Fig. 5D). Accordingly, in granulosa cells, *AMH* mRNA levels were not different between L follicles, YC, and C (Fig. 6D). When considering all the L follicles and cysts (L + YC + C, $n = 42$), AMH concentrations were negatively correlated with progesterone concentrations ($r = -0.45$, $P < 0.01$).

Functional Changes During Follicular Development in Normal Ovaries and Ovaries with Follicular Cysts

With the aim of investigating whether early antral follicular development was affected in ovaries with follicular cysts, 3–15 mm diameter follicles were compared to normal ovaries and ovaries with cysts. For each of the studied functional parameters, i.e., thymidine incorporation in granulosa cells, intrafollicular steroids, and AMH, no significant difference was

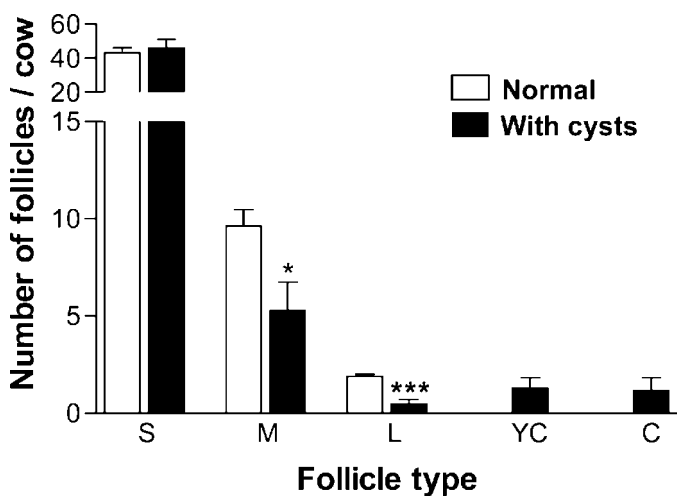


FIG. 3. Mean numbers of follicles and cysts per cow at slaughtering (D8). Follicular structures from normal ovaries of 10 cows and from ovaries with follicular cysts of 11 cows were allocated to different size classes: S (small, 3–4.5 mm), M (medium, 5–9.5 mm), L (large, 10–14.5 mm). YC (young cyst, ≥ 15 mm, developed after cyst regression), and C (later stage cyst, ≥ 15 mm, unregressed between D0 and D8). Open bars, normal ovaries; black bars, ovaries with follicular cysts (* $P < 0.05$ and *** $P < 0.001$ vs. normal ovaries).

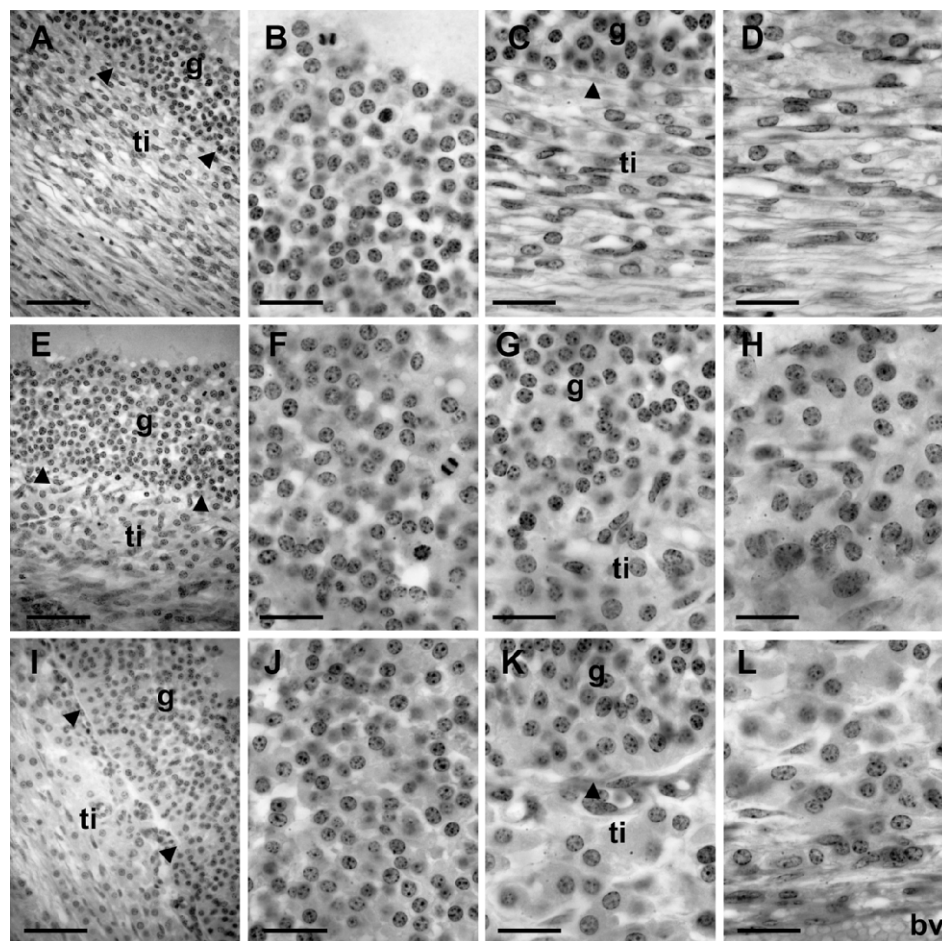


FIG. 4. Histological analysis of follicular walls of large follicles present on normal ovaries and cysts. Micrographs of a large follicle from normal ovary (A–D), a young cyst (E–H), and a later-stage cyst (I–L) show granulosa and theca layers (A, E, and I) and, at a larger magnification, granulosa cells (B, F, and J), the contact between granulosa layers and theca interna (C, G, and K), and theca cells (D, H, and L). The inner part of the follicular wall is at the top of all the micrographs. The arrowheads indicate the basement membrane separating granulosa and theca layers. g, granulosa; ti, theca interna; bv, blood vessel. Bar = 125 μ m (A, E, and I); 50 μ m (B–D, F–H, and J–L).

detected between ovaries with unregressed and regressed follicular cysts. Consequently, only two groups, normal ovaries (n = 10) and ovaries with follicular cysts (n = 11, with regressed or unregressed cysts), were compared in subsequent analyses.

For S follicles, no difference in basal thymidine incorporation by granulosa cells and in cell responsiveness to IGF1 was observed between normal ovaries and ovaries with follicular cysts (Fig. 7A). In contrast, for M follicles, IGF1 enhanced thymidine incorporation in granulosa cells from ovaries with cysts only (Fig. 7B).

In both groups, testosterone concentration in follicular fluid decreased during follicular growth (L vs. S follicles, $P < 0.01$ for normal ovaries and $P < 0.001$ for ovaries with cysts). In contrast, estradiol-17 β concentration was strongly increased in L compared to S follicles ($P < 0.001$ for both groups). Both

testosterone ($P < 0.001$) and estradiol-17 β ($P < 0.05$) concentrations were clearly higher in S follicles from ovaries with cysts compared to S follicles from normal ovaries (Fig. 8, A and B). Progesterone concentration decreased during follicular growth in normal ovaries only (L vs. S follicles, $P < 0.05$). In M follicles, a tendency to enhanced progesterone concentration was observed in ovaries with follicular cysts (Fig. 8C), and the percentage of M follicles with high (>200 ng/ml) progesterone concentration was clearly higher in these ovaries (37.8% vs. 4.8 %, ovaries with cysts vs. normal ovaries, $P < 0.001$). In granulosa cells of normal ovaries, *CYP19A1* and *CYP11A1* mRNA levels were both higher in L compared to S follicles ($P < 0.001$ and $P < 0.01$, respectively; Fig. 6, A and 6B); conversely *STAR* mRNA levels were lower in L follicles ($P < 0.001$, Fig. 6C). No difference was detected in *CYP19A1*, *CYP11A1*, and *STAR* mRNA levels in granulosa

TABLE 1. Growth features of the large follicles in normal ovaries and the cysts.

Follicle type	Follicular diameter at slaughtering (mm)	Follicular growth rate (mm/day)	[³ H]thymidine incorporation by granulosa cells (cpm/50 granulosa cells/24 h)*		
			Control	IGF1 (10 ng/ml)	IGF1 (100 ng/ml)
Normal ovaries					
Large follicles	13.6 \pm 0.3 ^a	1.35 \pm 0.52 ^a	3.68 \pm 0.54	4.35 \pm 0.70	5.46 \pm 1.12
Ovaries with cysts					
Young cysts	21.9 \pm 1.5 ^b	1.47 \pm 0.73 ^a	9.23 \pm 1.78 ^d	10.52 \pm 2.43 ^d	10.65 \pm 2.22 ^c
Cysts	24.7 \pm 1.3 ^b	0.06 \pm 0.66 ^b	ND	ND	ND

* ND, not determined.

^{a,b} Within a column, different superscript letters indicate significant differences between means ($P < 0.01$).

^{c,d} Values are significantly different vs. normal ovaries; ^c $P < 0.05$, ^d $P < 0.01$.

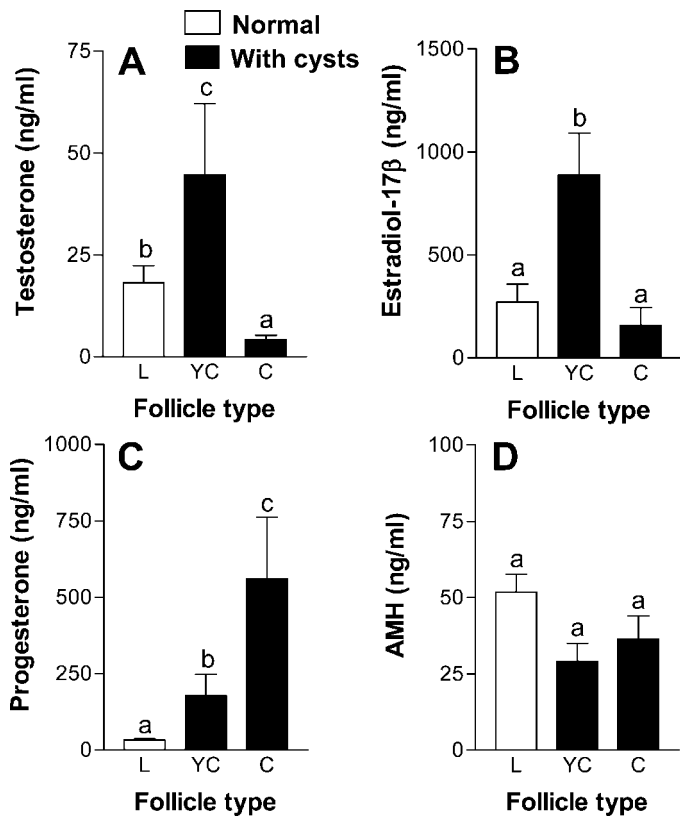
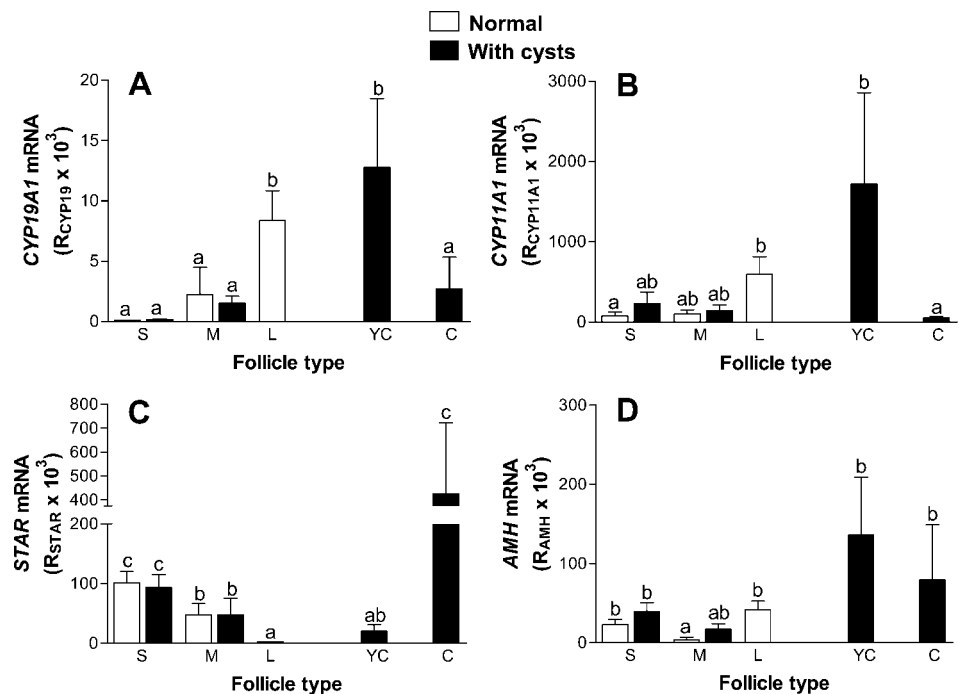


FIG. 5. Intrafollicular concentrations of steroids and AMH in the large follicles present on normal ovaries and in cysts. **A)** Testosterone. **B)** Estradiol-17 β . **C)** Progesterone. **D)** AMH. Data were obtained on L follicles ($n = 17$ follicular fluids, open bars) recovered from normal ovaries of 9 cows, YC ($n = 11$ follicular fluids, black bars), and later-stage C ($n = 11$ follicular fluids, black bars); the latter two are both recovered from ovaries of 8 cows with follicular cysts. Within each panel, different letters indicate significant differences between means resulting from multiple comparison tests between the three follicular structures. The level of significance of the differences is indicated in *Results*.

FIG. 6. *CYP19A1*, *CYP11A1*, *STAR*, and *AMH* mRNA expression in granulosa cells of follicles and cysts from normal ovaries and ovaries with follicular cysts. **A)** *CYP19A1*. **B)** *CYP11A1*. **C)** *STAR*. **D)** *AMH*. Data represent the results of reverse transcription and quantitative PCR on samples of granulosa cells of S follicles from normal ovaries ($n = 10$, open bars), S follicles from ovaries with follicular cysts ($n = 10$, black bars), M follicles from normal ovaries ($n = 7$, open bars), M follicles from ovaries with follicular cysts ($n = 7$, black bars), L follicles from normal ovaries ($n = 12$, open bars), YC ($n = 5$, black bars), and later-stage C ($n = 4$, black bars). Samples were recovered from 10 normal ovaries and 10 ovaries with follicular cysts. Within each panel, different letters indicate significant differences between means resulting from multiple comparison tests between all the studied follicular structures. The level of significance of the differences is indicated in *Results*.



cells of S and M follicles between normal ovaries and ovaries with cysts.

Intrafollicular AMH concentration decreased strongly (about 15- to 20-fold) during follicular growth in both normal ovaries and ovaries with follicular cysts (Fig. 8D, S vs. L follicles, $P < 0.001$ for both groups), with no clear variation in *AMH* mRNA levels in granulosa cells (Fig. 6B). No difference was detected in AMH concentration and *AMH* expression between normal ovaries and ovaries with follicular cysts.

DISCUSSION

Different models of induction of follicular cysts have been previously used to study the mechanisms of cyst formation in cattle, including administration of sublethal levels of progesterone during the follicular phase [48–50] and various estradiol treatments that in some studies were accompanied with high doses of progesterone [9, 11, 14, 51, 52], ACTH injections [53, 54], or removal of the corpus luteum just after ovulation [55]. In these different models, the experimental animals were mostly dairy cows. Our animal model is original since it concerns spontaneous development of cysts in beef cows.

In the studied Maine-Anjou beef cows, the presence of spontaneous cysts was observed in about 50% of the animals. This high frequency was unexpected since the incidence of anovulation (detected by rectal palpation, blood samples, or ultrasonography) has been reported to be from 6% to 30% in dairy cattle [56–59]. A number of clinical, environmental, and hereditary factors are responsible for the development of ovarian follicular cysts (for review, see [60]). The very high incidence of cysts observed in the studied beef cows may be related to the selection for gemellity that has been carried out for several years in this herd. Gemellity has been reported as a risk factor for follicular cysts [61], and increased twin ovulations have been observed in cows with cysts [9], suggesting an alteration in follicular selection or dominance [14]. In addition, the gonadotropin treatment administered to animals for embryo production 4 to 6 months prior to the initiation of the present study may have contributed to a long-

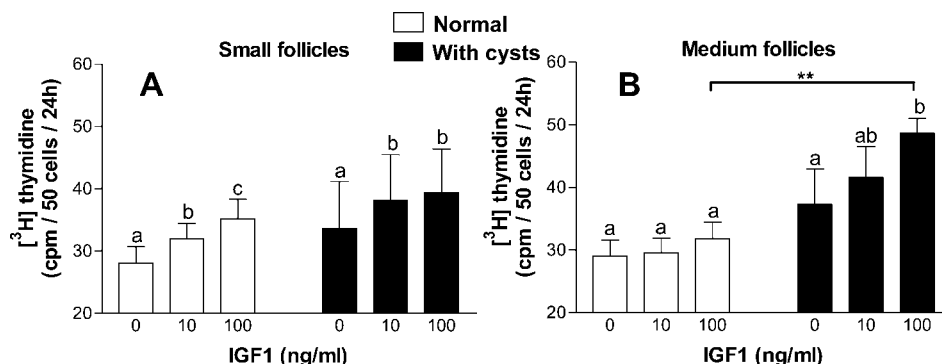


FIG. 7. $[^3\text{H}]$ Thymidine incorporation by granulosa cells of S (A) and M (B) follicles from normal ovaries and ovaries with follicular cysts in response to IGF1 in vitro. Data represent $[^3\text{H}]$ thymidine incorporated by granulosa cells of S follicles from normal ovaries (n = 8 cows, open bars), S follicles from ovaries with follicular cysts (n = 7 cows, black bars), M follicles from normal ovaries (n = 8 cows, open bars), and M follicles from ovaries with follicular cysts (n = 4 cows, black bars) cultured for 48 h with and without IGF1 (10 and 100 ng/ml). Data are expressed in cpm/50 cells/24 h. Within each panel, different letters indicate significant effects of IGF1 on $[^3\text{H}]$ thymidine incorporation by granulosa cells isolated from normal ovaries or ovaries with follicular cysts. cpm, counts per minute; **P < 0.01, normal ovaries vs. ovaries with follicular cysts.

lasting endocrine disturbance leading to follicular cyst formation.

In this study, cyst turnover occurred in cows with follicular cysts, in agreement with previous reports [9, 12, 14, 62, 63]. The young cysts that developed after experimental regression of the older ones had functional features quite different from those of the large early dominant follicles [46] that developed on normal ovaries, since both follicular growth and steroidogenesis were clearly higher in young cysts. Theca cells of young cysts were morphologically different from those of early dominant follicles, and testosterone concentration was higher in follicular fluid of the young cysts. Moreover, young cysts exhibited higher intrafollicular concentrations of estradiol and progesterone, without any associated difference in mRNA expression of the steroidogenic enzymes *CYP19A1* and *CYP11A1* and the steroidogenic factor *STAR* in granulosa cells. Altogether, these results suggest that enhanced stimulation of theca had sustained development of the young cysts. Previous studies have established that cows with cysts have a higher frequency and amplitude of LH pulsatile secretion than cows with ovulatory cycles [9, 11, 12]. Whether an enhancement of LH pulsatility is responsible for enhanced stimulation of theca cells and can explain cyst turnover is an important question that should be addressed in further studies with this animal model.

Compared to young cysts, later-stage cysts exhibited lower testosterone and estradiol but higher progesterone concentrations in follicular fluid. The low concentration of testosterone in follicular fluid of these cysts might be indicative of theca luteinization that has been shown to be associated with a drop in *CYP17A1* expression in the cow [64, 65], and hypertrophy of theca interna cells that was observed from morphological analysis of cysts also argue for this hypothesis. In granulosa cells of these cysts, *STAR* mRNA expression was strikingly higher than in cells of young cysts, whereas *CYP19A1* and *CYP11A1* mRNA expression were both lower. *STAR* imports cholesterol into mitochondria, and its expression pattern renders it an important marker of the luteinization process in granulosa cells of various animal species [66–68], including the cow [69, 70]. Decreases in *CYP19A1* and *CYP11A1* mRNA expression are also characteristic of luteinization process in bovine granulosa cells [64, 71]. Altogether, these results strongly suggest that luteinization occurred in both theca and granulosa cells during cyst maturation.

To our knowledge, functional characterization of small antral follicles in bovine ovaries with cysts has never been reported. From our results, small antral follicles between 3 and 10 mm diameter exhibited higher steroid intrafollicular concentrations in ovaries with cysts than in normal ovaries, without any associated difference in steroidogenic enzymes and *STAR* expression in granulosa cells. These results suggest

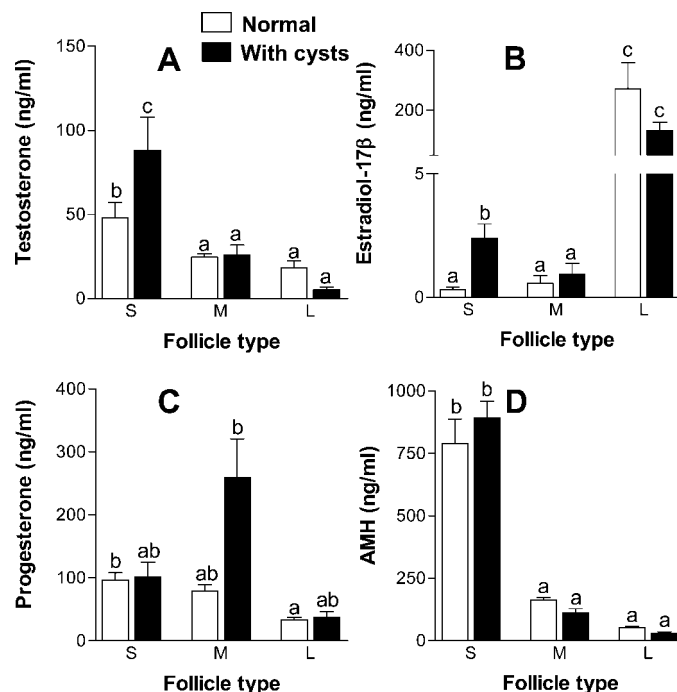


FIG. 8. Intrafollicular concentrations of steroids and AMH during follicular development in normal ovaries and ovaries with follicular cysts. A) Testosterone. B) Estradiol-17β. C) Progesterone. D) AMH. For normal ovaries, data were obtained on S (n = 9 pools of follicular fluid, open bars), M (n = 83 follicular fluids, open bars), and L (n = 17 follicular fluids, open bars) follicles, all recovered from the ovaries of 9 cows. For ovaries with follicular cysts, data were obtained on S (n = 7 pools of follicular fluid, black bars), M (n = 37 follicular fluids, black bars), and L (n = 4 follicular fluids, black bars) follicles, all recovered from the ovaries of 8 cows. Within each panel, different letters indicate significant differences between means resulting from multiple comparison tests between all the studied follicles. The level of significance of the differences is indicated in Results.

that the physiological conditions that lead to the formation of the cysts, possibly an enhancement in LH pulsatility, also predispose new small antral follicles to become cysts. However, only some of these small antral follicles would actually become cysts. For example, the existence of strong variations in progesterone concentration between individual follicles of 5–10 mm diameter in ovaries with follicular cysts (range: 7–1800 ng/ml) suggests that some of them, but not all, would be predisposed to luteinize. Moreover, in ovaries with follicular cysts, the presence of some large follicles with steroid concentrations similar to those of large follicles in normal ovaries suggests that a “normal” follicular growth is possible in ovaries with cysts. It can be thought that the chance for a small antral follicle to become a cyst would be increased when a cyst is already present on ovaries, which can explain the mechanism of cyst turnover.

Granulosa cells of small follicles between 3 and 5 mm diameter exhibited high proliferation rate and responsiveness to IGF1 in both normal ovaries and ovaries with cysts. However, in medium follicles between 5 and 10 mm diameter, only cells from ovaries with cysts were responsive to IGF1. The presence of large early dominant follicles in normal ovaries at this stage of the follicular wave is known to be associated with declining FSH plasmatic concentrations that lead to a decrease in growth rate of the smaller follicles of the cohort [5, 46]. In ovaries with follicular cysts, enhanced stimulation of theca cells of medium follicles may have sustained their granulosa cell proliferation rate and responsiveness to IGF1. The underlying mechanism of this control is unknown, but various theca-derived factors have been shown to regulate granulosa cell proliferation, acting in a paracrine way [72, 73]. The high proliferation rate observed in granulosa cells of the young cysts suggests that this type of control would also be operating during cyst development.

This study is the first description of changes in both AMH concentration in follicular fluid and *AMH* expression in granulosa cells during normal and cystic follicular growth in the cow. Our results show that AMH intrafollicular concentration decreased sharply during growth of antral follicles in both normal ovaries and ovaries with cysts and that the presence of cysts did not affect *AMH* expression by granulosa cells and its concentration in follicular fluid. Particularly, no difference was observed between large early dominant follicles and cysts. In contrast, AMH concentrations have been shown to be enhanced in follicular cysts of women with PCOS [15, 16]. Our results confirm that follicular cysts in bovine (at least in this Maine-Anjou population) and in human are quite different, despite the existence of similarities in some features of steroidogenesis, such as enhanced androgen production and luteinization [74].

The mechanisms regulating AMH production by granulosa cells are poorly understood. In situ hybridization studies in the rat have shown that *AMH* expression is the highest in preantral and small antral follicles and decreases during terminal follicular growth [75]. Accordingly, in humans, a decrease in the protein content of granulosa cells of large antral follicles has been shown by immunohistochemistry [26], and low AMH concentrations have been detected in the follicular fluid of preovulatory follicles [36–38]. In this study, we did not observe significant changes in *AMH* mRNA expression in bovine granulosa cells between small 3–5 mm and large 10–15 mm diameter follicles, whereas AMH concentration clearly dropped in the follicular fluid during follicular growth. This discrepancy can be partly explained by AMH dilution in follicular fluid after its secretion by granulosa cells, since between 3 and 10 mm diameter the follicular volume increases 37-fold whereas the number of granulosa cells, estimated from

histological data [76], increases only 11-fold. Moreover, various posttranscriptional mechanisms, including secretion rate and binding to extracellular matrix proteins [77], may regulate accumulation of growth factors in the antrum. Anyway, this decrease in intrafollicular AMH concentration may have important functional consequences for follicular development because it has been shown that AMH inhibits the induction of CYP19A1, and LH receptors by FSH in granulosa cells of antral follicles [34].

Both AMH concentration in follicular fluid and *AMH* expression in granulosa cells were not different between large early dominant follicles and cysts. However, when considering all the largest follicular structures including cysts, a negative relationship was observed between progesterone and AMH concentrations, the latter being the lowest in luteinized cysts. A similar observation has been reported in follicular fluid of human preovulatory follicles after hCG administration [37, 39]. Moreover, in the rat, a low *AMH* expression has been reported in corpora lutea, compared to antral follicles [75]. Altogether, these results suggest that the luteinization process may lead to an additional decrease in AMH production by granulosa cells. The mechanisms explaining this decrease are likely posttranscriptional but have not yet been investigated.

In conclusion, this study is the first report of functional changes in small antral follicles (<10 mm) preceding cyst formation in cow ovaries and of AMH concentrations in bovine follicles and cysts. Spontaneous development of cysts in cow ovaries was preceded by early changes in growth and steroidogenesis of small antral follicles of the cohort, likely explaining cyst turnover. In contrast, AMH concentration decreased in a similar way in follicles from normal ovaries and ovaries with cysts during terminal follicular development. Intrafollicular AMH would not be a marker of cystic development in cow, unlike in human follicles, but low AMH concentrations in cysts were associated with luteinization.

ACKNOWLEDGMENTS

The authors thank M. Francis Dupont and the “ruminant” team of the Experimental Unit UPEA PRC for animal management and participation in the experimental design.

REFERENCES

1. Savio JD, Keenan L, Boland MP, Roche JF. Pattern of growth of dominant follicles during the oestrous cycle of heifers. *J Reprod Fertil* 1988; 83: 663–671.
2. Sirois J, Fortune JE. Ovarian follicular dynamics during the estrous cycle in heifers monitored by real-time ultrasonography. *Biol Reprod* 1988; 39: 308–317.
3. Ginther OJ, Knopf L, Kastelic JP. Temporal associations among ovarian events in cattle during oestrous cycles with two and three follicular waves. *J Reprod Fertil* 1989; 87:223–230.
4. Adams GP, Matteri RL, Kastelic JP, Ko JC, Ginther OJ. Association between surges of follicle-stimulating hormone and the emergence of follicular waves in heifers. *J Reprod Fertil* 1992; 94:177–188.
5. Fortune JE. Ovarian follicular growth and development in mammals. *Biol Reprod* 1994; 50:225–232.
6. Ginther OJ, Knopf L, Kastelic JP. Ovarian follicular dynamics in heifers during early pregnancy. *Biol Reprod* 1989; 41:247–254.
7. Savio JD, Boland MP, Roche JF. Development of dominant follicles and length of ovarian cycles in post-partum dairy cows. *J Reprod Fertil* 1990; 88:581–591.
8. Kesler DJ, Garverick HA. Ovarian cysts in dairy cattle: a review. *J Anim Sci* 1982; 55:1147–1159.
9. Hamilton SA, Garverick HA, Keisler DH, Xu ZZ, Loos K, Youngquist RS, Salfen BE. Characterization of ovarian follicular cysts and associated endocrine profiles in dairy cows. *Biol Reprod* 1995; 53:890–898.
10. Vanholder T, Opsomer G, de Kruijff A. Aetiology and pathogenesis of

- cystic ovarian follicles in dairy cattle: a review. *Reprod Nutr Dev* 2006; 46:105–119.
11. Cook DL, Parfet JR, Smith CA, Moss GE, Youngquist RS, Garverick HA. Secretory patterns of LH and FSH during development and hypothalamic and hypophysial characteristics following development of steroid-induced ovarian follicular cysts in dairy cattle. *J Reprod Fertil* 1991; 91:19–28.
 12. Yoshioka K, Iwamura S, Kamomae H. Ultrasonic observations on the turnover of ovarian follicular cysts and associated changes of plasma LH, FSH, progesterone and oestradiol-17 beta in cows. *Res Vet Sci* 1996; 61: 240–244.
 13. Bigelow KL, Fortune JE. Characteristics of prolonged dominant versus control follicles: follicle cell numbers, steroidogenic capabilities, and messenger ribonucleic acid for steroidogenic enzymes. *Biol Reprod* 1998; 58:1241–1249.
 14. Calder MD, Manikkam M, Salfen BE, Youngquist RS, Lubahn DB, Lamberson WR, Garverick HA. Dominant bovine ovarian follicular cysts express increased levels of messenger RNAs for luteinizing hormone receptor and 3 beta-hydroxysteroid dehydrogenase delta(4),delta(5) isomerase compared to normal dominant follicles. *Biol Reprod* 2001; 65:471–476.
 15. Fallat ME, Siow Y, Marra M, Cook C, Carrillo A. Mullerian-inhibiting substance in follicular fluid and serum: a comparison of patients with tubal factor infertility, polycystic ovary syndrome, and endometriosis. *Fertil Steril* 1997; 67:962–965.
 16. Pellatt L, Hanna L, Brincat M, Galea R, Brain H, Whitehead S, Mason H. Granulosa cell production of anti-Mullerian hormone is increased in polycystic ovaries. *J Clin Endocrinol Metab* 2007; 92:240–245.
 17. Teixeira J, Maheswaran S, Donahoe PK. Mullerian inhibiting substance: an instructive developmental hormone with diagnostic and possible therapeutic applications. *Endocr Rev* 2001; 22:657–674.
 18. Josso N, Clemente N. Transduction pathway of anti-Mullerian hormone, a sex-specific member of the TGF-beta family. *Trends Endocrinol Metab* 2003; 14:91–97.
 19. Vigier B, Picard JY, Tran D, Legeai L, Josso N. Production of anti-Mullerian hormone: another homology between Sertoli and granulosa cells. *Endocrinology* 1984; 114:1315–1320.
 20. Takahashi M, Hayashi M, Manganaro TF, Donahoe PK. The ontogeny of mullerian inhibiting substance in granulosa cells of the bovine ovarian follicle. *Biol Reprod* 1986; 35:447–453.
 21. Bezar J, Vigier B, Tran D, Mauleon P, Josso N. Immunocytochemical study of anti-Mullerian hormone in sheep ovarian follicles during fetal and post-natal development. *J Reprod Fertil* 1987; 80:509–516.
 22. Ueno S, Takahashi M, Manganaro TF, Ragin RC, Donahoe PK. Cellular localization of mullerian inhibiting substance in the developing rat ovary. *Endocrinology* 1989; 124:1000–1006.
 23. Hirobe S, He WW, Lee MM, Donahoe PK. Mullerian inhibiting substance messenger ribonucleic acid expression in granulosa and Sertoli cells coincides with their mitotic activity. *Endocrinology* 1992; 131:854–862.
 24. Hirobe S, He WW, Gustafson ML, MacLaughlin DT, Donahoe PK. Mullerian inhibiting substance gene expression in the cycling rat ovary correlates with recruited or graafian follicle selection. *Biol Reprod* 1994; 50:1238–1243.
 25. Rajpert-De Meyts E, Jorgensen N, Graem N, Muller J, Cate RL, Skakkebaek NE. Expression of anti-Mullerian hormone during normal and pathological gonadal development: association with differentiation of Sertoli and granulosa cells. *J Clin Endocrinol Metab* 1999; 84:3836–3844.
 26. Weenen C, Laven JS, Von Bergh AR, Cranfield M, Groome NP, Visser JA, Kramer P, Fauser BC, Themmen AP. Anti-Mullerian hormone expression pattern in the human ovary: potential implications for initial and cyclic follicle recruitment. *Mol Hum Reprod* 2004; 10:77–83.
 27. Dutertre M, Gouedard L, Xavier F, Long WQ, di Clemente N, Picard JY, Rey R. Ovarian granulosa cell tumors express a functional membrane receptor for anti-Mullerian hormone in transgenic mice. *Endocrinology* 2001; 142:4040–4046.
 28. Salmon NA, Handyside AH, Joyce IM. Oocyte regulation of anti-Mullerian hormone expression in granulosa cells during ovarian follicle development in mice. *Dev Biol* 2004; 266:201–208.
 29. Vigier B, Watrin F, Magre S, Tran D, Josso N. Purified bovine AMH induces a characteristic freemartin effect in fetal rat prospective ovaries exposed to it in vitro. *Development* 1987; 100:43–55.
 30. di Clemente N, Ghaffari S, Pepinsky RB, Pieau C, Josso N, Cate RL, Vigier B. A quantitative and interspecific test for biological activity of anti-mullerian hormone: the fetal ovary aromatase assay. *Development* 1992; 114:721–727.
 31. Durlinger AL, Gruijters MJ, Kramer P, Karels B, Ingraham HA, Nachtigal MW, Uilenbroek JT, Grootegoed JA, Themmen AP. Anti-Mullerian hormone inhibits initiation of primordial follicle growth in the mouse ovary. *Endocrinology* 2002; 143:1076–1084.
 32. Durlinger AL, Kramer P, Karels B, de Jong FH, Uilenbroek JT, Grootegoed JA, Themmen AP. Control of primordial follicle recruitment by anti-Mullerian hormone in the mouse ovary. *Endocrinology* 1999; 140: 5789–5796.
 33. Durlinger AL, Gruijters MJ, Kramer P, Karels B, Kumar TR, Matzuk MM, Rose UM, de Jong FH, Uilenbroek JT, Grootegoed JA, Themmen AP. Anti-Mullerian hormone attenuates the effects of FSH on follicle development in the mouse ovary. *Endocrinology* 2001; 142:4891–4899.
 34. di Clemente N, Goxe B, Remy JJ, Cate RL, Josso N, Vigier B, Salese R. Inhibitory effect of AMH upon the expression of aromatase and LH receptors by cultured granulosa cells of rat and porcine immature ovaries. *Endocrine Reviews* 1994; 2:553–558.
 35. Kim JH, Seibel MM, MacLaughlin DT, Donahoe PK, Ransil BJ, Hametz PA, Richards CJ. The inhibitory effects of mullerian-inhibiting substance on epidermal growth factor induced proliferation and progesterone production of human granulosa-luteal cells. *J Clin Endocrinol Metab* 1992; 75:911–917.
 36. Seifer DB, MacLaughlin DT, Penzias AS, Behrman HR, Asmundson L, Donahoe PK, Haning RV Jr, Flynn SD. Gonadotropin-releasing hormone agonist-induced differences in granulosa cell cycle kinetics are associated with alterations in follicular fluid mullerian-inhibiting substance and androgen content. *J Clin Endocrinol Metab* 1993; 76:711–714.
 37. Fanchin R, Louafi N, Mendez Lozano DH, Frydman N, Frydman R, Taieb J. Per-follicle measurements indicate that anti-mullerian hormone secretion is modulated by the extent of follicular development and luteinization and may reflect qualitatively the ovarian follicular status. *Fertil Steril* 2005; 84: 167–173.
 38. Andersen CY, Byskov AG. Estradiol and regulation of anti-Mullerian hormone, inhibin-A, and inhibin-B secretion: analysis of small antral and preovulatory human follicles' fluid. *J Clin Endocrinol Metab* 2006; 91: 4064–4069.
 39. Fanchin R, Mendez Lozano DH, Frydman N, Gougeon A, di Clemente N, Frydman R, Taieb J. Anti-Mullerian hormone concentrations in the follicular fluid of the preovulatory follicle are predictive of the implantation potential of the ensuing embryo obtained by in vitro fertilization. *J Clin Endocrinol Metab* 2007; 92:1796–1802.
 40. Monniaux D, Pisselet C. Control of proliferation and differentiation of ovine granulosa cells by insulin-like growth factor-I and follicle-stimulating hormone in vitro. *Biol Reprod* 1992; 46:109–119.
 41. Campbell BK, Scaramuzzi RJ, Webb R. Induction and maintenance of oestradiol and immunoreactive inhibin production with FSH by ovine granulosa cells cultured in serum-free media. *J Reprod Fertil* 1996; 106:7–16.
 42. Saumande J, Tamboura D, Chupin D. Changes in milk and plasma concentrations of progesterone in cows after treatment to induce superovulation and their relationships with number of ovulations and of embryos collected. *Theriogenology* 1985; 23:719–731.
 43. Hochereau-de Reviers MT, Perreau C, Pisselet C, Fontaine I, Monet-Kuntz C. Comparisons of endocrinological and testis parameters in 18-month-old Ile de France and Romanov rams. *Domest Anim Endocrinol* 1990; 7:63–73.
 44. Kevenaar ME, Meerasahib MF, Kramer P, van de Lang-Born BM, de Jong FH, Groome NP, Themmen AP, Visser JA. Serum anti-mullerian hormone levels reflect the size of the primordial follicle pool in mice. *Endocrinology* 2006; 147:3228–3234.
 45. Yeh J, Kim B, Peresie J, Liang YJ, Arroyo A. Serum and ovarian Mullerian inhibiting substance, and their decline in reproductive aging. *Fertil Steril* 2007; 87:1227–1230.
 46. Fortune JE, Rivera GM, Evans AC, Turzillo AM. Differentiation of dominant versus subordinate follicles in cattle. *Biol Reprod* 2001; 65:648–654.
 47. Burns DS, Jimenez-Krassel F, Ireland JL, Knight PG, Ireland JJ. Numbers of antral follicles during follicular waves in cattle: evidence for high variation among animals, very high repeatability in individuals, and an inverse association with serum follicle-stimulating hormone concentrations. *Biol Reprod* 2005; 73:54–62.
 48. Sirois J, Fortune JE. Lengthening the bovine estrous cycle with low levels of exogenous progesterone: a model for studying ovarian follicular dominance. *Endocrinology* 1990; 127:916–925.
 49. Stock AE, Fortune JE. Ovarian follicular dominance in cattle: relationship between prolonged growth of the ovulatory follicle and endocrine parameters. *Endocrinology* 1993; 132:1108–1114.
 50. Silvia WJ, Hatler TB, Nugent AM, Laranja da Fonseca LF. Ovarian follicular cysts in dairy cows: an abnormality in folliculogenesis. *Domest Anim Endocrinol* 2002; 23:167–177.

51. Nadaraja R, Hansel W. Hormonal changes associated with experimentally produced cystic ovaries in the cow. *J Reprod Fertil* 1976; 47:203–208.
52. Gumen A, Sartori R, Costa FM, Wiltbank MC. A GnRH/LH surge without subsequent progesterone exposure can induce development of follicular cysts. *J Dairy Sci* 2002; 85:43–50.
53. Kawate N, Inaba T, Mori J. Changes in plasma concentrations of gonadotropins and steroid hormones during the formation of bovine follicular cysts induced by the administration of ACTH. *J Vet Med Sci* 1996; 58:141–144.
54. Ribadu AY, Nakada K, Moriyoshi M, Zhang WC, Tanaka Y, Nakao T. The role of LH pulse frequency in ACTH-induced ovarian follicular cysts in heifers. *Anim Reprod Sci* 2000; 64:21–31.
55. Gumen A, Wiltbank MC. Follicular cysts occur after a normal estradiol-induced GnRH/LH surge if the corpus hemorrhagicum is removed. *Reproduction* 2005; 129:737–745.
56. Garverick HA. Ovarian follicular cysts in dairy cows. *J Dairy Sci* 1997; 80:995–1004.
57. Bartolome JA, Archbald LF, Morresey P, Hernandez J, Tran T, Kelbert D, Long K, Risco CA, Thatcher WW. Comparison of synchronization of ovulation and induction of estrus as therapeutic strategies for bovine ovarian cysts in the dairy cow. *Theriogenology* 2000; 53:815–825.
58. Cartmill JA, El-Zarkouny SZ, Hensley BA, Lamb GC, Stevenson JS. Stage of cycle, incidence, and timing of ovulation, and pregnancy rates in dairy cattle after three timed breeding protocols. *J Dairy Sci* 2001; 84:1051–1059.
59. Gumen A, Guenther JN, Wiltbank MC. Follicular size and response to Ovsynch versus detection of estrus in anovular and ovular lactating dairy cows. *J Dairy Sci* 2003; 86:3184–3194.
60. Peter AT. An update on cystic ovarian degeneration in cattle. *Reprod Domest Anim* 2004; 39:1–7.
61. Kinsel ML, Marsh WE, Ruegg PL, Etherington WG. Risk factors for twinning in dairy cows. *J Dairy Sci* 1998; 81:989–993.
62. Cook DL, Smith CA, Parfet JR, Youngquist RS, Brown EM, Garverick HA. Fate and turnover rate of ovarian follicular cysts in dairy cattle. *J Reprod Fertil* 1990; 90:37–46.
63. Kengaku K, Tanaka T, Kamomae H. Changes in the peripheral concentrations of inhibin, follicle-stimulating hormone, luteinizing hormone, progesterone and estradiol-17beta during turnover of cystic follicles in dairy cows with spontaneous follicular cysts. *J Reprod Dev* 2007; 53:987–993.
64. Voss AK, Fortune JE. Levels of messenger ribonucleic acid for cytochrome P450 17 alpha-hydroxylase and P450 aromatase in preovulatory bovine follicles decrease after the luteinizing hormone surge. *Endocrinology* 1993; 132:2239–2245.
65. Komar CM, Berndtson AK, Evans AC, Fortune JE. Decline in circulating estradiol during the periovulatory period is correlated with decreases in estradiol and androgen, and in messenger RNA for p450 aromatase and p450 17alpha-hydroxylase, in bovine preovulatory follicles. *Biol Reprod* 2001; 64:1797–1805.
66. Ivell R, Bathgate R, Walther N. Luteal peptides and their genes as important markers of ovarian differentiation. *J Reprod Fertil Suppl* 1999; 54:207–216.
67. Murphy BD. Models of luteinization. *Biol Reprod* 2000; 63:2–11.
68. Espey LL, Richards JS. Temporal and spatial patterns of ovarian gene transcription following an ovulatory dose of gonadotropin in the rat. *Biol Reprod* 2002; 67:1662–1670.
69. Pescador N, Soumano K, Stocco DM, Price CA, Murphy BD. Steroidogenic acute regulatory protein in bovine corpora lutea. *Biol Reprod* 1996; 55:485–491.
70. Bao B, Calder MD, Xie S, Smith MF, Salfen BE, Youngquist RS, Garverick HA. Expression of steroidogenic acute regulatory protein messenger ribonucleic acid is limited to theca of healthy bovine follicles collected during recruitment, selection, and dominance of follicles of the first follicular wave. *Biol Reprod* 1998; 59:953–959.
71. Voss AK, Fortune JE. Levels of messenger ribonucleic acid for cholesterol side-chain cleavage cytochrome P-450 and 3 beta-hydroxysteroid dehydrogenase in bovine preovulatory follicles decrease after the luteinizing hormone surge. *Endocrinology* 1993; 132:888–894.
72. Monniaux D, Huet C, Besnard N, Clement F, Bosc M, Pisselet C, Monget P, Mariana JC. Follicular growth and ovarian dynamics in mammals. *J Reprod Fertil Suppl* 1997; 51:3–23.
73. Knight PG, Glister C. TGF-beta superfamily members and ovarian follicle development. *Reproduction* 2006; 132:191–206.
74. Magoffin DA. Ovarian enzyme activities in women with polycystic ovary syndrome. *Fertil Steril* 2006; 86(suppl 1):S9–S11.
75. Baarends WM, Uilenbroek JT, Kramer P, Hoogerbrugge JW, van Leeuwen EC, Themmen AP, Grootegoed JA. Anti-mullerian hormone and anti-mullerian hormone type II receptor messenger ribonucleic acid expression in rat ovaries during postnatal development, the estrous cycle, and gonadotropin-induced follicle growth. *Endocrinology* 1995; 136:4951–4962.
76. Monniaux D, Mariana JC, Gibson WR. Action of PMSG on follicular populations in the heifer. *J Reprod Fertil* 1984; 70:243–253.
77. Gumienny TL, Padgett RW. The other side of TGF-beta superfamily signal regulation: thinking outside the cell. *Trends Endocrinol Metab* 2002; 13:295–299.