



HAL
open science

Multimodal assessment of language and memory reorganization. A proof of concept in two patients with temporal lobe epilepsy.

Elise Roger, Cédric Pichat, Felix Renard, E. Cousin, Marcela Perrone-Bertolotti, Pascal Hot, L. Minotti, Anne-Sophie Job, P. Kahane, Agnes Trébuchon, et al.

► **To cite this version:**

Elise Roger, Cédric Pichat, Felix Renard, E. Cousin, Marcela Perrone-Bertolotti, et al.. Multimodal assessment of language and memory reorganization. A proof of concept in two patients with temporal lobe epilepsy.. OHBM (Organization of the human Brain Mapping) 2019, Jun 2018, Singapore, Singapore. , 2018, <10.13140/RG.2.2.20097.35686>. <hal-01916827>

HAL Id: hal-01916827

<https://hal.science/hal-01916827v1>

Submitted on 20 Nov 2018

HAL is a multi-disciplinary open access archive for the deposit and dissemination of scientific research documents, whether they are published or not. The documents may come from teaching and research institutions in France or abroad, or from public or private research centers.

L'archive ouverte pluridisciplinaire **HAL**, est destinée au dépôt et à la diffusion de documents scientifiques de niveau recherche, publiés ou non, émanant des établissements d'enseignement et de recherche français ou étrangers, des laboratoires publics ou privés.



HAL Authorization

Multimodal assessment of language and memory reorganization A proof of concept in two patients with temporal lobe epilepsy.

Roger, E.¹, Pichat, C.¹, Renard, F.², Cousin, E.^{1,2}, Perrone-Bertolotti, M.¹, Hot, P.¹,
Minotti, L.³, Job, AS.³, Kahane, P.³, Trebuchon, A.⁴, Krainik, A.² & Baciú, M.¹

¹Univ. Grenoble Alpes, CNRS LPNC UMR 5105, F-38000 Grenoble, France

²Univ. Grenoble Alpes, UMS IRMaGe CHU, F-38000 Grenoble, France

³Univ. Grenoble Alpes, Grenoble Institute of Neuroscience & Neurology Department CHUGA, France

⁴Univ. Aix-Marseille, Institut des Neurosciences des Systèmes, 13385 Marseille, France



CONTEXT & GOALS

Background

Temporal lobe epilepsy (TLE) accounts for 70-80% of epilepsy in adults (Jaimes-Bautista et al., 2015). The dysfunction (epileptic zone, EZ) is located in the temporal lobe and induces anatomical and functional reorganization of cerebral networks that seem to go hand in hand with various degrees of cognitive efficiency (for a review see Roger et al., 2018).

Main objectives

- 1) Underscore the importance of factoring in inter-subject variability and more informative descriptions of neurocognitive functioning that are based on individual characteristics – regardless the similarity of the EZ locations;
- 2) Emphasize the importance of taking into account structural connectivity to generate neurocognitive and anatomo-functional profiles that are more suitable and that reflect the patient's individual circumstances more closely.

RESULTS

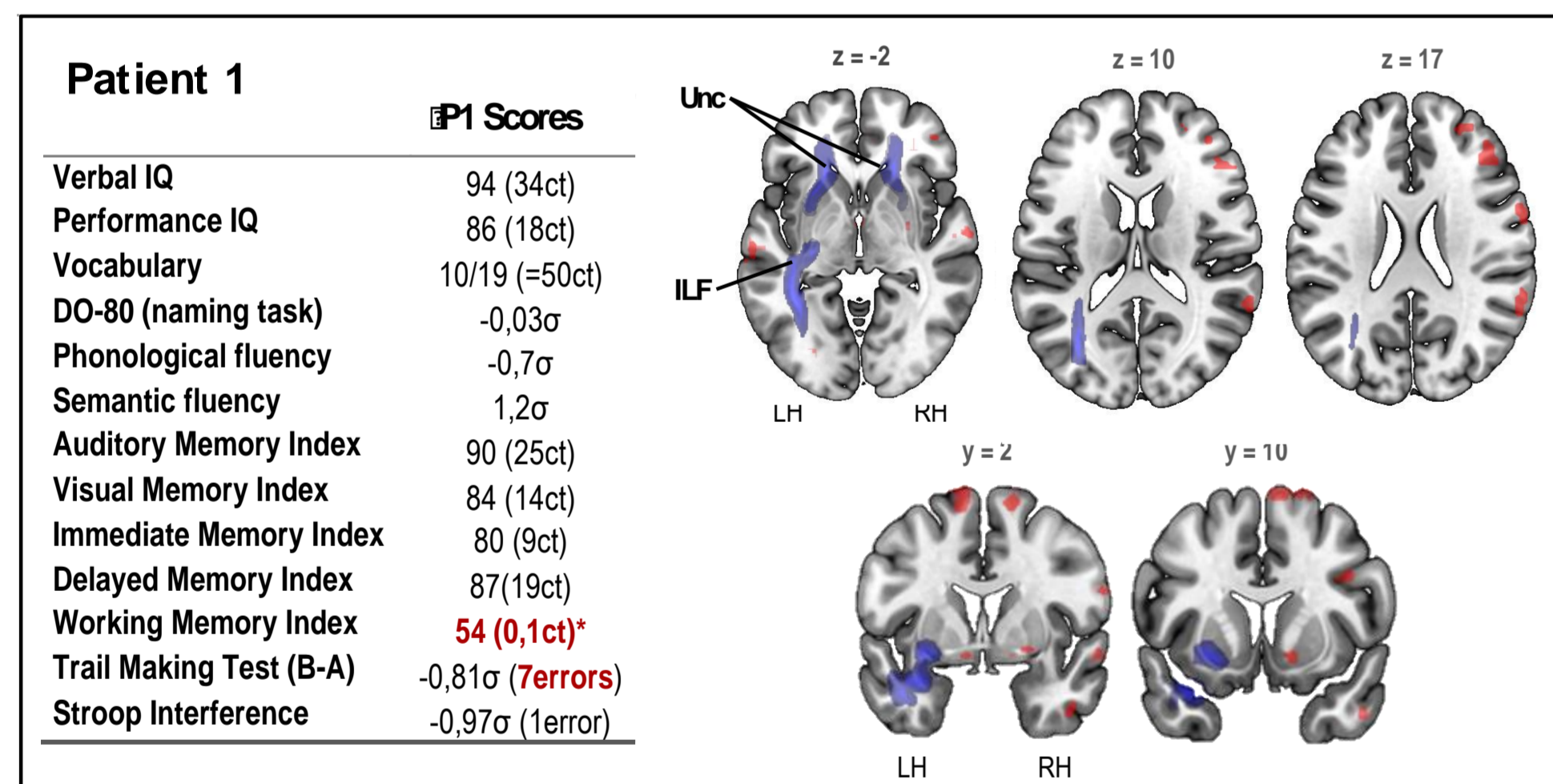


Figure 1. Multimodal data for P1 compared to the control group. Cognitive scores (raw & standard), functional activations (projected in red on an anatomical brain template) and white matter bundles deemed to be impaired (projected in blue) based on the FA parameter. Neuroimaging results are shown in a $p < .05$ FWE corrected threshold. Abbreviations: ILF: inferior longitudinal fasciculus, Unc: uncinate fasciculus.

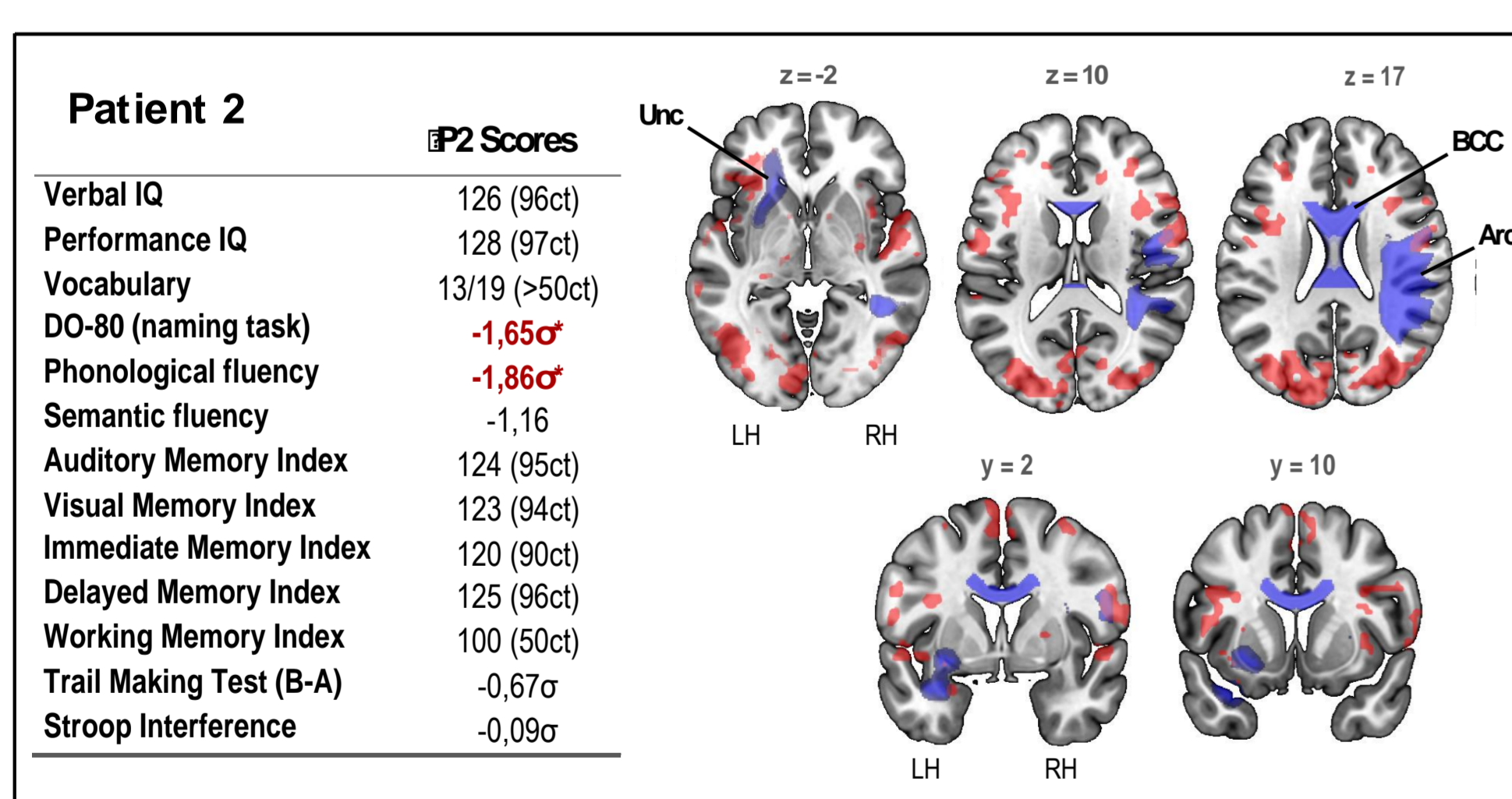


Figure 2. Multimodal data for P2, compared to the control group. Cognitive scores, functional activation (in red in the anatomical images), and white matter bundles deemed to be impaired (shown in blue) based on the FA parameter. Abbreviations: Unc: Uncinate fasciculus, BCC: body of the corpus callosum; Arc: Arcuate fasciculus.

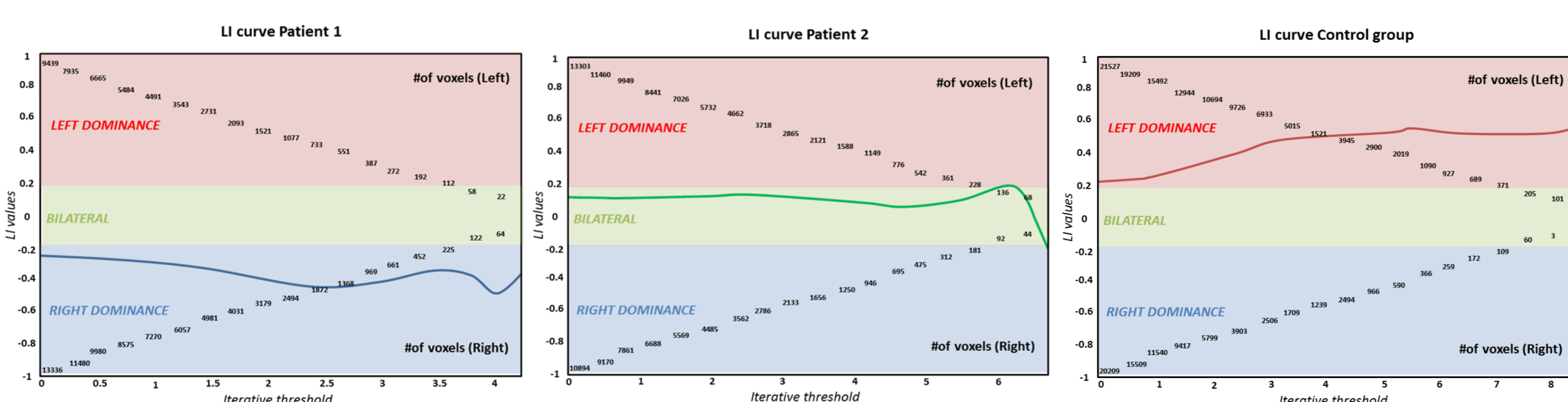
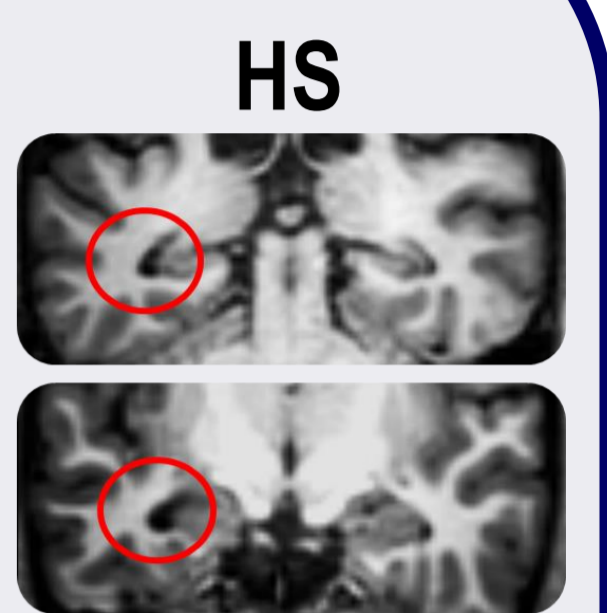


Figure 3. Lateralization indices (LI) for P1, P2 and the control group, based on t values (iterations). LI was computed on the basis of the number of activated voxels in the frontal region, reflecting the hemispheric specialization for language. LI-tool implemented in SPM12 was used. In each graph, the red area indicates positive LI (from +0.2 to +1) and a left hemispheric specialization, whereas the blue area indicates negative LI (from -0.2 to -1) and a right hemispheric specialization. The green area pertains to the LI between -0.2 and +0.2 and indicates bilateral representation of language. The calculation of LI was based on the method described by Seghier et al., 2008.

METHODS

Multiple case report

12 healthy subjects (mean age = 23.92, SD = 2.02, 9 females)
2 mesial TLE with HS matched in age of onset of the epilepsy, seizures frequency and number/type of AEDs



Neuroimaging

3T MR Achieva Philips imager with a 32-channel head coil

- dMRI: 60 dir. (voxel size: 2 x 2 x 2 mm, 128 x 126 slices of 2 mm thickness and no gap, TE = 67.2 ms, TR = 14000ms, EPI factor = 63, field of view = 256 mm, b value = 1500sec / mm²)
- Naming task-fMRI from the NEREC protocol (Perrone-Bertolotti et al., 2015) (400 dyn, 13'34" total duration, 44 axial slices, 3.5 mm thickness, TR = 2.0 s, TE = 30 ms, flip angle = 75°, field of view = 220mm, in-plane voxel size = 2,75x2,75x3 mm)

Cognitive scores

Several standard scores from a complete neuropsychological assessment.

Analyzes

Neuroimaging data: Fractional anisotropy (FA) was extracted on several fascicles of interest (FOI) by using Diffusionist. The FA values of the 2 patients were independently compared to the control group with modified Crawford t test (t') using the Singlims program. Using SPM12, fMRI statistical analyzes were performed individually and then at a group level for controls (one-sample t -test; $k > 5$; $p < 0.05$ FWE corrected; $t = 8.5$).

DISCUSSION & CONCLUSION

Synthesis of main results

- (a) Large scale white matter networks are impaired in focal epilepsy (TLE)
- (b) Structural connectivity and brain function appear to be closely related
- (c) Atypical hemispherical organization of language (right or bilateral) could be cognitively efficient or less efficient
- (d) Neurocognitive profiles are variable despite similar clinical features

Limitations

- Only qualitative and descriptive reports without statistical integration between data (in progress)
- The naming task is easy to performed in a clinical setting but it omits factors such as the syntactic features of language
- This study focuses on the inter-hemispheric level of reorganization and a challenge to reach now would be to identify the intra-hemispheric (regional) plasticity patterns
- Further studies would be needed to assess the reliability of results obtained from fMRI, structural connectivity and cognitive scores

Conclusion

A good understanding of epilepsy and its consequences requires integration of functional, structural and cognitive data.

References

- Jaimes-Bautista AG, Rodríguez-Camacho M, Martínez-Juárez IE, Rodríguez-Agudelo Y. Semantic Processing Impairment in Patients with Temporal Lobe Epilepsy. *Epilepsy Res Treat* 2015;2015:1-8. doi:10.1155/2015/746745.
- Perrone-Bertolotti, M., Girard, C., Cousin, E., Vidal, J. R., Pichat, C., Kahane, P., & Baciú, M. (2015). NEREC, an effective brain mapping protocol for combined language and long-term memory functions. *Epilepsy & Behavior*, 53, 140-148.
- Roger, E., Petit, L., Perrone-Bertolotti, M., Job, A. S., Minotti, L., Kahane, P., & Baciú, M. (2018). The link between structural connectivity and neurocognition illustrated by focal epilepsy. *Epileptic Disorders*, 20(2), 88-98.
- Seghier, M. L. (2008). Laterality index in functional MRI: methodological issues. *Magnetic resonance imaging*, 26(5), 594-601.