



**HAL**  
open science

## **Oncoplastic Resection of Breast Cancers Located in the Lower-Inner or Lower-Outer Quadrant with the Modified McKissock Mammoplasty Technique**

Pierre-Emmanuel Colombo, Marine Lefevre, Laure Delmond, Drissa Traore, William Jacot, Anne Mourregot, Marian Gutowski, Martin Bertrand, Philippe Rouanet

### ► To cite this version:

Pierre-Emmanuel Colombo, Marine Lefevre, Laure Delmond, Drissa Traore, William Jacot, et al.. Oncoplastic Resection of Breast Cancers Located in the Lower-Inner or Lower-Outer Quadrant with the Modified McKissock Mammoplasty Technique. *Annals of Surgical Oncology*, 2015, 22 (S3), pp.486 - 494. 10.1245/s10434-015-4727-5 . hal-01913732

**HAL Id: hal-01913732**

**<https://hal.science/hal-01913732v1>**

Submitted on 4 Nov 2024

**HAL** is a multi-disciplinary open access archive for the deposit and dissemination of scientific research documents, whether they are published or not. The documents may come from teaching and research institutions in France or abroad, or from public or private research centers.

L'archive ouverte pluridisciplinaire **HAL**, est destinée au dépôt et à la diffusion de documents scientifiques de niveau recherche, publiés ou non, émanant des établissements d'enseignement et de recherche français ou étrangers, des laboratoires publics ou privés.

# Oncoplastic Resection of Breast Cancers Located in the Lower- Inner or Lower-Outer Quadrant with the Modified McKissock Mammoplasty Technique

Pierre-Emmanuel Colombo, MD, PhD<sup>1</sup>, Marine Lefèvre, MD<sup>1</sup>, Laure Delmond, MD<sup>1</sup>, Drissa Traore, MD<sup>1</sup>, William Jacot, MD, PhD<sup>2</sup>, Anne Mourregot, MD<sup>1</sup>, Marian Gutowski, MD<sup>1</sup>, Martin M. Bertrand, MD<sup>1</sup>, and Philippe Rouanet, MD, PhD<sup>1</sup>

<sup>1</sup>Department of Surgical Oncology, Montpellier Cancer Institute (ICM), Montpellier, France; <sup>2</sup>Department of Medical Oncology, Montpellier Cancer Institute (ICM), Montpellier, France

## ABSTRACT

**Background.** Oncoplastic surgery for breast cancer (BC) may result in postoperative morbidity that can delay adjuvant treatment(s). The McKissock procedure is a reliable mammoplasty technique used in plastic surgery. The authors present their experiences in using a derived technique for the oncoplastic resection of extended malignancies located in the lower-inner (LIQ) or lower-outer (LOQ) breast quadrants.

**Methods.** Between 2011 and 2014, operative data of 25 patients receiving an oncoplastic resection for invasive BC or ductal carcinoma in situ (DCIS), using the modified McKissock procedure, were recorded. This technique conserved a bipedicle dermoglandular flap to improve the nipple–areola complex blood supply. Oncological and cosmetic results, as well as aesthetic outcomes and patients' satisfaction, were analyzed.

**Results.** Invasive BCs ( $n = 21$ ) and DCIS ( $n = 4$ ) were located in the LIQ ( $n = 18$ ) or LOQ ( $n = 7$ ). The median age of patients was 62 years (range 34–85), the mean resection weight was 134 g (range 43–314), and the global morbidity rate was 12 %. No nipple necrosis occurred in these patients. Free margins were obtained in 22 cases

(88 %) and the secondary mastectomy rate was 8 %. Contralateral symmetrization was performed, or was required, in the majority of cases (17/23). Cosmetic results were classified as excellent or good in 93 % of patients, and the median satisfaction rate on a visual analog scale was 9.6.

**Conclusion.** The modified McKissock procedure allows wide resection of cancers located in the LOQ or LIQ, and produced favorable postoperative outcomes and cosmetic results despite important resection weights.

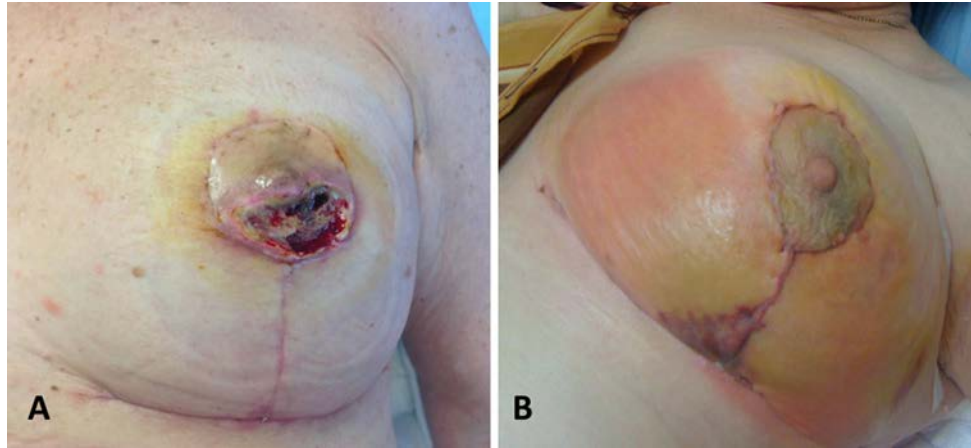
Breast surgery impacts local control and determines the cosmetic outcome in the management of breast cancer (BC).<sup>1</sup> During the last decade, oncoplastic surgery (OP-S) techniques have emerged in breast-conservation surgery (BCS) and are expanding dramatically.<sup>2–5</sup> OP-S combines large-volume glandular resection adapted to oncologic imperatives with an immediate breast reconstruction using techniques derived from plastic surgery. The main objective is to obtain satisfactory cosmetic results in comparison to traditional BCS, with an improvement of oncologic security on resection margins.<sup>1</sup> First derived from classical mammoplasty techniques, OP-S techniques have been described quadrant-by-quadrant with the aim of standardizing operative procedures and indications.<sup>2,6</sup> Studies have also mentioned the risk of postoperative morbidity, including delayed wound healing or glandular necrosis, which can postpone adjuvant treatments (Fig. 1).<sup>7</sup> This risk underlines the requirement of safe techniques, trained surgeons, and validated indications.<sup>8</sup>

The McKissock procedure is a robust mammoplasty technique widely used in plastic surgery for breast reduction, particularly in the case of hypertrophic breasts with advanced-to-severe ptosis.<sup>9,10</sup> This technique combines a

---

**Supplementary material** See end of the article.

P.-E. Colombo, MD, PhD  
e-mail: Pierre-Emmanuel.Colombo@icm.unicancer.fr



**FIG. 1** Clinical examples of dreaded complications associated with OP-S. **a** OP-S with large resection of lower quadrants of the left breast complicated by glandular necrosis and delayed wound healing.

**b** Partial nipple-areola necrosis after an 'inverted T' oncoplastic mammoplasty. OP-S oncoplastic surgery

glandular reduction in the lower-inner (LIQ) and lower-outer (LOQ) quadrants with a nipple-areola complex (NAC) transposition using a vertical bipedicle dermoglandular flap. Despite its vascular safety against skin and NAC ischemia, the McKissock procedure has not yet been reported in large series for OP-S indications.

Here, we report on a new OP-S technique derived from the McKissock procedure for extended BC or/and ductal carcinoma in situ (DCIS) requiring wide resection of either the LIQ or LOQ and immediate breast reconstruction. In this modified technique, only one lower quadrant is largely removed according to the tumor location. The bipedicle dermoglandular flap is conserved to fill the glandular defect while conserving safe vascularization of the NAC and the moved gland. The objective of our pilot study was to analyze the operative features and the oncologic/cosmetic outcomes of the modified McKissock procedure performed in OP-S for BCS.

## PATIENTS AND METHODS

### Patients

Between 2011 and 2014, all patients who underwent OP-S with the modified McKissock technique in our institution were recorded in a prospective database. Informed consent was obtained from all patients and the protocol was approved by the Institutional Review Ethics Committee. The study was conducted according to the Declaration of Helsinki principles. The inclusion criteria comprised invasive BC or DCIS, not suitable for classical BCS, requiring large resection of either the LIQ or the LOQ. Resection extensions were determined preoperatively on clinical examination and on imagery examinations, including mammograms, ultrasound and, in some cases, magnetic resonance imaging

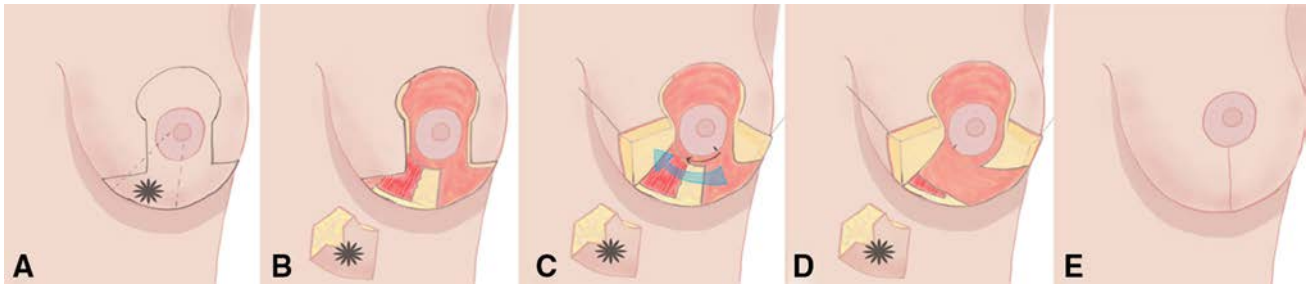
(MRI). MRI was systematically performed for invasive lobular carcinoma, multifocal BC, and in the case of neoadjuvant chemotherapy. Collected data were analyzed retrospectively.

### Preoperative Data

Analyzed preoperative data included patient and tumor characteristics (age, body mass index [BMI], breast cup size, involved quadrant, clinical and radiological tumor size). The indication for OP-S, possible preoperative treatments, and response to these treatments were also recorded.

### Operative Technique

Patients were operated on in a half-seated position with their arms extended to 90°. Preoperative markings and skin incisions were performed following a Wise pattern adapted to breast morphology, tumor extension, and planned excision (Figs. 2, 3, 4, and electronic supplementary Figs. S1 and S2).<sup>11</sup> After incision, the skin within the Wise pattern was deepithelialized in order to form a dual superior and inferomedial or inferolateral dermoglandular bipedicle flap according to tumor location (inferomedial for BC located in the LOQ, and inferolateral for BC located in the LIQ). The inferior root of the bipedicle dermoglandular flap was conserved but moved along the inframammary fold in the opposite breast lower quadrant. A large excision adapted to tumor extension was subsequently performed in the involved quadrant with an en bloc resection of the tumor and the surrounding glandular tissues with the overlying skin down to the pectoralis fascia. Macroscopic centimeter margins from tumors were taken and surgical clips were placed in the tumor bed. The excised specimen was



**FIG. 2** Surgical technique of the modified McKissock mammaplasty procedure used in OP-S. Step-by-step schematization is presented for an extended breast cancer located in the LIQ. **a** Skin incision is performed following a Wise pattern<sup>11</sup> adapted to breast morphology and planned excision. **b** The skin within the Wise pattern is deepithelialized in order to form a dual vertical dermoglandular bipedicle flap (the inferior root of the bipedicle flap is moved along the inframammary fold in the lower-outer part of the breast). A large excision is performed in the LIQ with an en bloc resection of the tumor and the surrounding glandular tissues with the overlying skin down to the pectoralis fascia. **c** Breast reconstruction is obtained by transposition of the vertical dermoglandular flap and the gland of the

weighted and oriented on a polystyrene plate with inked glandular margins. Subsequent breast reconstruction and reshaping was obtained by transposition of the vertical dermoglandular flap and the gland of the opposite lower quadrant toward the defect. The dermoglandular flap was attached without tension to the pectoral fascia, with a slight rotation of the NAC and a limited skin undermining in the opposite lower quadrant. In this region, the dermoglandular and the skin flaps were undermined cautiously, with preservation of a 1.5 cm thickness of subcutaneous fat to avoid skin ischemia. NAC repositioning and breast closure were performed classically on an ‘inverted T’ scar, which was protected by the inferior deepithelialized pedicle positioned behind the cutaneous scar. Contralateral symmetrization using the classical McKissock technique was performed in some cases during the same intervention or later, several months after the end of the adjuvant treatments according to the excision volume and the patient’s preference.

#### Postoperative Data

Postoperative data included resection weight, tumor sizes (DCIS and invasive components) and resection margins. Histological margins were considered as negative when the distance from the carcinoma to the margin was greater than or equal to 2 mm, and close/positive when the distance was inferior to 2 mm. Postoperative morbidity was analyzed in the first 30 days after surgery using the Clavien–Dindo classification.<sup>8</sup> Adjuvant chemotherapy treatment decisions were taken in pluridisciplinary meetings. All patients received postoperative radiotherapy (50 Gy on the breast and a 16 Gy boost on the tumor bed). The nature and

central and lower-outer quadrants toward the defect (*blue arrow*). The dermoglandular flap is attached in the LIQ without tension to the pectoral fascia, with a slight rotation of the NAC (*black arrow*) and a limited skin undermining in the LOQ. The dermoglandular and skin flaps are undermined cautiously with preservation of a 1–1.5 cm thickness of subcutaneous fat to avoid skin ischemia. **d, e** The NAC repositioning and breast closure are performed classically on an ‘inverted T’ scar that is protected by the inferior deepithelialized pedicle positioned behind the ‘inverted T’ cutaneous scar. *OP-S* oncoplastic surgery, *LIQ* lower-inner quadrant, *LOQ* lower-outer quadrant, *NAC* nipple-areolar complex

starting date of the first adjuvant treatment (radiotherapy or chemotherapy if indicated) were also recorded.

#### Oncological Follow-Up

All patients were clinically evaluated every 6 months after the end of the treatment for evidence of recurrence. Breast mammograms and ultrasounds were performed 6 months after the end of radiotherapy and repeated annually.

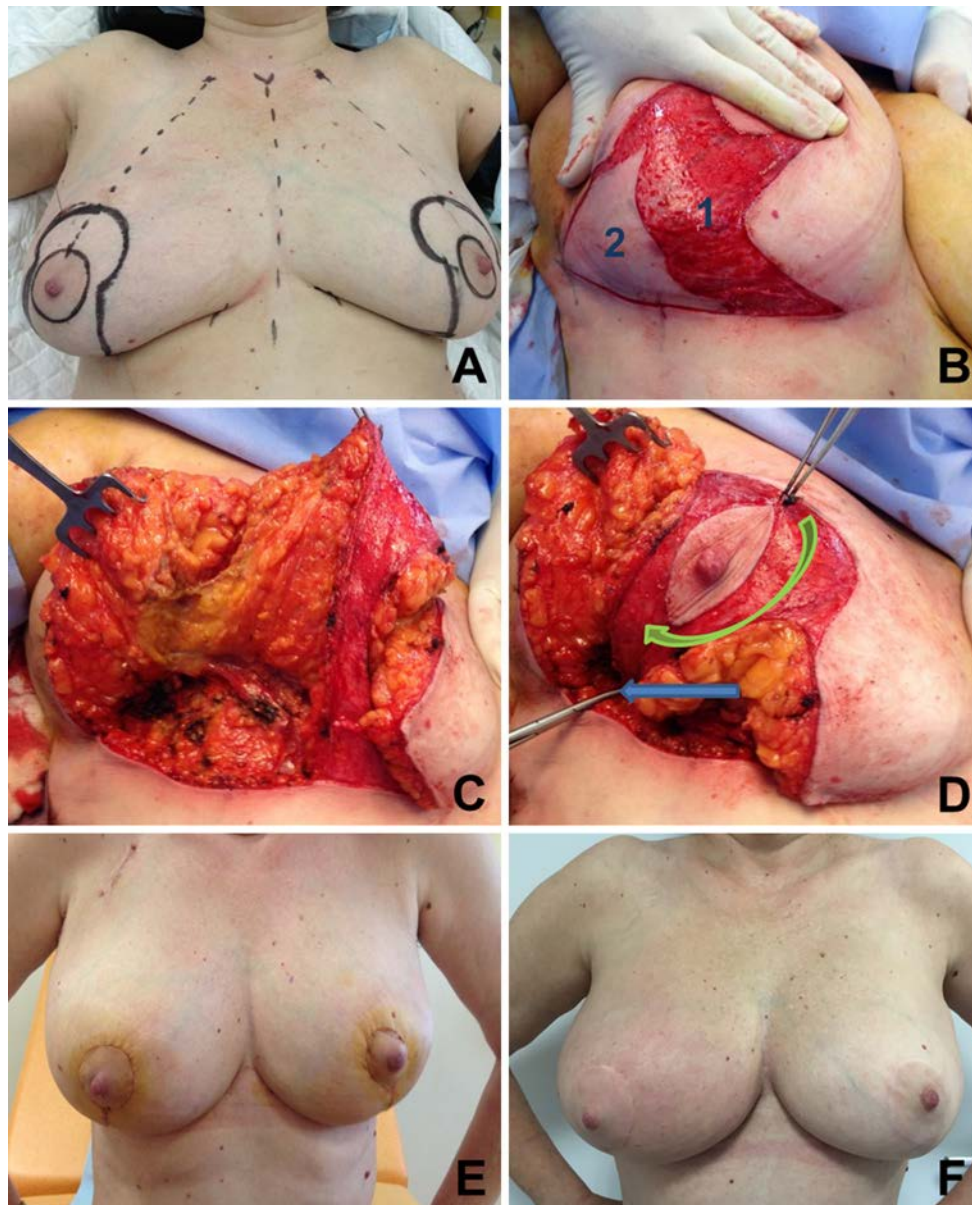
#### Cosmetic Results

The cosmetic result was analyzed 6 months after the end of the adjuvant radiotherapy with a 5-point score, ranging from 1 to 5, based on aesthetic sequelae, as reported previously by Clough et al.<sup>12</sup> Anonymized photographs of the patients were reviewed by a panel of three independent observers (staff not involved in the treatment of these patients), and assigned a score of between 1 and 5. Categories for evaluation included breast shape, NAC position, and breast/nipple symmetry.<sup>12</sup> The average score was used to determine the cosmetic outcome. The patient’s satisfaction was assessed using a questionnaire, including a linear visual analog scale ranging from 0 (not satisfied) to 10 (most satisfied). Evaluation included breast shape, NAC position, and breast symmetry.

## RESULTS

#### Patients

Between 2011 and 2014, 25 patients received an OP-S with the modified McKissock procedure in our institution

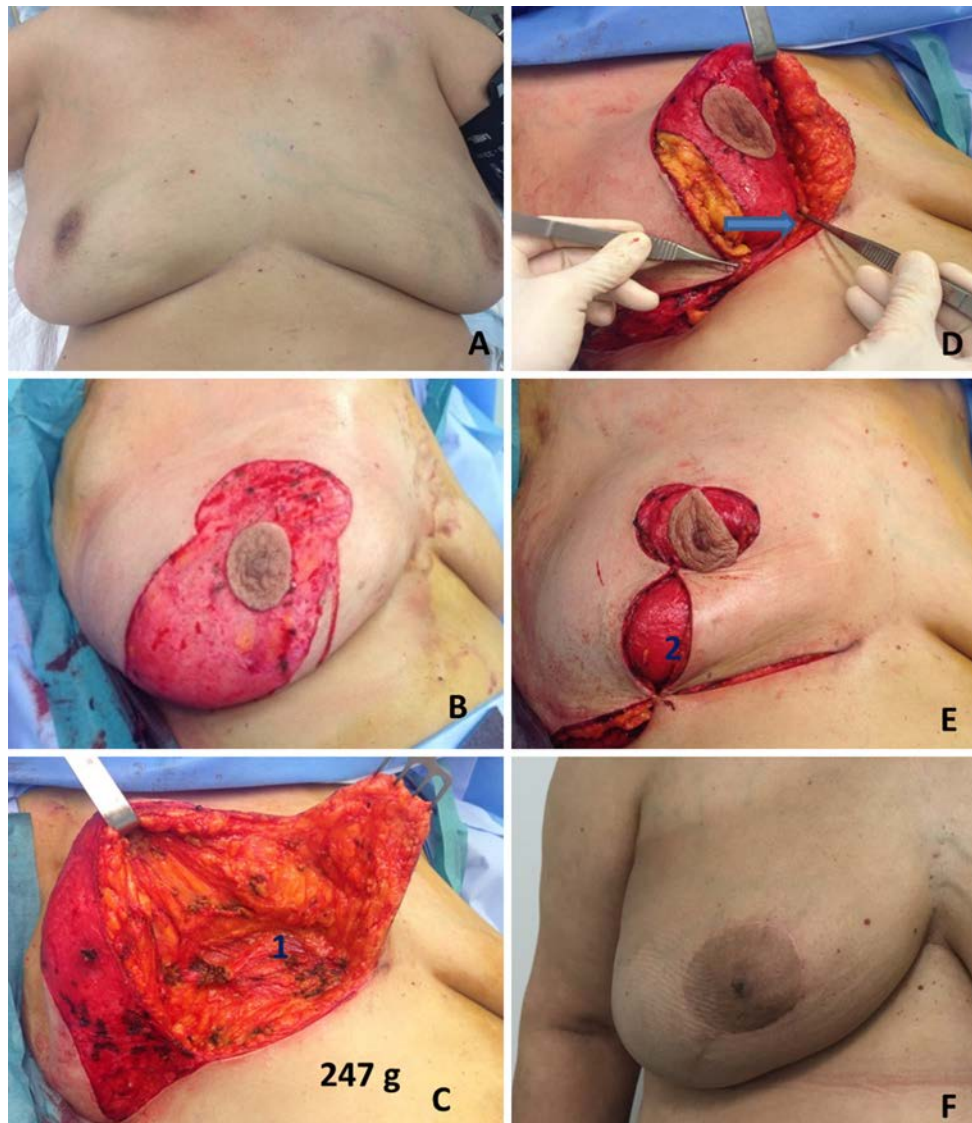


**FIG. 3** Representative photographs of oncoplastic surgery using the modified McKissock procedure for an invasive breast cancer located in the LOQ of the right breast, and reconstruction with an inferomedial and superior bipedicle. The size of the invasive component of breast tumor was 35 mm, and the resection weight was 212 g. **a** Preoperative drawing of the Wise pattern. **b** Periareolar deepithelialization with conservation of a dual dermal deepithelialized pedicle [superior and inferomedial (1)]. The skin (2) and the gland surrounding the breast tumor were largely resected in the lower-

outer breast quadrant. **c** Peroperative breast appearance after tumor resection. **d** Breast reconstruction: the deepithelialized flap is mobilized to fill the defect in the LOQ (blue arrow), with a slight rotation of the nipple-areola complex (green arrow). **e** Immediate postoperative result 14 days after oncoplastic surgery of the right breast and immediate contralateral symmetrization. **f** Appearance of breasts 1 year after the end of adjuvant chemotherapy and radiotherapy. LOQ lower-outer quadrant

(Table 1). Median age was 62 years (range 34–85), median BMI was 24 kg/cm<sup>2</sup> (range 19–38), and smoking was reported in five patients (20 %). Eighteen patients had their tumor located in the LOQ and seven in the LIQ. The tumor corresponded to an invasive BC in 14 cases (possibly associated with a limited DCIS), to an extensive DCIS in five cases and to an invasive BC associated with extensive

DCIS in six cases. Two patients received neoadjuvant chemotherapy (8 %), one with a fragmented response on MRI evaluation justifying OP-S indication (case 20), and the other with a multifocal human epidermal growth factor receptor-2 (HER2)-overexpressed tumor at presentation (case 23). One patient received neoadjuvant hormone therapy with insufficient response to perform a limited



**FIG. 4** Representative photographs of an oncoplastic surgery using the modified McKissock procedure for an invasive breast cancer located in the LIQ of the right breast, and reconstruction with an inferolateral and superior bipedicle. **a** T2N1 breast tumor located in the LIQ of the right breast with partial and fragmented response to neoadjuvant chemotherapy. **b** Preoperative drawing of the Wise pattern, and periareolar deepithelialization with conservation of a dual

dermal deepithelialized pedicle (superior and inferolateral). **c** Breast appearance after large removal of the LIQ (1). Total resection weight, 247 g. **d** Breast reshaping: the deepithelialized flap is mobilized to fill the defect in the LIQ (blue arrow). **e** The breast is closed on an 'inverted T' scar protected by the inferior root of the bipedicle flap (2). **f** Breast appearance 2 months after the end of adjuvant radiotherapy. *LIQ* lower-inner quadrant

lumpectomy (case 9). The most frequent indications for OP-S in this series were multifocal tumors (36 %), extended tumor size (24 %), and extensive DCIS (20 %). The clinical median size of invasive BC was 21 mm (range 0–60). For DCIS, the median extension of microcalcifications on the mammogram was 30 mm (range 0–60).

### Surgery

The mean resection weight was 134 g (range 43–314), and the pathological median tumor size was 23 mm (range

0–63) for invasive BC, and 21 mm (range 0–60) for DCIS. Surgical margins were negative for 22 patients (88 %) and close/positive in three cases (12 %). These last three patients underwent a complementary resection with conservative re-excision ( $n = 2$ ) and a secondary mastectomy ( $n = 1$ ). One patient was subjected to a bilateral prophylactic mastectomy despite free margins after the diagnosis of a BRCA-2 germline mutation. Considering all included patients (25), BCS was obtained with the modified McKissock technique for 23 patients (92 %), and the secondary mastectomy rate was 8 % (2/25).

**TABLE 1** Patient characteristics and operative data

Case	Age (years)	BMI	Cup size	Tumor breast location	Radiologic tumor size (mm)	Indication for OP surgery	Total resection weight (g)	Morbidity	Histological tumor size */## (mm)	Margins (<2 mm)	Re-intervention	Contralateral symmetrization	TNM	Global cosmetic result	Patient's satisfaction
1	34	30	D 34D	LIQ	27 (m)	Multifocality	120	None	10/25 (m)	-	-	Done	pT2 N0	4.4	10
2	70	22	C 36C	LOQ	37	Extended DCIS	122	None	20/11	-	-	Not required	pT1c N0	4.2	9
3	62	28	E 38DD	LIQ	30	Tumor size	97	None	33/28(m)	-	-	Not required	pT2 N1a	4	10
4	51	20	C 36C	LOQ	30	Multifocality	88	None	0/30 (m)	-	Mastectomy (BRCA2)	NA	pT2 N2a	NA	NA
5	66	36	C 42C	LOQ	20	Extended DCIS	164	None	50/7	+	Re-excision	Not required	pT1b N0	4	10
6	48	24	B 34B	LIQ	25	Extended DCIS	61	None	25/8	-	-	Done	pT1b N0	5	10
7	75	23	C 34C	LIQ	20	Multifocality	52	None	10/17 (m)	-	-	Not required	pT1cp N2a	4.3	
8	59	23	C 36C	LOQ	30	Extended DCIS	99	None	31/8	-	-	Done	pT1b N0	5	10
9	85	23	B 40B	LOQ	20	Extended ILC	43	None	0/14	-	-	Not required	ypT1c N0	3.3	10
10	60	38	D 38D	LOQ	7 (m)	Multifocality	117	None	5/10 (m)	-	-	Scheduled	pT1b N2a		
11	52	24	D 40D	LOQ	35	Tumor size	212	None	0/35	-	-	Done	pT2 N0	4.7	8
12	68	22	D 36D	LOQ	19 (m)	Multifocality	314	Hematoma	0/63	+	Mastectomy	NA	pT3 N0	NA	NA
13	75	36	D 36D	LOQ	10 (m)	Multifocality	147	None	60/8	-	-	Not required	pT1b N0	4	10
14	43	24	D 38D	LOQ	22	Extended DCIS	94	None	32/0	-	-	Done	pTis N0	5	10
15	60	27	E 36DD	LOQ	40	Multifocality	87	None	20/24 (m)	-	-	Done	pT2 N1a	5	9
16	65	24	C 34C	LOQ	28	Tumor size	77	None	0/29	-	-	Done	pT2 N1a	4	9
17	49	38	E 38DD	LOQ	60	Extended DCIS	306	Delayed wound healing	55/0	-	-	Done	pTis Nx	5	9
18	53	29	D 40D	LOQ	40	Extended DCIS	265	Hematoma	50/0	+	Re-excision	Done	pTis N0	4	9

TABLE 1 continued

Case	Age (years)	BMI	Cup size French/US	Tumor breast location	Radiologic tumor size (mm)	Indication for OP surgery	Total resection weight (g)	Morbidity	Histological tumor size ** (mm)	Margins (<2 mm)	Re-intervention	Contralateral symmetrization	TNM	Global cosmetic result	Patient's satisfaction
19	62	29	C 34C	LOQ	30	Tumor size	154	None	10/40	-	-	Scheduled	pT2 N1mi	-	-
20	67	27	D 40D	LIQ	50	Fragmented response to NAC	247	None	30/0	-	-	Scheduled	ypTis N0	-	-
21	44	24	C 36C	LOQ	45	Multifocality	94	None	40/21(m)	-	-	Scheduled	pT2 N1a	-	-
22	67	21	B 34B	LIQ	33	Extended ILC	45	None	0/21	-	-	Scheduled	pT2 N0	-	-
23	56	28	C 36C	LIQ	40	Multifocality	122	None	50/0	-	-	Scheduled	ypTis N0	-	-
24	78	19	B 34B	LOQ	25	Tumor size	66	None	5/25	-	-	Scheduled	pT2 N1a	-	-
25	79	21	D 34D	LOQ	40	Tumor size	157	None	0/35	-	-	Scheduled	pT2 N3a	-	-

BMI body mass index, OP oncoplastic, TNM tumor node metastasis stadification, LIQ lower-inner quadrant, LOQ lower-outer quadrant, m multifocal, DCIS ductal carcinoma in situ, ILC invasive lobular carcinoma, NAC nipple-areola complex, NA not applicable

### Adjuvant Treatments

All patients included in the study received postoperative radiotherapy. Adjuvant chemotherapy was indicated for 13 patients, all of whom received this treatment, with a median delay of 42 days (range 22–65) between surgery and the first chemotherapy cycle. For patients without chemotherapy, the median delay of radiotherapy initiation was 60 days (range 49–108). Considering all patients, the median delay between surgery and the first adjuvant treatment was 55 days (range 22–108).

### Morbidity

Two patients experienced postoperative grade III–IV complications according to the Clavien–Dindo classification.<sup>8</sup> Both patients required postoperative reintervention for hematoma drainage on postoperative day 2, and both had received curative anticoagulant treatment for a cardiovascular disease in the early postoperative period. Another patient experienced delayed wound healing that resulted in a favorable outcome with adapted dressing, but postponed radiotherapy initiation. The global morbidity rate including all grade I–IV complications was 12 % (3/25). No NAC ischemia or necrosis was observed in this study, either intra- or postoperatively.

### Postoperative Outcomes

Median follow-up was 25 months (range 11–49) after the date of surgery. No intramammary local breast recurrence was observed after a median follow-up of 22 months (range 7–44). One tumor recurred in retropectoral lymph nodes after the end of adjuvant chemotherapy and required complementary chemotherapy and lymphadenectomy.

### Cosmetic Outcomes and Patient Satisfaction

At the time of the study, contralateral symmetrization was performed in nine cases, and was required or scheduled in eight cases (17/23) (Table 1). Six patients did not require contralateral surgery according to the patient's and surgeon's opinion. Cosmetic evaluation was available for patients receiving definitive BCS and for whom contralateral symmetrization was carried out or was not required ( $n = 15$ ) (electronic supplementary Fig. S3). Patients with secondary mastectomy and patients scheduled for contralateral symmetrization were excluded from the cosmetic evaluation. The score was rated 'excellent' or 'good' (4–5/5) and 'fair' (3/5) in 13 and 1 patients, respectively. Median score was 4.4. No poor or bad cosmetic results were observed. The patient's satisfaction was evaluated for these 15 patients, and the median score was rated 9.6.



## DISCUSSION

Large removal of BC located in the lower quadrants may result in significant breast cosmetic sequelae after BCS and radiotherapy, including breast retraction and NAC bascule.<sup>13,14</sup> OP-S techniques employed for tumors situated at the lower-quadrants junction generally consist of an ‘inverted T’ scar with the skin and gland resection within the reduction pattern.<sup>6,13</sup> When the resection is more laterally positioned in the inner or outer quadrant, the glandular removal requires large undermining with the conservation of a glandular flap released from the skin and the pectoralis fascia. This can lead to glandular ischemia and fat necrosis, with consequent delay in wound healing and poor cosmetic results.<sup>8</sup> Moreover, regardless of tumor location, NAC transposition with a single dermal pedicle may be complicated by ischemia with the risk of partial or total necrosis (Fig. 1). These complications, common in the cases of diabetes or smoking, may delay adjuvant chemotherapy initiation. A recent study underlined that aggressive BC experienced adverse outcomes when chemotherapy was initiated more than 60 days after surgery.<sup>15</sup>

Specific OP-S techniques dedicated to the LIQ and the LOQ are employed in clinical practice. The ‘crescent’ technique allows the reconstruction of the lower quadrants using a deepithelialized fasciocutaneous flap at the inframammary fold. Recently, the LIQ-V technique was described, with promising preliminary results for tumors located in the LIQ.<sup>14</sup> Similarly, the ‘tennis racket’ and the ‘L’ mammaplasty were described for the LOQ resection. These techniques form part of the breast surgeon’s skill set but are not always usable, depending on breast and patient morphologies, particularly for hypertrophic or ptotic breasts.

In this study, the authors describe an OP-S technique derived from the McKissock mammaplasty procedure, available for moderated to large breast volumes. This technique conserved a bipedicle dermoglandular flap for NAC transposition and breast reshaping, and resulted in a low rate of postoperative complications and in the conservation of the protection against NAC ischemia. The number of patients included in this pilot study was limited; however, no instance of NAC necrosis, even partial, was observed for analyzed patients despite a significant smoking rate. In contrast, a recent study reported a 10 % rate of NAC necrosis after an ‘inverted T’ OP-S.<sup>16</sup> This favorable postoperative outcome allows the use of the aforementioned technique in ambulatory surgery without specific postoperative surveillance. Moreover, the bipedicle flap enables the displacement of the remaining gland from the central and lower parts of the breast towards the defect in the resected quadrant. This flap also supplies the remaining gland and provides high protection against glandular ischemia that can be associated with infection, delayed

wound healing, and long-term fat necrosis.<sup>7</sup> The bipedicle flap, positioned like an ‘internal brassiere’, supports the remaining breast tissue, reducing pressure on the scar, and restores, at a distance, the harmonious shape of the lower breast quadrants (Fig. S3). These theoretical data were confirmed in our study with the observation of a low rate of delayed wound healing despite extended resections and the absence of evolution towards fat necrosis formation. Another important consequence of the favorable postoperative outcome is the controlled delay in the start of chemotherapy observed for patients requiring adjuvant chemotherapy. Only one patient experienced a significant delay in radiotherapy initiation (delayed wound healing). Cosmetic evaluation and patient satisfaction were also favorable after adjuvant radiotherapy.

Our oncological postoperative results, in terms of quality of resection, confirmed that the described technique allows wide resection of BC in the lower parts of the breast, with high resection weights. All patients included in this study had BC that was not suitable for BCS without OP-S techniques. However, free margins were achieved for 21/25 cases with the use of this procedure (84 %). The rate of close/positive margins observed in this study (17 %) was comparable with that observed in experienced OP-S centers reporting 9–19 % rates of close/positive margins.<sup>3,6,17</sup> Our 8 % rate of secondary mastectomy is also similar to that observed in larger studies.<sup>3</sup> A longer follow-up is required to evaluate the long-term local recurrence rate of the described technique.

Despite its favorable postoperative outcome, the modified McKissock technique has some disadvantages. The technique induced an ‘inverted T’ scar along the inframammary fold that could impair long-term breast cosmesis. Breast reduction and reshaping modified breast appearance and frequently required immediate or secondary contralateral symmetrization. A second potential limitation of the modified McKissock technique is the requirement of extended gland transection explaining the postoperative hematoma observed in patients receiving postoperative anticoagulant treatment. This procedure should be employed with caution when anticoagulant treatment is mandatory in the immediate postoperative period, and requires experienced surgeons trained in breast reduction techniques.

## CONCLUSIONS

In this pilot study, the modified McKissock technique appeared as a safe and reliable OP-S technique for the resection of extended BC or DCIS located in the LIQ or the. In an experienced team, this technique provided high vascular protection of the nipple and the remaining gland,

and produced a low postoperative morbidity rate with favorable oncological results and high patient satisfaction. These features are of clinical interest for OP-S and justify larger evaluation with long-term cosmetic and oncological evaluation in multicentric studies.

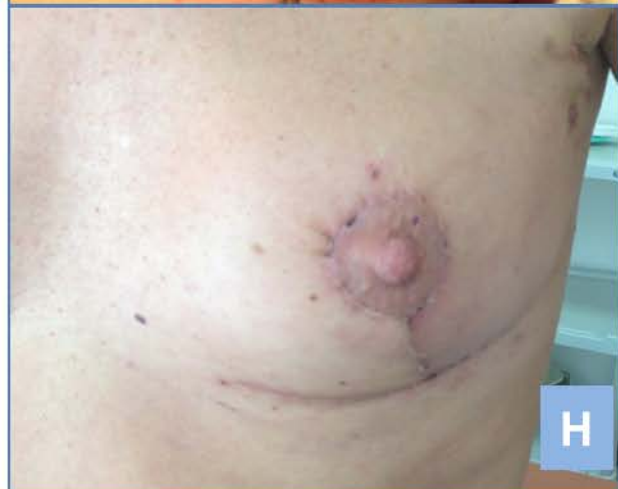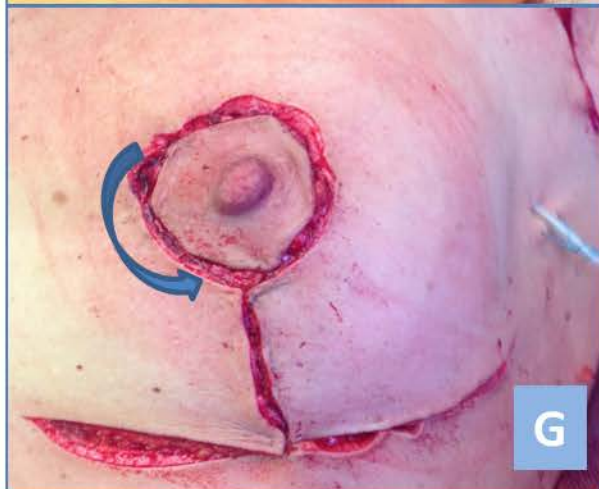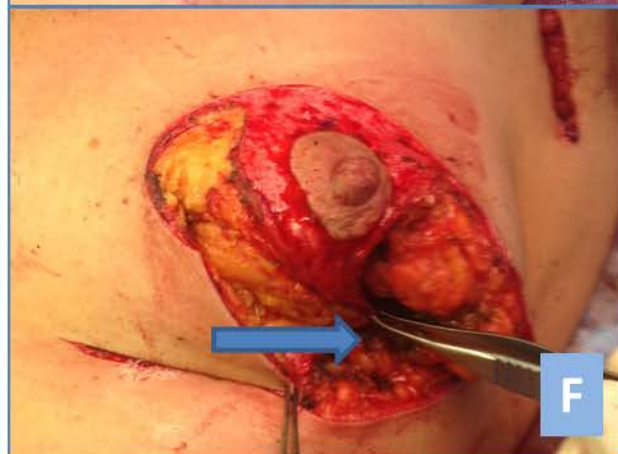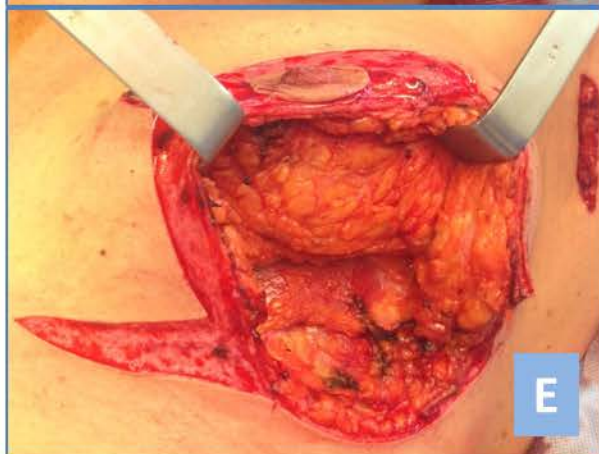
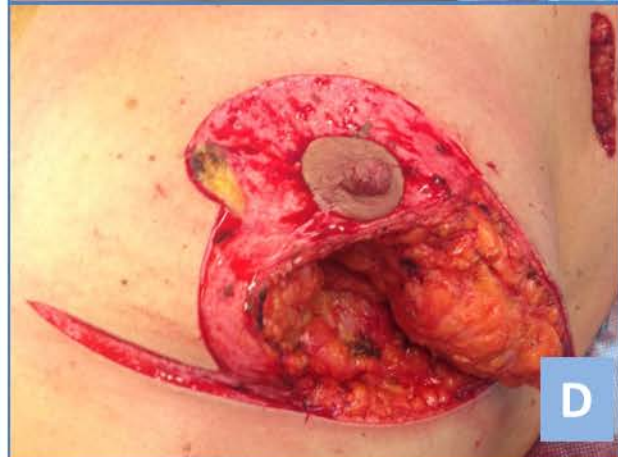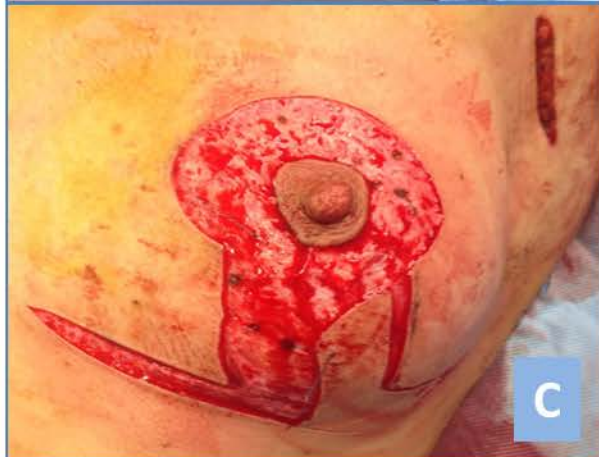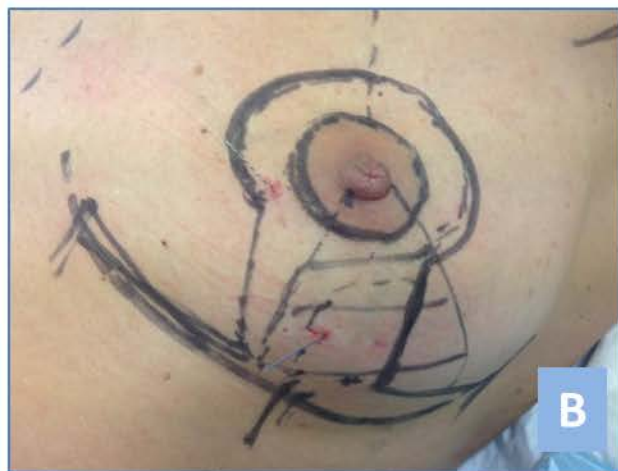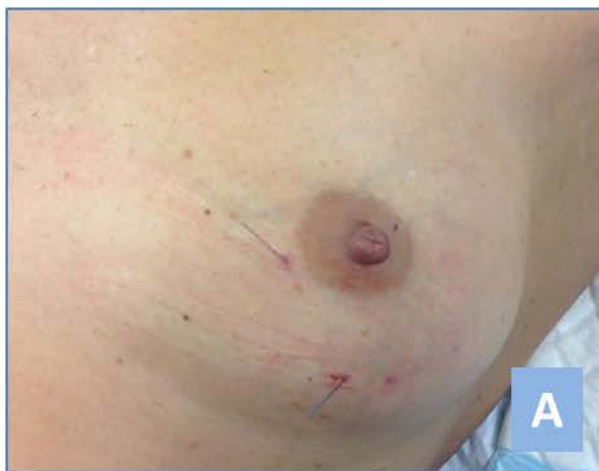**ACKNOWLEDGMENT** The authors thank Dr. H. de Forges and Oliver Wakeli for pre-submission editorial assistance. The authors thank Krishna B. Clough for provided expert advice.

**DISCLOSURES** Pierre-Emmanuel Colombo, Marine Lefèvre, Laure Delmond, Drissa Traore, William Jacot, Anne Mourregot, Marian Gutowski, Martin M. Bertrand, and Philippe Rouanet have no conflicts of interest to disclose, including specific financial interests and relationships relevant to the subject matter or materials discussed in this article. No funding was received for the presented work.

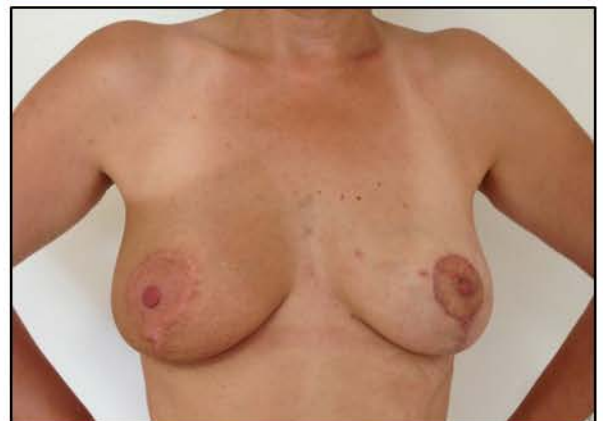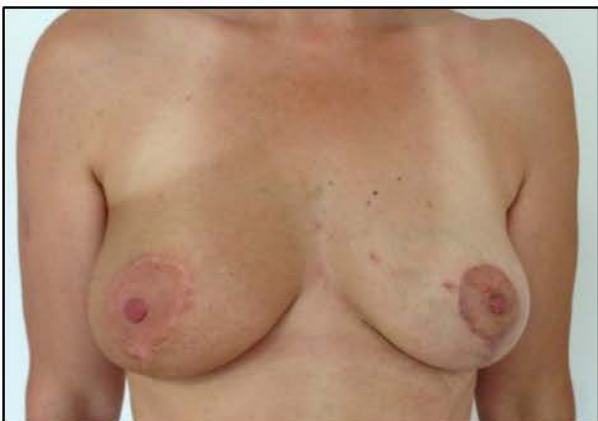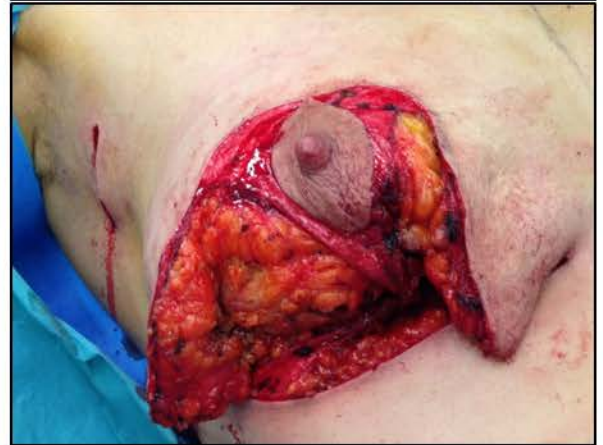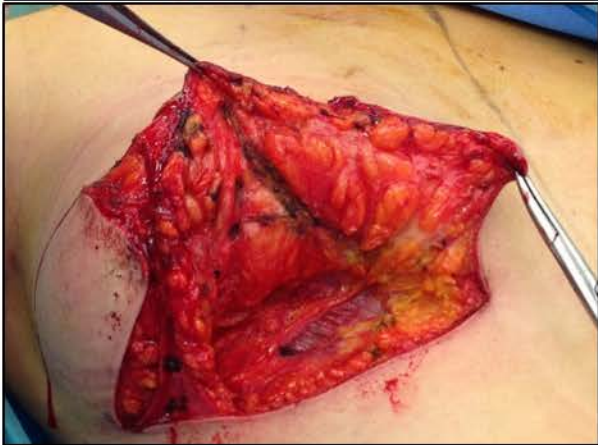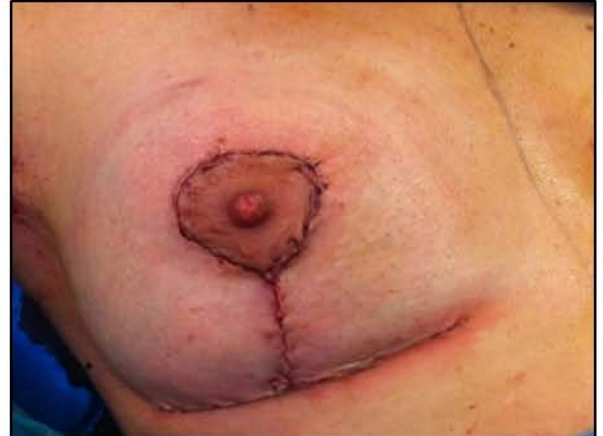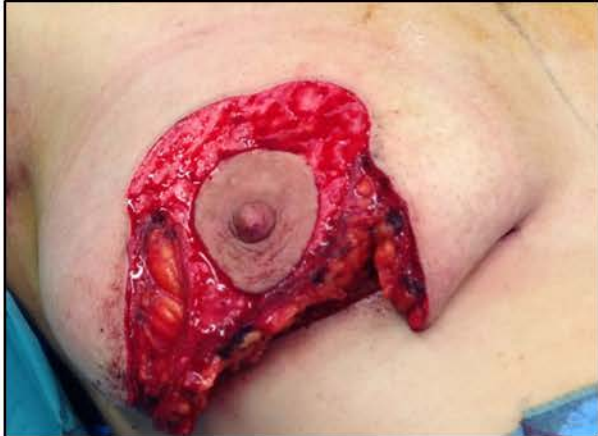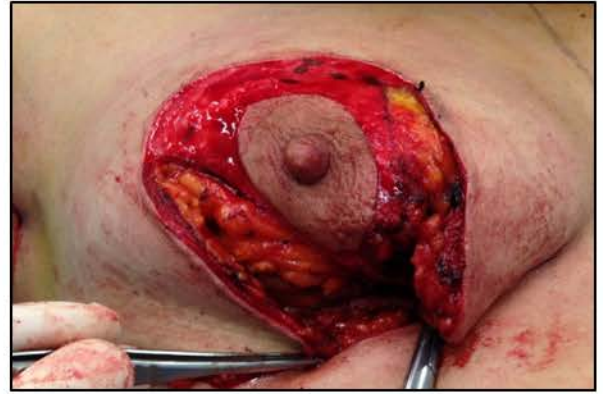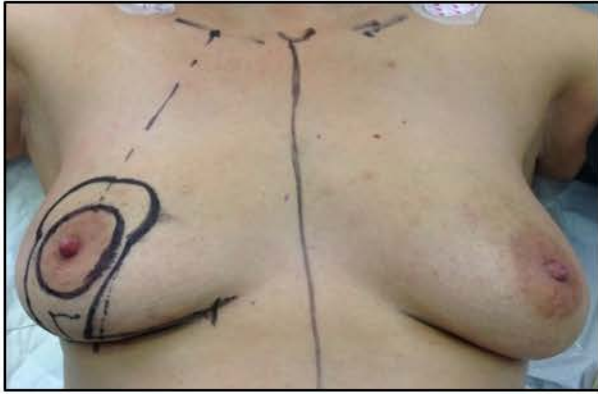## REFERENCES

1. Cochrane RA, Valasiadou P, Wilson AR, Al-Ghazal SK, Macmillan RD. Cosmesis and satisfaction after breast-conserving surgery correlates with the percentage of breast volume excised. *Br J Surg.* 2003;90(12):1505–9.
2. Clough KB, Kaufman GJ, Nos C, Buccimazza I, Sarfati IM. Improving breast cancer surgery: a classification and quadrant per quadrant atlas for oncoplastic surgery. *Ann Surg Oncol.* 2010;17(5):1375–91.
3. Fitoussi AD, Berry MG, Fama F, et al. Oncoplastic breast surgery for cancer: analysis of 540 consecutive cases [outcomes article]. *Plast Reconstr Surg.* 2010;125(2):454–62.
4. Urban C, Lima R, Schunemann E, Spautz C, Rabinovich I, Anselmi K. Oncoplastic principles in breast conserving surgery. *Breast.* 2011;20 Suppl 3:S92–5.
5. Rietjens M, Urban CA, Rey PC, et al. Long-term oncological results of breast conservative treatment with oncoplastic surgery. *Breast.* 2007;16(4):387–95.
6. Clough KB, Ihrai T, Oden S, Kaufman G, Massey E, Nos C. Oncoplastic surgery for breast cancer based on tumour location and a quadrant-per-quadrant atlas. *Br J Surg.* 2012;99(10):1389–95.
7. Tenofsky PL, Dowell P, Topalovski T, Helmer SD. Surgical, oncologic, and cosmetic differences between oncoplastic and nononcoplastic breast conserving surgery in breast cancer patients. *Am J Surg.* 2014;207(3):398–402; discussion 402.
8. Panhofer P, Ferenc V, Schutz M, et al. Standardization of morbidity assessment in breast cancer surgery using the Clavien Dindo Classification. *Int J Surg.* 2014;12(4):334–9.
9. McKissock PK. Reduction mammoplasty with a vertical dermal flap. *Plast Reconstr Surg.* 1972;49(3):245–52.
10. McKissock PK. Reduction mammoplasty by the vertical bipedicle flap technique. Rationale and results. *Clin Plast Surg.* 1976;3(2):309–20.
11. Wise RJ. A preliminary report on a method of planning the mammoplasty. *Plast Reconstr Surg.* 1956;17(5):367–75.
12. Clough KB, Cuminet J, Fitoussi A, Nos C, Mosseri V. Cosmetic sequelae after conservative treatment for breast cancer: classification and results of surgical correction. *Ann Plast Surg.* 1998;41(5):471–81.
13. Nos C, Fitoussi A, Bourgeois D, Fourquet A, Salmon RJ, Clough KB. Conservative treatment of lower pole breast cancers by bilateral mammoplasty and radiotherapy. *Eur J Surg Oncol.* 1998;24(6):50814.
14. Clough KB, Oden S, Ihrai T, Massey E, Nos C, Sarfati I. Level 2 oncoplastic surgery for lower inner quadrant breast cancers: the LIQ-V mammoplasty. *Ann Surg Oncol.* 2013;20(12):3847–54.
15. Gagliato Dde M, Gonzalez-Angulo AM, Lei X, et al. Clinical impact of delaying initiation of adjuvant chemotherapy in patients with breast cancer. *J Clin Oncol.* 2014;32(8):735–44.
16. Kronowitz SJ, Hunt KK, Kuerer HM, et al. Practical guidelines for repair of partial mastectomy defects using the breast reduction technique in patients undergoing breast conservation therapy. *Plast Reconstr Surg.* 2007;120(7):1755–68.
17. Meretoja TJ, Svarvar C, Jahkola TA. Outcome of oncoplastic breast surgery in 90 prospective patients. *Am J Surg.* 2010;200(2):224–8.

Fig.S1



**Fig. S2**



**Fig. S3**

