



HAL
open science

Epidermolysis bullosa simplex generalized severe induces a Th17 response and is improved by Apremilast treatment

E. Castela, M. K. Tulic, Aurore Rozières, E. Bourrat, Jean-François Nicolas, J. Kanitakis, P. Vabres, D. Bessis, J. Mazereeuw, F. Morice-Picard, et al.

► To cite this version:

E. Castela, M. K. Tulic, Aurore Rozières, E. Bourrat, Jean-François Nicolas, et al.. Epidermolysis bullosa simplex generalized severe induces a Th17 response and is improved by Apremilast treatment. *British Journal of Dermatology*, 2018, 10.1111/bjd.16897 . hal-01911034

HAL Id: hal-01911034

<https://hal.science/hal-01911034v1>

Submitted on 13 Jan 2025

HAL is a multi-disciplinary open access archive for the deposit and dissemination of scientific research documents, whether they are published or not. The documents may come from teaching and research institutions in France or abroad, or from public or private research centers.

L'archive ouverte pluridisciplinaire **HAL**, est destinée au dépôt et à la diffusion de documents scientifiques de niveau recherche, publiés ou non, émanant des établissements d'enseignement et de recherche français ou étrangers, des laboratoires publics ou privés.

University of Dundee

Epidermolysis bullosa simplex generalized severe induces a T helper 17 response and is improved by apremilast treatment

Castela, E.; Tulic, M. K.; Rozières, A.; Bourrat, E.; Nicolas, J.-F.; Kanitakis, J.

Published in:
British Journal of Dermatology

DOI:
[10.1111/bjd.16897](https://doi.org/10.1111/bjd.16897)

Publication date:
2019

Document Version
Peer reviewed version

[Link to publication in Discovery Research Portal](#)

Citation for published version (APA):

Castela, E., Tulic, M. K., Rozières, A., Bourrat, E., Nicolas, J.-F., Kanitakis, J., Vabres, P., Bessis, D., Mazereeuw, J., Morice-Picard, F., Baty, D., Berard, F., Lacour, J.-P., Passeron, T., & Chiaverini, C. (2019). Epidermolysis bullosa simplex generalized severe induces a T helper 17 response and is improved by apremilast treatment. *British Journal of Dermatology*, 180(2), 357-364. <https://doi.org/10.1111/bjd.16897>

General rights

Copyright and moral rights for the publications made accessible in Discovery Research Portal are retained by the authors and/or other copyright owners and it is a condition of accessing publications that users recognise and abide by the legal requirements associated with these rights.

Take down policy

If you believe that this document breaches copyright please contact us providing details, and we will remove access to the work immediately and investigate your claim.

PROFESSOR DIDIER BESSIS (Orcid ID : 0000-0002-3815-5417)

PROFESSOR JULIETTE MAZEREUW-HAUTIER (Orcid ID : 0000-0001-6259-9790)

DR FANNY MORICE-PICARD (Orcid ID : 0000-0002-4316-916X)

DR CHRISTINE CHIAVERINI (Orcid ID : 0000-0002-6063-5409)

Article type : Original Article

Epidermolysis bullosa simplex generalized severe induces a Th17 response and is improved by Apremilast treatment

Epidermolysis bullosa simplex generalized severe is an inflammatory disease

E. Castela ^{1,2}, M. K. Tulic ³, A. Rozières ², E. Bourrat ⁴, J.-F. Nicolas ^{2,5}, J. Kanitakis ^{6,7}, P. Vabres ⁸, D. Bessis ⁹, J. Mazereeuw ¹⁰, F. Morice-Picard ¹¹, D. Baty¹², F. Berard ⁵, J.-P. Lacour ^{1,13}, T. Passeron ^{1,3}, C. Chiaverini ^{1,13}

¹Department of Dermatology, CHU de Nice, France, ²INSERM U1111-CIRI851, Université Lyon1, France, ³INSERM U1065, Team 12, C3M, Nice, France, ⁴MAGEC, Saint-Louis Hospital, Paris, France, ⁵Department of Allergology and Clinical Immunology, Hospices Civils de Lyon, France, ⁶Department of Dermatology, Hospices Civils de Lyon, France, ⁷Department of Pathology, Hospices Civils de Lyon, France, ⁸Department of Dermatology, CHU de Dijon, France, ⁹Department of Dermatology, CHU de Montpellier, France, ¹⁰CRMRP, CHU de Toulouse, France, ¹¹CRMRP, CHU de Bordeaux, France, ¹²Scottish

This is the peer reviewed version of the following article: Castela, E., et al. (2018) 'Epidermolysis bullosa simplex generalized severe induces a Th17 response and is improved by Apremilast treatment', *British Journal of Dermatology*, which has been published in final form at <https://doi.org/10.1111/bjd.16897>. This article may be used for non-commercial purposes in accordance with Wiley Terms and Conditions for Self-Archiving.

This article is protected by copyright. All rights reserved.

Molecular Genetics Consortium, Ninewells Hospital, Dundee, Scotland, ¹³CREBHN, CHU de Nice, France.

Word count: 2575, Number of references: 30, Table: 1, Figures: 7

Corresponding author:

Christine Chiaverini, MD, PhD

CREBHN, Department of Dermatology, CHU de Nice, Hôpital Archet 2,

151 route de saint Antoine de Ginestière 06202 Nice Cedex 2 France

chiaverini.c@chu-nice.fr

This article was funded by DEBRA France and by a grant from the CHU of Nice, France.

IRB number: 12.001

The authors have no conflict of interest to declare.

This work has never been published before

BULLETED STATEMENTS

What is already known on this topic?

Epidermolysis bullosa simplex generalized severe (EBS-gen sev) is a rare disabling skin disorder related to skin fragility.

What this article adds to our knowledge?

This article is protected by copyright. All rights reserved.

We showed the presence of an immune infiltrate characterized by a Th17 phenotype in the skin of EBS-gen sev patients, and a marked improvement of skin condition in EBS patients after treatment with Apremilast, an anti-Th17 molecule.

SUMMARY

Background: Epidermolysis bullosa simplex generalized severe is a genetic disorder caused by mutation in *KRT5* or *KRT14* genes. Usually considered as a mechanical disease, recent data argue for additional inflammatory mechanisms.

Objectives: The aim of this study was to assess the inflammation in the skin of patients with EBS.

Methods: A first immunohistochemical retrospective study was performed on frozen skin samples from 17 EBS-gen sev patients. A second multicenter prospective study was conducted on 10 patients with severe EBS-gen sev. Blister fluid and epidermis were processed for immunochemistry analysis and quantitative real time PCR. Cytokine expression was analyzed in blister fluid and compared with controls.

Results: Histological analysis showed a constant dermal perivascular CD4+ lymphocytes infiltrate in skin biopsies of blister (n=17) as well as in rubbed skin (n=5), an epidermal infiltration of neutrophils and eosinophils in 70% of cases and an increased immunostaining for CXCL9 and CXCL10 in blistering skin. High levels of Th17 cytokines were detected in lesional skin. Three adult patients with EBS-gen sev were treated with apremilast with a dramatic improvement of skin blistering and good tolerance.

Conclusion: Our study demonstrates the importance of inflammation in EBS-gen sev patients and underlines the key role for Th17 cells in its pathogenesis. In addition, this study provides promising new therapeutic approaches for this disabling disorder.

INTRODUCTION

Epidermolysis bullosa is a group of hereditary disorders characterized by skin and mucosal fragility resulting in post-traumatic blistering¹. In EB simplex generalized severe (EBS-gen sev), blisters are present at birth, have a herpetiform pattern² and involve mucosa. Progressive improvement with age is common, but there is an increased neonatal mortality due to development of severe infections³. The disease results from mutations affecting either keratin 14 (K14) or 5 (K5), type I and type II intermediate filament (IF) proteins, respectively, expressed in basal keratinocytes in the epidermis⁴. EBS-gen sev was initially considered to be a mechanical disease due to the fragility of the patients' keratinocytes⁵. However, this theory fails to explain all the clinical features of the disease and recent studies have suggested that additional inflammatory mechanisms may be involved⁶⁻¹¹. The later hypothesis is supported by growing evidence for distinct regulatory functions of keratins in skin immunity and inflammation¹²⁻¹⁵, and encouraging results of topical anti-inflammatory treatments¹⁶. We have shown, for the first time, the presence of an immune infiltrate characterized by a Th17 phenotype in the skin of EB gen-sev patients, and a marked improvement of skin condition in EBS-gen sev patients after the use of Apremilast, an anti-Th17 molecule, suggesting a promising new treatment of this disabling disorder.

MATERIAL AND METHODS

The aim of this study was to analyze the skin inflammation associated with EBS-gen sev. Our study consisted of 2 parts: first, an immune-histochemical retrospective study using frozen skin samples and secondly, a multi-center prospective study. Molecular analysis was performed by the Scottish Molecular Genetic Consortium of Dundee University as previously described¹⁷.

Patients

Retrospective study: All patients with EBS-gen sev, who had skin biopsies at the edge of a non-infected blister taken between 1996 and 2012 for diagnosis and whose tissue was stored at -80°C were enrolled following their written consent. Diagnosis of EBS-gen sev was established on the association of clinical and immune-histological criteria.

Prospective study design: Patients older than 1 year of age from both sexes, who were diagnosed with EBS-gen sev, and who developed more than 2 new blisters *per* day, were eligible for this study. Six French centers participated during the period (March-October 2012). All procedures were approved by the Human Ethics Committees. Informed consent was obtained from all patients. In each center, following dermatological examination of the patient, the investigators filled in a standardized questionnaire and obtained the following biological samples: a) liquid content of at least 3 blisters (pooled in the same dry tube), and b) 2 blister roofs (one fixed in formalin for immunohistochemistry and one in RNAlater for RNA extraction).

Controls: Samples were obtained from 4 healthy volunteers, in whom blisters were induced by mechanical suction of the skin.

Therapeutic pilot study: Following the promising results seen with the initial biological data obtained, we proposed to 3 EBS-gen sev adult patients with disabling generalized blistering to start treatment with Apremilast.

Histological and Immuno-histochemical analysis

For the retrospective study, most skin samples were frozen. For the prospective study, the roofs of blisters had been conserved in Tissue-Tek® and stored at -80°C.

Skin sections were prepared and stained with hematoxylin-phloxine-saffron (HPS) (for assessing the cellular infiltrate), and immune-labeled for CD4 and CD8 T-cells or chemokine (C-X-C motif) ligands CXCL-9 and CXCL10. Detailed technique is available in supplementary data 1.

Analysis of gene expression in the blister roofs / RNA extraction and RT-PCR:

After fixation of blister roofs in RNAlater for 24 hours at 4°C, total RNA was extracted using the RNeasy extraction Kits (Qiagen) according to the manufacturer's protocol. RNA quantity was measured using a Nanodrop Spectrophotometer ND8000 (Thermo Fisher Scientific, Waltham, MA, USA). cDNA was prepared by reverse transcription with oligo-dT using the Omniscript RT kit (Qiagen) and used as a template for amplification by PCR with specific primers directed against Th1, Th2 and Th17 cytokine genes. mRNA was expressed as relative quantity above housekeeping gene control.

Cytokine analysis in the blister fluid:

The blister fluids were stored at 4°C and sent to the lab within 24 hours. Liquids were centrifuged at 2000 rpm for 10 minutes at 4°C. The supernatants were collected and frozen at -80°C. Immunoassays based on Luminex™ xMAP™ (multi-analyze profiling) technology was done on the blister's fluid for detection and quantitation of cytokines.

RESULTS:

EBS-gen sev patients have clinical hallmarks of inflammatory skin disease

Seventeen patients with EBS-gen sev were included in the retrospective study and 10 in the prospective study. Five patients participated in both arms of the study. Clinical and biological features are summarized in Table 1.

All patients had flare-ups of their disease and complained of spontaneous and unexplained flare-ups. Interestingly, inflammatory or general factors such as cutaneous infection (7/10), vaccines (2/10), teeth eruption (4/10) and fever (3/10) were reported to induce blisters whereas improvement was induced by protecting the skin from friction and cold, application of topical steroids (4/10), fever (3/10) and use of local or systemic antibiotics (7/10).

The blisters were often preceded by erythema, suggesting a pre-existing local inflammation (8/10) and in those cases, some patients reported that topical application of steroids could prevent the onset of blisters.

The mean duration of wound healing ranged from a few days (4/10) to two weeks (3/10). The majority of patients reported the development of non-healing blisters (8/10) over friction areas, with chronic extensive blisters. Emollient creams or petrolatum cream (6/10) and also topical antibiotics (7/10) were reported to be effective by patients, even without clinical infection.

Patients with EBS-gen sev have a perivascular dermal CD4+ lymphocytic infiltrate in blistering and rubbed skin.

Twenty-two frozen skin biopsies were analysed in the retrospective study. Among the 17 patients included, 5 had also a skin biopsy taken from rubbed, normal-looking skin. Examination of the HPS-stained sections showed a dermal inflammatory infiltrate in all

biopsies (Figure 1a). This infiltrate was always localized in the superficial dermis with a perivascular distribution; it was sparse (+) in 11 biopsies, moderate (++) in 9 biopsies and dense (+++) in 2 biopsies. Infiltrating cells were predominantly lymphocytic; neutrophils were detected in only 2 patients and eosinophils in 1 patient.

Immuno-histochemical staining for T-cell antigens showed that the inflammatory infiltrate mainly consisted of CD3+ T lymphocytes (Fig. 1b). Analysis of the lymphocytic subsets CD4 and CD8 T cells (Fig. 1c and 1d) showed that the infiltrate mainly composed of CD4+ lymphocytes (19/21 cases) (Fig. 1c). There was no difference in the type and the degree of immune infiltrate according to the mutational profile (*KRT5* vs *KRT14*). Interestingly, analysis of biopsies taken from rubbed skin showed similar results (Supplementary Fig. 1).

Infiltration with eosinophils and neutrophils can be present in lesional skin (Fig. 2)

For 5 patients from the retrospective study, histological analysis of a non-frozen skin biopsy of a blister was possible. An eosinophilic infiltrate was present in 4 of these patients in the dermis (4) and/or the epidermis (2). These eosinophils were not visible on the frozen sections, suggesting the limitation of this technique.

The prospective study included 10 roof blisters. Immunocytochemistry showed necrosis of the epidermis in all patients. Six patients had a dense epidermal neutrophilic infiltrate with eosinophils in 2 cases. In two patients the infiltrate was merely made of eosinophils. Two patients had no inflammatory cells in the epidermis.

The blister roof and fluid of EBS-gen sev overexpress Th17 cytokines (Fig. 3- 4).

Analysis of cytokine mRNA expression by Q-PCR in the blister roof was possible for 6 patients and results were compared to 4 controls. The levels of interleukin (IL) 8, a neutrophil chemoattractant produced by keratinocytes and macrophages, were elevated in all patients

(6/6), as were markers of Th17 immune response, including IL-17 (6/6), IL-21 (6/6) and IL-22 (4/6), which were significantly elevated compared with controls (Figure 3). The levels of Th1 [interferon gamma (IFN γ) and tumor necrosis factor alpha (TNF α)] and Th2 cytokines (IL-4, IL-5) remained unchanged, however T-regulatory cytokines [IL-10 and transforming growth factor beta (TGF β)] were elevated above baseline in 4/6 and 6/6 patients, respectively (Fig. 3).

The cytokine protein content of the blister fluid was analyzed in 8 EBS-gen sev patients and was compared with the blister fluid from 4 healthy controls. We found significantly increased levels of TNF α and Chemokine (C-C motif) ligand 20 (CCL20), two inflammatory cytokines, IL-5 (a Th2 cytokine) and IL-22 (Fig. 4). Other Th2 cytokines, such as IL-4 and IL-13, remained unchanged. The levels of Th1 cytokines IFN γ , IL-6 and IL-1 β were increased but the difference failed to reach statistical significance (Supplementary Fig. 2).

Finally, analysis of Th17 cytokines at the protein level supported the data obtained at the mRNA level, which showed increased levels of IL-17A, IL-17F, IL-21 and IL-22 (Fig. 4). Taken together, these results argue for the role of inflammation, and especially inflammation mediated by Th17 cells, in the pathogenesis of EBS-gen sev.

Blistering skin of patients with EBS-gen sev overexpresses CXCL-9 and CXCL10

Keratinocytes are potent attractants for immune cells as they secrete large amounts of chemokines¹⁸⁻¹⁹. We thus hypothesized that an increased production of chemokines in EBS-gen sev skin could be the initiating event for the immune infiltrate. Using EBS-gen sev skin from 4 children with the disease and 4 skins from healthy controls, we have found significantly increased number of CXCL9 and CXCL10-immunopositive cells in EBS-gen sev skin compared with controls (Fig. 5).

Treatment of EBS-gen sev patients with Apremilast improves cutaneous symptoms (Fig. 6).

Based on these data, we initiated a treatment with Apremilast in 3 adult patients (3 women aged 33 to 55 years) with EBS-gen sev. Apremilast is a small molecule which specifically inhibits cyclic AMP phosphodiesterase-4 and Th1/Th17 activation and has been approved for the treatment of psoriasis^{20, 21}. Patients 1 and 2 were a mother and her daughter with *K5* mutation, mutational status was unknown for patient 3. Before treatment, all patients had at least 4 or 5 body zones with chronic active blistering, despite protective measures and topical treatments. The patients started Apremilast according to the psoriasis regimen (progressive increase of daily dose from 10mg/d to 30mg twice daily²⁰) in spring or summer. After 10, 15 and 30 days respectively, a dramatic decrease in the number of blisters was observed. The 3 patients initially complained of mild abdominal pain and diarrhea, which progressively disappeared within one month. Patient 3 complained of persistent nausea and stopped the treatment after 7 months. No other adverse events were reported. There was no recurrence after 10 and 8 months of treatment for patient 1 and 2 respectively. Patient 3 had recurrence of blistering two days after the discontinuation of Apremilast.

DISCUSSION

In our study we confirm that patients with EBS-gen sev have clinical hallmarks of an inflammatory skin disease. Furthermore, patients have a dermal infiltrate of CD3+CD4+ lymphocytes in lesional and, to a lesser extent, in non-lesional skin, and epidermal necrosis, suggesting a role for cell-mediated immunity. These results are in accordance with literature^{10, 11}. Keratinocytes are the main cells producing CXCL9, CXCL10 and CCL20, three potent attractors of lymphocytes in the skin of patients with several auto-immune skin

diseases or in the early phases of wound healing^{18, 22-24}. Consistent with these results we found an increased expression of CXCL9 and CXCL10 in the lesional skin compared with control skin, and an increased level of CCL20 in the blister fluid of patients, suggesting that these chemokines are likely to play an important role in lymphocytic infiltrate. An upregulation of CCL2 and CCL20 has already been shown in the skin of K5^{-/-} mice, but not in K14^{-/-} mice⁶. In our study, the levels of CCL20 were not related to the mutational status of the patients.

To try to understand what type of inflammation was induced by the cutaneous CD4⁺ T cells, we analyzed the liquid and the roof of the blisters, and found increased levels of IL-8, IL-1 β , IL-5 and an abundance of Th17 cytokines, at both the mRNA and protein levels. Unfortunately, due to the very small amount of material available and the small number of patients, we were not able to explore the expression of all cytokines. Increased levels of IL-1 β and IL-8 have previously been shown *in vitro* and in the skin of EBS patients^{7, 8, 25}. It has been previously shown that in the early stages of wound healing, keratinocytes become “activated” and release inflammatory molecules, such as IL-1 and IL-8 (to initiate innate immunity and subsequent neutrophil recruitment) but also CCL20 (to recruit monocytes/myeloid dendritic cells and T-cells into a focal skin region)¹⁸. Taken together, these data suggest that the increase in IL-1 and 8 is not specific to EBS, but is more likely to be induced by the wound and can partially explain the granulocytic infiltrate observed in the lesional skin.

The increased expression of IL-5, at both mRNA level on the blister roof and at protein level by ELISA in the blister fluid, is an intriguing finding. IL-5 is a Th2 cytokine and a key mediator in eosinophil maturation, activation and recruitment. Its elevated level in skin of EBS patients is in accordance with the presence of eosinophils in the skin of EBS patients. Surprisingly, other Th2 cytokines such as IL-4 and IL-13 were not increased in our patients, suggesting that IgE may not play a crucial role in the development and/or progress of this disease. The reason for this increase is not known, however IL-5 and eosinophils are involved

This article is protected by copyright. All rights reserved.

in the physiopathology of bullous pemphigoid, an auto-immune blistering disease of the skin, suggesting that this data is not casual²⁶.

Here we show, for the first time, that EB is characterized by an increase in cytokines inducing the differentiation of T cells in Th17 cells, such as TGF- β , IL-6 and IL-21, high levels of Th17 effector cytokines such as IL-17, IL-21 and IL-22, and low levels of cytokines inhibiting the Th17 differentiation, such as IFN γ and IL-4. These data strongly suggest the involvement of the Th17 immune response in the pathogenesis of EBS-gen sev. Th17 cells play a role in adaptive immunity protecting the body against pathogens *via* the production of antimicrobial peptides, recruitment of immunocytes *via* induction of chemokines such as CCL20, and tissue repair by enhancing epithelial proliferation²⁷. The Th17 signaling pathway is tightly controlled and is terminated after infection is abated and tissue repair completed. However, the Th17 signaling is persistently activated in inflammatory or genetic diseases such as psoriasis²⁸, rheumatoid arthritis and ichthyosis²⁹. In psoriasis, Th17 cells are recruited by CCL20; this chemokine is released from keratinocytes by Th17 cytokines, highlighting the critical role of CCL20 in Th17 activation and psoriasis pathogenesis. In EBS-gen sev, mutation of *KRT5/14* can lead to a “stressed” phenotype of keratinocytes with an uncontrolled Th17 activation by infection, physical or chemical stress. Based on these results, we examined the effect of Apremilast, an approved treatment used in psoriasis, in EBS-gen sev patients³⁰. In the 3 treated patients, Apremilast achieved a rapid and sustained improvement. Limitations of this pilot therapeutic study is the limited number of patients treated and the absence of objective assessment of improvement; however, these patients were the most severely-affected adult patients who had active diffuse blisters despite topical treatment. The sustained improvement up to 7 to 10 months of follow-up supports the value of this therapeutic approach. According to our results, anti-IL17 antibodies could also be of interest for treating EBS-gen sev patients.

Taken together, our results demonstrate the importance of inflammation in EBS-gen sev and underline the key role of Th17 activation. They also provide a promising new therapeutic approach for this disabling disorder.

References

- 1 Fine JD, Bruckner-Tuderman L, Eady RA *et al.* Inherited epidermolysis bullosa: updated recommendations on diagnosis and classification. *J Am Acad Dermatol* 2014; 70: 1103-26.
- 2 Dowling GB, Meara RH. Epidermolysis bullosa resembling juvenile dermatitis herpetiformis. *Br J Dermatol* 1954; 66: 139-43.
- 3 Sprecher E. Epidermolysis bullosa simplex. *Dermatol Clin* 2009; 28: 23-32.
- 4 Coulombe PA. Discovery of keratin function and role in genetic diseases: the year that 1991 was. *Mol Biol Cell.* 2016 Sep 15;27(18):2807-10.
- 5 Beriault DR, Haddad O, McCuaig JV, Robinson ZJ, Russell D, Lane EB, Fudge DS. The mechanical behavior of mutant K14-R125P keratin bundles and networks in NEB-1 keratinocytes. *PLoS One.* 2012;7(2):e31320.
- 6 Roth W, Reuter U, Wohlenberg C *et al.* Cytokines as genetic modifiers in K5^{-/-} mice and in human epidermolysis bullosa simplex. *Hum Mutat* 2009; 30: 832-41.
- 7 Wally V, Lettner T, Peking P, Peckl-Schmid D, Muraier EM, Hainzl S, Hintner H, Bauer JW. The pathogenetic role of IL-1 β in severe epidermolysis bullosa simplex. *J Invest Dermatol.* 2013 Jul;133(7):1901-3
- 8 Lettner T, Lang R, Klausegger A, Hainzl S, Bauer JW, Wally V. MMP-9 and CXCL8/IL-8 are potential therapeutic targets in epidermolysis bullosa simplex. *PLoS One.* 2013 Jul 19;8(7):e70123

- 9 Wagner M, Trost A, Hintner H *et al.* Imbalance of intermediate filament component keratin 14 contributes to increased stress signaling in epidermolysis bullosa simplex. *Exp Dermatol* 2013; 22: 292-4.
- 10 Castiglia D, El Hachem M, Diociaiuti A, Carbone T, De Luca N, Pascucci M, Zambruno G, Cavani A. T-lymphocytes are directly involved in the clinical expression of migratory circinate erythema in epidermolysis bullosa simplex patients. *Acta Derm Venereol.* 2014 May;94(3):307-11.
- 11 El-Hawary MS1, Abdel-Halim MR, Sayed SS, Abdelkader HA. Apocytolysis, a proposed mechanism of blister formation in epidermolysis bullosa simplex. *Arch Dermatol Res.* 2015 May;307(4):371-7.
- 12 Hobbs RP, Lessard JC, Coulombe PA. Keratin intermediate filament proteins - novel regulators of inflammation and immunity in skin. *J Cell Sci* 2013; 125: 5257-8.
- 13 Coulombe PA, Lee CH. Defining keratin protein function in skin epithelia: epidermolysis bullosa simplex and its aftermath. *J Invest Dermatol* 2012; 132: 763-75.
- 14 Coulombe PA. The Molecular Revolution in Cutaneous Biology: Keratin Genes and their Associated Disease: Diversity, Opportunities, and Challenges. *J Invest Dermatol.* 2017 May;137(5):e67-e71.
- 15 Salas PJ, Forteza R, Mashukova A. Multiple roles for keratin intermediate filaments in the regulation of epithelial barrier function and apico-basal polarity. *Tissue Barriers.* 2016 May 2;4(3):e1178368
- 16 Wally V, Kitzmueller S, Lagler F, Moder A, Hitzl W, Wolkersdorfer M, et al. Topical diacerein for epidermolysis bullosa: a randomized controlled pilot study. *Orphanet J Rare Dis.* 2013 May 7;8:69

- 17 Rugg EL, Horn HM, Smith FJ *et al.* Epidermolysis bullosa simplex in Scotland caused by a spectrum of keratin mutations. *J Invest Dermatol* 2007; 127: 574-80. *J Cell Sci.* 2004 Apr 15;117(Pt 10):1989-99.
- 18 Kennedy-Crispin M, Billick E, Mitsui H, Gulati N, Fujita H, Gilleaudeau P, Sullivan-Whalen M, Johnson-Huang LM, Suárez-Fariñas M, Krueger JG. Human keratinocytes' response to injury upregulates CCL20 and other genes linking innate and adaptive immunity. *J Invest Dermatol.* 2012 Jan;132(1):105-13.
- 19 Marshall A, Celentano A, Cirillo N, McCullough M, Porter S. Tissue-specific regulation of CXCL9/10/11 chemokines in keratinocytes: Implications for oral inflammatory disease. *PLoS One.* 2017 Mar 2;12(3):e0172821.
- 20 Sakkas LI, Mavropoulos A, Bogdanos DP. Phosphodiesterase 4 inhibitors in immune-mediated diseases: mode of action, clinical applications, current and future perspectives. *Curr Med Chem.* 2017 May 29.
- 21 Papp K, Reich K, Leonardi CL, Kircik L, Chimenti S, Langley RG, Hu C, Stevens RM, Day RM, Gordon KB, Korman NJ, Griffiths CE. Apremilast, an oral phosphodiesterase 4 (PDE4) inhibitor, in patients with moderate to severe plaque psoriasis: Results of a phase III, randomized, controlled trial (Efficacy and Safety Trial Evaluating the Effects of Apremilast in Psoriasis [ESTEEM] 1). *J Am Acad Dermatol.* 2015 Jul;73(1):37-49.
- 22 Rashighi M, Harris JE. Interfering with the IFN- γ /CXCL10 pathway to develop new targeted treatments for vitiligo. *Ann Transl Med.* 2015 Dec;3(21):343.
- 23 Kennedy-Crispin M, Billick E, Mitsui H, Gulati N, Fujita H, Gilleaudeau P, Sullivan-Whalen M, Johnson-Huang LM, Suárez-Fariñas M, Krueger JG. Human keratinocytes' response to injury upregulates CCL20 and other genes linking innate and adaptive immunity. *J Invest Dermatol.* 2012 Jan;132(1):105-13.

- 24 Liu Y, Lagowski JP, Gao S, Raymond JH, White CR, Kulesz-Martin MF. Regulation of the psoriatic chemokine CCL20 by E3 ligases Trim32 and Piasy in keratinocytes. *J Invest Dermatol*. 2010 May;130(5):1384-90.
- 25 Alexeev V, Salas-Alanis JC, Palisson F, Mukhtarzada L, Fortuna G, Uitto J, South A, Igoucheva O5. Pro-inflammatory chemokines and cytokines dominate the blister fluid molecular signature in epidermolysis bullosa patients and affect leukocyte and stem cell migration. *J Invest Dermatol*. 2017 Jul 20.
- 26 de Graauw E, Sitaru C, Horn M, Borradori L, Yousefi S, Simon HU, Simon D. Evidence for a role of eosinophils in blister formation in bullous pemphigoid. *Allergy*. 2017 Jul;72(7):1105-1113.
- 27 Zheng Y, Danilenko DM, Valdez P, Kasman I, Eastham-Anderson J, Wu J, et al. Interleukin-22, a T(H) 17 cytokine, mediates IL-23-induced dermal inflammation and acanthosis. *Nature* 2007;445:648–651.
- 28 Lynde C, Poulin Y, Vender R, Bourcier M, Khalil S Interleukin 17A: toward a new understanding of psoriasis pathogenesis. *J Am Acad Dermatol*. 2014 Jul;71(1):141-50.
- 29 Paller AS, Renert-Yuval Y, Suprun M, Esaki H, Oliva M, Huynh TN, Ungar B, Kunjraiva N, Friedland R, Peng X, Zheng X, Estrada YD, Krueger JG, Choate KA, Suárez-Fariñas M, Guttman-Yassky E. An IL-17-dominant immune profile is shared across the major orphan forms of ichthyosis. *J Allergy Clin Immunol*. 2017 Jan;139(1):152-165.
- 30- Wittmann M, Helliwell PS. Phosphodiesterase 4 inhibition in the treatment of psoriasis, psoriatic arthritis and other chronic inflammatory diseases. *Dermatol Ther (Heidelb)*. 2013 Apr 27;3(1):1-15.

Abbreviations

EBS-gen sev: Epidermolysis bullosa simplex generalized severe

IF: intermediate filament

LC: Langerhans cells

CXCL: Chemokine (C-X-C motif) ligand

IL: interleukin

IFN γ : interferon gamma

TNF α : tumor necrosis factor alpha

TGF β : transforming growth factor beta

CCL20: Chemokine (C-C motif) ligand 20

Legends

Table 1: *Demographic and molecular features of EBS patients.*

KRT5: keratin gene, KRT14 Keratin 14 gene, NA: not available, NF: not found. AD: autosomal dominant, M: male, F: female, d: day, m: month, y: year. Some patients were included in both the retrospective and prospective study. Their number of inclusion in the prospective study is indicated in brackets.

Figure 1: Immunostaining of a frozen skin biopsy of blister (patient 11) (magnification x100). The inflammatory infiltrate was assessed as moderate (++), dermal, perivascular and mainly lymphocytic, CD4+ predominant (19/22 biopsies). a) Hematoxylin-phloxine-saffron (HPS) stain b) total CD3+ lymphocytes, c) CD4+ T cells, d) CD8+ T cells.

Figure 2: HPS staining of a formalin-fixed, paraffin-embedded skin biopsy (a) and blister roof (b and c) (x200). Epidermal and dermal infiltrate of eosinophils in the skin of patient 1 of the retrospective study (a). Eosinophils (b) and neutrophils (c) infiltrate the blister roof of

This article is protected by copyright. All rights reserved.

patients 2 and 6 in the prospective study, respectively. Eosinophils are indicated by blue arrows, neutrophils with black arrows.

Figure 3: Quantitative PCR on the roof of an EBS-gen sev blister.

mRNA expression of pro-inflammatory (IL-8, TNF α), Th1 (IFN γ), Th2 (IL-4, IL-5), Th17 (IL-17, IL-21, IL-22) and regulatory (IL-10, TGF β) cytokines. Data is presented as relative values with median compared to controls. The red line indicates when genes are increased 2 or more fold.

Figure 4: Quantitative dosage by ELISA of the blister fluid cytokines of EBS-gen sev patients compared to fluid of suction blisters. A- Cytokines reaching statistical difference. B- Th17 cells cytokines.

Figure 5: Immunostaining for CXCL9 and CXCL10 in frozen skin biopsy (retrospective study) from 4 patients compared to control. CXCL9+ cells are stained green and CXCL10+ cells are stained red. Cells expressing both chemokines are yellow. CXCL9 was purchased from Life Technologies SAS (Courtaboeuf, France) and CXCL10 from Abcam (Parus, France), both antibodies used at 1:100 dilution.

Figure 6: Pictures of patient 1, 2 and 3 before (a/c/e respectively) and 1.5 months after Apremilast treatment (b/d/f). Note the absence of blisters after treatment.

Table 1

	N°	Sex	Age	transmission	Mutation
Retrospective study	1	F	3d	de novo	K14: c.368A>G exon 1 (p.Asn123Ser)
	2/(1)	F	7 d/2y	de novo	K5: c.527A>G exon 1 (p.Asn176Ser)
	3	F	7 d	AD	NA
	4	M	7 d	de novo	K14 : c.416T>C exon 1 (p.Met119Thr)
	5	M	10 d	de novo	NA
	6	M	10 d	de novo	K14: c.355A>G exon 1 (p.Met119Val)
	7/(8)	F	12 d / 6y	de novo	K5: c. XXG>A exon 7 (p.Glu466Gly)
	8	F	13 d	de novo	K5: c.771_772delGT exon x (p.Tyr258X)
	9	M	3 m	de novo	K14
	10	F	4 m	NA	K14
	11/(2)	F	8 m / 2,5y	de novo	K5: c.556G>T, exon 2 (p.Val186Ile)
	12/(3)	F	4y /6y	de novo	K5: c.527A>G, exon 1 (p.Asn176Ser)
	13	F	8	AD	NA
	14	F	22 y	AD	NA
	15	F	25 y	AD	NA
	16/(7)	F	26 y/ 32y	de novo	K5: c. G.656-751del96pb exon 1 (p.Val164_Lys185del)
	17	F	27 y	AD	K14: c.1131dupT exon 6
Prospective study	4-	M	43 y	de novo	NF
	5-	F	8 y	de novo	K14: c. (p.Arg125Pro) exon 1
	6-	M	61 y	AD	K5: c.555+1G>A exon 1 (p.Val164_Lys185 del)
	9-	M	34y	AD	K5: c.555+1G>A exon 1 (p.Val164_Lys185 del)
	10-	F	28y	de novo	K5: c.1401C>G exon 7 (p.Ile467Met)

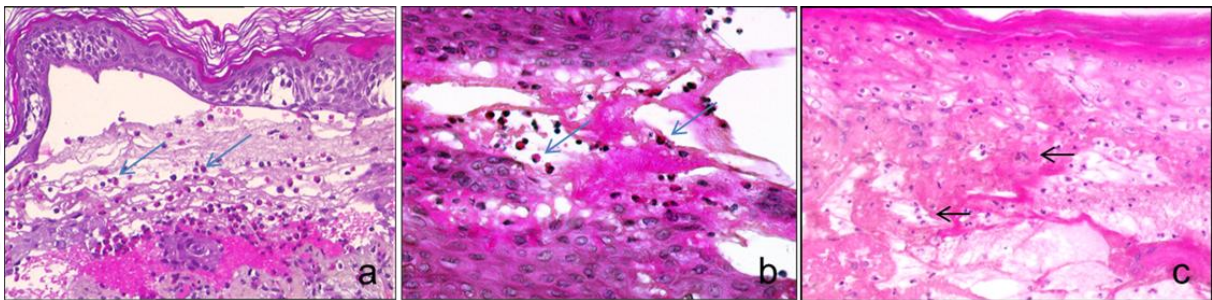
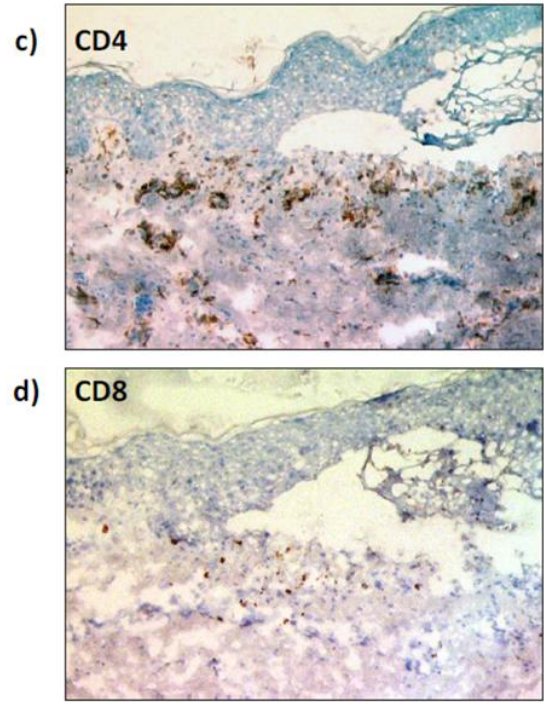
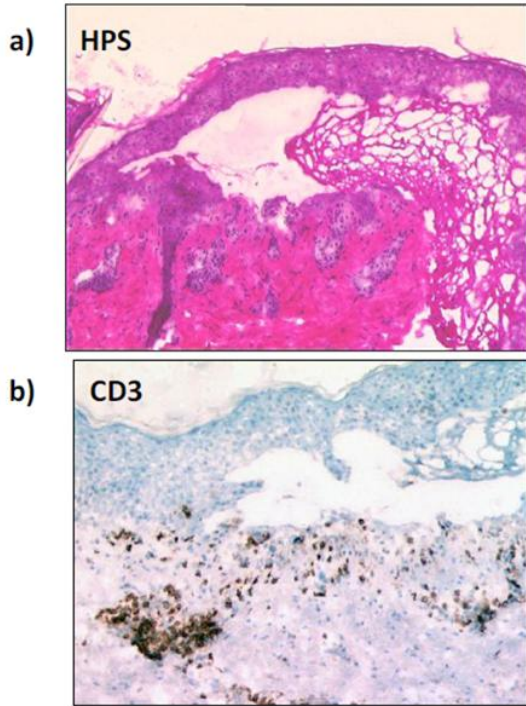


Figure 3

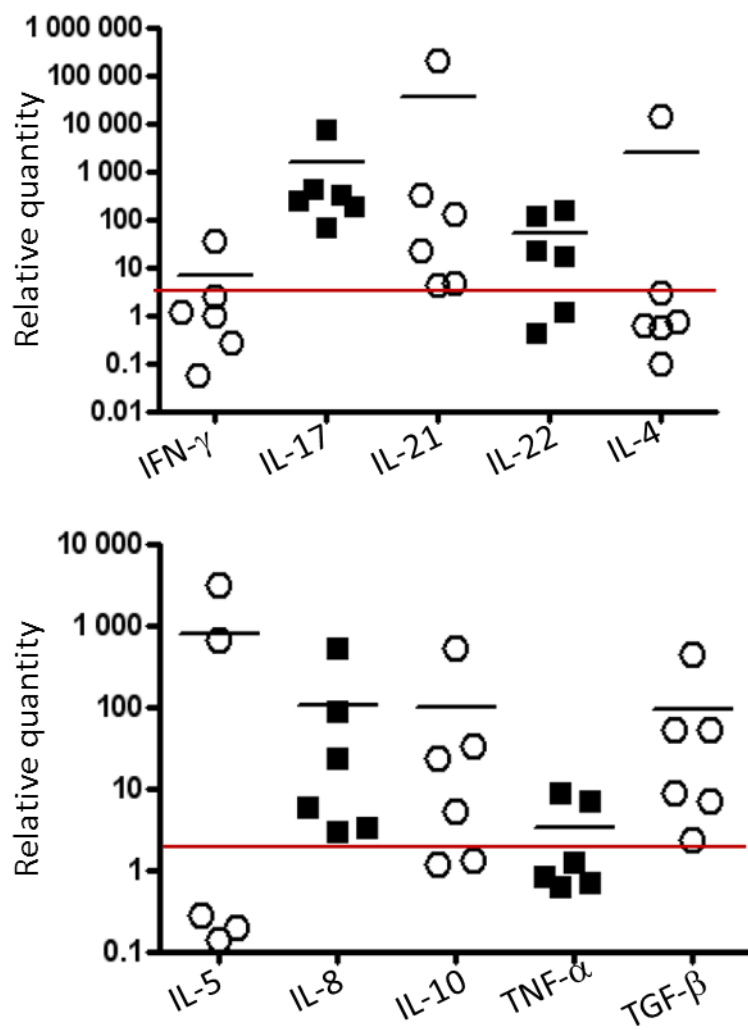


Figure 4

