



HAL
open science

A Case of Miliary Tuberculosis Presenting with Whitlow of the Thumb

Romaric Larcher, Albert Sotto, Jean-Marc Mauboussin, Jean-Philippe Lavigne, François-Xavier Blanc, Didier Laureillard

► **To cite this version:**

Romaric Larcher, Albert Sotto, Jean-Marc Mauboussin, Jean-Philippe Lavigne, François-Xavier Blanc, et al.. A Case of Miliary Tuberculosis Presenting with Whitlow of the Thumb. *Acta Dermatovenereologica*, 2016, 96 (4), pp.560 - 561. 10.2340/00015555-2285 . hal-01909474

HAL Id: hal-01909474

<https://hal.science/hal-01909474>

Submitted on 25 May 2021

HAL is a multi-disciplinary open access archive for the deposit and dissemination of scientific research documents, whether they are published or not. The documents may come from teaching and research institutions in France or abroad, or from public or private research centers.

L'archive ouverte pluridisciplinaire **HAL**, est destinée au dépôt et à la diffusion de documents scientifiques de niveau recherche, publiés ou non, émanant des établissements d'enseignement et de recherche français ou étrangers, des laboratoires publics ou privés.



Distributed under a Creative Commons Attribution - NonCommercial 4.0 International License

SHORT COMMUNICATION

A Case of Miliary Tuberculosis Presenting with Whitlow of the Thumb

Romaric Larcher¹, Albert Sotto^{1*}, Jean-Marc Mauboussin¹, Jean-Philippe Lavigne², François-Xavier Blanc³ and Didier Laureillard¹¹Infectious Disease Department, ²Department of Microbiology, University Hospital Caremeau, Place du Professeur Robert Debré, FR-0029 Nîmes Cedex 09, and ³L'Institut du Thorax, Respiratory Medicine Department, University Hospital, Nantes, France. *E-mail: albert.sotto@chu-nîmes.fr
Accepted Nov 10, 2015; Epub ahead of print Nov 11, 2015

Tuberculosis remains a major public health concern, accounting for millions of cases and deaths worldwide. In 2013, an estimated 9.0 million people developed tuberculosis and 1.5 million died from the disease (1). Among the 5.4 million new notified cases, 2.6 million had bacteriologically confirmed pulmonary tuberculosis, 2.0 million had clinically diagnosed pulmonary tuberculosis, and 0.8 million had extra-pulmonary tuberculosis (1). Extra-pulmonary tuberculosis can affect any organ of the body, and has a broad spectrum of manifestations (2). Cutaneous tuberculosis is an uncommon manifestation of tuberculosis, accounting for 0.5–2% of all extra-pulmonary tuberculosis (3). Cutaneous tuberculosis is caused mainly by infection with *Mycobacterium tuberculosis* complex and occasionally by infection with *M. bovis* or BCG vaccine. The clinical appearance of cutaneous tuberculosis can vary, depending on the exogenous or endogenous origin of the infection.

We report here an original case of disseminated tuberculosis, revealed by a whitlow, and describe our diagnostic approach, treatment and outcome. The patient provided written consent for publication of this case report.

CASE REPORT

A 75-year-old woman with a medical history of autoimmune thyroiditis treated with L-thyroxin was admitted to the emergency department with pain, oedema, erythema of the left thumb, and fever for 3 days. Her general practitioner diagnosed a whitlow and started pristinamycin with no improvement. The patient reported back pain that had started 6 months previously, associated with a vertebral fracture of T11–T12, which had been treated with corticosteroids for 3 months.

At admission, physical examination revealed an inflammatory swelling of the left thumb. The skin was tender from the base of the thumb to the thenar region. Extension of the left thumb was limited. Diagnosis of a sheath phlegmon affecting the flexor of the left thumb was established. Surgery with drainage, and co-amoxiclav treatment were performed immediately. The patient was then transferred to the infectious diseases department. Results of intra-operative samples of pus and initial blood cultures were negative. Despite 10 days of intravenous co-amoxiclav, followed by 15 days of piperacillin-tazobactam, evolution of the skin wound was unfavourable (Fig. 1a).

Because of a mild dyspnoea with normal auscultation of the lungs and tenderness of the thoracic spine at T10–T11–T12 levels, additional investigations were performed. Arterial blood gas showed mild hypoxia (PO₂ 66 mmHg) associated with respiratory alkalosis (pH 7.52 and bicarbonates 25 mmol/l) and significant hypocapnia (PCO₂ 27 mmHg). A chest X-ray revealed a miliary. The white blood cell count was 5,700/mm³

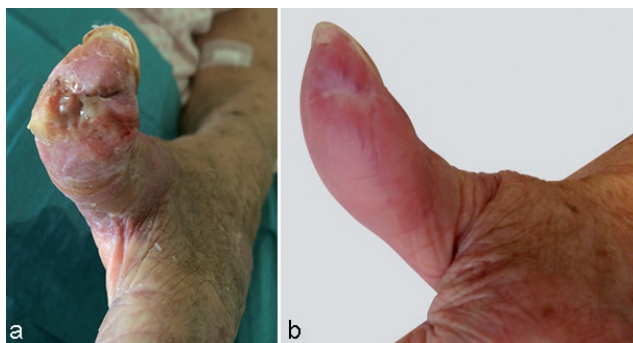


Fig. 1. (a) Sheath phlegmon of the left thumb at admission to the infectious diseases department; and (b) evolution of the left thumb after 9 months of tuberculosis treatment.

and lymphocytes were at 720/mm³. C-reactive protein (CRP) was 166 mg/l. Blood electrolytes and liver function tests were normal. Radiography of the spine was suggestive of a T10–T11 spondylodiscitis. Thoracic computed tomography (CT)-scan revealed uniformly distributed 1–3 mm pulmonary nodules, strongly suggesting infectious miliary. Magnetic resonance imaging confirmed the diagnosis of spondylodiscitis, showing STIR hypersignal with irregularity and erosion of the endplate of the T10–T11–T12 vertebral bodies, STIR hypersignal of discs, epidural and pre-vertebral collections, and local compression of the spinal cord without T2 hypersignal.

The association of a pulmonary miliary and a spondylodiscitis led us to consider the diagnosis of disseminated tuberculosis. CT-scan-guided discovertebral biopsies of T12 were acid-fast bacilli (AFB) smear-positive. Antibiotic failure on the thumb wound led us to perform a *M. tuberculosis complex* PCR from the skin biopsy, which was positive. Cultures from discovertebral biopsies, skin biopsy and gastric aspiration proved positive for drug-sensitive *M. tuberculosis*. The HIV test was negative.

After 2 weeks of standard anti-tuberculosis treatment (isoniazid, rifampicin, ethambutol and pyrazinamide), fever, pain and dyspnoea all improved. Evolution of the left thumb wound was also favourable. Clinical and biological tolerance of the treatment was good. According to drug susceptibility test results, ethambutol was stopped after 1.5 months of anti-tuberculosis treatment. Isoniazid, rifampicin and pyrazinamide were prescribed for a total of 3 months, while both isoniazid and rifampicin were continued for a further 9 months. Anti-tuberculosis therapy resulted in a favourable outcome with complete resolution of the skin lesion (Fig. 1b).

DISCUSSION

In the present case, the diagnosis of disseminated tuberculosis was established because of the association of a pulmonary miliary, Pott's disease, and a phlegmon of the flexor sheath of the thumb. Tuberculosis explains the fact

that the sheath phlegmon evolved unfavourably despite rapid surgery and conventional antibiotic treatment.

Cutaneous tuberculosis can have various clinical manifestations. Infection can be acquired through exogenous routes from direct inoculation of *M. tuberculosis* into the skin. With this route of infection, clinical manifestations are tuberculous chancre, tuberculosis verrucosa cutis, and in some cases, lupus vulgaris. These clinical manifestations are commonly observed in healthcare workers and are difficult to diagnose because of their paucibacillary nature, leading to a high frequency of negative cultures. Cutaneous tuberculosis can also result from an endogenous infection, secondary to a pre-existing primary focus. Tuberculosis cutis orificialis, scrofuloderma, and most cases of lupus vulgaris, result from contiguous dissemination, acute miliary tuberculosis and tuberculous abscess from lymphohematogenous dissemination (3). Tuberculous abscesses, or gumma, has been described in individuals with acute miliary tuberculosis and may infrequently affect immunocompetent adults (4). These are non-tender fluctuant subcutaneous nodules. The nodules eventually penetrate the skin, resulting in the development of ulcers and draining sinuses (3, 5). Lesions may occur at any skin site, but frequently develop on the extremities. Satellite regional lymph nodes are usually not present (3, 5). Tuberculous gumma have a poor prognostic value in immunocompetent individuals and may persist for years if untreated (3, 5). The confirmation of the diagnosis of tuberculous gumma is based on identification of bacilli by AFB stains, or culture or PCR that demonstrates the presence of *M. tuberculosis complex* (6, 7), and requires aspiration or skin biopsy (8).

In our case, PCR and culture from the skin biopsy were positive and explained the unfavourable outcome of the wound with standard antibiotic treatment. However, the diagnosis of disseminated tuberculosis was based initially on the positive AFB-smear of gastric aspiration and of vertebral biopsies of T12, later confirmed by PCR and culture. In general, manifestations of miliary pulmonary can be acute, but are more likely to be sub-acute or chronic (9). Patients often report dyspnoea or cough, and hypoxemia is common. In the present case, the patient had a febrile dyspnoea with mild hypoxemia related to a sub-acute or chronic miliary tuberculosis. Pathogenesis is likely to be a lympho-haematogenous dissemination of *M. tuberculosis* from a pulmonary focus with embolization to vertebral bones then to the left thumb joint and the skin. This dissemination was favoured by the corticosteroids given to treat the back pain.

Treatment of cutaneous tuberculosis is the same as for systemic tuberculosis (6, 7). The therapeutic response of cutaneous lesions can be assessed clinically. Surgical treatment is not usual for the management of cutaneous tuberculosis, but is sometimes required to manage extensive or recalcitrant tuberculous skin lesions (6, 7). The treatment duration is usually 6 months. In our case, the treatment duration was dependent on the bone involvement. We opted for a 12-month regimen (10).

In conclusion, disseminated tuberculosis can be revealed by an atypical cutaneous lesion mimicking a whitlow and can be observed in non-HIV-infected patients. This diagnosis should be considered when the outcome is unfavourable despite surgery and antibiotic treatment, notably in the context of immunosuppression.

ACKNOWLEDGEMENT

The authors would like to thank Emma Rubenstein for her assistance with the manuscript preparation.

The authors declare no conflicts of interest.

REFERENCES

1. Global tuberculosis report 2014. [Cited 2015 Feb 25]. Available from: http://apps.who.int/iris/bitstream/10665/137094/1/9789241564809_eng.pdf?ua=1.
2. Zumla A, Raviglione M, Hafner R, Fordham von Reyn C. Tuberculosis. *N Engl J Med* 2013; 368: 745–755.
3. Santos JB, Figueiredo AR, Ferraz CE, Oliveira MH, da Silva PG, Medeiros VLS. Cutaneous tuberculosis: epidemiologic, etiopathogenic and clinical aspects – part I. *An Bras Dermatol* 2014; 89: 219–228.
4. Almagro M, Del Pozo J, Rodríguez-Lozano J, Silva JG, Yebra-Pimentel MT, Fonseca E. Metastatic tuberculous abscesses in an immunocompetent patient. *Clin Exp Dermatol* 2005; 30: 247–249.
5. MacGregor RR. Cutaneous tuberculosis. *Clin Dermatol* 1995; 13: 245–255.
6. Dias MFRG, Bernardes Filho F, Quaresma MV, do Nascimento LV, Nery JA da C, Azulay DR. Update on cutaneous tuberculosis. *An Bras Dermatol* 2014; 89: 925–938.
7. Santos JB, Figueiredo AR, Ferraz CE, Oliveira MH, da Silva PG, Medeiros VLS. Cutaneous tuberculosis: diagnosis, histopathology and treatment – part II. *An Bras Dermatol* 2014; 89: 545–555.
8. Sharma SK, Mohan A. Extrapulmonary tuberculosis. *Indian J Med Res* 2004; 120: 316–353.
9. Sharma SK, Mohan A, Sharma A, Mitra DK. Miliary tuberculosis: new insights into an old disease. *Lancet Infect Dis* 2005; 5: 415–430.
10. Ramachandran S, Clifton IJ, Collyns TA, Watson JP, Pearson SB. The treatment of spinal tuberculosis: a retrospective study. *Int J Tuberc Lung Dis Off J Int Union Tuberc Lung Dis* 2005; 9: 541–544.