



HAL
open science

Experimental evaluation of the NeVa™ thrombectomy device a novel stent retriever conceived to improve efficacy of organized clot removal

Paolo Machi, Arthur J. Ulm, Gianmarco Bernava, Olivier Brina, Karl Olof Lovblad, Franck Jourdan

► To cite this version:

Paolo Machi, Arthur J. Ulm, Gianmarco Bernava, Olivier Brina, Karl Olof Lovblad, et al.. Experimental evaluation of the NeVa™ thrombectomy device a novel stent retriever conceived to improve efficacy of organized clot removal. *Journal de Neuroradiologie / Journal of Neuroradiology*, 2018, 10.1016/j.neurad.2018.03.005 . hal-01897302

HAL Id: hal-01897302

<https://hal.science/hal-01897302v1>

Submitted on 17 Oct 2018

HAL is a multi-disciplinary open access archive for the deposit and dissemination of scientific research documents, whether they are published or not. The documents may come from teaching and research institutions in France or abroad, or from public or private research centers.

L'archive ouverte pluridisciplinaire **HAL**, est destinée au dépôt et à la diffusion de documents scientifiques de niveau recherche, publiés ou non, émanant des établissements d'enseignement et de recherche français ou étrangers, des laboratoires publics ou privés.

Experimental evaluation of the NeVa™ thrombectomy device a novel stent retriever conceived to improve efficacy of organized clot removal

Paolo Machi ^{a,*}, Arthur J. Ulm ^b, Gianmarco Bernava ^a, Olivier Brina ^a, Karl Olof Lovblad ^a, Franck Jourdan ^c

^a University Hospital of Geneva, Switzerland

^b Nashville Neurosurgery Associates, Nashville, TN, USA

^c Department of Mechanical Engineering, University of Montpellier, France

ABSTRACT

Background and purpose. – Stent retrievers are recognized as the most effective devices for intracranial thrombectomy. Although highly effective, such devices fail in clot removal when the brain vessel occlusion is due to organized, firm clots. The mechanism of failure is that during the retrieval, devices remain compressed by the organized clot and slide between it and the vessel wall without any removal effect. The aim of the current study is to present the preclinical evaluation of the NeVa™ device, a novel stent retriever designed to improve the incorporation and removal of organized thrombi.

Materials and methods. – Preclinical evaluation of the NeVa™ device was divided in three main chapters: efficacy analysis, mechanical analysis and safety analysis. Efficacy and mechanical analysis aimed to investigate the behavior during the retrieval of the NeVa™ device and its interaction with experimental organized clots. Safety analysis was conducted on animals in order to investigate the effect of the NeVa™ device on real arteries after simulated thrombectomy maneuvers.

Results. – NeVa™ device showed a high rate of “optimal clot integration” and “effective clot removal” which was related to constant cohesion to the vessel wall during retrievals. Safety analysis showed as the most frequent finding the disruption of the intima of the tested vessels with, in some cases, minimal disruption of the internal elastic lamina.

Conclusions. – The NeVa™ device has demonstrated safety and efficacy in a pre-clinical study. Such encouraging, preliminary results have to be compared with those of clinical trials.

Keywords:

Mechanical thrombectomy
Stent retriever
Ischemic stroke

Introduction

A number of trials demonstrated that stent retriever based MTB is a safe and effective treatment for acute ischemic stroke. Successful artery recanalization rates range between 58% and 88% [1–5]. Nevertheless, in a relatively high percentage of cases (up to 42%) stent retrievers fail in clot removal. One possible source of treatment failure is organized, firm clots. The mechanism of failure is

that during the retrieval, devices remain compressed by the organized clots and slide between the clot and the vessel wall without any removal effect [6]. The aim of the current study is to present the preclinical evaluation of the NeVa™ device, a novel stent retriever designed to improve the incorporation and removal of organized thrombi. The novel feature of the NeVa™ devices is the presence of offset drop zones which allow for the incorporation of organized clot to the inside of the device during retrieval.

Materials and methods

Description of the NeVa™ device

The device comes in two sizes for site-specific deployment: NeVa™ T and NeVa™ M1 (Fig. 1). There are five zones along the devices. From proximal to distal: flow restoration zone, first drop

Abbreviations: MTB, mechanical thrombectomy; MCA, middle cerebral artery; ACA, anterior cerebral artery; ICA, internal carotid artery; OCI, optimal clot integration; NOCI, not optimal clot integration; ECR, effective clot removal; NECR, not effective clot removal; DSA, digital subtracted angiography.

* Corresponding author at: Geneva University Hospital, Rue Gabrielle-Perret-Gentil 4, CH-1205 Geneva, Switzerland.

E-mail address: Paolo.Machi@hcuge.ch (P. Machi).

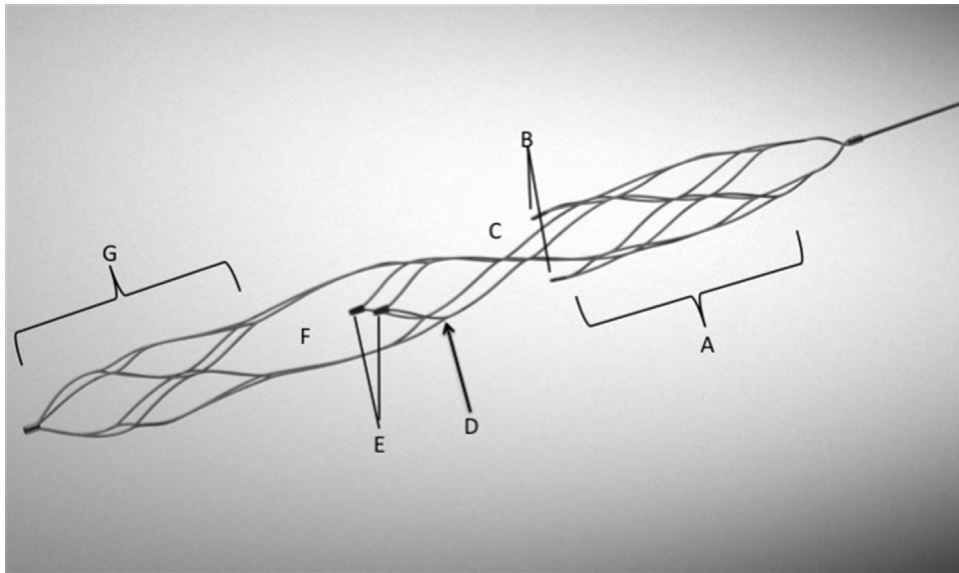


Fig. 1. Neva™ T (4.5–44 mm) and Neva™ M1 (4.0–36 mm) configurations. From proximal to distal (A) flow restoration zone, (B) proximal tandem markers, (C) first drop zone, (D) inter-drop zone support cell, (E) distal tandem markers, (F) second drop zone, (G) distal capture basket.

zone, inter-drop zone support cell, second drop zone and distal capture basket. These structural zones correspond with radial force and function. The proximal portion of the device acts as a common stent retriever compressing the thrombus toward vessel wall and re-establishing some flow within the artery (by-pass effect). The drop zones are perpendicular to each other, such configuration provide a 360° entry area to improve the likelihood of clot capture. Radiopaque markers are located at the edge of the drop zones and allow the optimal deployment regarding the interaction clot/device. The distal portion of the device is closed ended and functions as a capture basket designed to reduce distal embolization during retrieval. Neva™ T measures 4.5 mm in diameter and 44 mm in length and Neva™ M1 measures 4.0 mm in diameter and 36 mm in length; both devices are 0.021 in microcatheter compatible.

Efficacy analysis

Organized clot removal efficacy and device behavior during retrieval were evaluated while performing experimental thrombectomies using a vascular phantom and organized clot homologues. Experiments were performed under fluoroscopy using a bi-plane angiography system (Allura FD 20, Philips Healthcare, Best, Netherlands). A high definition video camera simultaneously filming experiments was used for double control. Procedures were performed by two neurointerventionalists with experience in MTB (PM, GB).

Vascular phantom

Tests were performed using a 3D printed vascular model made by stereolithography with a translucent photosensitive resin reproducing the MCA, the ACA and the ICA. The diameter of the MCA was 2.5 mm, the diameter of the ICA varied from 3 to 6 mm (from distal to proximal) (Fig. 2). The phantom was continuously flushed by a gear pump injecting water heated to 37 °C to simulate the in vivo expansion temperature of the nitinol devices.

Clot model

Organized clot homologues were produced with human blood; five healthy volunteers without history of medication use consented to provide blood samples for the study. Organized clots were produced with platelet-rich plasma. It was extracted from whole

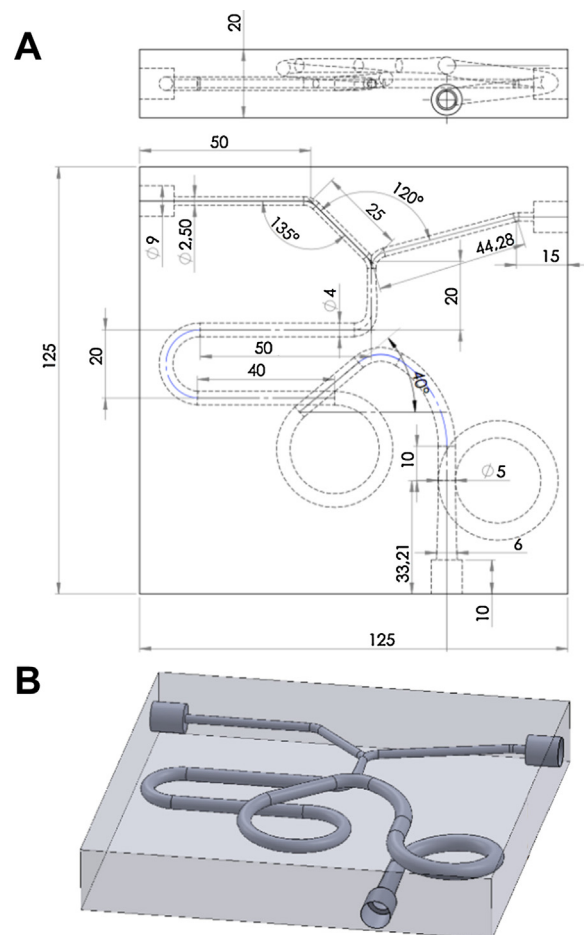


Fig. 2. (A, B) The scheme of the rigid 3D printed vascular phantom used for efficacy analysis.

blood after centrifugation at 350 g for 10 min at 22°. Hence, platelet-rich plasma was incubated at 37° for 1 h and thereafter organized clots were extracted [7–9]. Clots were produced in diameters of 4 mm (middle) and 6 mm (large).

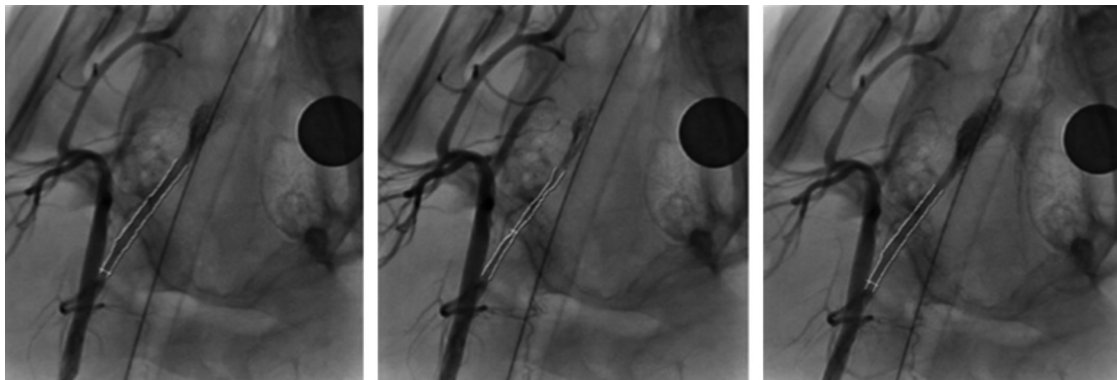


Fig. 3. GLP angiographic evaluation, the presence and severity of vasospasm were quantified after four deployments; three re-sheathings and simulated clot retrieval were performed. A baseline angiogram was performed and the vessel diameter quantified and compared to T 10 min after retrieval and then at time points extending out to 60 min. All vessels returned to within 90% of baseline on final angiography.

Experimental thrombectomies

The interaction of the device with the organized thrombus and the behavior of the device during retrieval were evaluated using fluoroscopy and magnified video imaging. Organized clots of 4 and 6 mm in diameter were delivered within the MCA or the terminal ICA of the phantom respectively. For the evaluation of Neva™ T the clot was delivered at terminal ICA while for Neva™ M1 the clot was delivered at M1. Procedures were performed using standard technique via a 6F-guiding catheter connected to the phantom [8]. For both devices the aim was to evaluate whether the drop zones were a point of capture of the clot and whether the operator could influence clot integration by performing a succession of pull and release maneuvers guided by the markers located at the leading edge of the drop zones oriented 90° offset relative to each other (Fig. 1). No anterograde flow arrest or concomitant aspiration were performed during the retrievals. For each thrombectomy procedure, operators performed up to three passes and ten thrombectomies were performed for each device. Results were scored as follows: optimal clot integration (OCI; when clots entered the drop zones)/not optimal clot integration (NOCI), effective clot removal (ECR; when clots were completely removed from the phantom)/not effective clot removal (NECR).

Mechanical analysis

Mechanical analysis aimed to evaluate the radial force variation of Neva™ devices during the retrieval. Such measurements were performed by *Pull up traction tests* [9]. For these tests, devices were deployed within silicon tubes of different diameters (1.5 mm and 3 mm) and the delivery wires were connected to the traction transducer arm of a tensile test machine. The traction arm retrieved the devices for 5 mm at a velocity of 2 mm/s. Each stent was tested 5 times and the average value of the force exerted by the machine during the retrieval was used to calculate the radial pressure of the device over the tube wall, these values were expressed in Pascal (Newton/m²).

Safety analysis

Such analysis was conducted on animals in order to investigate the effect of Neva™ devices on real arteries after simulated thrombectomy maneuvers. Procedures were performed in accordance with labs standard operating procedures and ethical guidelines of the institutional animal care committee. Three swine were employed for the study. The procedures were performed under DSA guidance. Each device was tested in two branches of the external carotid artery in the following manner: vessels

were selected with a standard 0.021 in. microcatheter; hence, the Neva™ device was deployed in the vessel and re-sheathed into the microcatheter using a combination of pushing the catheter while pulling the device. The device was deployed and re-sheathed three times after which it was deployed a fourth time and a complete retrieval performed by dragging the device from the study vessel into a 6F guide-catheter placed in the common carotid artery. The test was repeated with the same device in a second vessel in an identical manner. Pre and post deployment/retrieval angiograms were performed and a quantitative assessment of vasospasm was performed using the GE segment analysis software (Fig. 3). According to Grandin' classification [10] vasospasm was graded as follows: mild = vessel diameter reduction of ≤25%, moderate = vessel diameter reduction of 25–50% (or 50–75% for a focal segment), severe = vessel diameter reduction of 50–75% (or >75% for a focal segment). Furthermore, angiographic images were evaluated for the presence of complications including vessel perforation, extravasation or dissection. After testing, animals were euthanized and the study branches as well as control vessels (lingual arteries) were examined for evidence of gross injury and then harvested and sent to an independent laboratory for histopathological examination. In order to assess the degree of arterial injury a semiquantitative analysis of histopathologic changes of the tested vessel was conducted [11]. For such analysis the following parameters were recorded: endothelial loss, presence of platelet or fibrin on the luminal surface, hemorrhage in the media and/or in the adventitia, medial injury. These parameters were used to calculate a score ranging from 0 (no vessel injury) to 20 (highest degree of injury) (Table 1).

Results

Efficacy analysis

Results of experimental thrombectomies are reported in (Table 2). Neva™ M1 demonstrated the highest rate of OCI which was related to ECR ($n = 7$ out of 10). Neva™ T showed similar overall rate of ECR ($n = 7$ out of 10) although in one case the clot was not integrated into the device but remained engaged within the stent struts during the retrieval. The average number of passes for Neva™ M1 was 1.8 while for Neva™ T it was 1.9. Both devices maintained constant adhesion to the vessel wall during retrievals. In addition, when retrieved over sharp angles of the rigid vascular phantom, the devices showed limited elongation. This was due to the design of the device. The Drop zones divide the device into five separate compartments (Fig. 1). When retrieved over a sharp angle, the proximal compartment (“flow restoration zone”) initially

Table 1
Scheme used for a semiquantitative analysis of histopathologic changes of the tested vessel.

Score	0	1	2	3	4
Endothelial loss (%)	None	<25% of circumference	25–50%	51–75%	>75%
Thrombus (fibrin/platelet)	None	Minimal, focal	Mild, multifocal	Moderate, regionally diffuse	Severe, marked diffuse or total luminal occlusion
Adventitial hemorrhage	None	Focal, occasional	Multifocal and regional	Regionally diffuse	100% red blood cells
Medial hemorrhage	None	Focal, occasional	Multifocal and regional	Regionally diffuse	100% red blood cells
Medial injury (device induced)	None	Focal disruption of the IEL	Widespread disruption of IEL	Medial tear not extending beyond the EEL	Medial tear with involvement of the EEL

From Noguiera et al. Ref. [11].

IEL = internal elastic lamina; EEL = external elastic lamina.

Table 2
Results of experimental thrombectomies.

	OCI	NOCI	ECR	NECR
Neva™ M1	7/10	3/10	7/10	3/10
Neva™ T	6/10	4/10	6/10	4/10

OCI: optimal clot integration, NOCI: not optimal clot integration, ECR: effective clot removal, NECR: not effective clot removal. Neva™ M1 was tested with clots of 4 mm, Neva™ T was tested with clot of 6 mm.

elongates but beyond the angle promptly re-expands. The ability to re-expand and regain adhesion to the wall is due to the fact that the segments of the device are connected by parallel and offset thin linear struts that do not transmit the tangential friction exerted by the angle during the retrieval. Such behavior allowed for constant cohesion to the vessel wall during retrievals. Maintaining wall apposition has been shown to be a factor that improves the efficacy of clot removal [12,13].

Mechanical analysis

The purpose of the test was to determine the radial force shift when devices were retrieved in tubes of different diameters, 1.5 mm and 3.5 mm respectively. All devices showed significant reduction of the radial force with Neva™ M1 having a 30% reduction of radial force and Neva™ T demonstrating a 42% reduction in radial force. The lower value was recorded for both devices in tubes

Table 3
Values of radial pressure exerted by Neva™ devices and currently available stent retrievers in tube of 1.5 and 3.5 mm of diameter. Values were measured by Pull up traction tests and are expressed in Pascal (N/m²).

	Size	Radial pressure Pa (N/m ²) (1.5 mm tube)	Radial pressure Pa (N/m ²) (3.5 mm tube)
Trevor PV	4–20	920	50
	3–20	300	60
Eric	3–20	220	–
	4–24	1540	340
	6–44	770	400
Embotrap	5–21	1430	770
Penumbra 3D	4.5–26	1360	400
Revive	4.5–22	1360	850
Mindframe	3–23	1250	330
Solitaire FR	4–20	1110	530
	6–30	1060	580
Preset	4–20	1090	730
	6–30	630	600
Preset LT	3–20	1060	160
	4–20	460	480
Catch	3–15	840	220
	4–20	1810	360
	6–30	1870	900
Neva™ M1	4–36	1533	1020
Neva™ T	4.5–44	1486	853

Adapted from the publication of Machi et al. [9].

of 3.5 mm, but in each case the radial force was higher than 853 Pa (N/m²) (Table 3).

Safety analysis

For such analysis a total of six vessels from three animals were evaluated. After repeated maneuvers of devices deployment, re-sheathing and retrieving (reported above) all vessels showed vasospasm just after stent retrieval (first 10 min). Recovery of the vasospasm (complete or <10%) was recorded at 60 min after the experimental procedures. No vessel perforations or dissections were observed on per-procedural DSA controls. Pathology showed no swelling, bruising or perforation of the treated vessels. Histology found different degrees of endothelial loss for all examined vessels. A focal lesion of the internal elastic lamina was recorded in one case for Neva™ M1. Medial hemorrhage or thrombus formation were not found in the examined samples. Injury scores ranged from 2.63 to 2.88 (out of 20); the most common finding was endothelial loss.

Discussion

Efficacy of clot removal is due to the interaction between the stent retriever and the clot. Depending on the degree of the migration of the stent struts into the clot after deployment, the clot is completely integrated, partially penetrated by the struts or remains outside the stent. Clot removal failure is usually due to the presence of an organized large, clot. In such instance the stent does not penetrate the clot, but remains compressed between the clot and the vessel wall and during the retrieval, the device slides beside it without retrieving it [14–19]. The penetration of the struts within the clot is promoted by device radial force and large openings between device filaments [20]. We report on pre-clinical data related to the safety and efficacy of the Neva™ platform of thrombectomy devices, which were engineered to improve interaction with organized clot. The main difference in comparison with currently available stent retrievers is the presence of drop zones that are enlarged openings within the device allowing for the lateral integration of the clots. Radiopaque markers located just proximal to the drop zones, allows the operator to mentally see the interaction of the device with the clot, particularly when clot is externally compressing the device at the interface. In such cases, the operator can maneuver by gently pulling and releasing the delivery guidewire to effect micromovement of the retriever in order to facilitate internal capture of external organized thrombus identified by an opening of the markers.

The markers placed at the leading edge of them identify drop zones. When the stent is retrieved over the clot the markers are compressed and pushed together and are identifiable as a single point, in such a configuration the device is constrained and the drop zones are closed and the clot cannot entry through them. In order to allow the drop zones to open, the operator has to release tension on the push wire until the device expands so the opening of the

Table 4

Adapted from the publication of Machi et al. [9], results of experimental thrombectomy performed with currently available stent retrievers in a similar study with white experimental clots produced with the same protocol.

Device	Size	Large white clot	Medium white clot	%
Trepo PV	4–20	0/5	2/5	0–33%
	3–20	0/5	1/5	0–20%
Eric	3–20	0/5	1/5	0–20%
	4–24	0/5	2/5	0–33%
	6–44	0/5	3/5	0–60%
Embotrap	5–21	1/5 ^a	2/5	20–40%
Penumbra 3D	4.5–26	0/5	2/5	0–40%
Revive	4.5–22	1/5 ^a	2/5	20–40%
Mindframe	3–23	0/5	2/5	0–40%
Solitaire FR	4–20	0/5	3/5	0–60%
	6–30	1/5 ^a	3/5	20–60%
Preset	4–20	0/5	3/5	0–60%
	6–30	2/5 ^a	3/5	40–60%
Preset LT	3–20	0/5	1/5	0–20%
	4–20	0/5	2/5	0–40%
Catch	3–15	0/5	1/5	0–20%
	4–20	1/5 ^a	1/5	20–20%
	6–30	1/5 ^a	3/5	20–60%
Neva™ M1	4–36	NA	7/10	70%
Neva™ T	4.5–44	6/10	NA	60%

^a Minimal clot displacement.

drop zones is identified by the separation of the proximal markers. The operator must not perform a pushing movement because markers pushed toward the vessel wall could damage the endothelium, instead a succession of tension (pulling) and release cycles are repeated until the markers open and the device is pulled proximally.

We divided our preclinical evaluation in three main chapters: efficacy analysis, mechanical analysis and safety analysis. Efficacy analysis permitted the visualization of the drop zones incorporating the firm clot and capturing the clot in the distal closed end. Considering that *Experimental thrombectomies* were performed using organized, firm clots, the overall rate of OCT and ECR has to be considered high for Neva™ devices in comparison to results obtained in a similar study in which currently available stent retrievers were tested in similar phantom with experimental organized clot produced with the same protocol used in the present study [9] (Table 4). Furthermore, the vascular phantom allowed visualization of the device as it traversed tortuous bends mimicking the carotid siphon. The Neva™ devices demonstrated good wall apposition and resisted stretch related deformation during retrieval. Such feature is another factor, which is positively related to effective clot removal. Mechanical analysis permitted evaluation of the radial pressure shift of devices during the retrieval. Both Neva™ devices showed a shift of the radial pressure when retrieved in vessels of increasing diameter, namely tubes of 1.5 mm and 3.5 mm. Radial pressure values ranged from 1486 to 853 Pa (N/m²) for Neva™ T and from 1533 to 1020 Pa for Neva™ M1. These values appear lightly higher in comparison to those of other stent retrievers (Table 3). Such feature along with their peculiar design could explain the effective behavior of Neva™ devices during the retrieval. Finally, the safety analysis performed in the animal study demonstrated that the features of the device, including offset drop zones, does not appear to change the safety profile compared to a similar study on Trevo device (Stryker, Kalamazoo, Michigan, USA) published by Nogueira et al. [11]. Authors report for the tested arteries an injury score ranging from 4.3 to 4.5 (out of 20) while for Neva™ devices scores ranged from 2.63 to 2.88. Similarly to this study the histopathological analysis of the tested vessels showed as the most frequent finding the disruption of the intima due to severe endothelial loss with, in some cases, minimal disruption of the internal elastic lamina. Nevertheless no cases of medial and adventitia hemorrhage, perforation or dissection have been recorded.

Some degree of vasospasm was noted during experiments; in all cases it recovered fully or to less than 10% on serial controls performed for 30–60 min after final retrieval.

In summary, the Neva™ device has demonstrated safety and efficacy in a pre-clinical study. Such encouraging, preliminary results have to be compared with those of clinical trials to determine if this novel device improves upon current stent retriever outcomes in the treatment of acute ischemic stroke.

Disclosure of interest

Legacy Ventures funded this project; however, all the performance data analysis and interpretation was performed by the authors, independent of Legacy Ventures's input or interpretation. Jay Ulm has stock ownership in Legacy Ventures.

References

- [1] Berkhemer OA, Fransen PS, Beumer D, van den Berg LA, Lingsma HF, Yoo AJ, et al. A randomized trial of intraarterial treatment for acute ischemic stroke. *N Engl J Med* 2015;372:11–20.
- [2] Jovin TG, Chamorro A, Cobo E, de Miquel MA, Molina CA, Rovira A, et al. Thrombectomy within 8 hours after symptom onset in ischemic stroke. *N Engl J Med* 2015;372:2296–306.
- [3] Saver JL, Goyal M, Bonafe A, Diener HC, Levy JL, Pereira VM, et al. Stent-retriever thrombectomy after intravenous t-PA vs. t-PA Alone in stroke. *N Engl J Med* 2017;372:2285–95.
- [4] Goyal M, Demchuk AM, Menon BK, Eesa M, Rempel JL, Thornton J, et al. Randomized assessment of rapid endovascular treatment of ischemic stroke. *N Engl J Med* 2015;372:1019–30.
- [5] Campbell BC, Mitchell PJ, Kleinig TJ, Dewey HM, Churilov L, Yassi N, et al. Endovascular therapy for ischemic stroke with perfusion-imaging selection. *N Engl J Med* 2015;372:1009–18.
- [6] Wenger KJ, Berkefeld J, Wagner M. Flat panel detector computed tomography for the interaction between contrast-enhanced thrombi and stent retrievers in stroke therapy: a pilot study. *Clin Neuroradiol* 2014;24:251–4.
- [7] Katori N, Tanaka KA, Szlam F, Levy JH. The effect of platelet count on clot retraction and tissue-plasminogen activator-induced fibrinolysis on thrombelastography. *Anesth Analg* 2005;100:1781–5.
- [8] Machi P, Costalat V, Lobotesis K, Maldonado IL, Vendrell JF, Riquelme C, et al. Solitaire FR thrombectomy system: immediate results in 56 consecutive acute ischemic stroke patients. *J Neurointerv Surg* 2012;4(January (1)):62–6.
- [9] Machi P, Jourdan F, Ambard D, Reynaud C, Lobotesis K, Sanchez M, et al. Experimental evaluation of stent retriever's mechanical properties and effectiveness. *J Neurointerv Surg* 2016;1–7.
- [10] Grandin CB, Cosnard G, Hammer F, Duprez TP, Stroobandt G, Mathurin P, et al. Vasospasm after subarachnoid hemorrhage: diagnosis with MR angiography. *AJNR Am J Neuroradiol* 2000;21:1611–7.
- [11] Nogueira RG, Levy EI, Gounis M, Siddiqui AH. The Trevo device: preclinical data of a novel stroke thrombectomy device in two different animal models of arterial thrombo-occlusive disease. *J Neurointerv Surg* 2012;4:295–300.
- [12] Madjidyar J, Hermes J, Freitag-Wolf S, Jansen O. Stent-thrombus interaction and the influence of the aspiration on mechanical thrombectomy: evaluation of different stent retrievers in a circulation model. *Neuroradiology* 2018. <http://dx.doi.org/10.1007/s00234-015-1526-4>.
- [13] Boeckh-Behrenc T, Schubert M, Förschler A, Prothmann S, Kreiser K, Zimmer C, et al. The impact of histological clot composition in embolic stroke. *Clin Neuroradiol* 2014. <http://dx.doi.org/10.1007/s00062-014-0347-x>.
- [14] Mordasini P, Frabetti N, Gralla J, Schroth G, Fischer U, Arnold M, et al. In vivo evaluation of the first dedicated combined flow-restoration and mechanical thrombectomy device in a swine model of acute vessel occlusion. *AJNR Am J Neuroradiol* 2011;32:294–300.
- [15] Yuki I, Kan I, Vinters HV, Kim RH, Golshan A, Vinuela FA, et al. The impact of thromboemboli histology on the performance of a mechanical thrombectomy device. *AJNR Am J Neuroradiol* 2012;33:643–8.
- [16] Roth C, Junk D, Papanagiotou P, Keuler A, Körner H, Schumacher M, et al. A Comparison of 2 stroke devices: the new aperio clot-removal device and the solitaire AB/FR. *AJNR Am J Neuroradiol* 2012;33:1317–20.
- [17] Gralla J, Schroth G, Remonda L, Fleischmann A, Fandino J, Slotboom J, et al. A dedicated animal model for mechanical thrombectomy in acute stroke. *AJNR Am J Neuroradiol* 2006;27:1357–61.
- [18] Hofmeister J, Kulcsar Z, Bernava G. The catch mini stent retriever for mechanical thrombectomy in distal intracranial occlusions. *J Neuroradiol* 2018. <http://dx.doi.org/10.1016/j.neurorad.2018.01.051>.
- [19] Pierot L, Gauvrit JY, Costalat V, Piotin M, Mounayer C, Herbreteau DJ, et al. Endovascular treatment of acute ischemic stroke with ERIC device. *J Neuroradiol* 2017;44:367–70.
- [20] Wenger KJ, Nagle F, Wagner M, Berkefeld J. Improvement of stent retriever design and efficacy of mechanical thrombectomy in a flow model. *Cardiovasc Intervent Radiol* 2013;36:192–7.