



HAL
open science

Encephalitis caused by an unusual human herpes virus type 6 and *Toxoplasma gondii* co-infection in a cord blood transplant recipient

Alexandra Chapuis, Cécile Chabrot, Audrey Mirand, Philippe Poirier, Céline Nourrisson

► **To cite this version:**

Alexandra Chapuis, Cécile Chabrot, Audrey Mirand, Philippe Poirier, Céline Nourrisson. Encephalitis caused by an unusual human herpes virus type 6 and *Toxoplasma gondii* co-infection in a cord blood transplant recipient. *International Journal of Infectious Diseases*, 2016, 46, pp.79-81. 10.1016/j.ijid.2016.04.002 . hal-01883191


HAL Id: hal-01883191

<https://hal.science/hal-01883191v1>

Submitted on 27 Sep 2018

HAL is a multi-disciplinary open access archive for the deposit and dissemination of scientific research documents, whether they are published or not. The documents may come from teaching and research institutions in France or abroad, or from public or private research centers.

L'archive ouverte pluridisciplinaire **HAL**, est destinée au dépôt et à la diffusion de documents scientifiques de niveau recherche, publiés ou non, émanant des établissements d'enseignement et de recherche français ou étrangers, des laboratoires publics ou privés.



Case Report

Encephalitis caused by an unusual human herpes virus type 6 and *Toxoplasma gondii* co-infection in a cord blood transplant recipient



Alexandra Chapuis^a, Cécile Chabrot^b, Audrey Mirand^{c,d}, Philippe Poirier^{a,e},
Céline Nourrisson^{a,e,*}

^a Laboratoire de Parasitologie-Mycologie, Centre de Biologie, CHU Gabriel Montpied, 58, rue Montalembert, F-63003 Clermont-Ferrand, France

^b Service d'Hématologie clinique et Thérapie cellulaire, CHU Estaing, Clermont-Ferrand, France

^c Service de Virologie, Centre National de Référence des Enterovirus–Parechovirus, Clermont-Ferrand, France

^d Université d'Auvergne, EA4843 « Epidémiologie et Pathogénie des Infections à Entérovirus », Faculté de Médecine, Clermont-Ferrand, France

^e Clermont Université, Université Blaise Pascal-Université d'Auvergne-CNRS, UMR 6023 Laboratoire Microorganismes: Génome et Environnement, Clermont-Ferrand, France

ARTICLE INFO

Article history:

Received 13 February 2016

Received in revised form 18 March 2016

Accepted 1 April 2016

Corresponding Editor: Eskild Petersen, Aarhus, Denmark.

Keywords:

Toxoplasmosis

HHV-6

Cord blood transplantation

Encephalitis

Cerebral co-infection

SUMMARY

Background: The case of a central nervous system human herpes virus type 6 (HHV-6) and *Toxoplasma gondii* co-infection after an umbilical cord blood transplantation in a chronic myelomonocytic leukaemia patient is reported.

Case report: A 65-year-old Caucasian man underwent an umbilical cord blood transplantation within the context of chronic myelomonocytic leukaemia. On day 37 post-graft, he presented with a severe headache; PCRs of cerebrospinal fluid and blood were positive for *T. gondii* and HHV-6. The patient was treated with pyrimethamine and sulfadiazine associated with ganciclovir.

Conclusion: HHV-6 reactivation can trigger a reactivation of *T. gondii*. This case suggests that patients who are seropositive for *T. gondii* and who present with HHV-6 reactivation should be monitored closely for toxoplasmosis.

© 2016 The Authors. Published by Elsevier Ltd on behalf of International Society for Infectious Diseases. This is an open access article under the CC BY-NC-ND license (<http://creativecommons.org/licenses/by-nc-nd/4.0/>).

1. Introduction

Reactivation of latent infections are life-threatening diseases in immunocompromised patients. We describe a cerebral toxoplasmosis in a context of human herpes virus type 6 reactivation after an umbilical cord blood transplantation.

2. Case report

A 65-year-old man was hospitalized in the haematology clinic for an umbilical cord blood transplantation within the context of chronic myelomonocytic leukaemia diagnosed in September 2013. The patient underwent 11 courses of azacitidine treatment before transplantation. The patient's medical history revealed him to be seropositive for hepatitis A virus, Epstein–Barr virus, and *Toxoplasma gondii*.

Immunosuppressive therapy was started on September 15, 2014 with ciclosporin 300 mg daily and mycophenolate mofetil 1 g twice a day. On September 18, 2014 he received two umbilical cord blood transplants, with good tolerance, and remained in aplasia for 27 days. The patient was continued on antimicrobial prophylaxis with fluconazole and aciclovir during aplasia. On day 4 post-graft, the anti-*T. gondii* IgG value was 91 IU/ml (positive value ≥ 8 IU/ml; BioMérieux Vidas Toxo IgG) and anti-*T. gondii* IgM was negative (BioMérieux Vidas Toxo IgM). On day 11 post-graft, a febrile episode associated with an inflammatory reaction (C-reactive protein 129 mg/l; normal value < 3 mg/l) was treated successfully with piperacillin. Antibiotic therapy was stopped on day 28 after the recovery of blood marrow suppression. Corticosteroids consisting of prednisone 1 mg/kg daily were started on day 20 after a skin rash appeared on the patient's back and chest, covering more than 50% of his body. Mycophenolate mofetil was stopped on day 35 post-graft and ciclosporin was continued at 210 mg twice a day.

On day 37 post-graft, the patient presented a severe headache and moderate fever. Blood count analysis revealed a leukocyte

* Corresponding author. Tel.: +33 4 73 75 01 95; fax: +33 4 73 75 01 96.
E-mail address: c_nourrisson@chu-clermontferrand.fr (C. Nourrisson).

count of 2.26×10^9 cells/l, with lymphocytes of 0.45×10^9 cells/l. A computed tomography (CT) scan of the brain was performed, but did not highlight any bleeding or infectious lesions. Cerebrospinal fluid (CSF) sampled on day 40 showed an increase in proteins (2.69 g/l; normal range 0.15–0.45 g/l) and lactate (4.9 mmol/l; normal range 0.6–2.2 mmol/l), and 98×10^6 red blood cells/l and 21×10^6 leukocytes/l, with a predominance of monocytes (68%) and lymphocytes (20%). May–Grünwald–Giemsa staining of the CSF highlighted tachyzoites of *T. gondii* (Figure 1). The *T. gondii* load measured using quantitative PCR was 1800 parasites/ml in CSF and 960 parasites/ml in blood. Viral investigation of the CSF yielded a positive PCR for human herpes virus type 6 (BioMérieux CMV, HHV-6, 7, 8, R-gene Assay) with a cycle threshold value of 37.6, indicating a low viral load. HHV-6 genome quantification in blood was positive below 1000 copies/ml. The anti-*Toxoplasma* IgG value was 43 IU/ml. Treatment for cerebral toxoplasmosis comprising pyrimethamine (50 mg daily) and sulfadiazine (500 mg three times daily) was started on day 41, for 6 weeks, associated with antiviral treatment (ganciclovir, 10 mg/kg daily). The patient's clinical condition improved rapidly, with a regression of the headache; he became afebrile on day 45. The anti-*Toxoplasma* IgG value was 45 IU/ml.

CSF sampled on day 49 still displayed pleocytosis, with 32×10^6 lymphocytes/l. *Toxoplasma* real-time PCR was positive (39 parasites/ml), whereas HHV-6 PCR was negative. Magnetic resonance imaging performed on the same day did not show any cerebral abscess indicative of toxoplasmosis, but showed images suggestive of graft-versus-host disease (GVHD). Real-time PCR performed on the blood was positive for HHV-6 (1726 copies/ml) but negative for *T. gondii*. Complete negativity of the HHV-6 quantitative PCR occurred on day 74. The patient was discharged from hospital on day 64, but was readmitted 10 days later for diarrhoea associated with acute renal insufficiency inducing metabolic acidosis and hyperkalaemia. A colonic biopsy showed grade 3 GVHD and methylprednisolone was increased to 2 mg/kg daily. On day 78, the patient became confused with meningeal syndrome and was transferred to the intensive care unit. Blood cultures were positive for *Escherichia coli*. CSF analysis showed poor cellularity (2×10^6 red blood cells/l and 4×10^6 leukocytes/l) associated with an increase in lactate (7.2 mmol/l) and proteins (0.96 g/l). Real-time PCR for *T. gondii* and HHV-6 performed on both CSF and blood were negative. Empirical antibiotic therapy was started with piperacillin–tazobactam and gentamicin. The patient died on day 82 of multiorgan failure.

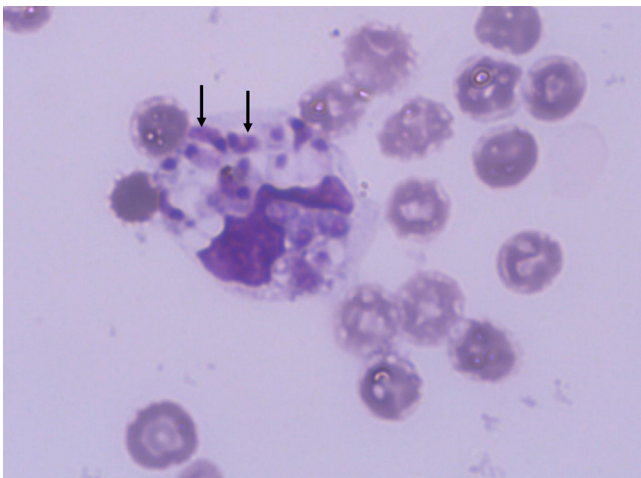


Figure 1. Tachyzoites of *Toxoplasma gondii* inside neutrophils in May–Grünwald–Giemsa-stained CSF samples (x1000). Arrows show tachyzoites.

3. Discussion

Umbilical cord blood transplantation (CBT) is an alternative source of haematopoietic stem cells and is used in both paediatric and adult cancer patients. The complete immaturity of the immune system at birth has the advantages of inducing fewer immunological complications and not requiring a perfect match between the donor and recipient.

Patients undergoing allogeneic hematopoietic stem cell transplantation (HSCT) are especially susceptible to severe toxoplasmosis, with an estimated incidence of between 0.4% and 8.7% according to the endemicity.¹ In HSCT patients, toxoplasmosis mainly results from the reactivation of a latent infection rather than primary infection. CBT is associated with an additional delay in immune reconstitution, which is an important risk factor for toxoplasmosis and other opportunistic diseases. The rate of severe toxoplasmosis has been reported to be significantly higher in CBT patients than in those undergoing other types of allogeneic HSCT.¹ In most cases, reactivation occurs during the second or third month post-HSCT. To monitor the reactivation of toxoplasmosis, a weekly PCR follow-up in blood is recommended, particularly during the high-risk periods and for patients who are not receiving prophylaxis.² Indeed, the administration of primary chemoprophylaxis should be considered in high-risk HSCT recipients and should be maintained for 6 months post-HSCT.² Co-trimoxazole prophylaxis is widely used in European HSCT centres.² PCR is the most powerful tool for the diagnosis of cerebral toxoplasmosis, as direct staining is rarely positive and serology can give false results in the immunosuppressed patient.

HHV-6 encephalitis appears to occur more frequently in patients undergoing CBT.³ Some studies have suggested that the increased prevalence of HHV-6 reactivation may be due to the large number of immature T-cells present in umbilical cord blood. HHV-6 represents an important emerging pathogen responsible for central nervous system (CNS) complications accompanying HSCT.³ The diagnosis of HHV-6 meningoencephalitis includes neurological manifestations and positive detection of HHV-6 DNA in the CSF, in the absence of any other identifiable pathogen.⁴ Mortality rates attributable to HHV-6 meningitis remain high, and many survivors present cognitive sequelae.³ HHV-6 reactivation has also been associated with an increased risk of GVHD, cytopenia, opportunistic infections, and fever.³ Initially developed to target human cytomegalovirus infection, ganciclovir has been shown to be effective against HHV-6 in both in vitro and in vivo studies. Thus, the American Society of Transplantation recommends the use of ganciclovir and foscarnet as first-line therapy for HHV-6 encephalitis.^{5,6}

The concomitant detection of DNA for both *T. gondii* and HHV-6 in the CSF has only been reported once, in a retrospective analysis of 181 CSF samples from patients with suspected viral meningitis.⁷ This co-infection was observed in an HIV-infected patient, but no detailed description of the neurological signs was mentioned in that report. A case of unilateral panuveitis associated with HHV-6 and *T. gondii* co-infection has also been described.⁸ Clinical symptoms were suggestive of ocular toxoplasmosis and the evolution was favourable after anti-*Toxoplasma* and antiviral combination treatment. The pathogenicity of HHV-6 is not well understood, but it could participate in the reactivation of *T. gondii*.

The primary risk factor for toxoplasmosis in the patient presented here was CBT without anti-*Toxoplasma* prophylaxis. However, although transient, the concomitant reactivation of HHV-6 could have played a role in the occurrence of the toxoplasmosis. Both HHV-6 and *T. gondii* show neurotropism and a latency stage in the CNS, and HHV-6 is also known to replicate in CD4+ cells and deplete T-cells, which may favour intracellular opportunistic pathogens such as *Toxoplasma*.⁹ This

mechanism has been reported previously in mice carrying latent *T. gondii* and infected with murine cytomegalovirus (MCMV).¹⁰ Acute MCMV infection in mice was associated with a striking decrease in lung CD4+ cells and an increased rate of pulmonary toxoplasmosis.

In conclusion, the first case of a CNS *T. gondii* and HHV-6 co-infection in a CBT recipient is reported herein. This case suggests that patients who are seropositive for *Toxoplasma* and who present with HHV-6 reactivation should to be monitored closely for toxoplasmosis. Data on HHV-6 and *Toxoplasma* co-infection are scarce and further clinical studies are required to clarify the link between HHV-6 and *Toxoplasma* reactivations.

Conflict of interest: None.

References

1. Hakko E, Ozkan HA, Karaman K, Gulbas Z. Analysis of cerebral toxoplasmosis in a series of 170 allogeneic hematopoietic stem cell transplant patients. *Transpl Infect Dis* 2013;**15**:575–80.
2. Derouin F, Pelloux H, ESCMID Study Group on Clinical Parasitology. Prevention of toxoplasmosis in transplant patients. *Clin Microbiol Infect* 2008;**14**:1089–101.
3. Ogata M, Satou T, Kadota J, Saito N, Yoshida T, Okumura H, et al. Human herpesvirus 6 (HHV-6) reactivation and HHV-6 encephalitis after allogeneic hematopoietic cell transplantation: a multicenter, prospective study. *Clin Infect Dis* 2013;**57**:671–81.
4. Corti M, Villafañe MF, Trione N, Mamanna L, Bouzas B. Human herpesvirus 6: report of emerging pathogen in five patients with HIV/AIDS and review of the literature. *Rev Soc Bras Med Trop* 2011;**44**:522–5.
5. Agut H, Bonnafous P, Gautheret-Dejean A. Laboratory and clinical aspects of human herpesvirus 6 infections. *Clin Microbiol Rev* 2015;**28**:313–35.
6. Razonable RR, Zerr DM. AST Infectious Diseases Community of Practice. HHV-6, HHV-7 and HHV-8 in solid organ transplant recipients. *Am J Transplant* 2009;**9**(Suppl 4):S97–100.
7. Del Prete R, Di Taranto AM, Lipsi MR, Natalicchio MI, Antonetti R, Miragliotta G. Simultaneous detection of viruses and *Toxoplasma gondii* in cerebrospinal fluid specimens by multiplex polymerase chain reaction-based reverse hybridization assay. *New Microbiol* 2009;**32**:143–6.
8. Glâtre F, Rousseau E, Bacin F. Unilateral uveitis with HHV6-positive polymerase chain reaction in aqueous humor for an etanercept-treated woman: a case report. *J Fr Ophthalmol* 2010;**33**:561–3.
9. Lusso P, Ensoli B, Markham PD, Ablashi DV, Salahuddin SZ, Tschachler E, et al. Productive dual infection of human CD4+ T lymphocytes by HIV-1 and HHV-6. *Nature* 1989;**337**:370–3.
10. Pomeroy C, Filice GA, Hitt JA, Jordan MC. Cytomegalovirus-induced reactivation of *Toxoplasma gondii* pneumonia in mice: lung lymphocyte phenotypes and suppressor function. *J Infect Dis* 1992;**166**:677–81.