



HAL
open science

Induced vomiting in conjunction with the “Heimlich maneuver” for gastric foreign body extraction in dogs: 100 cases

Cyril Duperrier-Simond, Françoise Roux, Jack-Yves Deschamps

► **To cite this version:**

Cyril Duperrier-Simond, Françoise Roux, Jack-Yves Deschamps. Induced vomiting in conjunction with the “Heimlich maneuver” for gastric foreign body extraction in dogs: 100 cases. IVECCS, Sep 2018, Nouvelle Orléans, United States. 2018. hal-01881413

HAL Id: hal-01881413

<https://hal.science/hal-01881413>

Submitted on 25 Sep 2018

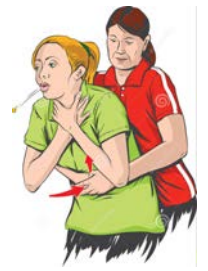HAL is a multi-disciplinary open access archive for the deposit and dissemination of scientific research documents, whether they are published or not. The documents may come from teaching and research institutions in France or abroad, or from public or private research centers.

L'archive ouverte pluridisciplinaire **HAL**, est destinée au dépôt et à la diffusion de documents scientifiques de niveau recherche, publiés ou non, émanant des établissements d'enseignement et de recherche français ou étrangers, des laboratoires publics ou privés.

Induced vomiting in conjunction with the “Heimlich maneuver” for gastric foreign body extraction in dogs: 100 cases

Dr Cyril DUPERRIER-SIMOND, DVM,
Pr Françoise ROUX, DVM, PhD, DACVECC, DECVCEC,
Pr Jack-Yves DESCHAMPS, DVM, PhD,

ONIRIS,
College of Veterinary Medicine,
Emergency and critical care unit,
La Chantrerie, CS 40706, 44 307 Nantes Cedex 03, FRANCE
E-mail: jack.deschamps@oniris-nantes.fr



Introduction

Gastric foreign bodies are conventionally managed by endoscopic extraction or gastrotomy.

Method

This study examines the results of a first-line non-invasive technique for the management of foreign body ingestion, or in which a gastric foreign body had been identified by imaging, in a population of dogs presented to an emergency department between January 1, 2013 and March 1, 2017.

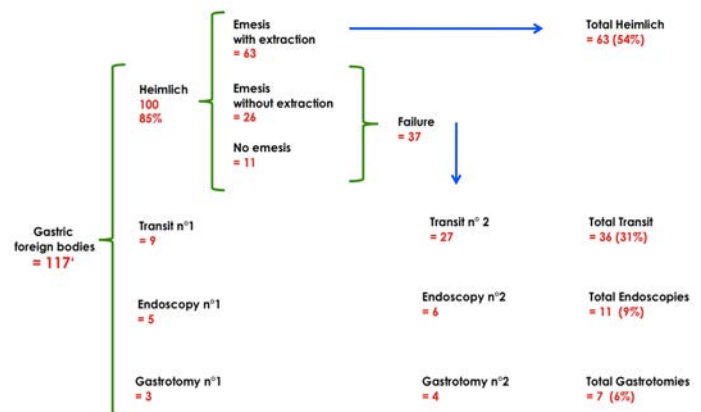
Our practice favors **oral evacuation**. The technique consists of giving a **large meal, inducing vomiting** with an emetic substance and then exerting **pressure on the abdomen during vomiting**. We have named this procedure the "Heimlich maneuver" in reference to the procedure described by H. J. Heimlich in 1970 for airway obstruction in humans. In case of failure options are considered: “wait-and-see,” endoscopic extraction or gastrotomy.



Results

117 dogs were identified. Initially, induced vomiting in conjunction with a “Heimlich maneuver” was attempted in 100 dogs (85%); 77 (77%) of these dogs vomited, allowing **extraction of 63 (63%) foreign bodies**, 54% of the total. Surveillance without intervention was elected in 9 dogs (8%); 5 dogs (4%) underwent endoscopic extraction; and 3 dogs (3%) underwent extraction by gastrotomy.

Subsequently, among the 37 dogs for which the foreign body was not recovered (23 dogs who did not vomit and 14 dogs who vomited but in whom the Heimlich maneuver did not produce the foreign body), 27 dogs (23% of total gastric foreign bodies) received no treatment, 6 dogs (5%) underwent endoscopic extraction and 4 dogs (3%) underwent gastrotomy.



Among the 77 foreign bodies recovered, the most represented were bones (n = 9), stones (n = 7), plastic (n = 6), socks (n = 5) and textiles (n = 5). Potentially wounding foreign bodies were extracted successfully: a drill tip, glass, a needle, a bulb socket, copper wire (2 cases), a beer capsule. Some foreign bodies were bulky with regard to the size of the dog: a floorcloth, a tampon, a sponge. A catheter ingested during hospitalization was recovered by this technique. No complications were observed.



In total, induction of vomiting associated with the **Heimlich maneuver resulted in extraction of 54%** of gastric foreign bodies, and **“wait-and-see” sufficed in 30%**. Non-invasive management was therefore effective in 84% of cases. **Only 16% of cases required intervention: endoscopic extraction (10%) or gastrotomy (6%).**

Conclusion

We propose a novel, simple, minimally-invasive, cheap and often effective extraction technique for gastric foreign bodies in dogs. This technique and “wait-and-see” should be considered before endoscopy or gastrotomy is attempted.