



HAL
open science

STAT3 Gain of Function: A New Kid on the Block in Interstitial Lung Diseases

Alexandre Fabre, Sarah Marchal, Lisa Renee Forbes, Tiphanie Phillips Vogel, Vincent Barlogis, Valerie Triolo, Pierre-Simon Rohrlich, Etienne Berard, Diane Frankel, Damien Ambrosetti, et al.

► **To cite this version:**

Alexandre Fabre, Sarah Marchal, Lisa Renee Forbes, Tiphanie Phillips Vogel, Vincent Barlogis, et al.. STAT3 Gain of Function: A New Kid on the Block in Interstitial Lung Diseases. American Journal of Respiratory and Critical Care Medicine, 2018, 197 (11), pp.E22-E23. 10.1164/rccm.201707-1500IM . hal-01858930

HAL Id: hal-01858930

<https://hal.science/hal-01858930>

Submitted on 12 Apr 2019

HAL is a multi-disciplinary open access archive for the deposit and dissemination of scientific research documents, whether they are published or not. The documents may come from teaching and research institutions in France or abroad, or from public or private research centers.

L'archive ouverte pluridisciplinaire **HAL**, est destinée au dépôt et à la diffusion de documents scientifiques de niveau recherche, publiés ou non, émanant des établissements d'enseignement et de recherche français ou étrangers, des laboratoires publics ou privés.

STAT3 Gain of Function: A New Kid on the Block in Interstitial Lung Diseases

Alexandre Fabre^{1,2*}, Sarah Marchal^{3*}, Lisa Renee Forbes⁴, Tiphonie Phillips Vogel⁴, Vincent Barlogis⁵, Valérie Triolo³, Pierre-Simon Rohrlach^{6,7}, Etienne Bérard^{7,8}, Diane Frankel^{2,9}, Damien Ambrosetti¹⁰, Christine Soler⁶, Marie Hoflack¹¹, Marie Baque¹², Emmanuelle Bosdure¹³, Mélisande Baravalle¹³, Ania Carsin¹³, Jean-Christophe Dubus^{2,13}, and Lisa Giovannini-Chami^{3,7}

¹Service de Pédiatrie Multidisciplinaire, ⁵Service d'Hématologie Pédiatrique, ⁹Service de Biologie Cellulaire, and ¹³Service de Pneumologie Pédiatrique, Assistance Publique des Hôpitaux de Marseille, Timone Enfant, Marseille, France; ²Aix Marseille Université, Institut National de la Santé et de la Recherche Médicale, Génétique Médicale Fonctionnelle, Marseille, France; ³Service de Pneumologie et de Gastroentérologie Pédiatrique, ¹¹Service d'Endocrinologie et de Neurologie Pédiatrique, and ¹²Service de Radiologie Pédiatrique, Hôpitaux Pédiatriques de Nice CHU-Lenval, Nice, France; ⁴Section of Immunology, Allergy, and Rheumatology, Department of Pediatrics, Baylor College of Medicine, Center for Human Immunobiology, Texas Children's Hospital Infusion Center, Houston, Texas; ⁶Service d'Hématologie Pédiatrique, ⁸Service de Néphrologie Pédiatrique, and ¹⁰Service d'Anatomo-Pathologie, Centre Hospitalier Universitaire de Nice, Nice, France; and ⁷Université de Nice-Sophia Antipolis, Nice, France

ORCID ID: 0000-0002-5084-213X (L.G.-C.).

A 5-year-old girl with failure to thrive and multiorgan disease was referred to our center for chronic hypoxemia. On evaluation, we noted tachypnea (respiratory rate 35/min), supraclavicular retractions, median diurnal oxygen saturation as measured by pulse oximetry (Sp_{O_2}) = 91.7% at rest, percentage of time below Sp_{O_2} 90% at 26% during sleep, and clubbing. A computed tomography scan showed diffuse interstitial lung disease (Figure 1). Spirometry was normal (TLC, 83% of predicted; FEV₁, 83% of predicted; FEV₁/FVC, 98%; and forced expiratory flow, midexpiratory phase, 142% of predicted), but it was not possible to measure DL_{CO}. BAL analysis found hypercellularity (490×10^3 cells/ml), lymphocytosis (69% lymphocytes), and a negative microbiological evaluation. Transbronchial lung biopsies were inconclusive.

The patient's medical history included intrauterine growth restriction, severe growth failure (−4 SD), lymphocytic enteropathy with total villous atrophy, pseudoceliac disease, hepatosplenomegaly, dental abnormalities, and atopic dermatitis. After the progression of lung disease, she subsequently developed bilateral knee oligoarthritis and worsening enteropathy, requiring parenteral nutrition. Further extrapulmonary evaluation showed massive hyper-IgA, B-lymphocyte deficiency, renal disease with tubulopathy, central corticotropic insufficiency, and lymphocytic sialadenitis.

Given the complexity of the patient's multiorgan autoimmune disease, whole-exome sequencing was performed showing a heterozygous germline gain-of-function (GOF) *STAT3* (signal transducer and activator of transcription 3) mutation (E415L). Segregation of the mutation and Sanger verification confirmed a *de novo* mutation. Luciferase reporter assay, performed as previously described (1), confirmed GOF activity (data not shown). *STAT3* GOF, described recently, results in early-onset growth failure, multiorgan autoimmunity, immunodeficiency, and lymphoproliferation. To date, 28 cases have been reported; among these, 7 presented with interstitial pneumonitis (1–4), of which 4 were consistent with lymphoid interstitial pneumonia. In addition, several publications have suggested that aberrant *STAT3* signaling plays a critical role in the pathogenesis of interstitial and fibrotic lung disease (5).

STAT3 GOF is an important new clinical entity to consider in childhood interstitial lung disease associated with hematological and multiorgan autoimmune disease. ■

Author disclosures are available with the text of this article at www.atsjournals.org.

*These authors contributed equally to this work.

Author Contributions: A.F., S.M., L.R.F., and L.G.-C. drafted the initial manuscript, participated in the conceptualization and design of the case report, contributed to the acquisition of data, performed a complete review of the current bibliography, critically revised the manuscript, and approved the final manuscript as submitted; T.P.V. participated in the conceptualization and design of the case report, performed the functional assessment of the mutation with luciferase reporter assay, critically revised the manuscript, and approved the final manuscript as submitted; V.B., V.T., P.-S.R., E. Bérard, C.S., M.H., E. Bosdure, M. Baravalle, A.C., and J.-C.D. were involved in clinical follow-up of the patient, participated in the conceptualization and design of the case report, contributed to the acquisition of data, critically revised the manuscript, and approved the final manuscript as submitted; M. Baque participated in the conceptualization and design of the case report, contributed to the acquisition of the computed tomography scan, critically revised the manuscript, and approved the final manuscript as submitted; D.A. participated in the conceptualization and design of the case report, contributed to the acquisition of accessory salivary gland biopsy data, critically revised the manuscript, and approved the final manuscript as submitted; and D.F. participated in the conceptualization and design of the case report, analyzed BAL cytopspins, critically revised the manuscript, and approved the final manuscript as submitted.

Am J Respir Crit Care Med Vol 197, Iss 11, pp e22–e23, Jun 1, 2018

Copyright © 2018 by the American Thoracic Society

Originally Published in Press as DOI: 10.1164/rccm.201707-1500IM on March 28, 2018

Internet address: www.atsjournals.org

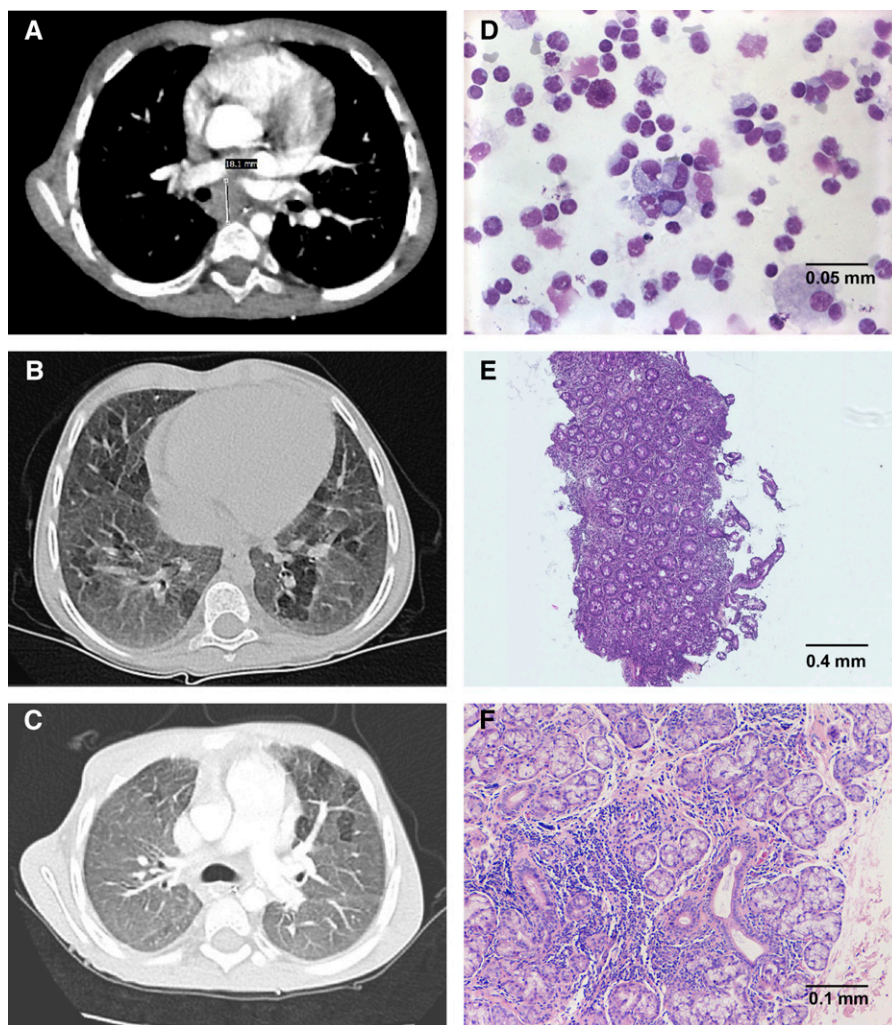


Figure 1. (A–C) Chest computed tomography scans showing (A) subcarinal adenomegaly and (B and C) ground-glass opacities with mosaic pattern and interlobular septal thickening. (D–F) Cytology and histology showing lymphoproliferation: (D) BAL cytospins: massive lymphocytosis (stained with May-Grünwald-Giemsa); (E) whole biopsy slide showing almost total villous atrophy with an inflammatory background, presence of a mononuclear material with very dense focal regions of increased intraepithelial lymphocytes (hematoxylin and eosin–stained section); and (F) accessory salivary gland biopsy: massive lymphoid infiltrate, interstitial fibrosis, and acinar atrophy (hematoxylin and eosin–stained section).

Acknowledgment: The authors thank Dr. P. Gauchez and Dr. J. Del-Grande for their help with the study of the intestinal biopsy; Dr. Cano for metabolic evaluation; Dr. Vely and

Dr. Farnarier for immunologic evaluation; Prof. C. Badens and Dr. C. Lacoste for their help with the molecular biology study; Prof. S. Ehl and Dr. M. Heeg for their help in the

functional study of the STAT3 mutation; and Prof. P. Roll, Dr. A. Robaglia-Schlupp, and Dr. E. Kaspi for their reassessment with Dr. Frankel of the BAL.

References

- Milner JD, Vogel TP, Forbes L, Ma CA, Stray-Pedersen A, Niemela JE, *et al.* Early-onset lymphoproliferation and autoimmunity caused by germline STAT3 gain-of-function mutations. *Blood* 2015;125: 591–599.
- Haapaniemi EM, Kaustio M, Rajala HL, van Adrichem AJ, Kainulainen L, Glumoff V, *et al.* Autoimmunity, hypogammaglobulinemia, lymphoproliferation, and mycobacterial disease in patients with activating mutations in STAT3. *Blood* 2015;125:639–648.
- Flanagan SE, Haapaniemi E, Russell MA, Caswell R, Allen HL, De Franco E, *et al.* Activating germline mutations in STAT3 cause early-onset multi-organ autoimmune disease. *Nat Genet* 2014;46:812–814.
- Weinreich MA, Vogel TP, Rao VK, Milner JD. Up, down, and all around: diagnosis and treatment of novel STAT3 variant. *Front Pediatr* 2017;5: 49.
- Pechkovsky DV, Prêle CM, Wong J, Hogaboam CM, McAnulty RJ, Laurent GJ, *et al.* STAT3-mediated signaling dysregulates lung fibroblast-myofibroblast activation and differentiation in UIP/IPF. *Am J Pathol* 2012;180:1398–1412.