



HAL
open science

Isolation of *Coxiella burnetii* from an acromioclavicular infection with low serological titres

Clea Melenotte, Geraldine Bart, Francoise Kraeber-Bodere, Serge Cammilleri, Benoit Le Goff, Didier Raoult

► **To cite this version:**

Clea Melenotte, Geraldine Bart, Francoise Kraeber-Bodere, Serge Cammilleri, Benoit Le Goff, et al.. Isolation of *Coxiella burnetii* from an acromioclavicular infection with low serological titres. *International Journal of Infectious Diseases*, 2018, 73, pp.27-29. 10.1016/j.ijid.2018.05.018 . hal-01858909

HAL Id: hal-01858909

<https://hal.science/hal-01858909v1>

Submitted on 22 Aug 2018

HAL is a multi-disciplinary open access archive for the deposit and dissemination of scientific research documents, whether they are published or not. The documents may come from teaching and research institutions in France or abroad, or from public or private research centers.

L'archive ouverte pluridisciplinaire **HAL**, est destinée au dépôt et à la diffusion de documents scientifiques de niveau recherche, publiés ou non, émanant des établissements d'enseignement et de recherche français ou étrangers, des laboratoires publics ou privés.



Case Report

Isolation of *Coxiella burnetii* from an acromioclavicular infection with low serological titresCléa Melenotte^a, Géraldine Bart^b, Françoise Kraeber-Bodere^c, Serge Cammilleri^c, Benoit Le Goff^{cd}, Didier Raoult^{a,*}^a Aix-Marseille Université, IRD, APHM, MEPHI, IHU-Méditerranée Infection, Marseille, France^b Service de Rhumatologie, Hotel-Dieu, CHU Nantes, Nantes, France^c Service de Médecine Nucléaire, Hotel-Dieu, CHU Nantes, Nantes, France^d Centre de Médecine Nucléaire, Assistance Publique des Hôpitaux de Marseille, Marseille, France

ARTICLE INFO

Article history:

Received 9 April 2018

Received in revised form 23 May 2018

Accepted 29 May 2018

Corresponding Editor: Eskild Petersen, Aarhus, Denmark

Keywords:

Q fever

Coxiella burnetii

Acromio-clavicular infection

Q fever serology

ABSTRACT

Coxiella burnetii acromioclavicular infection is a new infectious focus, evidenced here for the first time using the gold standard, culture. Positron emission tomography had a crucial role in identifying the deep infectious focus, even when *C. burnetii* serological titres were low.

© 2018 The Authors. Published by Elsevier Ltd on behalf of International Society for Infectious Diseases. This is an open access article under the CC BY-NC-ND license (<http://creativecommons.org/licenses/by-nc-nd/4.0/>).

In July 2017, a 64-year-old woman presented to the hospital with joint pain in the left shoulder and right buttock, which had evolved over the course of 1 week, without fever. Her medical history included arterial hypertension and chronic lymphocytic leukaemia, for which she had received allograft treatment 2 years previously. She was still receiving prednisolone orally, 20 mg per day, and nilotinib, 300 mg twice a day, for cutaneous and gastrointestinal graft rejection. On physical examination, she had weakness and decreased range of motion of the right shoulder. She complained of pain in the left buttock radiating to the hind side of the thigh. Laboratory tests showed haemoglobin of 10 g/dl, raised C-reactive protein (94 mg/l), and elevated transaminases (alanine aminotransferase and aspartate aminotransferase 45 IU/l and 52 IU/l respectively). An ultrasound of the right shoulder revealed acromioclavicular bursitis and multiple bone erosions. A positron emission tomography (PET) scan identified two hyper-metabolic foci, one in the acromioclavicular joint and one in the left hip (Figure 1A). The results of serological tests for *Coxiella burnetii* were positive, with phase I IgG of 100, IgM of 0, and IgA of 0, and phase II IgG of 200, IgM of 0, and IgA of 0. Synovial and bone biopsies from both joints were then sampled. *C. burnetii* PCR (Eldin

et al., 2016a) was positive for both samples, and culture of *C. burnetii* grew after 2 weeks (Figure 1B). Antibiotics were started in the form of 200 mg of oral doxycycline once per day and 200 mg of hydroxychloroquine three times per day for 18 months. At her last follow-up appointment in January 2018, the patient showed signs of clinical improvement. The fever and joint pain had disappeared and the patient had regained the range of motion of her shoulder and hip joints. The inflammatory syndrome regressed and hepatic cytolysis improved. No control PET scan or ultrasound imaging was performed.

Q fever is a worldwide zoonosis caused by the intracellular bacterium *C. burnetii*. Osteoarticular infection represents 1% of *C. burnetii* clinical manifestations. This report presents the third case of an acromioclavicular infection caused by *C. burnetii* (Eldin et al., 2016a,b; Angelakis et al., 2016). Evidence of the bacterium was proved here, for the first time, using three different techniques, including serology, PCR, and culture. The infective focus was identified using two imaging tools. *Staphylococcus aureus* is the most common microorganism isolated from acromioclavicular joint aspiration. *Streptococcus viridans*, *Streptococcus bovis*, and *Mycobacterium avium* have also been described. Most reports concern patients with an underlying predisposition or suffering from an immunocompromising disease (Iyengar et al., 2009).

Although immunosuppression has been considered as a condition predisposing to *C. burnetii* infection, the data in this

* Corresponding author at: IHU, Méditerranée Infection, 19-21 Boulevard Jean Moulin, 13385 Marseille Cedex 05, France.

E-mail address: didier.raoult@gmail.com (D. Raoult).

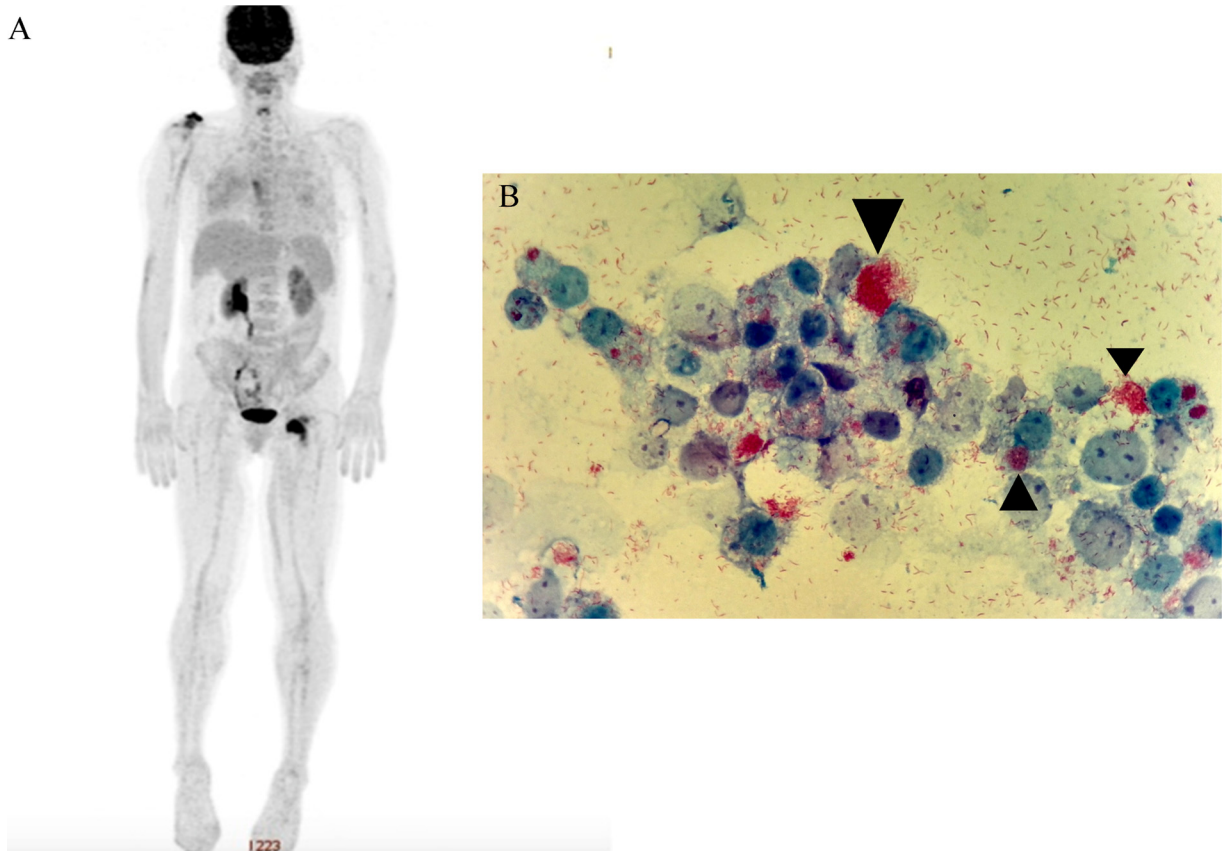


Figure 1. PET scan imaging and culture from the joint fluid. (A) Whole body PET scan imaging showed hyper-metabolism of the acromioclavicular joint and the hip joint. (B) Culture of the acromioclavicular synovial biopsy was positive for *Coxiella burnetii* after 2 weeks. Culture was performed using the shell-vial method on human embryonic lung (HEL) cells with Gimenez staining. L929 cells are coloured malachite green and *C. burnetii* bacteria are coloured pink with fuchsin. *C. burnetii* is an intracellular and fastidious bacterium located in the intracytoplasmic vacuoles (arrowhead).

regard remain controversial, as reported in recent studies from the Netherlands and French Guiana (Raoult, 1990; Epelboin et al., 2012; Schoffelen et al., 2014). By contrast, the capacity for *C. burnetii* to evade the immune response is well established and depends on host factors (Raoult, 1990; Melenotte et al., 2016). In a recent large prospective cohort study, it was demonstrated that, unlike the case presented here, immunocompromised patients were not at risk of Q fever complications (unpublished data). Nonetheless, because the patient was receiving immunosuppressive therapy, the primary infection may have been masked. Moreover, tyrosine kinase inhibitor therapy has recently been described as responsible for changes in humoral immunity of treated patients in whom low levels of immunoglobulin and rare cases of severe hypogammaglobulinemia have been reported (Rajala et al., 2017). This could explain the low serological titre observed in the patient described here, who presented a persistent active acromioclavicular *C. burnetii* infection.

PET scanning has revolutionized the diagnosis of infectious diseases by identifying foci that would have gone unnoticed using standard computed tomography (Eldin et al., 2016b; Kouijzer et al., 2018). As illustrated here, *C. burnetii* serological titres were low. Regarding the criteria defined in the Netherlands, this case of persistent focalized *C. burnetii* could have been wrongly excluded from the ‘chronic infection’ category (Kampschreur et al., 2015). In immunocompromised patients with fever, chills may not be apparent. In conclusion, serology is not sufficient to define the type of infection related to Q fever. The search for a deep infectious focus must be systematic, and PET scanning is critical in this approach.

Acknowledgments

We thank Nathalie Duclos, Emeline Vial, and Clio Grimaldier for the culture of the *Coxiella burnetii* specimen in the NSB3 routine laboratory and the photography performed. This work was supported by the French Government under the “Investissements d’avenir” (Investments for the Future) program, managed by the Agence Nationale de la Recherche (ANR, fr: National Agency for Research), (reference: Méditerranée Infection 10-IAHU-03).

Conflict of interest

The authors have no financial conflicts of interest.

References

- Angelakis E, Thiberville S-D, Million M, Raoult D. Sternoclavicular joint infection caused by *Coxiella burnetii*: a case report. *J Med Case Rep* 2016;31(10):139.
- Eldin C, Melenotte C, Mediannikov O, Ghigo E, Million M, Edouard S, et al. From Q fever to *C. burnetii* infection: a change of paradigm. *Clin Microbiol Rev* 2016a;30(1):115–90.
- Eldin C, Melenotte C, Million M, Cammilleri S, Sotto A, Elsendoorn A, et al. 18F-FDG PET/CT as a central tool in the shift from chronic Q fever to *Coxiella burnetii* persistent focalized infection: a consecutive case series. *Medicine* 2016b;95:e4287.
- Epelboin L, Chesnais C, Boullé C, Drogoul AS, Raoult D, Djossou F, et al. Q fever pneumonia in French Guiana: prevalence, risk factors, and prognostic score. *Clin Infect Dis* 2012;55(1):67–74.
- Iyengar KP, Gudena R, Chitgopkar SD, Ralte P, Hughes P, Nadkarni JB, et al. Primary septic arthritis of the acromio-clavicular joint: case report and review of literature. *Arch Orthop Trauma Surg* 2009;129(January (1)):83–6.

- Kampschreur LM, Wegdam-Blans MC, Wever PC, Renders NH, Delsing CF, Sprong T, et al. Chronic Q fever diagnosis – consensus guideline versus expert opinion. *Emerg Infect Dis* 2015;21(7):1183–8.
- Kouijzer IJE, Kampschreur LM, Wever PC, Hoekstra C, van Kasteren MEE, de Jager-Leclercq MGL, et al. The value of 18F-FDG PET/CT in diagnosis and during follow-up in 273 patients with chronic Q fever. *J Nucl Med* 2018;59(1):127–33.
- Melenotte C, Million M, Audoly G, Gorse A, Dutronc H, Roland G, et al. B-cell non-Hodgkin lymphoma linked to *Coxiella burnetii*. *Blood* 2016;127(1):113–21.
- Rajala HLM, Missiry ME, Ruusila A, Koskenvesa P, Brümmendorf TH, Gjertsen BT, et al. Tyrosine kinase inhibitor therapy-induced changes in humoral immunity in patients with chronic myeloid leukemia. *J Cancer Res Clin Oncol* 2017;143(8):1543–54.
- Raoult D. Host factors in the severity of Q fever. *Ann N Y Acad Sci* 1990;590:33–8.
- Schoffelen T, Kampschreur LM, van Roeden SE, Wever PC, den Broeder AA, Nabuurs-Franssen MH, et al. *Coxiella burnetii* *Coxiella burnetii* infection (Q fever) in rheumatoid arthritis patients with and without anti-TNF α therapy. *Ann Rheum Dis* 2014;73(7):1436–8.