



**HAL**  
open science

## Hyperkinetic motor seizures: a common semiology generated by two different cortical seizure origins

Lisa Vaugier, Aileen Mcgonigal, Stanislas Lagarde, Agnès Trébuchon, William Szurhaj, Philippe Derambure, Fabrice Bartolomei

### ► To cite this version:

Lisa Vaugier, Aileen Mcgonigal, Stanislas Lagarde, Agnès Trébuchon, William Szurhaj, et al.. Hyperkinetic motor seizures: a common semiology generated by two different cortical seizure origins. *Epileptic Disorders*, 2018, 19 (3), pp.362 - 368. 10.1684/epd.2017.0932 . hal-01851691

**HAL Id: hal-01851691**

**<https://hal.science/hal-01851691>**

Submitted on 30 Jul 2018

**HAL** is a multi-disciplinary open access archive for the deposit and dissemination of scientific research documents, whether they are published or not. The documents may come from teaching and research institutions in France or abroad, or from public or private research centers.

L'archive ouverte pluridisciplinaire **HAL**, est destinée au dépôt et à la diffusion de documents scientifiques de niveau recherche, publiés ou non, émanant des établissements d'enseignement et de recherche français ou étrangers, des laboratoires publics ou privés.

# Hyperkinetic motor seizures: a common semiology generated by two different cortical seizure origins

Lisa Vaugier<sup>1</sup>, Aileen McGonigal<sup>1,2</sup>, Stanislas Lagarde<sup>1,2</sup>,  
Agnes Trébuchon<sup>1,2</sup>, William Szurhaj<sup>3</sup>, Philippe Derambure<sup>3</sup>,  
Fabrice Bartolomei<sup>1,2</sup>

<sup>1</sup> APHM, Hôpital de la Timone, Service de Neurophysiologie Clinique, Marseille

<sup>2</sup> Aix-Marseille Univ, INSERM U751, Marseille

<sup>3</sup> Université de Lille II, Lille, Nord-Pas-de-Calais, France

Received November 23, 2016; Accepted June 16, 2017

**ABSTRACT** – We report a 37-year-old, right-handed patient with drug-resistant focal epilepsy whose seizures were characterized by explosive hyperkinetic behaviour. Video-SEEG revealed bifocal organization of epilepsy with two distinct cortical origins of seizures: the right temporal pole and left temporal lateral and perisylvian cortex. Irrespective of the cortical pattern of seizure onset, the hyperkinetic semiology was extremely similar. This supports a major role for “final common pathway” subcortical circuits in the genesis of the hyperkinetic semiology in this patient.

**Key words:** focal epilepsy, hyperkinetic / hypermotor semiology, central pattern generator

Seizures involving hyperkinetic (or hypermotor) behaviour are characterized by excessive and sometimes explosive movements (Blume *et al.*, 2001), the pathophysiological basis of which remains poorly understood. While hyperkinetic semiological patterns are diverse, their common feature is excessive motor activity, predominant in axial and proximal structures (Rheims *et al.*, 2008; Bonini *et al.*, 2014). Patients may present with large movements, usually rapid balletic limb movements, which may be of variable directionality and rhythmicity, often associated with axial movements such as trunk torsion or pelvic

thrusting. The excessive motor activity may be associated or not with emotional motor expression such as fear or anger (appearance suggestive of attack or defence), in which case vocalization is a common feature; the apparent emotional context and recognisable pattern of behaviour lends an “integrated” appearance to the motor signs (Bonini *et al.*, 2014). In other semiological patterns, the excess motor activity may appear organised in complex motor sequences, resembling physiological activity such as cycling, walking or boxing (Nobili *et al.*, 2004; Tassinari *et al.*, 2005a; Nobili *et al.*, 2007). Because of their

**Correspondence:**

Lisa Vaugier  
APHM, Hôpital de la Timone,  
Service de neurophysiologie clinique,  
13005 Marseille, France  
<lisa.vaugier@ap-hm.fr>

excessively repetitive nature, such ictal motor patterns can be also characterized as stereotypies (McGonigal *et al.*, 2008). Other seizures with hyperkinetic movements show neither emotional expression nor clearly recognisable physiological-type movement sequences, but rather apparent uncoordinated and disjointed movements, which may be associated with tonic and sometimes dystonic limb and/or facial contraction (Bonini *et al.*, 2014).

Explosive hyperkinetic motor behaviour was first described in the context of orbitofrontal seizures (Tharp, 1972) and was subsequently recognized as a typical component of nocturnal frontal seizures (Rheims *et al.*, 2008; Bonini *et al.*, 2014). However, over the past decade, the concept of a univocal frontal origin has been challenged by several reports showing that other cortical epileptogenic zones (such as the temporal pole and parieto-insular region) may trigger similar hyperkinetic behaviour during seizures (Nobili *et al.*, 2004; Ryvlin *et al.*, 2006; Vaugier *et al.*, 2009). Of course, seizures with semiology characterized by complex motor behaviour tend to involve widely distributed cortical networks, and not only seizure onset but propagation patterns are key to clinical expression (Bartolomei *et al.*, 2013). The hypothesis that predominantly subcortical generators lead to some hyperkinetic behaviours has been postulated, with the idea that loss of higher cortical control during the seizure leads to release of "instinctive motor behaviours" (Tassinari *et al.*, 2005a).

Here, we report a patient with nocturnal hyperkinetic seizures, in whom essentially the same semiological expression was produced by seizure origins from either the right temporal polar cortex or the left perisylvian region. This case adds further evidence to the hypothesis that some forms of hyperkinetic semiology are not directly produced by a specific cortical region but are more dependent upon subcortical organization.

## Case presentation

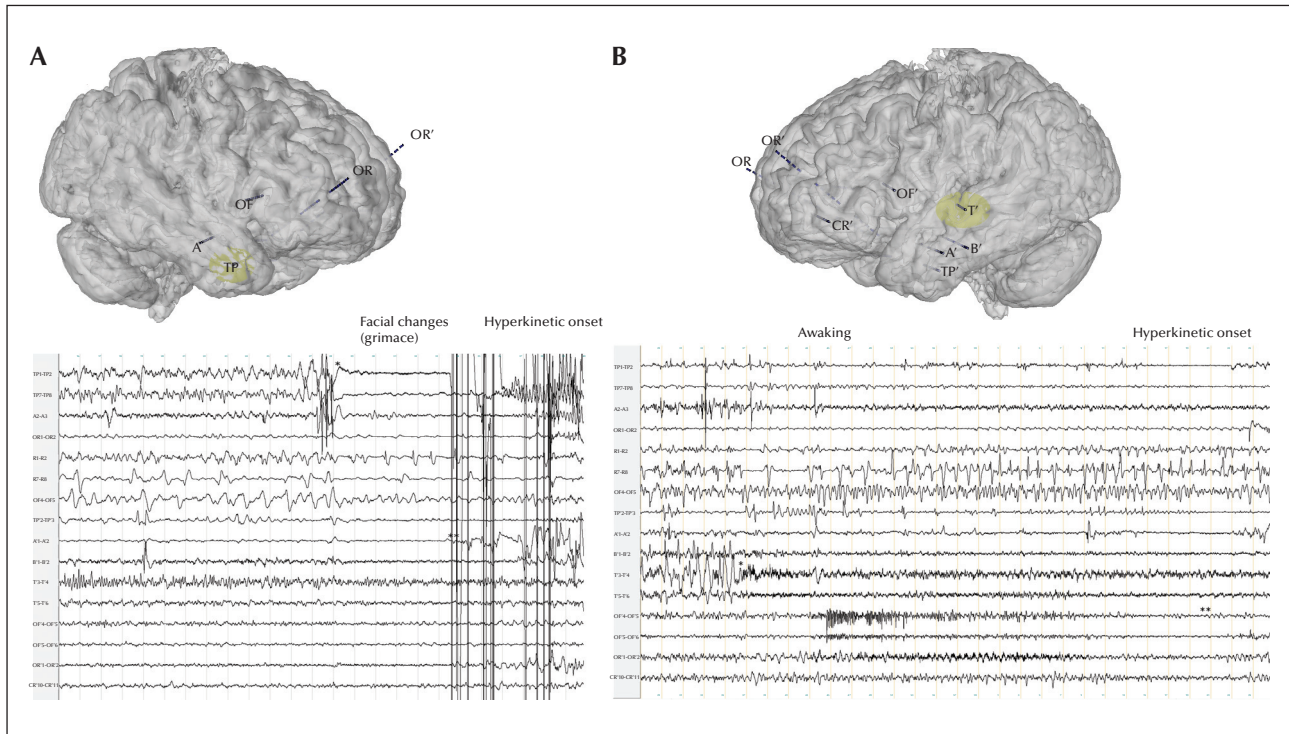
A 37-year-old, right-handed man was admitted for assessment of intractable refractory epilepsy. Birth and psychomotor development were normal. He had complex febrile seizures at 9 months. Seizures started at age 13 years and were mostly nocturnal with hyperkinetic semiology. He was sometimes able to report a subjective experience of a rising unpleasant warm sensation in the body, associated with dyspnoea. He would then present facial grimacing and fairly explosive hyperkinetic motor signs with pedalling, side-to-side semi-rhythmic rocking, rotation of the body, neck extension, and pelvic thrusting. Seizures were resistant to antiepileptic drugs and recurred every night. Long-

term video-EEG showed interictal right anterior spikes and sharp waves. Ictal video-EEG showed semiology as described above, with bilateral flattening on scalp EEG. Cerebral MRI was normal and FDG-PET (positron emission tomography) showed left temporo-polar and left fronto-opercular hypometabolism. Stereoelectroencephalography (SEEG) was indicated with the aim of identifying the epileptogenic zone. SEEG exploration was carried out during long-term video-EEG monitoring. Recordings were performed using intracerebral multiple-contact electrodes (10-15 contacts; length: 2 mm; diameter: 0.8 mm; 1.5 mm apart), placed according to Talairach's stereotactic method, as previously reported (Bartolomei *et al.*, 2008). Signals were recorded on a 128-channel Deltamed TM system. They were sampled at 256 Hz and recorded on a hard disk (16 bits/sample), without a digital filter. The SEEG scheme is indicated in *figure 1*. Two separate epileptogenic zones were identified, associated with very similar hyperkinetic semiological expression (*figure 2*): one with seizure onset in the right temporal pole/orbitofrontal cortex system (*figure 1A*) and the other in the left temporal lateral cortex and opercular region (*figure 1B*). The right temporo-polar seizures were characterized by rapid changes in facial expression (with grimace more pronounced on the right side) and significant hyperkinetic semiology including repetitive rocking and rotation of the body (*figure 2*). The first electrical changes were observed under the form of a rapid discharge affecting the temporal pole, preceded by a polyspike complex (*figure 1A*). No involvement of the cingulate gyrus was observed. The left operculo-insular seizures were sometimes associated with an aura (disgust and throat striction). Ictal symptoms included first swallowing movements and a slightly more delayed hyperkinetic phase. Hyperkinetic movements were very similar (prominent rotational movement and facial contortion) (*figure 2B*). The initial SEEG discharge was observed in the left posterior insular cortex under the form of a rhythmic discharge with beta frequency (*figure 1B*). A delayed involvement of the frontal opercular regions, the anterior insular cortex, and the temporal regions was observed.

The bilateral/multifocal organization of the epilepsy finally led to contraindication for curative surgery.

## Discussion

This case shows that two distinct, independent and bilateral epileptogenic cortical networks may produce almost identical hyperkinetic seizure semiology in the same patient. The specific epileptogenic cortical regions involved in our case (the left operculo-insular and temporal polar-orbitofrontal regions) have



**Figure 1.** SEEG implantation and the two different ictal onsets recorded in the patient. (A) Seizure starts from the right temporal polar cortex by a rapid discharge (\*) before the emergence of clinical semiology. (B) Seizure starting from the left temporal region (firstly from the temporal gyrus) and then the fronto-opercular region. The pattern here is different with changes first appearing at the T' electrodes (\*) and then involving the left orbito-frontal region (OR', \*\*) and the left opercular cortex (OF'). The ictal hyperkinetic sequence is delayed following seizure onset.



**Figure 2.** Sequences of hyperkinetic signs for the two types of seizures (lasting for 30 seconds) with (A) right temporo-polar onset and (B) left temporo-perisylvian onset.

previously been identified as a potential source of hyperkinetic seizures. In particular, temporo-frontal seizures (with preferential involvement of the temporal pole and orbital frontal cortex) (Nobili *et al.*, 2004; Vaugier *et al.*, 2009) have been reported with ictal hyperkinetic motor behaviour. Hyperkinetic motor

behaviour encompasses many diverse semiological presentations which seem likely to have different pathophysiological mechanisms. As such, the heterogeneous category “hyperkinetic seizures” *per se* is not necessarily a useful one when trying to elucidate the brain dynamics involved. For example,

hyperkinetic motor behaviour, including intense emotional expression (screaming, fearful and/or angry facial expression, swearing, or attack behaviour), has been well-described in seizures involving the limbic fronto-temporal system (Bartolomei *et al.*, 2005; Tassinari *et al.*, 2005b; Bonini *et al.*, 2014). In this context, emergence of explosive motor behaviour has been related to decoupling between the orbito-frontal cortex and the amygdala (key structures within the emotional limbic system), directly produced by altered network dynamics due to cortical seizure activity, which is postulated to produce dysregulation of cortical emotional control (Bartolomei *et al.*, 2005). The repetitive nature of some hyperkinetic behaviour (such as rhythmic body rocking) suggests the possibility of a similar mechanism to that involved in the production of motor stereotypies which may occur in other clinical conditions, involving cortical-striatal circuits (Edwards *et al.*, 2012). In the context of epilepsy, recognisable motor patterns, especially locomotor behaviour but also grooming or eating behaviour, have been interpreted to be related to the release of primitive, stereotyped motor behaviours, depending on central pattern generators, which can also be observed in some sleep disorders (Tassinari *et al.*, 2005a). However, possible mechanisms and the circuitry involved remain unknown, mainly because electrophysiological investigation of such epilepsy cases predominantly involves only the cortical components of the likely involved cortico-subcortical circuits, based on clinical indication. It is probable that cortico-subcortical interactions, depending on the precise localization and electrophysiological pattern of cortical seizure activity, can influence clinical expression. There is some evidence for the latter in terms of patterns of motor stereotypies in frontal seizures, which seem to be organized along a rostro-caudal cortical axis (McGonigal and Chauvel, 2014). While intracranial EEG offers relatively limited possibilities for better understanding the role of subcortical structures, functional imaging may provide some clues, although ictal recordings are rare. In an interictal PET study, significant hypometabolism was observed in the caudate head and midbrain in patients showing ictal hyperkinetic behaviour, compared to those without (Guedj *et al.*, 2012). In another study, Masuda and co-workers have used ictal SPECT and voxel-based analysis to identify the neuronal networks generating specific ictal symptomatology in patients with hyperkinetic seizures. They showed that both cortical and subcortical regions are involved during these kinds of seizures. In particular, the mesencephalic locomotor nucleus could be the most likely relay to trigger access to spinal central pattern generators responsible for the hyperkinetic movements (Masuda *et al.*, 2012).

Our case adds further indirect evidence for the crucial role of subcortical organization of some forms of hyperkinetic motor behaviour. While subcortical circuits necessarily play an important part of any semiological expression, it may be that some semiological patterns are more “cortical-dependent” whereas others are more “subcortical-dependent”. The present observation is indeed in favour of this hypothesis; since essentially identical hyperkinetic behaviour could emerge from seizure onset in two distinct and bilaterally independent cortical networks, it seems likely that this was expressed via a “final common pathway”, organized within basal ganglia and brainstem structures. □

#### Disclosures.

The authors have no conflict of interest to disclose.

#### References

- Bartolomei F, Trebuchon A, Gavaret M, Regis J, Wendling F, Chauvel P. Acute alteration of emotional behaviour in epileptic seizures is related to transient desynchrony in emotion-regulation networks. *Clin Neurophysiol* 2005;116: 2473-9.
- Bartolomei F, Chauvel P, Wendling F. Epileptogenicity of brain structures in human temporal lobe epilepsy: a quantified study from intracerebral EEG. *Brain* 2008;131: 1818-30.
- Bartolomei F, Guye M, Wendling F. Abnormal binding and disruption in large scale networks involved in human partial seizures. *EPJ Nonlinear Biomed Phys* 2013;1.
- Blume WT, Luders HO, Mizrahi E, Tassinari C, van Emde Boas W, Engel J Jr. Glossary of descriptive terminology for ictal semiology: report of the ILAE task force on classification and terminology. *Epilepsia* 2001;42:1212-8.
- Bonini F, McGonigal A, Trebuchon A, *et al.* Frontal lobe seizures: from clinical semiology to localization. *Epilepsia* 2014;55:264-77.
- Edwards MJ, Lang AE, Bhatia KP. Stereotypies: a critical appraisal and suggestion of a clinically useful definition. *Mov Disord* 2012;27:179-85.
- Guedj E, McGonigal A, Vaugier L, Mundler O, Bartolomei F. Metabolic brain PET pattern underlying hyperkinetic seizures. *Epilepsy Res* 2012;101:237-45.
- Masuda H, Shariff E, Tohyama J, Murakami H, Kameyama S. Clinical patterns and pathophysiology of hypermotor seizures: an ictal SPECT study. *Epileptic Disord* 2012;14:32-40.
- McGonigal A, Chauvel P. Prefrontal seizures manifesting as motor stereotypies. *Mov Disord* 2014;29:1181-5.
- McGonigal A, Gavaret M, Da Fonseca AT, *et al.* MRI-negative prefrontal epilepsy due to cortical dysplasia explored by stereoelectroencephalography (SEEG). *Epileptic Disord* 2008;10:330-8.

Nobili L, Cossu M, Mai R, et al. Sleep-related hyperkinetic seizures of temporal lobe origin. *Neurology* 2004;62: 482-5.

Nobili L, Francione S, Mai R, et al. Surgical treatment of drug-resistant nocturnal frontal lobe epilepsy. *Brain* 2007;130:561-73.

Rheims S, Ryvlin P, Scherer C, et al. Analysis of clinical patterns and underlying epileptogenic zones of hypermotor seizures. *Epilepsia* 2008;49(12): 2030-40.

Ryvlin P, Minotti L, Demarquay G, et al. Nocturnal hypermotor seizures, suggesting frontal lobe epilepsy, can originate in the insula. *Epilepsia* 2006;47: 755-65.

Tassinari CA, Rubboli G, Gardella E, et al. Central pattern generators for a common semiology in fronto-limbic seizures and in parasomnias. A neuroethologic approach. *Neurol Sci* 2005a;26(3): s225-32.

Tassinari CA, Tassi L, Calandra-Buonaura G, et al. Biting behavior, aggression, and seizures. *Epilepsia* 2005b;46: 654-63.

Tharp BR. Orbital frontal seizures. An unique electroencephalographic and clinical syndrome. *Epilepsia* 1972;13: 627-42.

Vaugier L, Aubert S, McGonigal A, et al. Neural networks underlying hyperkinetic seizures of "temporal lobe" origin. *Epilepsy Res* 2009;86: 200-8.