



HAL
open science

Angiostrongylus cantonensis Infection of Central Nervous System, Guiana Shield

Antoine Defo, Noémie Lachaume, Emma Cuadro-Alvarez, Chimène Maniassom, Elise Martin, Falucar Njuieyon, Fanny Henaff, Yajaira Mrsic, Annabelle Brunelin, Loïc Epelboin, et al.

► **To cite this version:**

Antoine Defo, Noémie Lachaume, Emma Cuadro-Alvarez, Chimène Maniassom, Elise Martin, et al.. Angiostrongylus cantonensis Infection of Central Nervous System, Guiana Shield. *Emerging Infectious Diseases*, 2018, 24 (6), pp.1153-1155. 10.3201/eid2406.180168 . hal-01844487

HAL Id: hal-01844487

<https://hal.science/hal-01844487>

Submitted on 19 Jul 2018

HAL is a multi-disciplinary open access archive for the deposit and dissemination of scientific research documents, whether they are published or not. The documents may come from teaching and research institutions in France or abroad, or from public or private research centers.

L'archive ouverte pluridisciplinaire **HAL**, est destinée au dépôt et à la diffusion de documents scientifiques de niveau recherche, publiés ou non, émanant des établissements d'enseignement et de recherche français ou étrangers, des laboratoires publics ou privés.

prevalence and a semi-quantitative assessment of the relative risks to cattle. *Vet J*. 2007;173:287–301. PubMed <http://dx.doi.org/10.1016/j.tvjl.2005.11.011>

3. Payne A. Role of wildlife in the *Mycobacterium bovis* multi-host system and risk of transmission between wildlife and cattle: experimental study in Côte d'Or: Université Claude Bernard—Lyon I; 2014 [cited 2014 Mar 3]. <https://tel.archives-ouvertes.fr/tel-01081144/document>
4. Millán J, Jiménez MA, Viota M, Candela MG, Peña L, León-Vizcaino L. Disseminated bovine tuberculosis in a wild red fox (*Vulpes vulpes*) in southern Spain. *J Wildl Dis*. 2008;44:701–6. PubMed <http://dx.doi.org/10.7589/0090-3558-44.3.701>
5. Matos AC, Figueira L, Martins MH, Pinto ML, Matos M, Coelho AC. New insights into *Mycobacterium bovis* prevalence in wild mammals in Portugal. *Transbound Emerg Dis*. 2016;63:e313–22. PubMed <http://dx.doi.org/10.1111/tbed.12306>
6. Lambert S, Hars J, Réveillaud E, Moyen JL, Gares H, Rambaud T, et al. Host status of wild roe deer in bovine tuberculosis endemic areas. *Eur J Wildl Res*. 2017;63:15. <http://dx.doi.org/10.1007/s10344-016-1071-4>
7. King HC, Murphy A, James P, Travis E, Porter D, Hung YJ, et al. The variability and seasonality of the environmental reservoir of *Mycobacterium bovis* shed by wild European badgers. *Sci Rep*. 2015;5:12318. PubMed <http://dx.doi.org/10.1038/srep12318>
8. Gallagher J, Clifton-Hadley RS. Tuberculosis in badgers; a review of the disease and its significance for other animals. *Res Vet Sci*. 2000;69:203–17. PubMed <http://dx.doi.org/10.1053/rvsc.2000.0422>
9. Delahay RJ, Langton S, Smith GC, Clifton-Hadley RS, Cheeseman CL. The spatio-temporal distribution of *Mycobacterium bovis* (bovine tuberculosis) infection in a high-density badger population. *J Anim Ecol*. 2000;69:428–41. <http://dx.doi.org/10.1046/j.1365-2656.2000.00406.x>
10. Gallagher J. The role of other animals in the epidemiology of tuberculosis in the badger. In: Zuckerman L, editor. *Badgers, cattle and tuberculosis*. London: Her Majesty's Stationery Office; 1980. p. 86–98.

Address for correspondence: María Laura Boschioli, ANSES—Animal Health Laboratory, 14 rue Pierre et Marie Curie, 94701 Maisons-Alfort, CEDEX, France; email: maria-laura.boschioli@anses.fr

EMERGING INFECTIOUS DISEASES®

Conference
summaries
and other reports
available online

[https://wwwnc.cdc.gov/eid/articles/
conference-summaries/volume-23](https://wwwnc.cdc.gov/eid/articles/conference-summaries/volume-23)

Angiostrongylus cantonensis Infection of Central Nervous System, Guiana Shield

Antoine L. Defo, Noémie Lachaume,
Emma Cuadro-Alvarez, Chimène Maniassom,
Elise Martin, Falucar Njuieyon, Fanny Henaff,
Yajaira Mrcic, Annabelle Brunelin, Loic Epelboin,
Denis Blanchet, Dorothée Harrois,
Nicole Desbois-Nogard, Yvonne Qvarnstrom,
Magalie Demar, Céline Dard, Narcisse Elenga

Author affiliations: Andrée Rosemon Hospital, Cayenne, French Guiana (A.L. Defo, N. Lachaume, E. Cuadro-Alvarez, C. Maniassom, E. Martin, F. Njuieyon, F. Henaff, Y. Mrcic, A. Brunelin, L. Epelboin, D. Blanchet, M. Demar, N. Elenga); Université de Guyane, Cayenne (L. Epelboin, D. Blanchet, M. Demar, N. Elenga); Basse-Terre Hospital, Guadeloupe, French West Indies (D. Harrois); University Hospital of Martinique, Fort-de-France, Martinique (N. Desbois-Nogard); Centers for Disease Control and Prevention, Atlanta, Georgia, USA (Y. Qvarnstrom); University Hospital of Grenoble-Alpes, Grenoble, France (C. Dard)

DOI: <https://doi.org/10.3201/eid2406.180168>

We report a case of eosinophilic meningitis complicated by transverse myelitis caused by *Angiostrongylus cantonensis* in a 10-year-old boy from Brazil who had traveled to Suriname. We confirmed diagnosis by serology and real-time PCR in the cerebrospinal fluid. The medical community should be aware of angiostrongyliasis in the Guiana Shield.

In September 2017, a previously healthy 10-year-old boy from Brazil came to the emergency department of Andrée Rosemon Hospital in Cayenne, French Guiana, a French territory that forms the Guiana Shield together with Guyana (formerly British Guiana), Suriname, and the Brazil state of Amapá. He related a 4-day history of helmet headache, repeated vomiting, and hyperthermia (38.5°C). The patient had lived in Saint-Laurent-du-Maroni, a city on the French Guiana border with Suriname, for 5 years and had recently returned from a 3-day trip in Suriname. He had no memory of ingesting slugs, snails, or uncooked vegetables, but he reported playing with snails during the rainy season (April–August).

At admission to the pediatric department, he was afebrile with a good state of consciousness (Glasgow coma score 15). Our physical examination revealed a stiff neck, with positive Kernig and Brudzinski signs but no focal deficits. Hematology revealed a leukocyte count of 12.30×10^9 cells/L (reference range $4\text{--}14.5 \times 10^9$ cells/L) with 5.49×10^9 eosinophils/L (reference range $0.05\text{--}0.85 \times 10^9$

eosinophils/L). C-reactive protein was <3 mg/L; liver and renal function tests were normal. Computed tomography of the head showed unremarkable results. We performed a lumbar puncture; cerebrospinal fluid (CSF) analysis revealed 8.7×10^6 leukocytes/L (30% neutrophils and 70% lymphocytes), protein 0.43 g/L, glucose 4.2 mmol/L, and lactates 2.2 mmol/L. Gram stain result was negative for bacteria. Results of India ink test and microscopic examination of CSF were negative for *Cryptococcus* spp. We saw no helminth larvae in the CSF. Serologic test results for *Treponema pallidum*, *Borrelia burgdorferi*, *Leptospira* spp., *Mycoplasma pneumoniae*, *Chlamydia pneumoniae*, *Brucella* spp., herpes simplex virus, and HIV were all negative. Microscopic examinations of 3 fecal specimens using the concentration method and Baermann technique showed negative results. We began empiric treatment with intravenous cefotaxime (300 mg/kg/d).

On day 6 of hospitalization, paraparesis of the lower limbs (more marked on the left) and dysuria appeared; meningeal syndrome persisted. A cerebromedullary magnetic resonance imaging (MRI) scan revealed myelitis lesions through a marrow signal abnormality ranging from T2 to T10 and a discrete signal enhancement after gadolinium injection (Figure, panel A). Electroencephalography results were unremarkable. We performed a second lumbar puncture on day 7; CSF showed 5.5×10^6 leukocytes/L with 92% eosinophils, protein 0.42 g/L, glucose 2.80 g/L, and lactates 2.7 mmol/L. Results of CSF bacterial cultures and PCRs for herpes simplex virus and enterovirus were negative. Serologic testing by Western blot was negative for *Gnathostoma* spp. nematodes but

positive for *Angiostrongylus* spp. roundworms by detection of the specific 31-kDa antigenic band (1). Diagnosis of angiostrongyliasis was confirmed by *A. cantonensis* DNA detection in the CSF by real-time PCR performed by the US Centers for Disease Control and Prevention (Atlanta, GA, USA) (2).

We treated the patient with oral ivermectin (200 μ g/kg/d for 10 days) in combination with intravenous methylprednisolone (30 mg/kg/d for 5 days), followed by oral prednisolone (2 mg/kg/d), which was gradually discontinued over 1 month. The patient's condition improved noticeably, with progressive disappearance of headaches, dysuria, and paraparesis in the following weeks. A cerebromedullary MRI performed on day 38 after admission showed almost complete recovery from the anomalies detected previously and did not report new anomalies (Figure, panel B). Three months after the onset of the disease, the patient had recovered completely without any sequelae.

Our findings demonstrate the presence of *A. cantonensis* roundworms in the Guiana Shield, in the context of a recent emergence of angiostrongyliasis in Brazil (3), the Caribbean region (including other French territories of the Americas) (4,5), and the southern United States (6,7). The frequency of *A. cantonensis* infections in humans in the Guiana Shield is probably underestimated as a result of the spontaneous course of recovery for most cases (8), lack of knowledge of the parasite by health professionals, limited availability of laboratory diagnostic tools, and the absence of national surveillance. Although the disease usually resolves spontaneously, case-fatality rates can reach 5% (9). The lack of clinical suspicion for angiostrongyliasis

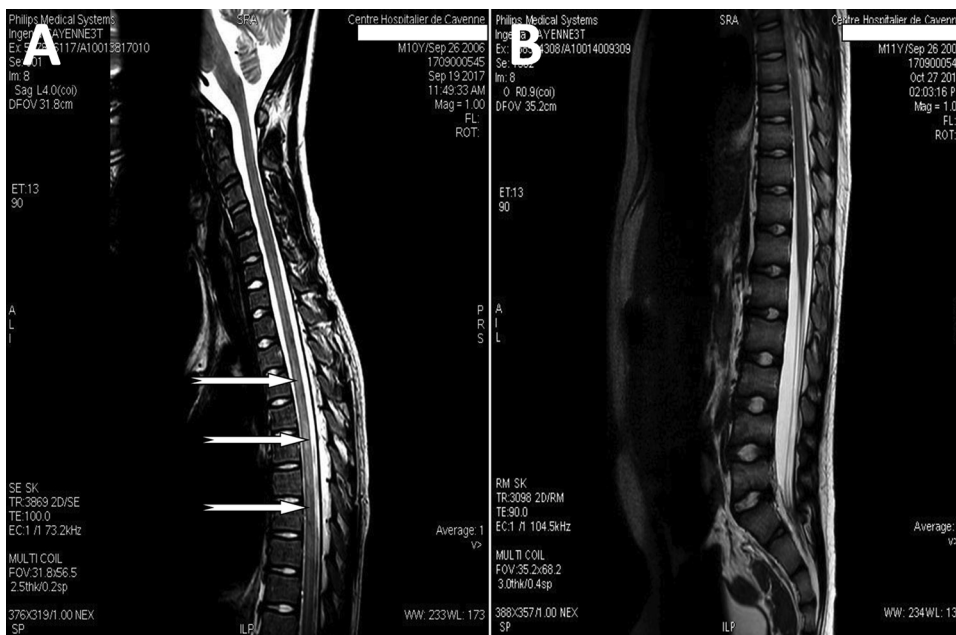


Figure. Magnetic resonance imaging (MRI) of the spine in a 10-year-old boy from Brazil with *Angiostrongylus cantonensis* infection. A) MRI before treatment showing myelitis; sagittal T1 postcontrast sequences show intramedullary enhancement in the thoracic spinal cord T2–T10 with diffuse leptomeningeal enhancement (arrows). B) Normal MRI 1 month after treatment.

on the basis of signs and symptoms and delay in initiation of treatment may lead to adverse neurologic outcomes, especially in young children (10). Because the patient in this study had traveled to Suriname shortly before symptom onset, the country of origin of the infection could not be determined. The likely route of transmission was contact with a contaminated mollusk, such as the giant African snail *Achatina fulica fulica*, which is a new and invasive species in Latin America and a known vector for *A. cantonensis* roundworms. Our case illustrates the necessity for healthcare providers to consider angiostrongyliasis in cases of eosinophilic meningitis in the Guiana Shield, especially in young children.

Acknowledgments

The authors are thankful for the support of D. Jeanbourquin of the department of radiology at Andrée Rosemon Hospital, Cayenne, French Guiana, for help in interpreting MRI radiographies.

The authors have obtained a written consent to publish from the child's parents.

About the Author

Dr. Defo is a neurologic pediatrician at Centre Hospitalier Andrée Rosemon in Cayenne, French Guiana. His research interests include epilepsy and pediatric tropical infectious diseases.

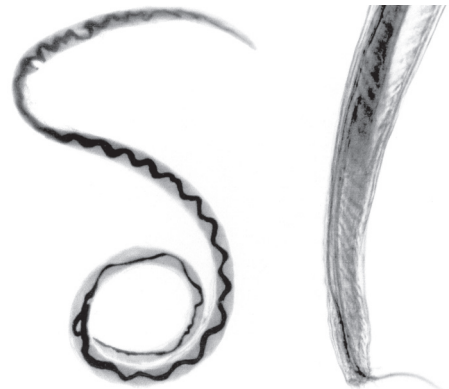etymologia

Angiostrongylus [an"je-o-stron'jĩ-ləs]

Ronnie Henry

From the Greek *angeion* (“vessel”) + *strongylos* (“round”), *Angiostrongylus* is a genus of parasitic nematodes (roundworms) in the family *Angiostrongylidae*, 2 species of which are known to parasitize humans. *A. cantonensis* (commonly known as rat lungworm) was first described in 1935 (as *Pulmonema cantonensis*) from rats in Canton, China. It is the most common cause of eosinophilic meningitis in Asia and the Pacific Basin, but cases have been reported in many parts of the world. *A. costaricensis* roundworms were first described in 1971 in Costa Rica from surgical specimens from children with eosinophilic infiltration in the abdominal cavity. The distribution of this species ranges from the southern United States to northern Argentina.

There is still debate about what taxonomic name should be used. *A. cantonensis* remains in general use, but some researchers suggest it should be changed to *Parastrongylus cantonensis* on the basis of the morphology of the adult male bursa and the definitive host being rats.



Adult *Angiostrongylus cantonensis* nematode recovered from rat lung. Image from *Enzootic Angiostrongylus cantonensis* in Rats and Snails after an Outbreak of Human Eosinophilic Meningitis, Jamaica, John F. Lindo et al, *Emerging Infectious Diseases*, Vol. 8, No. 3, March 2002.

Sources

1. Chen HT. A new pulmonary nematode, *Pulmonema cantonensis*, n.g., n.sp. in Canton rats [in French]. *Ann Parasitol.* 1935;13:312–7. <http://dx.doi.org/10.1051/parasite/1935134312>
2. Cowie RH. Biology, systematics, life cycle, and distribution of *Angiostrongylus cantonensis*, the cause of rat lungworm disease. *Hawaii J Med Public Health.* 2013;72(Suppl 2):6–9.
3. Morera P, Céspedes R. *Angiostrongylus costaricensis* n. sp. (Nematoda: Metastrongyloidea), a new lungworm occurring in man in Costa Rica. *Rev Biol Trop.* 1970;18:173–85.
4. Simner PJ. Medical parasitology taxonomy update: January 2012 to December 2015. *J Clin Microbiol.* 2017;55:43–7. <http://dx.doi.org/10.1128/JCM.01020-16>
5. Ubelaker JE. Systematics of species referred to the genus *Angiostrongylus*. *J Parasitol.* 1986;72:237–44. <http://dx.doi.org/10.2307/3281599>

Address for correspondence: Ronnie Henry, Centers for Disease Control and Prevention, 1600 Clifton Rd NE, Mailstop E03, Atlanta, GA 30329-4027, USA; email: boq3@cdc.gov

DOI: <https://doi.org/10.3201/eid2406.ET2406>

References

1. Nuamtanong S. The evaluation of the 29 and 31 kDa antigens in female *Angiostrongylus cantonensis* for serodiagnosis of human angiostrongyliasis. *Southeast Asian J Trop Med Public Health*. 1996;27:291–6.
2. Qvarnstrom Y, Xayavong M, da Silva AC, Park SY, Whelen AC, Calimlim PS, et al. Real-time polymerase chain reaction detection of *Angiostrongylus cantonensis* DNA in cerebrospinal fluid from patients with eosinophilic meningitis. *Am J Trop Med Hyg*. 2016;94:176–81. <http://dx.doi.org/10.4269/ajtmh.15-0146>
3. Morassutti AL, Thiengo SC, Fernandez M, Sawanyawisuth K, Graeff-Teixeira C. Eosinophilic meningitis caused by *Angiostrongylus cantonensis*: an emergent disease in Brazil. *Mem Inst Oswaldo Cruz*. 2014;109:399–407. <http://dx.doi.org/10.1590/0074-0276140023>
4. Slom TJ, Cortese MM, Gerber SI, Jones RC, Holtz TH, Lopez AS, et al. An outbreak of eosinophilic meningitis caused by *Angiostrongylus cantonensis* in travelers returning from the Caribbean. *N Engl J Med*. 2002;346:668–75. <http://dx.doi.org/10.1056/NEJMoa012462>
5. Dard C, Piloquet JE, Qvarnstrom Y, Fox LM, M'kanda H, Hebert JC, et al. First evidence of angiostrongyliasis caused by *Angiostrongylus cantonensis* in Guadeloupe, Lesser Antilles. *Am J Trop Med Hyg*. 2017;96:692–7.
6. Al Hammoud R, Nayas SL, Murphy JR, Heresi GP, Butler JJ, Pérez N. *Angiostrongylus cantonensis* meningitis and myelitis, Texas, USA. *Emerg Infect Dis*. 2017;23:1037–8. <http://dx.doi.org/10.3201/eid2306.161683>
7. Foster CE, Nicholson EG, Chun AC, Gharfeh M, Anvari S, Seeborg FO, et al. *Angiostrongylus cantonensis* infection: a cause of fever of unknown origin in pediatric patients. *Clin Infect Dis*. 2016;63:1475–8. <http://dx.doi.org/10.1093/cid/ciw606>
8. Hochberg NS, Park SY, Blackburn BG, Sejvar JJ, Gaynor K, Chung H, et al. Distribution of eosinophilic meningitis cases attributable to *Angiostrongylus cantonensis*, Hawaii. *Emerg Infect Dis*. 2007;13:1675–80. <http://dx.doi.org/10.3201/eid1311.070367>
9. Epelboin L, Blondé R, Chamouine A, Chrisment A, Diancourt L, Villemant N, et al. *Angiostrongylus cantonensis* infection on Mayotte Island, Indian Ocean, 2007–2012. *PLoS Negl Trop Dis*. 2016;10:e0004635. <http://dx.doi.org/10.1371/journal.pntd.0004635>
10. Murphy GS, Johnson S. Clinical aspects of eosinophilic meningitis and meningoencephalitis caused by *Angiostrongylus cantonensis*, the rat lungworm. *Hawaii J Med Public Health*. 2013;72 (Suppl 2):35–40.

Address for correspondence: Antoine L. Defo, Andrée Rosemon Hospital, Pediatric Department, Rue des flamboyants, BP 6006, 97306 Cayenne CEDEX, French Guiana; email: antoine.defo@ch-cayenne.fr

Letters

Letters commenting on recent articles as well as letters reporting cases, outbreaks, or original research are welcome. Letters commenting on articles should contain no more than 300 words and 5 references; they are more likely to be published if submitted within 4 weeks of the original article's publication. Letters reporting cases, outbreaks, or original research should contain no more than 800 words and 10 references. They may have 1 Figure or Table and should not be divided into sections. All letters should contain material not previously published and include a word count.

Molecular Diagnosis of *Taenia saginata* Tapeworm Infection in 2 Schoolchildren, Myanmar

Eun Jeong Won, Bong-Kwang Jung, Hyemi Song, Mi-Seon Kim, Hyun-Seung Kim, Keon Hoon Lee, Min-Jae Kim, Myung Geun Shin, Jong Hee Shin, Soon-Pal Suh, Sung-Jong Hong, Woon-Mok Sohn, Thi Thi Htoon, Htay Htay Tin, Jong-Yil Chai

Author affiliations: Chonnam National University Medical School, Gwangju, South Korea (E.J. Won, M.G. Shin, J.H. Shin, S.-P. Suh); Korea Association of Health Promotion, Seoul, South Korea (B.-K. Jung, H. Song, M.-S. Kim, H.-S. Kim, K.-H. Lee, J.-Y. Chai); Asan Medical Center, Seoul (M.-J. Kim); Chung-Ang University College of Medicine, Seoul (S.-J. Hong); Gyeongsang National University School of Medicine, Jinju, South Korea (W.-M. Sohn); National Health Laboratory, Yangon, Myanmar (T.T. Htoon, H.H. Tin)

DOI: <https://doi.org/10.3201/eid2406.180217>

Taenia saginata is the most common human tapeworm worldwide but has been unknown in Myanmar. In 2017, fecal examination in Yangon, Myanmar, revealed eggs of *Taenia* species in 2 children from a monastic school. Several proglottids expelled after medication with praziquantel were morphologically and molecularly confirmed to be *T. saginata* tapeworms.

Human taeniasis is a parasitic infection caused by tapeworm species including *Taenia saginata*, *T. solium*, and *T. asiatica* (1). *T. saginata* tapeworm infection is acquired through ingestion of raw or undercooked beef; pork is the infection source for *T. solium* and *T. asiatica* tapeworms (1). Because of differences in the life cycle, geographic distribution of these parasites can be affected by regional lifestyle, including dietary habit. Little is known about taeniasis in Myanmar. We report 2 cases of taeniasis caused by *T. saginata* tapeworms in Myanmar.

In June 2017, the Korea Association of Health Promotion, in cooperation with the National Health Laboratory, Myanmar, conducted a survey of intestinal parasitic infections near the Yangon region of Myanmar. The Institutional Review Board of the Ministry of Health and Sports, Myanmar (Ethical Review Committee no. 005117) approved the study. A total of 467 fecal samples were obtained from school-age children living in the district of Shwe Pyi Thar, Myanmar. In fecal examination using the Kato-Katz thick-smear technique, we found the eggs of *Taenia* tapeworms in 2 brothers, 8 and 10 years of age (Figure, panel A). They had never traveled out of Myanmar,