



HAL
open science

Lateral reinforcement in anterior cruciate ligament reconstruction

Timothy D. Lording, Sebastien Lustig, Elvire Servien, Philippe Neyret

► **To cite this version:**

Timothy D. Lording, Sebastien Lustig, Elvire Servien, Philippe Neyret. Lateral reinforcement in anterior cruciate ligament reconstruction. *Asia-Pacific Journal of Sports Medicine, Arthroscopy, Rehabilitation and Technology*, 2014, 1 (1), pp. 3-10. <10.1016/j.asmart.2013.12.002>. <hal-01827783>

HAL Id: hal-01827783

<https://hal.science/hal-01827783v1>


Submitted on 2 Jul 2018

HAL is a multi-disciplinary open access archive for the deposit and dissemination of scientific research documents, whether they are published or not. The documents may come from teaching and research institutions in France or abroad, or from public or private research centers.

L'archive ouverte pluridisciplinaire **HAL**, est destinée au dépôt et à la diffusion de documents scientifiques de niveau recherche, publiés ou non, émanant des établissements d'enseignement et de recherche français ou étrangers, des laboratoires publics ou privés.



HAL Authorization



Review article

Lateral reinforcement in anterior cruciate ligament reconstruction

Timothy D. Lording^{a,b,*}, Sébastien Lustig^b, Elvire Servien^b, Philippe Neyret^b

^a Frankston Hospital, Hastings Road, Frankston, VIC 3199, Australia

^b Albert Trillat Center, Lyon North University Hospital, 103 Grande rue de La Croix Rousse, 69004 Lyon, France

Received 18 October 2013; accepted 25 November 2013

Available online 24 January 2014

Abstract

Lateral extra-articular procedures were popular in the treatment of anterior cruciate ligament injury in the nineteen seventies and eighties, but fell from favor due to poor results, concerns regarding biomechanics, and concurrent advances in intra-articular reconstruction. Persistent problems with rotational control in modern reconstructive techniques have led to a resurgence of interest in the concept of lateral reinforcement. In this article, we examine the history of lateral extra-articular procedures, the reasons for renewed interest in the technique, recent research that lends support to lateral procedures and possible indications for selective use.

Copyright © 2014, Asia Pacific Knee, Arthroscopy and Sports Medicine Society. Published by Elsevier (Singapore) Pte Ltd. This is an open access article under the CC BY-NC-ND license (<http://creativecommons.org/licenses/by-nc-nd/4.0/>).

Keywords: Anterior cruciate ligament; Anterior cruciate ligament reconstruction; Anterolateral ligament

Introduction

Anterior cruciate ligament (ACL) injury is common, with a reported incidence as high as 80/100,000 per year.¹ Surgical treatment aims to restore knee stability and allow return to activity, as well as to prevent secondary injury² and the development of osteoarthritis (OA). Modern reconstruction techniques have achieved good results for the majority of patients, however, there remains a group for whom rotational instability remains an issue.³

Lateral extra-articular reconstruction procedures were devised to address anterolateral rotational laxity. Widely used during the nineteen seventies and eighties, they were largely abandoned due to concerns regarding poor biomechanics, and the superior results of intra-articular techniques.

Today, the addition of lateral extra-articular reinforcement to intra-articular reconstruction has again been proposed as one possible solution to failure in ACL reconstruction. This raises the important question: have previous concerns with this procedure been adequately addressed?

The rationale for early lateral extra-articular procedures

ACL injury generally produces both translational and rotational abnormalities. Early attempts at surgical intervention, both intra- and extra-articular, attempted to address only anterior tibial translation.⁴ In 1979, Slocum and Larson, recognizing the importance of rotational instability in the ACL deficient knee, introduced the concept of rotational laxity, and described a “rotational stability test”.⁵ Their work focused on anteromedial rotation associated with medial sided injury, and they went on to develop a pes anserinus transfer to hold the tibia in internal rotation.⁶

Evidence for damage to the lateral structures of the knee in ACL injury was described as early as 1879. Prior to the invention of radiographs, Ségond described an avulsion fracture of the proximal tibia during cadaveric experiments to reproduce ACL injury.⁷ He hypothesised that this avulsion, from just posterior to the iliotibial tract insertion, was the insertion site of the middle third of the lateral capsular ligament. Norwood published on the incidence of ligamentous injuries associated with acute anterolateral rotatory instability.⁸ In 36 knees, he found only four with isolated ACL injury, 26 with ACL and additional lateral injury (to the lateral capsular

* Corresponding author. Frankston Hospital, Hastings Road, Frankston, VIC 3199, Australia. Tel.: +61 33788318331.

E-mail address: tlording@iinet.net.au (T.D. Lording).

ligament, the iliotibial tract or both) and six knees with lateral capsular ligament injury alone.

Lateral extra-articular procedures were promoted as having a biomechanical advantage over intra-articular reconstruction in terms of rotational control. This was due to the longer lever arm of a laterally based reconstruction to resist torque. Ellison described the ACL as, “the hub of the wheel”, and noted, “it is easier to control rotation of a wheel at its rim than at its hub”.⁹

Early extra-articular procedures

Early extra-articular procedures were performed as isolated operations and in combination with intra-articular procedures and generally used iliotibial band as graft material. The most common procedures were the Lemaire, Ellison and Macintosh procedures.

Lemaire procedure

Described in 1967, the Lemaire procedure involved harvesting an 18 cm × 1 cm strip of iliotibial band.¹⁰ Left attached distally at Gerdy’s tubercle, the strip was then routed under the lateral collateral ligament (LCL) before passing

through a bone tunnel proximal to its insertion. The graft was again passed under the LCL before being secured in a second bony tunnel at Gerdy’s tubercle.

Ellison procedure

Ellison described his iliotibial band transfer operation in 1979.¹¹ In this procedure, the iliotibial band was elevated from Gerdy’s tubercle with a button of bone. The iliotibial band was then routed under the proximal section of the LCL before being secured just anterior to Gerdy’s tubercle with a staple (Fig. 1A). Of note in Ellison’s original description is plication of the mid-third capsular ligament.

MacIntosh procedure

The original MacIntosh procedure, described in 1980, was termed the “lateral substitution reconstruction” and used a 20 cm long strip of iliotibial band left attached at Gerdy’s tubercle.¹² Similar to the Lemaire procedure, the graft was passed under the LCL. Rather than using bone tunnels, however, the graft was passed through a subperiosteal tunnel behind the origin of the LCL and looped behind the insertion

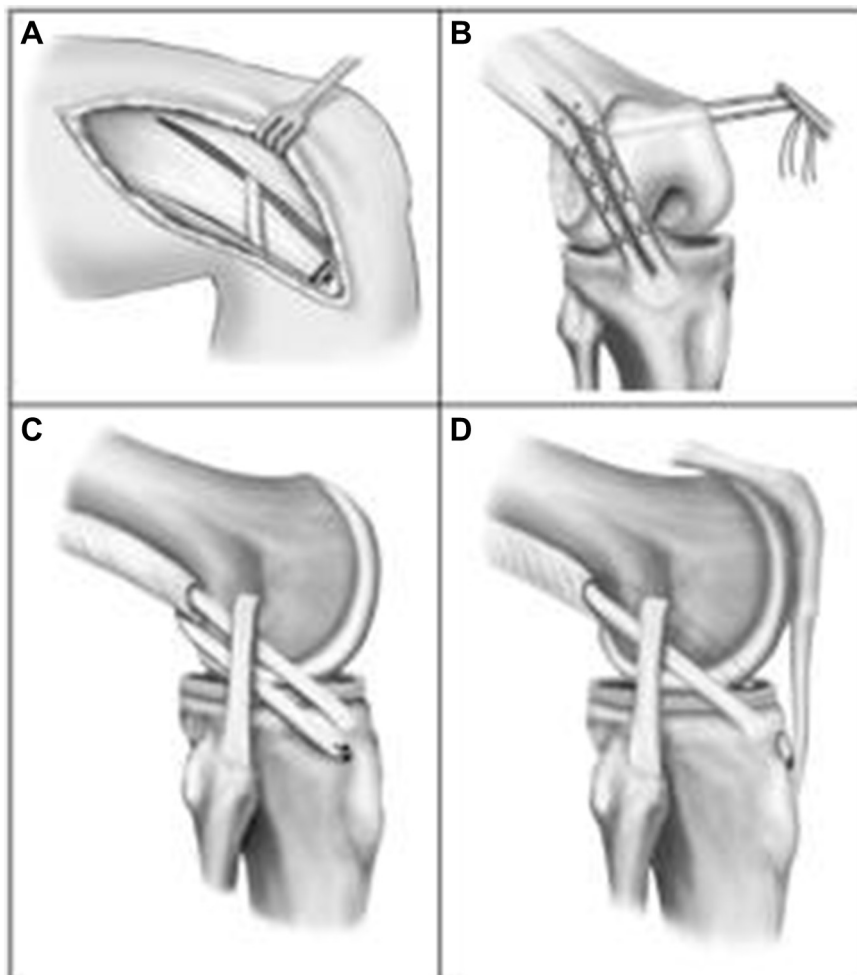


Fig. 1. Early extra-articular techniques. (A) Ellison procedure. (B) Andrews mini-reconstruction. (C) MacIntosh 1. (D) MacIntosh 2 “over-the-top”. Reproduced with permission from McCulloch PC, Lattermann C, Boland AL, Bach BR Jr. An illustrated history of anterior cruciate ligament surgery. *J Knee Surg.* 2007;20:95–104.

of the lateral intermuscular septum, before passing again under the lateral collateral ligament (Fig. 1C).

MacIntosh also described a combined intra- and extra-articular procedure. In this case, after passage deep to the LCL, the iliotibial band graft was passed over-the-top behind the lateral femoral condyle, into the joint and secured in a tibial bone tunnel (Fig. 1D).

Andrews procedure

Andrews published his “mini-reconstruction” technique for anterolateral instability in 1983.¹³ Intended to provide stability through a full range of motion, in this procedure the iliotibial band was split longitudinally and tenodesed onto the lateral femur, such that “a ligament is created that closely approximates the biomechanical function of the ACL” (Fig. 1B).

Combined procedures

As intra-articular procedures were popularised, various combined techniques were described. Besides the MacIntosh over-the-top procedure, these were complimentary rather than inherently combined procedures. Examples included intra-articular patella tendon reconstruction with MacIntosh lateral substitution¹⁴ as well as combinations with synthetic ligaments and augmentation devices.^{15,16}

Results for early extra-articular procedures

Reported results for isolated extra-articular procedures are generally poor. Kennedy reported 57% good or excellent results for the Ellison procedure.¹⁷ All patients had persistent anterior drawer sign, and 24 of 28 had positive pivot-shift at 6 months. Ellison reported 83% good or excellent results in 18 knees with his procedure up to 41 months post-operatively. Fox reported 63% excellent or fair results in 76 knees using a modification of Ellison’s technique.¹⁸

Neyret reported the results for isolated extra-articular reconstruction using the Lemaire procedure in 33 knees in 31 amateur skiers.¹⁹ 16 patients were very satisfied or satisfied with the result. At one year, pivot-shift was positive in 9 of 18 knees tested, and at final follow up was positive in 12 of 15 knees. The result, particularly in patients under 35 years of age, was dependent on the status of the medial meniscus.

Ireland and Trickey reported abolished anterolateral jerk in 42 of 50 knees using the Macintosh procedure at 2.25 years.¹² Of note, less than half of the excellent and satisfactory results were able to return to sport at their previous level.

Reporting on 62 knees at two years follow-up, Andrews claimed 94% objectively and 91% subjectively acceptable results for his mini-reconstruction.¹³ His reporting highlights the difficulty in comparing results from a time when many, often non-validated scoring systems were used.²⁰

A number of factors were blamed for the poor results of these early procedures, principally poor biomechanics caused by their non-anatomical nature and a perceived predisposition to lateral compartment OA.

Sydney examined the kinematic effect of the Andrews procedure on cadaveric knees.²¹ He found the repair non-functional between 0–20°, taut from 20–60° and overly tight at 90° of flexion, suggesting graft stretch as a cause of deteriorating results. He also noted the repair tended to hold the tibia in abnormal external rotation. Similar results were published by Draganich with regards to the Müller anterolateral femorotibial ligament tenodesis.²² He described over-constraint of tibial internal rotation from 30–90° of flexion. Engebretsen, studying the effect of an extra-articular tenodesis on intra-articular graft tension, found an abnormal externally rotated tibial resting position after tenodesis, which increased with application of an anterior load.²³ These findings were confirmed by Amis and Scammell, who found an isolated extra-articular procedure improved but did not correct knee stability compared to intra-articular and combined procedures.²⁴ Some authors have raised concerns regarding the development of lateral compartment OA due to over-constraint of the lateral compartment, however there appears to be little evidence for this in the literature.

The results for combined procedures were more encouraging. Bertoia reported excellent or good results in 31 of 34 knees using the MacIntosh lateral substitution over-the-top procedure.²⁵ Pivot-shift was abolished in 91%. Zarins reported a reduction of pivot-shift to 0 or 1+ in 91 of 100 knees using the MacIntosh over-the-top procedure supplemented with an intra-articular semitendinosus graft.²⁶ Rackemann, using a MacIntosh extra-articular procedure combined with a medial third patella tendon intra-articular reconstruction in 74 knees, reported satisfactory results in 93% and one positive pivot shift at six years.²⁷ Dejour reported results for 251 cases treated with patella tendon intra-articular reconstruction combined with Lemaire’s procedure.²⁸ He found 83% excellent or good functional results, though 24% had equivocal pivot-shift findings.

The value of a combined intra- and extra-articular approach versus intra-articular reconstruction alone was first studied by Jensen in 1983.²⁹ In this retrospective study, he found the most marked improvement in anterolateral rotatory instability in the combined procedure group. This finding, however, was challenged by other authors. Strum in 1989 reported no benefit to a combined procedure over intra-articular reconstruction alone, stressing the importance of a well performed intra-articular procedure.³⁰ O’Brien reported no difference in clinical results for the two groups, but noted a 40% incidence of chronic pain and/or swelling associated with the extra-articular procedure.³¹ Anderson compared bone-patella tendon-bone, hamstring and hamstring combined with extra-articular procedures in a prospective, randomised study.³² He found no benefit to the addition of the extra-articular procedure.

Renewed interest in extra-articular procedures

Today most anterior cruciate ligament surgery consists of intra-articular reconstruction using autogenous bone-patella tendon-bone or hamstring grafts or allograft. Despite advances in surgical technique and instrumentation, failure remains an issue. Graft failure rates have been quoted as high as

24%.³³ There is no universally accepted definition of failure, however, and outright graft failure is only part of the story. Stiffness, ongoing instability and pain may all signify failure. Many are unable to return to their desired activity level, with a recent meta-analysis by Adern finding return to pre-injury level of sports was only 63%.³⁴

ACL injury rarely occurs in isolation. Associated ligamentous, meniscal and chondral injuries all affect the results of surgery.³⁵ To add to this complexity, not all ACL injured knees will produce symptomatic instability,³⁶ and some knees will demonstrate a positive pivot-shift despite an intact ACL.³⁷

Persistent pivot-shift has been shown to be associated with poor patient satisfaction.³ Evidence suggests that even successful ACL reconstruction does not restore normal knee biomechanics, in particular with regards to rotational control.^{38–40}

Double bundle ACL reconstruction and anatomical single bundle reconstruction have been proposed to address this issue. In double bundle reconstruction, the postero-lateral bundle is intended to better resist the pivot shift.⁴¹ Whilst biomechanical studies have suggested this technique is superior to single bundle techniques in terms of rotational control,⁴² clinical superiority has not been demonstrated.⁴³

Anatomical single bundle ACL reconstruction aims to place the femoral tunnel in the foot print of the native ACL, rather than the more vertical position associated with older transtibial techniques.⁴⁴ The increased graft obliquity is intended to better resist rotational instability, however, biomechanical studies have shown mixed results.^{45,46} These grafts are also subjected to higher forces than non-anatomical grafts⁴⁷ which in turn may predispose to higher failure rates.

Lateral extra-articular reinforcement has been proposed as one possible solution to this problem.

Recent advances

Anatomy

The anatomy of the knee remains incompletely understood, particularly in regards to the functional anatomy of the lateral side. Numerous authors have described a structure connecting the lateral femoral condyle, lateral meniscus and lateral tibial plateau.^{48–50} This structure has been described as part of the iliotibial tract, a capsular thickening or a ligament in its own right, and been variously referred to as the “capsulo-osseous layer” of the iliotibial tract, the “midthird lateral capsular ligament”, the “lateral capsular ligament”,⁵¹ and most recently the “anterolateral ligament”⁵⁰ (Fig. 2).

Vincent and colleagues identified a structure, which they termed the anterolateral ligament, in 30 consecutive total knee arthroplasties, as well as 10 cadaver knees.⁵² At cadaveric dissection, the structure was found to arise from just anterior to the popliteus tendon insertion in nine knees, or from the popliteus tendon itself in one. It was closely associated with the lateral meniscus at the junction of its anterior and middle thirds. Its insertion was onto the anterolateral proximal tibia, 5 mm from the articular cartilage and always posterior to the most posterior border of Gerdy’s tubercle. Histological

analysis demonstrated a distinct fibrous structure, with some fibres inserting onto the meniscus. Recent published work by Claes and colleagues has identified this structure in 40 of 41 cadaveric knees.⁵³ They found the structure to originate posterior and proximal to the popliteus tendon insertion, on the lateral femoral epicondyle, and noted no connections between this structure and the iliotibial band.

Terry suggested that injury to the capsulo-osseous layer of the iliotibial band may be responsible for the variety of clinical findings in the ACL injured knee,⁵⁴ and failure to address associated injuries is a recognised cause of failed ACL reconstruction.⁵⁵ Future research should help to standardise nomenclature and clarify the biomechanics of this ligament. Should this confirm a role in the restraint of rotatory laxity, lateral extra-articular techniques may be shown to be more anatomical than once thought, and may be able to be modified to be truly anatomical reconstructive procedures.

Combined procedures

Isolated extra-articular procedures are no longer recommended.⁵⁶ Their role in combined procedures with modern intra-articular techniques, however, is less clear.

As previously described, Kato has demonstrated increased graft forces in anatomically placed single bundle reconstructions.⁴⁷ This may predispose anatomical grafts to early failure due to fixation failure or stretch, or later graft rupture. Engebretsen showed that an iliotibial tenodesis reduced the force in an ACL graft by an average 43%.²³ Draganich demonstrated load sharing between an intra- and extra-articular reconstruction, and suggested that the extra-articular procedure may have a role in protecting the intra-articular reconstruction during the healing phase.⁵⁷ Whilst these studies did not use anatomical intra-articular reconstructions, they suggest a role for extra-articular procedures in combined operations in some cases.

Monaco and colleagues compared 10 anatomical single bundle reconstructions with lateral extra-articular reinforcement with 10 double bundle ACL reconstructions using a navigation system.⁵⁸ They found no difference in anteroposterior translation between the two groups, but a significant reduction in internal rotation at 30° of knee flexion in the extra-articular reinforcement group.

Hamstring grafts

Early lateral procedures tended to use iliotibial band as graft material. The strength of this material depends on the width harvested, however, it is generally weaker than hamstring tendons and able to withstand significantly lower maximum stresses.⁵⁹ More recently, techniques have been described using hamstring tendon for lateral reinforcement.

Marcacci has described a technique of intra- and extra articular reconstruction using hamstring tendons.⁶⁰ The gracilis and semitendinosus tendons are stripped but their tibial insertions maintained. The sutured graft is then passed through a tibial tunnel and over-the-top of the lateral femoral condyle.

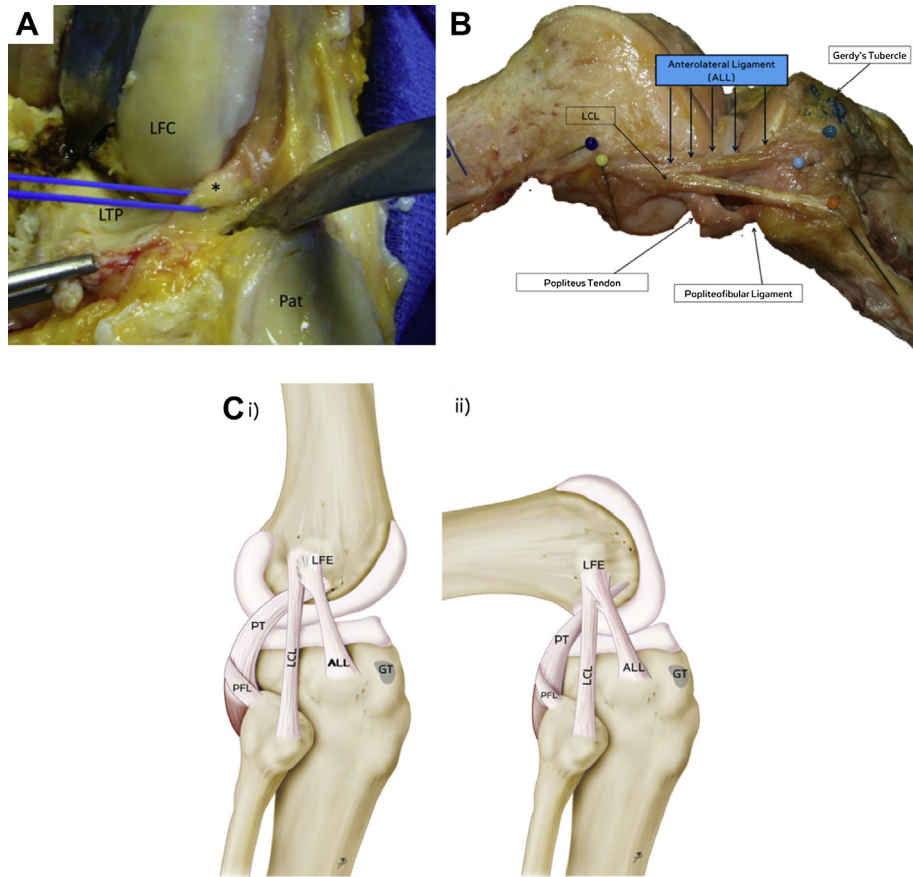


Fig. 2. (A) Intra-operative photograph during left total knee arthroplasty demonstrating the anterolateral ligament (asterix), lateral femoral condyle (LFC), patella (Pat) and lateral tibial plateau (LTP).⁵² (B) Dissection of a right knee demonstrating the anterolateral ligament (ALL). (C) Anatomic drawing considering the ALL and its relationship with well-known anatomical landmarks on the lateral aspect of the human knee.⁵³ (Ci) Knee in full extension. (Cii) Knee in 90° of flexion. LCL = lateral collateral ligament; GT = Gerdy's tubercle; LFE = lateral femoral epicondyle; PT = popliteus tendon; PFL = popliteo-fibular ligament. Reproduced with permission from Claes S, Vereecke E, Maes M, Victor J, Verdonk P, Bellemans J. Anatomy of the anterolateral ligament of the knee. *J Anat.* 2013;223:321–328.

A groove is formed in the lateral femur for stability and bone healing, and the tendons fixed with two bone staples. The remaining graft is passed deep to the iliotibial band and secured at Gerdy's tubercle.

At 11 years' follow-up of 54 knees in high level sports-persons, Marcacci reported 90.7% excellent or good results using the International Knee Documentation Committee (IKDC) score.⁶¹ Three knees (5.5%) showed a slight pivot-shift.

Neyret has described a technique using a bone-patella tendon-bone intra-articular graft and a gracilis tendon graft for the extra-articular reinforcement.⁶² The gracilis is threaded through a drill hole in one of the bone blocks, to create a continuous graft. The patella tendon graft is passed antero-grad through a femoral and tibial tunnel, locking the gracilis tendon in the femoral tunnel with the press-fit of the bony block. The two free limbs are then passed deep to the LCL and through either end of a bony tunnel through Gerdy's tubercle and sutured to one another (Fig. 3).

Lateral osteoarthritis

Concerns regarding over-constraint and development of lateral compartment degenerative arthritis were based predominantly on biomechanical studies of isolated extra-articular

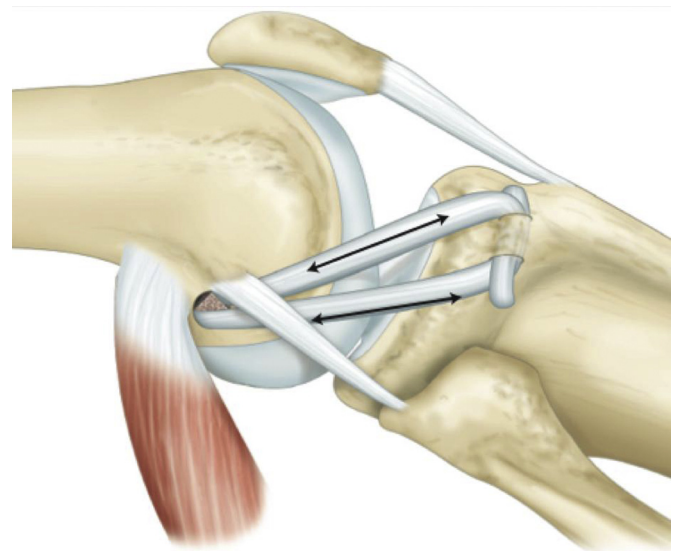


Fig. 3. Schematic diagram showing the extra-articular reinforcement technique of Neyret. This figure was published in: Neyret P, Demey G, Servien E, Lustig S. *Traité de chirurgie de genou*, page 57. Copyright © 2012 Elsevier Masson SAS. All rights reserved.

procedures and little clinical evidence for this exists.²¹ Over-constraint was not demonstrated by Draganich when an extra-articular procedure was performed after an appropriate intra-articular reconstruction.⁵⁷ Zaffagnini, in a prospective, randomised trial of bone-patella tendon-bone, four strand hamstring and Marcacci's combined technique, found no difference in radiological outcome between the groups at 5 years.⁶³ Long term follow up by Marcacci has not demonstrated an increase in lateral compartment OA at 11 years with his technique.⁶¹

Research by Jonsson and colleagues suggests that patients with residual pivot-shift post reconstruction are at higher risk for the development of OA than those with residual antero-posterior laxity.⁶⁴

Possible indications for extra-articular reinforcement

The future role of lateral extra-articular reinforcement procedures will likely be in specific subsets of patients known to be at increased risk of failure with isolated intra-articular reconstruction. Degree of instability, associated injuries, young age at operation, and revision procedures may all be appropriate indications.

Clinical,⁶⁵ radiological⁶⁶ and even intra-operative navigation based criteria⁶⁷ have been proposed to help identify patients who may benefit based on degree of instability. It is likely, however, that the degree of instability observed is related to damage to other structures, such as the anterolateral ligament, that we are only beginning to fully appreciate.^{53,54} LaPrade as early as 2000 claimed 95% accuracy in diagnosis of injury to the meniscotibial portion of the midthird lateral capsular ligament using magnetic resonance imaging.⁴⁹ Should biomechanical testing confirm a role for this structure in anterolateral instability, advances in imaging should allow us to diagnose this injury and thus identify patients likely to benefit from lateral reinforcement. Loss of the medial meniscus, which increases intra-articular graft forces by 33–50%⁶⁸ and has been shown to negatively influence knee stability post reconstruction⁶⁹ and may be another appropriate indication.

The results of revision ACL reconstruction are generally inferior to primary reconstruction.⁷⁰ There is conflicting evidence regarding the efficacy of lateral reinforcement in revision surgery. Colombet has described a combined technique of intra- and extra-articular reconstruction using a hamstring tendon graft in a "4 + 2" configuration.⁷¹ Using navigation to measure laxity, he found no significant improvement in anteroposterior translation and improved rotational control only at 90° of flexion with the addition of the lateral procedure. Trojani reported on a multicentre series of 189 revision procedures, of which 26 included a lateral procedure.⁷² He found a significant improvement in pivot-shift results in the lateral procedure group, with 80% negative pivot-shift compared to 63%. There was no significant difference, however, in the IKDC scores.

Conclusion

Lateral extra-articular reinforcement in conjunction with intra-articular reconstruction may be an important option in

the control of rotational laxity of the knee. Advances in understanding the complex lateral anatomy and biomechanics of the knee may allow the development of more anatomical procedures. Improved diagnostic techniques should help to identify patients most likely to benefit. Further research is needed to clarify the indications for this procedure in high risk and revision cases.

Conflicts of interest

The authors declare that they have no financial or non-financial conflicts of interest related to the subject matter or materials discussed in the manuscript.

References

- Swedish ACL Register. *Annual Report 2012*. 2013:1–36.
- Kennedy J, Jackson MP, O'Kelly P, Moran R. Timing of reconstruction of the anterior cruciate ligament in athletes and the incidence of secondary pathology within the knee. *J Bone Joint Surg Br*. 2010;92-B:362–366.
- Kocher MS, Steadman JR, Briggs K, Zurakowski D, Sterett WI, Hawkins RJ. Determinants of patient satisfaction with outcome after anterior cruciate ligament reconstruction. *J Bone Joint Surg Am*. 2002;84-A:1560–1572.
- Schindler OS. Surgery for anterior cruciate ligament deficiency: a historical perspective. *Knee Surg Sports Traumatol Arthrosc*. 2011;20:5–47.
- Slocum DB, Larson RL. Rotatory instability of the knee. Its pathogenesis and a clinical test to demonstrate its presence. *J Bone Joint Surg Am*. 1968;50:211–225.
- Slocum DB, Larson RL. Pes anserinus transplantation. A surgical procedure for control of rotatory instability of the knee. *J Bone Joint Surg Am*. 1968;50:226–242.
- Ségon P. *Recherches cliniques et expérimentales sur les épanchements sanguins du genou par entorse*. Progrès Médicale. 1879 [In French].
- Norwood LA, Andrews JR, Meisterling RC, Glancy GL. Acute anterolateral rotatory instability of the knee. *J Bone Joint Surg Am*. 1979;61:704–709.
- Ellison AE. Anterolateral rotatory instability. In: Funk Jr FJ, ed. *Symposium on the Athlete's Knee, Surgical Repair and Reconstruction, American Academy of Orthopaedic Surgeons*. 1978:178–193.
- Lemaire M. Ruptures anciennes du ligament croisé antérieur du genou. *J Chir*. 1967;311–320 [In French].
- Ellison AE. Distal iliotibial-band transfer for anterolateral rotatory instability of the knee. *J Bone Joint Surg Am*. 1979;61:330–337.
- Ireland J, Trickey EL. Macintosh tenodesis for anterolateral instability of the knee. *J Bone Joint Surg Br*. 1980;62:340–345.
- Andrews JR, Sanders R. A "mini-reconstruction" technique in treating anterolateral rotatory instability (ALRI). *Clin Orthop Relat Res*. 1983;93–96.
- Dandy DJ. Some clinical aspects of reconstruction for chronic anterior cruciate ligament deficiency. *Ann R Coll Surg Engl*. 1995;77:290–298.
- Dandy DJ, Gray AJ. Anterior cruciate ligament reconstruction with the Leeds-Keio prosthesis plus extra-articular tenodesis. Results after six years. *J Bone Joint Surg Br*. 1994;76:193–197.
- Moyen B, Jenny J-Y, Mandrino AH, Lerat J-L. Comparison of reconstruction of the anterior cruciate ligament with and without a Kennedy ligament-augmentation device: a randomized, prospective study. *J Bone Joint Surg Am*. 1992;74:1313–1319.
- Kennedy JC, Stewart R, Walker DM. Anterolateral rotatory instability of the knee joint. An early analysis of the Ellison procedure. *J Bone Joint Surg Am*. 1978;60:1031–1039.
- Fox JM, Blazina ME, Del Pizzo W, Ivey FM, Broukhim B. Extra-articular stabilization of the knee joint for anterior instability. *Clin Orthop Relat Res*. 1980:56–61.

19. Neyret P, Palomo JR, Donell ST, Dejour H. Extra-articular tenodesis for anterior cruciate ligament rupture in amateur skiers. *Br J Sports Med.* 1994;28:31–34.
20. Johnson DS, Smith RB. Outcome measurement in the ACL deficient knee—what's the score? *The Knee.* 2001;8:51–57.
21. Sydney SV, Haynes DW, Hungerford DS, Gerdes MH. *The Altered Kinematic Effect of an Iliotibial Band Tenodesis on the Anterior Cruciate Deficient Knee.* Orthopaedic Research Society, Transaction of Annual Meeting. 1987:340.
22. Draganich LF, Reider B, Miller PR. An in vitro study of the Müller anterolateral femorotibial ligament tenodesis in the anterior cruciate ligament deficient knee. *Am J Sports Med.* 1989;17:357–362.
23. Engebretsen L, Lew WD, Lewis JL, Hunter RE. The effect of an iliotibial tenodesis on intraarticular graft forces and knee joint motion. *Am J Sports Med.* 1990;18:169–176.
24. Amis AA, Scammell BE. Biomechanics of intra-articular and extra-articular reconstruction of the anterior cruciate ligament. *J Bone Joint Surg Br.* 1993;75:812–817.
25. Bertoia JT, Urovitz EP, Richards RR, Gross AE. Anterior cruciate reconstruction using the MacIntosh lateral-substitution over-the-top repair. *J Bone Joint Surg Am.* 1985;67:1183–1188.
26. Zarins B, Rowe CR. Combined anterior cruciate-ligament reconstruction using semitendinosus tendon and iliotibial tract. *J Bone Joint Surg Am.* 1986;68:160–177.
27. Rackemann S, Robinson A, Dandy DJ. Reconstruction of the anterior cruciate ligament with an intra-articular patellar tendon graft and an extra-articular tenodesis. Results after six years. *J Bone Joint Surg Br.* 1991;73:368–373.
28. Dejour H, Walch G, Neyret P, Adeleine P. Results of surgically treated chronic anterior laxities: apropos of 251 cases reviewed with a minimum follow-up of 3 years. *Rev Chir Orthop Reparatrice Appar Mot.* 1988;74:622–636 [In French].
29. Jensen JE, Slocum DB, Larson RL, James SL, Singer KM. Reconstruction procedures for anterior cruciate ligament insufficiency: a computer analysis of clinical results. *Am J Sports Med.* 1983;11:240–248.
30. Strum GM, Fox JM, Ferkel RD, et al. Intraarticular versus extraarticular reconstruction for chronic anterior cruciate ligament instability. *Clin Orthop Relat Res.* 1989;245:188–198.
31. O'Brien SJ, Warren RF, Wickiewicz TL, et al. The iliotibial band lateral sling procedure and its effect on the results of anterior cruciate ligament reconstruction. *Am J Sports Med.* 1991;19:21–25.
32. Anderson AF, Snyder RB, Lipscomb AB. Anterior cruciate ligament reconstruction a prospective randomized study of three surgical methods. *Am J Sports Med.* 2001;29:272–279.
33. Barrett GR, Luber K, Replogle WH, Manley JL. Allograft anterior cruciate ligament reconstruction in the young, active patient: Tegner activity level and failure rate. *Arthroscopy.* 2010;26:1593–1601.
34. Ardern CL, Webster KE, Taylor NF, Feller JA. Return to sport following anterior cruciate ligament reconstruction surgery: a systematic review and meta-analysis of the state of play. *Br J Sports Med.* 2011;45:596–606.
35. George MS, Dunn WR, Spindler KP. Current concepts review: revision anterior cruciate ligament reconstruction. *Am J Sports Med.* 2006;34:2026–2037.
36. Noyes FR, Matthews DS, Moar PA, Grood ES. The symptomatic anterior cruciate-deficient knee. Part II: the results of rehabilitation, activity modification, and counseling on functional disability. *J Bone Joint Surg Am.* 1983;65:163–174.
37. Fetto JF, Marshall JL. Injury to the anterior cruciate ligament producing the pivot-shift sign. *J Bone Joint Surg Am.* 1979;61:710–714.
38. Loh JC, Fukuda Y, Tsuda E, Steadman RJ, Fu FH, Woo SLY. Knee stability and graft function following anterior cruciate ligament reconstruction: comparison between 11 o'clock and 10 o'clock femoral tunnel placement. *Arthroscopy.* 2003;19:297–304.
39. Woo SL, Kanamori A, Zeminski J, Yagi M, Papageorgiou C, Fu FH. The effectiveness of reconstruction of the anterior cruciate ligament with hamstrings and patellar tendon a cadaveric study comparing anterior tibial and rotational loads. *J Bone Joint Surg Am.* 2002;84:907–914.
40. Ristanis S, Stergiou N, Patras K, Vasiliadis HS, Giakas G, Georgoulis AD. Excessive tibial rotation during high-demand activities is not restored by anterior cruciate ligament reconstruction. *Arthroscopy.* 2005;21:1323–1329.
41. Zelle BA, Vidal AF, Brucker PU, Fu FH. Double-bundle reconstruction of the anterior cruciate ligament: anatomic and biomechanical rationale. *J Am Acad Orthop Surg.* 2007;15:87–96.
42. Yagi M, Wong EK, Kanamori A, Debski RE, Fu FH, Woo SLY. Biomechanical analysis of an anatomic anterior cruciate ligament reconstruction. *Am J Sports Med.* 2002;30:660–666.
43. Meredith RB, Vance KJ, Appleby D, Lubowitz JH. Outcome of single-bundle versus double-bundle reconstruction of the anterior cruciate ligament: a meta-analysis. *Am J Sports Med.* 2008;36:1414–1421.
44. Bedi A, Feeley BT, Williams RJ. Management of articular cartilage defects of the knee. *J Bone Joint Surg Am.* 2010;92:994–1009.
45. Kato Y, Maeyama A, Lertwanich P, et al. Biomechanical comparison of different graft positions for single-bundle anterior cruciate ligament reconstruction. *Knee Surg Sports Traumatol Arthrosc.* 2012;21:816–823.
46. Markolf KL, Jackson SR, McAllister DR. A comparison of 11 o'clock versus oblique femoral tunnels in the anterior cruciate ligament-reconstructed knee: knee kinematics during a simulated pivot test. *Am J Sports Med.* 2010;38:912–917.
47. Kato Y, Ingham SJM, Kramer S, Smolinski P, Saito A, Fu FH. Effect of tunnel position for anatomic single-bundle ACL reconstruction on knee biomechanics in a porcine model. *Knee Surg Sports Traumatol Arthrosc.* 2009;18:2–10.
48. Terry GC, Hughston JC, Norwood LA. The anatomy of the iliopatellar band and iliotibial tract. *Am J Sports Med.* 1986;14:39–45.
49. LaPrade RF, Gilbert TJ, Bollom TS, Wentorf F, Chaljub G. The magnetic resonance imaging appearance of individual structures of the posterolateral knee. A prospective study of normal knees and knees with surgically verified grade III injuries. *Am J Sports Med.* 2000;28:191–199.
50. Vieira ELC, Vieira EA, Teixeira da Silva R, dos Santos Berlfein PA, Abdalla RJ, Cohen M. An anatomic study of the iliotibial tract. *Arthroscopy.* 2007;23:269–274.
51. Campos JC, Chung CB, Lektrakul N, et al. Pathogenesis of the Second Fracture: anatomic and MR imaging evidence of an iliotibial tract or anterior oblique band avulsion. *Radiology.* 2001;219:381–386.
52. Vincent J-P, Magnussen RA, Gezmez F, et al. The anterolateral ligament of the human knee: an anatomic and histologic study. *Knee Surg Sports Traumatol Arthrosc.* 2011;20:147–152.
53. Claes S, Vereecke E, Maes M, Victor J, Verdonk P, Bellemans J. Anatomy of the anterolateral ligament of the knee. *J Anat.* 2013;223:321–328.
54. Terry GC, Norwood LA, Hughston JC, Caldwell KM. How iliotibial tract injuries of the knee combine with acute anterior cruciate ligament tears to influence abnormal anterior tibial displacement. *Am J Sports Med.* 1993;21:55–60.
55. The MARS Group, Wright RW, Huston LJ, et al. Descriptive epidemiology of the Multicenter ACL REVISION Study (MARS) cohort. *Am J Sports Med.* 2010;38:1979–1986.
56. Pearl AJ, Bergfeld JA, Medicine AOSFS. *Extraarticular Reconstruction in the Anterior Cruciate Ligament Deficient Knee.* Human Kinetics Publishers; 1992.
57. Draganich LF, Reider B, Ling M, Samuelson M. An in vitro study of an intraarticular and extraarticular reconstruction in the anterior cruciate ligament deficient knee. *Am J Sports Med.* 1990;18:262–266.
58. Monaco E, Labianca L, Contedua F, De Carli A, Ferretti A. Double bundle or single bundle plus extraarticular tenodesis in ACL reconstruction? *Knee Surg Sports Traumatol Arthrosc.* 2007;15:1168–1174.
59. Noyes FR, Butler DL, Grood ES, Zernicke RF, Hefzy MS. Biomechanical analysis of human ligament grafts used in knee-ligament repairs and reconstructions. *J Bone Joint Surg Am.* 1984;66:344–352.
60. Marcacci M, Zaffagnini S, Iacono F, Neri MP, Loretto I, Petitto A. Arthroscopic intra- and extra-articular anterior cruciate ligament reconstruction with gracilis and semitendinosus tendons. *Knee Surg Sports Traumatol Arthrosc.* 1998;6:68–75.
61. Marcacci M, Zaffagnini S, Giordano G, Iacono F, Presti ML. Anterior cruciate ligament reconstruction associated with extra-articular tenodesis:

- a prospective clinical and radiographic evaluation with 10- to 13-year follow-up. *Am J Sports Med.* 2009;37:707–714.
62. Neyret P, Demey G, Servien E, Lustig S. *Traité de chirurgie de genou.* Elsevier Masson; 2012 [In French].
63. Zaffagnini S, Marcacci M, Lo Presti M, Giordano G, Iacono F, Neri MP. Prospective and randomized evaluation of ACL reconstruction with three techniques: a clinical and radiographic evaluation at 5 years follow-up. *Knee Surg Sports Traumatol Arthrosc.* 2006;14:1060–1069.
64. Jonsson H, Riklund-Ahlström K, Lind J. Positive pivot shift after ACL reconstruction predicts later osteoarthritis: 63 patients followed 5-9 years after surgery. *Acta Orthop Scand.* 2004;75:594–599.
65. Giraud B, Besse JL, Cladiere F, Ecochard R, Moyen B, Lerat J-L. Intra-articular reconstruction of the anterior cruciate ligament with and without extra-articular supplementation by quadriceps tendon plasty: seven-year follow-up. *Rev Chir Orthop Reparatrice Appar Mot.* 2006;92:788–797 [In French].
66. Lerat J-L, Moyen BL, Cladiere F, Besse JL, Abidi H. Knee instability after injury to the anterior cruciate ligament Quantification of the Lachman test. *J Bone Joint Surg Br.* 2000;82:42–47.
67. Musahl V, Kopf S, Rabuck S, et al. Rotatory knee laxity tests and the pivot shift as tools for ACL treatment algorithm. *Knee Surg Sports Traumatol Arthrosc.* 2011;20:793–800.
68. Papageorgiou CD, Gil JE, Kanamori A, Fenwick JA, Woo SL, Fu FH. The biomechanical interdependence between the anterior cruciate ligament replacement graft and the medial meniscus. *Am J Sports Med.* 2001;29:226–231.
69. Trojani C, Sbihi A, Djian P, et al. Causes for failure of ACL reconstruction and influence of meniscectomies after revision. *Knee Surg Sports Traumatol Arthrosc.* 2010;19:196–201.
70. Noyes FR, Barber-Westin SD. Revision anterior cruciate surgery with use of bone-patellar tendon-bone autogenous grafts. *J Bone Joint Surg Am.* 2001;83:1131–1143.
71. Colombet PD. Navigated intra-articular ACL reconstruction with additional extra-articular tenodesis using the same hamstring graft. *Knee Surg Sports Traumatol Arthrosc.* 2010;19:384–389.
72. Trojani C, Beaufile P, Burdin G, et al. Revision ACL reconstruction: influence of a lateral tenodesis. *Knee Surg Sports Traumatol Arthrosc.* 2012;20:1565–1570.