



HAL
open science

Cardiac MRI assessment of the effects of dietary Eicosapentaenoic acid (EPA) on the adverse consequences of sepsis

Amidou Traore, Thibault Leger, Guilhem Pages, Lucie Cassagnes, Kasra
Azarnoush, J.-M. Bonny, Luc Demaison

► To cite this version:

Amidou Traore, Thibault Leger, Guilhem Pages, Lucie Cassagnes, Kasra Azarnoush, et al.. Cardiac MRI assessment of the effects of dietary Eicosapentaenoic acid (EPA) on the adverse consequences of sepsis. Joint Annual Meeting ISMRM-ESMRMB, Jun 2018, Paris, France. 2018. hal-01824991

HAL Id: hal-01824991

<https://hal.science/hal-01824991v1>

Submitted on 27 Jun 2018

HAL is a multi-disciplinary open access archive for the deposit and dissemination of scientific research documents, whether they are published or not. The documents may come from teaching and research institutions in France or abroad, or from public or private research centers.

L'archive ouverte pluridisciplinaire **HAL**, est destinée au dépôt et à la diffusion de documents scientifiques de niveau recherche, publiés ou non, émanant des établissements d'enseignement et de recherche français ou étrangers, des laboratoires publics ou privés.

Amidou Traore^a, Thibault Leger^b, Guilhem Pagès^a, Lucie Cassagnes^c, Azarnoush Karsa^d, Jean-Marie Bonny^a and Luc Demaison^b

^a AgroResonance - UR370 QuaPA, F-63122, Saint Genès Champanelle, France, ^bUCA, UNH, CRNH, F-63000, Clermont-Ferrand, France, ^cCHU, Department of diagnostic and interventional radiology, 63003 Clermont-Ferrand, France, ^dHeart Surgery Department, CHU, Clermont-Ferrand, France

Aim

Severe sepsis is a serious syndrome requiring adequate medical care. It results in multi-organ damage with a significant toxicity: during the early phase of sepsis, cardiac mechanical activity is increased, but it progressively declines until cardiac failure. In the Western societies, the consumption of omega6 ($\omega 6$) polyunsaturated fatty acids (PUFA) is too high whereas that of omega3 ($\omega 3$) PUFA is too low. Yet the consequences of sepsis could be altered by PUFA based-dietary which modulate the inflammatory process. The aim of this study was to determine the effects of a dietary based on eicosapentaenoic acid (EPA, C20:5 $\omega 3$) a fatty of the $\omega 3$ series, on the adverse cardiac consequences of sepsis in a newly developed rat model of early-onset sepsis induced by cecal ligation and puncture.

Material and Method

Animal

32 female Wistar rats fed during 14 days with

a diet deficient in $\omega 3$ (n=16)
a regimen enriched with EPA (187 mg/day) (n=16)

- cecal ligation and puncture (**Deficient and septic, n=8**)
- Sham operated (**Deficient sham, n=8**)
- cecal ligation and puncture (**EPA septic, n=8**)
- Sham operated (**EPA sham, n=8**)

48h after the surgical intervention, the animals were anaesthetized with isofurane for cardiac MR imaging.

Cardiac MRI

Cine MR imaging was carried out at 11.7T (500MHz) with a 72-mm inner diameter volume coil. Ten to 12 contiguous 1-mm slices were acquired to cover the heart from the base to the apex using short-axis left ventricular (LV) bright blood imaging protocol based on the navigator self-gated FLASH sequence (TR/TE =6/2.5 ms, FA =8°, FOV= 5x5 cm, 256x256 matrix, slice thickness 1 mm, oversampling 400) → reconstruction of 16 movie frames per slice.

After imaging session, rats were euthanized and the heart removed for analysis of mitochondrial function.

Image analysis

After semi-automatic segmentation of the LV (Fig. 1), using Segment software¹, the time evolution of EDV² (Fig. 2) were obtained. From this curve, morphological and functional parameters, i.e., end diastolic volume (EDV), end systolic volume (ESV), ejection fraction (EF), heart rate (HR) and cardiac output (CO), along with the contraction and relaxation rates, were then derived.

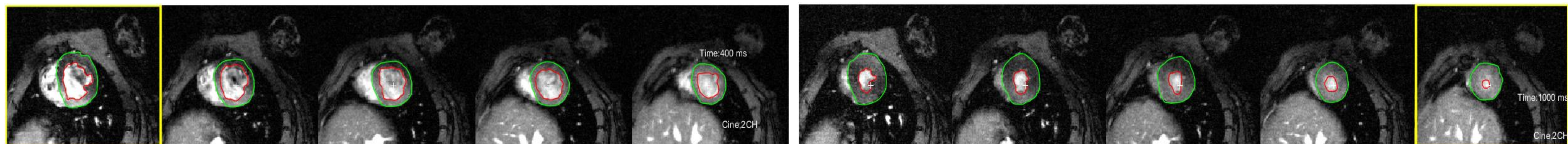


Fig. 1: To determine the time evolution of the epicardium (green) and endocardium (red) volumes, each slice was segmented. The images show 5 slices for both the End-diastolic (left) and End systolic (right).

Results

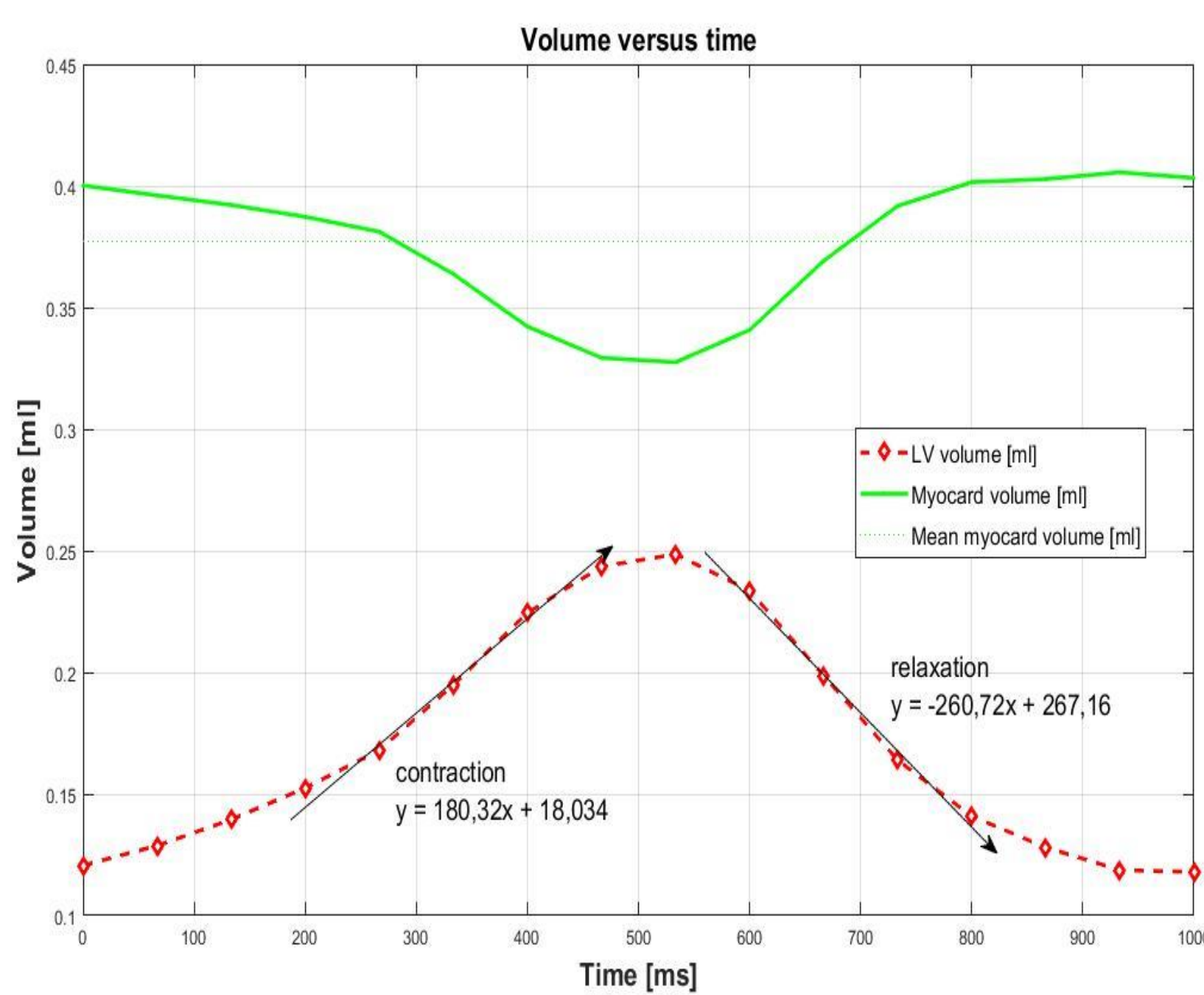


Fig 2 : Example of the evolution of the left ventricular epi- (green) and endo- (red) cardium volumes in one cardiac cycle. The contraction and relaxation rates were respectively derived from the ascending and descending of heavy slopes of the endocardium

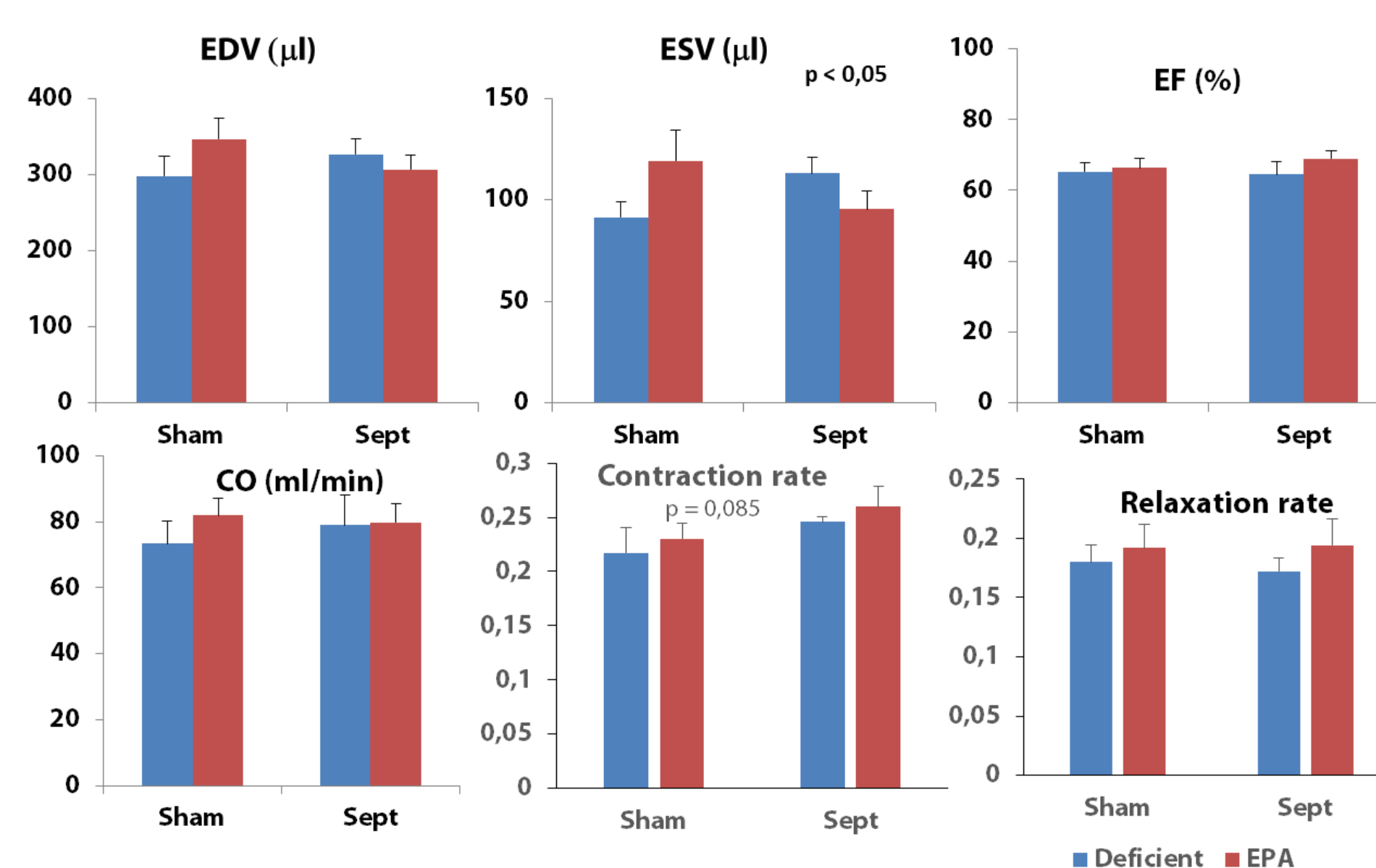


Fig 3 : Left ventricular functional parameters for control (sham operated) (n=16) and sepsis (n=16) rats. In each group, rats were fed without (n=8) and with EPA based dietary (n=8). Data are mean and the bars are standard deviation of the mean.

	Rate of ATP synthesis (nmoles/min/mg of proteins)	Lactate release to oxygen consumption ratio (µmoles/min/gof dry weight)
Deficient sham operated	379 ± 49	0,1443 ± 0,0110
Deficient and Septic	239 ± 58*	0,2175 ± 0,0340 *
EPA sham operated	411 ± 47	0,1391 ± 0,0199
EPA septic	416 ± 35	0,1713 ± 0,0175

Table 1 : Summary of the main results of the myocardial energy metabolism. Mitochondrial ATP production from malate and glutamate substrates is significantly (*) reduced by sepsis in deficient rats. Sepsis also induced an increase of the myocardial ratio between lactate production (anaerobic glycolysis) and oxygen consumption (aerobic metabolism). No modification was observed in the EPA groups.

Figure 1 shows an example of semi-automatic segmentation results. The timeframes of the EDV and ESV (max and min cavity) were manually adjusted. The resultant evolution of the endocardium volume at different cardiac time points (Fig. 2) allows the determination of the rates of contraction and relaxation. Figure 3 shows the derived myocardial functions. Sepsis did not alter significantly the EDV, ESV, EF, HR and CO. The rate of relaxation was not modified by the pathology event either. However, the speed of contraction tended to be increased ($p = 0.085$) with the sample size used in the present study. EPA based dietary seems to have no noticeable influence on the global cardiac functions. The main results of energy metabolism (table 1) showed that sepsis induced 1)- a significant decrease in ATP production in the deficient group and 2)- a significant increase in anaerobic glycolysis.

Discussion and conclusion

That sepsis tended to increase the rate of contraction indicates that the pathology was in its early hyperdynamic phase with an activation of cardiac function. Since in omega-3 deficient animals, early sepsis induced drop in mitochondrial respiration ($p < 0.001$) compared to control rats, with no difference observed in EPA animals, the absence of difference in MRI global cardiac function in septic rats may be attributed to the activation of the anaerobic ATP production in the deficient group compensating the decrease in mitochondrial activity and maintaining the cardiac mechanical activity.

¹ <http://segment.heiberg.se> Riegler, J. et al. (2010)

² J. Magn. Reson. Imaging, 32: 869–877.