



HAL
open science

Conventional radiography in juvenile idiopathic arthritis: Joint recommendations from the French societies for rheumatology, radiology and paediatric rheumatology

Pauline Marteau, Catherine Adamsbaum, Linda Rossi-Semerano, Michel de Bandt, Irène Lemelle, Chantal Deslandre, Tu Anh Tran, Anne Lohse, Elisabeth Solau-Gervais, Christelle Sordet, et al.

► To cite this version:

Pauline Marteau, Catherine Adamsbaum, Linda Rossi-Semerano, Michel de Bandt, Irène Lemelle, et al.. Conventional radiography in juvenile idiopathic arthritis: Joint recommendations from the French societies for rheumatology, radiology and paediatric rheumatology. *European Radiology*, 2018, 10.1007/s00330-018-5304-7 . hal-01795616

HAL Id: hal-01795616

<https://hal.science/hal-01795616>

Submitted on 4 Jan 2022

HAL is a multi-disciplinary open access archive for the deposit and dissemination of scientific research documents, whether they are published or not. The documents may come from teaching and research institutions in France or abroad, or from public or private research centers.

L'archive ouverte pluridisciplinaire **HAL**, est destinée au dépôt et à la diffusion de documents scientifiques de niveau recherche, publiés ou non, émanant des établissements d'enseignement et de recherche français ou étrangers, des laboratoires publics ou privés.



Distributed under a Creative Commons Attribution 4.0 International License



Conventional radiography in juvenile idiopathic arthritis: Joint recommendations from the French societies for rheumatology, radiology and paediatric rheumatology

Pauline Marteau¹ · Catherine Adamsbaum^{2,3} · Linda Rossi-Semerano⁴ · Michel De Bandt⁵ · Irène Lemelle⁶ · Chantal Deslandre^{7,8} · Tu Anh Tran^{9,10} · Anne Lohse¹¹ · Elisabeth Solau-Gervais¹² · Christelle Sordet¹³ · Pascal Pillet¹⁴ · Brigitte Bader-Meunier¹⁵ · Julien Wipff¹⁶ · Cécile Gaujoux-Viala¹⁷ · Sylvain Breton¹⁸ · Valérie Devauchelle-Pensec^{1,19}

Received: 29 July 2017 / Revised: 3 December 2017 / Accepted: 2 January 2018 / Published online: 26 March 2018
© The Author(s) 2018

Abstract

Background Juvenile idiopathic arthritis (JIA) can cause structural damage. However, data on conventional radiography (CR) in JIA are scant.

Objective To provide pragmatic guidelines on CR in each non-systemic JIA subtype.

Methods A multidisciplinary task force of 16 French experts (rheumatologists, paediatricians, radiologists and one patient representative) formulated research questions on CR assessments in each non-systemic JIA subtype. A systematic literature review was conducted to identify studies providing detailed information on structural joint damage. Recommendations, based on the evidence found, were evaluated using two Delphi rounds and a review by an independent committee.

Results 74 original articles were included. The task force developed four principles and 31 recommendations with grades ranging from B to D. The experts felt strongly that patients should be selected for CR based on the risk of structural damage, with routine CR of the hands and feet in rheumatoid factor-positive polyarticular JIA but not in oligoarticular non-extensive JIA.

Conclusion These first pragmatic recommendations on CR in JIA rely chiefly on expert opinion, given the dearth of scientific evidence. CR deserves to be viewed as a valuable tool in many situations in patients with JIA.

Electronic supplementary material The online version of this article (<https://doi.org/10.1007/s00330-018-5304-7>) contains supplementary material, which is available to authorized users.

✉ Pauline Marteau
pauline.marteau@chu-brest.fr

¹ Service de rhumatologie, CHU de Brest, Brest, France

² Paediatric Radiology, Hôpital Bicêtre, Paris, France

³ Paris Sud University Hôpital Bicêtre, Le Kremlin Bicêtre AHP, Paris, France

⁴ Paediatric Rheumatology, Reference Centre for Autoinflammatory Diseases, Hôpital Bicêtre, AP-HP, Le Kremlin Bicêtre, France

⁵ Rheumatology, Martinique University Hospital, P Zobda-Quitman Hospital, Route de Chateauboeuf, 97200 Martinique FWI, France

⁶ Paediatric Onco-Haematology, CHRU Nancy, 5 Allée du Morvan, 54500 Vandoeuvre les Nancy, France

⁷ Rheumatology A, Cochin Hospital, AHP, Paris, France

⁸ Université René Descartes Paris 5, Paris, France

⁹ Paediatrics, University Hospital, Nîmes, France

¹⁰ INSERM U 1183, Montpellier University, Montpellier, France

¹¹ Rheumatology, Nord Franche Comte Hospital, CHBM 14 rue de Mulhouse, 9000 Belfort, France

¹² Rheumatology, Poitiers University Hospital, Poitiers, France

¹³ Rheumatology, Haute-pierre Hospital, Strasbourg, France

¹⁴ Paediatrics, Pellegrin-Enfants, place Amélie Raba Léon, 33076 Bordeaux cedex, France

¹⁵ Paediatric Rheumatology, Hôpital Necker, Paris, France

¹⁶ Rheumatology A, Cochin Hospital, Paris, France

¹⁷ Rheumatology, Carêmeau University Hospital, 30029 Nîmes cedex 9, France

¹⁸ Paediatric Radiology, Necker-Enfants Malades Hospital, Assistance Publique Hôpitaux de Paris, 149 rue de Sèvres, 75743 Paris Cedex 15, France

¹⁹ Lymphocytes B et Autoimmunité, Université de Bretagne Occidentale, LabEx IGO, UMR1227, Brest, France

Key Points

- CR is a valuable imaging technique in selected indications.
- CR is routinely recommended for peripheral joints, when damage risk is high.
- CR is recommended according to the damage risk, depending on JIA subtype.
- CR is not the first-line technique for imaging of the axial skeleton.

Keywords Juvenile idiopathic arthritis · Conventional radiography · Recommendations · Structural damage · Erosions

Abbreviations

ACPA	Anti-Citrullinated Protein Antibody
CR	Conventional radiography
DMARDs	Disease-modifying Antirheumatic drugs
ERA	Enthesitis-related arthritis
EULAR	European League Against Rheumatism
GRADE	Grading of Recommendations, Assessment, Development and Evaluation
ILAR	International League Against Rheumatism
JIA	Juvenile idiopathic arthritis
jPsA	Juvenile psoriatic arthritis
JSN	Joint space narrowing
MRI	Magnetic resonance imaging
oJIA	Oligoarticular juvenile idiopathic arthritis
OMERACT	Outcome Measures in Rheumatology
PReS	Paediatric Rheumatology European Society
PICO	Population, Intervention, Comparison, Outcome
pJIA	Polyarticular juvenile idiopathic arthritis
RA	Rheumatoid arthritis
RF	Rheumatoid factor
SFIPP	French Society for Paediatric and Prenatal Imaging
SFR	French Society for Radiology
SFR	French Society for Rheumatology
sJIA	Systemic juvenile idiopathic arthritis
SLR	Systematic literature review
SOFREMIP	French Society for Paediatric Rheumatology and Internal Medicine
TMJ	Temporo-mandibular joint
US	Ultrasound

Introduction

Juvenile idiopathic arthritis (JIA) is a heterogeneous group of chronic inflammatory joint conditions that can cause structural damage [1]. Seven mutually exclusive subtypes of JIA are defined in the 2001 Edmonton classification developed by the International League Against Rheumatism (ILAR) [2]. This classification has been challenged and modifications suggested, such as exclusion of systemic-onset JIA (sJIA) due to its similarity to autoinflammatory diseases [3, 4].

The prevalence of joint damage among patients with JIA has been estimated at 8–27 % in extended oligoarticular JIA (oJIA), 35–67 % in polyarticular JIA (pJIA) and up to 80 % in rheumatoid factor (RF)-positive pJIA [5, 6]. The main treatment objectives in JIA are to control the pain and to prevent structural damage. Joint space narrowing (JSN), bone erosions and demineralization are radiographic findings shared between JIA and adult rheumatoid arthritis (RA). Changes specific to the paediatric population are early growth plate closure, epiphyseal deformity and growth asymmetry [7].

Conventional radiography (CR), magnetic resonance imaging (MRI) and ultrasound (US) are the imaging modalities most often used to evaluate joint inflammation or structural damage [8]. MRI and US hold considerable promise but are still under evaluation in JIA. CR remains the most readily available imaging technique for detecting and monitoring structural damage. However, potential limitations of CR in JIA include the risk of radiation-induced harm to the patient, interpretation difficulties raised by skeletal immaturity, and the delayed development of structural joint damage. Furthermore, because JIA is rare, little is known about the potential effects of synthetic or biological disease-modifying anti-rheumatic drugs (DMARDs) on structural joint damage [9–11]. Thus, whereas recommendations based on large studies are available for the radiographic assessment of chronic inflammatory joint disease in adults [12, 13], no similar guidelines have been developed for JIA. A task force was recently convened by the European League Against Rheumatism (EULAR) – Paediatric Rheumatology European Society (PReS) to develop recommendations about imaging studies for diagnosing and managing JIA [14]. Although this undertaking acknowledged, for the first time, that an assessment of imaging studies in JIA was needed, the task force neither focussed on CR nor provided specific guidance for everyday practice.

We established a multidisciplinary task force to develop guidelines on the use of CR for the diagnosis and follow-up of each JIA subtype in everyday practice. Our project was supported by the French Society for Rheumatology (SFR), French Society for Paediatric Rheumatology and Internal Medicine (SOFREMIP), French Society for Paediatric and Prenatal Imaging

(SFIPP), French Society for Radiology (SFR), and largest non-profit paediatric rheumatology patient organisation in France (KOURIR).

Methods

Field of research

We considered the following situations, at diagnosis and during follow-up, in each of the following five subtypes of JIA (oJIA, pJIA with and without RF and/or anti-citrullinated peptide antibody (ACPA), juvenile psoriatic arthritis (jPsA), and enthesitis-related arthritis (ERA)) Undifferentiated arthritis, as a heterogeneous subset related to one or several subtypes, and systemic JIA, having a peculiar articular course and structural prognosis, were left aside. Experts also focused on juvenile monoarthritis. Special attention was directed to the cervical spine, hip and temporo-mandibular joints (TMJs).

Recommendation development process

The task force comprised 16 JIA experts (eight rheumatologists, five paediatricians, two paediatric radiologists experienced in skeletal disease and one patient organisation representative). We used the Grading of Recommendations, Assessment, Development and Evaluation (GRADE) method [15, 16] for elaborating, evaluating, disseminating and implementing recommendations elaborated by the EULAR and the Outcome Measures in Rheumatology (OMERACT) group [17, 18], and the Population, Intervention, Comparison, Outcome (PICO) process to frame the research questions.

We considered structural radiographic abnormalities: JSN, erosions, pseudo-joint space widening for sacro-iliac joint [19, 20] and ankylosis [12]. A research fellow (PM) assisted by two experts in systematic review methodology (CGV, methodologist; and VDP, convenor) performed a systematic literature review by searching PubMed, Scopus/Elsevier, and the Cochrane Library. Original articles including clinical trials, retrospective cohort studies, other retrospective studies, and case-control studies published between 1980 and December 2016 were identified. The following indexing was used: ‘juvenile idiopathic arthritis’ OR ‘juvenile rheumatoid arthritis’ OR ‘juvenile chronic arthritis’ OR ‘juvenile psoriatic arthritis’ OR ‘enthesitis-related arthritis’ OR ‘juvenile spondyloarthritis’ AND ‘radiography’ OR ‘X-ray’ (see Appendix 1 for details). The quality of evidence and grades of recommendation were determined according to the standards of the Oxford Centre for Evidence-Based Medicine [21]. Recommendations were graded A to D depending on the level of the underlying evidence (from 1A to 4) [18].

The task force debated and formulated a preliminary set of recommendations based on the systematic literature review

supplemented, when necessary, by their expert opinion. This set was then evaluated by a panel of 14 independent French-speaking experts. Modifications were debated by the task force. The final recommendations were then rated on a 10-point scale by the task force and independent panel through a Delphi process.

Results

Systematic literature review

Of the 118 publications identified by the literature search, 74 [5, 6, 9–11, 19, 20, 22–88] original articles, as well as one abstract [89] and one online recommendation [90], were included (Fig. 1, Table 1).

Recommendations

The experts elaborated four overarching principles and 31 recommendations. Table 2 lists the recommendations.

Overarching principles

Radiation exposure was taken into account (principle B), according to French Society for Radiology recommendations [90] (Appendix 2). Much of the cartilage is still radio-transparent in children younger than 5 years of age. In this age group, the need for CR must be evaluated with great care (principle C) [91].

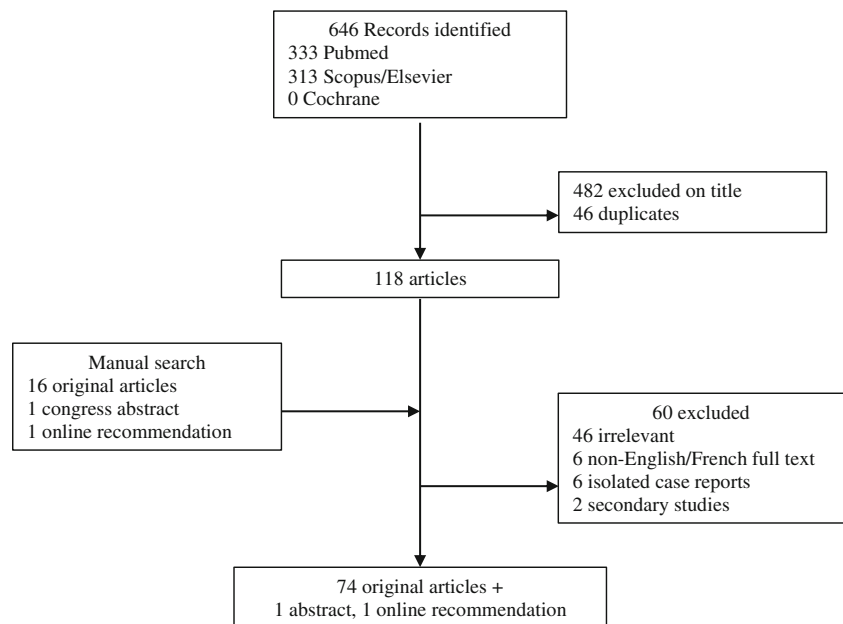
Other imaging modalities such as US and MRI are increasingly used in JIA. Although promising, they are not discussed herein. They will be the focus of specific recommendations (principle D).

Oligoarticular JIA (oJIA)

1. *CR should not be performed routinely as a diagnostic investigation in oJIA.* The literature review identified ten studies in which CR was performed, even in patients younger than 4 years. Among them, one focussed specifically on oJIA [35] and nine investigated several JIA subtypes but reported data separately for oJIA [6, 24, 27, 36–38, 40, 42, 43]. The usefulness of CR is limited by the incomplete ossification of the epiphyses, most notably in the youngest age groups [33]. Therefore, when the diagnosis is definitive, CR is not recommended.

2. and 3. During follow-up, CR should be performed on affected joint(s) that remain symptomatic after 3 months. By ‘symptomatic joints’*, we mean painful and/or swollen joints and/or joints that are limited in motion. In patients with persistently symptomatic* joints, the reiteration of CR during follow-up is at the discretion of the physician. Several studies

Fig. 1. Systematic literature review flow-chart



showed evidence of radiographic progression early in the natural history of oJIA [24, 27, 35, 38].

4. *In patients with clinically inactive disease (CID), CR should not be performed routinely.* The diagnosis of CID relies on physician judgement, aided by validated tools [92–94]. No data are available on radiographic disease progression in clinically silent joints in patients with oJIA.

5. *In patients with extended oJIA, the recommendations for pJIA should be applied.* The number of affected joints is strongly associated with structural damage in oJIA [35].

6. *In patients with structural damage, the selection and timing of specific imaging techniques to further assess the damaged joint during follow-up is guided by clinical considerations.*

Joints with structural damage must undergo specific CR evaluations during the patient's growth.

Polyarticular JIA (pJIA)

7. and 8. *Routine CR of the wrists, hands and forefeet is strongly recommended at the diagnosis of polyarticular JIA with positive RF/ACPA. CR of other joints than wrists, hands and forefeet, is recommended at the diagnosis for symptomatic joints*only.* Prospective studies were reviewed, with special attention to early pJIA. Erosions and JSN occurred preferentially at the hands, wrists and feet [11, 31, 43, 48–51], joints that were sometimes asymptomatic [31] CR at the diagnosis provides a reference for assessing disease progression. It is supported by 'adult' recommendations [13] for rheumatoid arthritis, which has a similar structural evolution.

9. and 10. *In new-onset RF/ACPA-negative pJIA with adverse prognostic factors, CR at diagnosis should be performed as for RF/ACPA-positive pJIA.* Box 1 lists the factors

of adverse prognostic significance in pJIA [31, 44, 50, 51]. These factors are associated with a pattern of joint damage over time similar to that seen in RF/ACPA-positive pJIA [38].

Box 1: Factors of adverse prognostic significance in polyarticular juvenile idiopathic arthritis (pJIA)

Early involvement of wrists
Symmetric arthritis
Distal, small-joint arthritis
Elevated ESR/CRP
Pre-existing radiographic abnormalities

ESR, erythrocyte sedimentation rate; CRP, serum C-reactive protein level

11. *In new-onset, RF/ACPA-negative pJIA without adverse prognostic factors, at diagnosis, CR should be confined to symptomatic* joints.* This recommendation is based on expert opinion.

12. *In RF/ACPA-positive pJIA, CR of the hands, wrists and forefeet is strongly recommended 1 year after disease onset, and when transitioning from paediatric to adult healthcare. At other time points, the use of CR during follow-up is at the discretion of the physician.* Prospective studies found evidence of joint damage even in asymptomatic joints [31]. Patients with long-standing disease had high prevalences of joint erosions (30–70 % in historical studies) [5, 28, 38, 40, 44, 48, 54], close to those in adults with RA [48]. In RA, joint destruction at asymptomatic sites is a major predictor of adverse outcomes [13, 95]. However, radiographic progression with erosions in asymptomatic joints is not well documented in JIA and may have been underestimated. In a study of 471 joints in 67 patients with polyarticular JIA, radiographs showed erosions at the hands and feet in 36 % and 39 % of

Table 1 Details of the studies identified by the systematic literature review

Article	Design	JIA subtype	Number of patients	Imaging findings used as outcome	Imaging technique	Purpose
Maldonado-Cocco 1980 [46]	Prospective	JRA	100	Primary	CR	To assess the frequency of carpal ankylosis
Williams and Ansell 1985 [54]	Retrospective	RF+ pJIA	81	Primary	CR	To assess peripheral radiographic progression
Poznanski 1991 [26]	Narrative review	JRA	NA	NA	CR	To develop a first score for assessing radiographic damage
Harel 1993 [10]	Prospective	JRA	23	Primary	CR	To assess effects of MTX on radiographic progression evaluated based on carpal length
Ravelli 1998 [11]	Retrospective	pJIA	26	Primary	CR	To assess carpal length changes during MTX therapy in pJIA (with bilateral wrist involvement)
Guillaume 2000 [35]	Prospective	oJIA	207	Secondary	CR	To identify prognostic factors in oJIA
Al-Matar 2002 [36]	Retrospective	oJIA	205	Secondary	CR	To identify early features associated with poor outcome in oligoarticular-onset JIA
Flatø 2002 [30]	Retrospective	JRA, SEA, JPsA, IBD-associated arthritis	314	Primary	CR	To assess factors associated with radiographic sacroiliitis in JIA
Huemer 2002 [64]	Prospective	JPsA, oJIA	87	No	NA	To compare clinical features of JPsA and oJIA, including patterns of joint involvement, and to discuss classification
Laiho 2002 [70]	Cross-sectional	JCA	159	Primary	CR	To evaluate radiographic inflammatory changes in the cervical spine
Mason 2002 [49]	Cross-sectional	Polyarticular JRA	60	Primary	CR	To assess the frequency of in hand/wrist CR damage at diagnosis
Oen 2002 [39]	Narrative review	JIA	NA	NA	NA	To identify outcome predictors, including radiographic findings
Bowyer 2003 [40]	Retrospective	oJIA, pJIA, sJIA	703	Secondary	CR	To assess health status 1 and 5 years after disease onset
Doria 2003 [45]	Cross-sectional	JRA	60	Primary	CR	To assess inter- and intra- observer variability of two scoring systems (Larsen/modified Larsen), comparison to MRI
Flatø 2003 [50]	Case-control	JRA	268	Secondary	CR	To assess long-term prognostic factors
Magni-Manzoni 2003 [51]	Prospective	pJIA, extended oJIA, sJIA, JPsA, ERA	94	Primary	CR	To assess the rate of radiographic progression (Poznanski score)
Oen 2003 [38]	Retrospective	JRA	216	Primary	CR	To assess radiographic damage in early and advanced disease
Oen 2003 [37]	Retrospective	JRA	393	Secondary	CR	To identify early predictors of long-term outcome
Ravelli and Martini 2003 [6]	Narrative review	All subtypes	NA	NA	NA	To identify early predictors of outcomes, including radiographic outcomes
Tsitsami 2003 [68]	Retrospective	oJIA, JPsA, UA	185	Secondary	CR	To evaluate associations between a familial history of psoriasis and the outcome of oligoarticular JIA
Van Rossum 2003 [31]	Prospective	pJIA, oJIA, extended oJIA	67	Primary	CR	To describe radiographic features
Twilt 2004 [73]	Cross-sectional	JIA (all subtypes)	97	Primary	CR	To evaluate the prevalence of radiographic damage on the OPG
Mason 2005 [5]	Prospective	Polyarticular JRA	12	Primary	CR	To assess radiographic progression after 2 years
Van Rossum 2005 [29]	Prospective	pJIA, oJIA	66	Primary	CR	To assess sensitivity of Dijkstra radiographic score
Helenius 2006 [83]	Prospective	Adult: RA, AS, SPA, MCTD	67	Primary	CR, MRI	To describe clinical, radiographic and MRI findings in rheumatic diseases
Rossi 2006 [33]	Prospective	pJIA	25	Primary	CR	To assess the reliability of the Sharp and Larsen radiographic scoring systems
Flatø 2006 [58]	Case / control	ERA/oJIA, pJIA	55/55	Secondary	CR	To compare clinical, functional and radiological features in ERA versus other JIA subtypes
Selvaag 2006 [28]	Prospective	sJIA, pJIA, oJIA, ERA	137	Primary	CR	To assess radiographic findings at diagnosis and 3-years later
Billian 2007 [82]	Prospective	sJIA, RF+ and RF- pJIA, oJIA, ERA, JPsA	100	Secondary	CR	To describe clinical, orthodontic, OPG and lateral cephalogram in 46 patients
Gilliam 2008 [44]	Retrospective	RF+ and RF- pJIA, oJIA, sJIA	68	Secondary	CR	To evaluate associations of markers, including radiographic changes, to disease severity
Habib 2008 [47]	Cross-sectional	pJIA, sJIA, oJIA	68	Secondary	CR	To determine the prevalence and significance of ACPAs in JIA

Table 1 (continued)

Article	Design	JIA subtype	Number of patients	Imaging findings used as outcome	Imaging technique	Purpose
Nielsen 2008 [9]	Retrospective	extended oJIA, sJIA, pJIA, JPsa	40	Primary	CR	To evaluate the radiographic outcome (Poznanski score) during etanercept therapy
Pedersen 2008 [84]	Prospective	JIA (subtype not specified)	15	Primary	CR, MRI	To describe clinical, CR and MRI features; to compare CR to MRI
Rostom 2008 [57]	Cross-sectional	JIA (all subtypes)	121	Primary	CR	To determine the prevalence of clinical and radiological hip involvement
Müller 2009 [77]	Prospective	JIA (all subtypes)	30	Primary	US, MRI	To compare clinical examination/US to MRI
Butbul 2009 [62]	Retrospective	JPsa, oJIA, pJIA	106	No	NA	To compare clinical features in JPsa to other JIA subtypes with similar patterns of joint disease – including growth abnormalities
Endén 2009 [71]	Cross-sectional	sJIA, pJIA/ fibromyalgia (control)	134/24	Primary	CR	To describe growth and cervical vertebrae size in JIA (vs. control)
Flatø 2009 [63]	Retrospective	JPsa, oJIA, pJIA	336	Secondary	CR	To compare JPsa features (including radiographic sacro-iliitis) and outcomes to other JIA subtypes
Lin 2009 [60]	Cross-sectional	Juvenile AS	47 juvenile AS, 122 adult AS	Secondary	CR	To compare clinical, laboratory and radiographic features between juvenile and adult-onset AS
Tafaghodi 2009 [34]	Retrospective	JIA (all subtypes)	174	Primary	CR	To assess radiographic characteristics of JIA (118 patients) vs. ALL (56 patients)
Arvidsson 2010 [76]	Prospective	JRA	60	Primary	CR, CT	To assess TMJ imaging during follow-up for long-standing JIA
Pagnini 2010 [20]	Prospective	ERA	59	Primary	CR, MRI	To identify predictors of sacroiliitis
Stoll 2010 [19]	Retrospective	ERA, JSpA, JPsa	143	Primary	CR, MRI	To identify risk factors for sacroiliitis
Cannizzaro 2011 [85]	Retrospective	oJIA, RF+ and RF- pJIA, JPsa, ERA, sJIA	223	Secondary	CR, MRI	To determine the incidence of TMJ involvement in different JIA subtypes
Kjellberg 2011 [72]	Case-control	pJIA, oJIA, JPsa, ERA, UA	82	Primary	CR	To compare radiographic cephalometry findings in JIA and healthy controls
Ravelli 2011 [24]	Retrospective	oJIA, RF- negative pJIA, JPsa, UA	971	Secondary	CR	To compare disease characteristics depending on ANA status
Stoll 2011 [65]	Retrospective	JPsa, oJIA	87/503	No	NA	To compare clinical features of oJIA vs. JPsa
Stoll 2011 [66]	Narrative review	JPsa	NA	No	NA	To identify features of JPsa, in comparison with other subtypes of JIA
Bertilsson 2012 [41]	Prospective	JCA	132	Secondary	CR	To prospectively investigate the characteristics and outcome predictors over 5 years of follow-up
Lipinska 2012 [27]	Prospective	oJIA, pJIA, sJIA	74	Secondary	CR	To assess the Steinbrocker score depending on ACPA status
Bertilsson 2013 [42]	Prospective	JCA	132	Secondary	CR	To evaluate long-term outcomes, after 17 years of follow-up
Chen 2012 [56]	Cross-sectional	Juvenile-onset AS	67	Secondary	CR	To compare clinical, laboratory and radiographic features of juvenile-/adult-/late-onset AS
Ozawa 2012 [52]	Cross-sectional	pJIA, sJIA	40	Secondary	CR	To compare radiological and laboratory findings in pJIA and sJIA
Abramowicz 2013 [75]	Retrospective	JIA	51	Primary	MRI	To identify prevalence of synovitis on MRI, TMJ imaging and clinical predictive factors
Elhai 2013 [48]	Prospective	pJIA	43	Primary	CR	To compare radiological outcomes of pJIA at transition vs. matched RA patients
Elhai 2013 [69]	Cross-sectional	pJIA/RA	57/58	Primary	CR	To compare the frequency of cervical spine radiographic damage between long-standing pJIA and RA
Jadon 2013 [59]	Systematic review	Juvenile-onset AS	NA	NA	CR	To compare clinical, social and radiographic features of adult- vs. juvenile-onset AS
Omar 2013 [53]	Cross-sectional	oJIA, pJIA, sJIA	54	Secondary	CR	To assess correlations linking ACPA presence to the JADAS and Sharp van der Heijde scores

Table 1 (continued)

Article	Design	JIA subtype	Number of patients	Imaging findings used as outcome	Imaging technique	Purpose
Cedströmer 2013 [78]	Retrospective	oJIA, sJIA, pJIA, JPsA, ERA	266	Secondary	CR	To describe clinical findings and disease activity and their associations with CR abnormalities
Giancane 2014 [43]	Prospective	RF+ and RF- pJIA, sJIA, extended oJIA, UA, JPsA	186	Primary	CR	To assess radiographic outcomes during follow-up (1–10 years)
Jaremkó 2014 [61]	Cross-sectional	Juvenile AS	26	Primary	CR, MRI	To compare the usefulness of CR and MRI for sacro-iliac joint evaluation at diagnosis of juvenile AS
Rodriguez-Lozano 2014 [32]	Cross-sectional	sJIA, RF+ and RF- pJIA, JPsA, extended oJIA	60 CR	NA	CR	To assess the inter-observer reliability of CR interpretation
Abramowicz 2014 [74]	Retrospective	oJIA, pJIA, JPsA	30	Primary	CR, MRI	To identify radiographic findings associated with TMJ synovitis on MRI
Górska 2014 [79]	Cross-sectional	oJIA, pJIA	26	Primary	CR	To describe orthodontic and radiographic findings
Koos 2014 [80]	Case-control	oJIA, RF- negative pJIA, ERA, JPsA/non-JIA controls	23/23	Primary	Cone Beam CT	To describe pathological changes in TMJs
Koos 2014 [81]	Cross-sectional	JIA (all subtypes)/controls	134/134	Primary	MRI	To evaluate the reliability of clinical symptoms for diagnosing TMJ synovitis
Ringold 2014 [55]	Recommendations	pJIA	NA	NA	CR	To develop CARRA recommendations for treating new-onset pJIA
Colebatch-Bourm 2015 [87]	Recommendations	All subtypes	NA	NA	CR, US, MRI	EULAR recommendations/ all imaging techniques
Ravelli 2015 [23]	Narrative review	JPsA	NA	NA	No	To assess the classification of JPsA and its relation to oJIA
Chan 2016 [22]	Prospective	JPsA and non-psoriatic JIA	57	No	No	To discuss the classification of JPsA
Jadon 2016 [88]	Prospective	Adult AS and PsA	402	Primary	CR	To compare radiographic features of AS vs. PsA with axial disease
Kavanaugh 2016 [25]	Phase III clinical trial	Adult PsA	405	Primary	CR	To assess the efficacy of golimumab on radiographic progression in adult PsA
Kristensen 2016 [86]	Systematic review	All subtypes	NA	NA	MRI	To identify clinical predictors of TMJ involvement, needing imaging assessment
Weiss 2016 [67]	Prospective	JSpA	40	Primary	CR, MRI	To evaluate the prevalence of sacroiliitis, compared to physical examination findings
Guide du bon usage des examens d'imagerie (French online recommendation) [90]	Recommendations	NA	NA	NA	CR	To develop recommendations about CR for focal limb pain
Ravelli 2014 [89] (ACR Pediatric Rheumatology Symposium)	Clinical trial	pJIA	87	Primary	CR	To assess the effect of tocilizumab on pJIA after 2 years, using the van der Heijde and Poznanski scores

ACPA anti-citrullinated protein antibody, ALL acute lymphoblastic leukaemia, ANA antinuclear antibody, AS ankylosing spondylitis, CARRA Childhood Arthritis and Rheumatology Research Alliance, CR conventional radiography, IBD inflammatory bowel disease, JADAS Juvenile Arthritis Disease Activity Score, JCA juvenile chronic arthritis (former EULAR criteria), JRA juvenile rheumatoid arthritis (former ACR criteria), JPsA juvenile psoriatic arthritis, JSpA juvenile spondyloarthritis, MCTD mixed connective tissue disease, MTX methotrexate, NA not applicable, oJIA oligoarticular juvenile idiopathic arthritis, OPG orthopantomogram, pJIA polyarticular juvenile idiopathic arthritis, SEA seronegative enthesopathy and arthropathy, sJIA systemic juvenile idiopathic arthritis, UA undifferentiated arthritis

Table 2 Recommendations about CR as a diagnostic and follow-up investigation in non-systemic JIA, with scores for agreement among experts, levels of evidence and grade

Recommendations	Mean agreement score (\pm SD)	Level of evidence	Grade
<i>Overarching principles</i>			
A. A CR assessment is necessary in JIA.	9.30 (\pm 1.26)	-	-
B. The potential risks associated with exposure to ionising radiation must always be considered when using CR.	9.70 (\pm 0.70)	-	-
C. CR is difficult to interpret in skeletally immature patients, particularly those <5 years of age.	8.95 (\pm 1.73)	-	-
D. Other imaging techniques, such as US and MRI, are being developed in JIA, and will be discussed in specific recommendations.	8.95 (\pm 1.85)	-	-
<i>Oligoarthritis (oJIA)</i>			
1. CR should not be performed routinely as a diagnostic investigation.	8.20 (\pm 1.94)	3	C
2. During follow-up, CR should be performed on affected joint(s) that remain symptomatic* after 3 months	9.10 (\pm 2.17)	4	D
3. In patients with persistently symptomatic* joints, the reiteration of CR during follow-up is at the discretion of the physician.	9.15 (\pm 1.04)	4	D
4. In patients with inactive disease, CR is not recommended.	9.45 (\pm 0.83)	4	D
5. In patients with extended oJIA, the recommendations for pJIA should be applied.	9.30 (\pm 0.92)	3	C
6. In patients with structural damage, the selection and timing of specific imaging techniques to further assess the damaged joint during follow-up is guided by clinical considerations.	9.15 (\pm 1.04)	4	D
<i>Polyarthritis (pJIA)</i>			
7. Routine CR of the wrists, hands, and forefeet is strongly recommended at the diagnosis of polyarticular JIA with positive RF/ACPA.	9.30 (\pm 1.26)	2B, 3	B
8. CR of other joints than wrists, hands, and forefeet, is recommended at the diagnosis for symptomatic* joints only.	9.00 (\pm 1.49)	2B,3	B
9. In new-onset RF/ACPA-negative pJIA with adverse prognostic factors, CR at diagnosis should be performed as for RF/ACPA-positive pJIA (recommendation #7).	8.55 (\pm 2.46)	3	C
10. Adverse prognostic factors are early wrist involvement, distal involvement, symmetric arthritis, high CRP/ESR, and bone erosions.	9.35 (\pm 0.81)	2B	B
11. In new-onset, RF/ACPA-negative pJIA without adverse prognostic factors, at diagnosis, CR should be confined to symptomatic* joints.	8.15 (\pm 2.28)	4	D
12. In RF/ACPA-positive pJIA, CR of the hands, wrists, and forefeet is strongly recommended	8.6 (\pm 1.31)	2A, 2B	B
- 1 year after disease onset	8.30 (\pm 1.72)	2B	B
- and when transitioning from paediatric to adult healthcare	8.85 (\pm 0.99)	4	D
At other time points, the use of CR during follow-up is at the discretion of the physician.	9.25 (\pm 0.85)	4	D
13. Routine CR of other joints is not recommended.	9.40 (\pm 0.75)	4	D
14. During the follow-up of RF/ACPA-negative pJIA with adverse prognostic factors, CR should be performed as for RF/ACPA-positive pJIA (recommendation #12).	9.00 (\pm 2.03)	3	C
15. During the follow-up of RF/ACPA-negative pJIA without adverse prognostic factors, the use of CR is at the discretion of the physician.	9.50 (\pm 1.17)	4	D
16. CR can be repeated in patients who remain symptomatic longer than 3 months.	8.25 (\pm 2.10)	4	D
17. In patients with structural damage, the selection and timing of specific imaging techniques during follow-up is guided by clinical considerations.	9.35 (\pm 0.81)	4	D
<i>Enthesitis-related arthritis (ERA)</i>			
18. In patients with axial ERA, CR of the spine and hip joints should be performed only when needed for the differential diagnosis.	8.05 (\pm 2.42)	4	D
19. During the follow-up of axial ERA, CR should be considered only for the hip joints, depending on the clinical course and availability of US and/or MRI.	8.90 (\pm 1.33)	3	C
20. CR is not recommended for multifocal enthesitis.	9.10 (\pm 0.97)	4	D
21. In patients with isolated enthesitis, CR can be considered as a tool for establishing the differential diagnosis.	8.35 (\pm 2.43)	4	D

Table 2 (continued)

Recommendations	Mean agreement score (\pm SD)	Level of evidence	Grade
<i>Psoriatic arthritis (jPsA)</i>			
22. No specific recommendation can be made about CR in juvenile psoriatic arthritis.	9.20 (\pm 0.83)	4	D
23. Guidance may be taken from the recommendations above, depending on the clinical presentation, or from recommendations issued for adults.	9.35 (\pm 0.74)	4	D
<i>Situations of specific interest</i>			
<i>Monoarthritis</i>			
24. At the diagnosis of acute monoarthritis, CR of the involved joint should be performed, with two perpendicular views.	9.35 (\pm 1.04)	3	C
25. At the diagnosis of acute monoarthritis, comparative CR of the contralateral joint is unnecessary.	8.50 (\pm 2.39)	4	D
26. In patients with persistent neck pain related to JIA, MRI is preferable over CR.	9.60 (\pm 0.68)	4	D
27. When MRI is unavailable, CR is recommended only for the cervical spine and should consist only in a lateral view.	8.80 (\pm 1.56)	4	D
28. In patients with JIA who have neurological symptoms of spinal cord compression and neck pain, cervical MRI must be performed, on an emergency basis.	9.80 (\pm 0.52)	3	C
29. CR of the TMJs is not recommended when cross-sectional imaging is available.	9.20 (\pm 1.47)	3	C
30. Routine CR of the hip joint is not recommended in patients with pJIA.	9.25 (\pm 1.02)	3	C
31. When CR of a symptomatic hip joint is performed, a single view should be obtained, i.e., either an antero-posterior view or a frog leg view.	9.05 (\pm 1.28)	4	D

JIA juvenile idiopathic arthritis, CR conventional radiography, oJIA oligoarticular juvenile idiopathic arthritis, pJIA polyarticular juvenile idiopathic arthritis, RF rheumatoid factor, ACPA anti-citrullinated protein antibody, ERA enthesitis-related arthritis, TMJ temporo-mandibular joint

*Symptomatic joints: swollen and/or painful joints, and/or joints with motion range limitation

cases, respectively [31]. Our literature review identified some data on the best times for CR. One study suggested a higher risk of radiographic progression within the first year after disease onset [51]. The experts felt that CR contributed to ease the transition from paediatric to adult healthcare [96].

13. *Routine CR of other joints is not recommended.* No data were found on which to base specific recommendations.

14. *During the follow-up of RF/ACPA-negative pJIA with adverse prognostic factors, CR should be performed as for RF/ACPA-positive pJIA* (see recommendation #12).

15. *During the follow-up of RF/ACPA-negative pJIA without adverse prognostic factors, the use of CR is at the discretion of the physician.* No scientific data were available on which to base specific recommendations.

16. and 17. *CR can be repeated in patients who remain symptomatic* longer than 3 months. In patients with structural damage, the selection and timing of specific imaging techniques during follow-up is guided by clinical considerations.* The experts emphasised the need for careful attention to joints with active disease. In prospective studies, the time interval separating CR assessments of the same joints ranged from 8 months to 24 years. The 3-month interval in this recommendation was based on expert opinion.

Enthesitis-related arthritis (ERA)

18. In patients with axial ERA, CR of the spine and hip joints should be performed only when needed for the differential diagnosis. Axial manifestations may arise at the spine, hips and sacro-iliac joints. A radiographic view specifically designed to assess the sacro-iliac joints is not recommended, as the results are not interpretable in skeletally immature patients and radiation exposure is significant [20]. In patients with axial inflammatory pain, MRI (for both sacro-iliac and hip joints) and US (for the hip joint) may be more relevant [67].

19. *During the follow-up of axial ERA, CR should be considered only for the hip joints, depending on the clinical course and availability of US and/or MRI.* ERA is associated with a high prevalence of hip joint arthritis [30, 56, 58–60]. MRI or US are non-irradiating methods capable of detecting hip joint effusion; in addition, MRI can detect bone oedema. Therefore, in the future, MRI and US may deserve consideration as first-line imaging techniques. CR, however, is appropriate for monitoring known structural damage and deformities.

20. and 21. *CR is not recommended for multifocal enthesitis. In patients with isolated enthesitis, CR can be*

considered as a tool for establishing the differential diagnosis. When isolated enthesitis is suspected, CR may contribute to the differential diagnosis (e.g. with post-traumatic changes or osteochondritis); otherwise, CR is unhelpful for assessing peri-articular manifestations.

Psoriatic juvenile arthritis (jPsA)

22. *No specific recommendation can be made about CR in juvenile psoriatic arthritis.* Scientific data are scarce [62–66, 68]. The definition of this entity is still debated [68]. Traditionally, two subtypes are described, an axial inflammatory disease resembling axial ERA and a peripheral joint disease resembling oJIA [66].

23. Guidance may be taken from the recommendations above, depending on the clinical presentation, or from recommendations issued for adults.

Situations of specific interest

Monoarthritis 24. *At the diagnosis of acute monoarthritis, CR of the involved joint should be performed, with two perpendicular views.* The French Society for Radiology [90] strongly recommends CR of any site of focal bone pain in paediatric patients, with the goal of excluding a tumour, osteomyelitis, or a haematological malignancy [34, 97].

25. *At the diagnosis of acute monoarthritis, comparative CR of the contralateral joint is unnecessary.* Because cartilage thickness varies within individuals, comparison to the healthy contra-lateral joint is uninformative [26, 33].

Cervical spine 26. *In patients with persistent neck pain related to JIA, MRI is preferable over CR.*

27. *When MRI is unavailable, CR is recommended only for the cervical spine and should consist only of a lateral view.*

28. *In patients with JIA who have neurological symptoms of spinal cord compression and neck pain, cervical MRI must be performed, on an emergency basis.*

In a cohort study of oJIA, 2.4 % of patients had cervical spine damage at the diagnosis [35]. Cervical spine erosions and ankylosis are common in advanced pJIA [42, 71]. Evidence-based data are too scarce to recommend any specific pattern of radiological follow-up. Atlanto-axial diastasis may be normal in paediatric patients, and dynamic CR is therefore irrelevant. MRI is the most sensitive imaging technique, and is mandatory when spinal cord compression is suspected [98].

Temporomandibular joints 29. *CR of the TMJs is not recommended when cross-sectional imaging is available.*

TMJ damage is common in JIA, with the prevalence ranging across studies from 17 % to 87 % [73]. The TMJ cartilage is thin and condylar erosions therefore develop early. The panoramic radiograph is often normal at disease onset.

Cross-sectional imaging offers better diagnostic performance. Imaging of the TMJs is not usually performed on a routine basis but is required in the event of pain, mouth-opening limitation or audible cracking of the TMJs [74, 76–81, 83, 84]. MRI is considered the best imaging technique, although distinguishing the normal appearance from abnormal changes can be challenging [99, 100]. Cone-beam computed tomography allows three-dimensional reconstructions [101]. The usefulness of US TMJ imaging is under debate [77, 102].

Hip joint 30. *Routine CR of the hip joint is not recommended in patients with pJIA.*

31. *When CR of a symptomatic hip joint is performed, a single view should be obtained, i.e. either an antero-posterior view or a frog leg view.*

In RF/ACPA-positive pJIA, hip joint damage is common [48] but CR of the hip joint is associated with a high level of ionising radiation exposure, so the hip is not among the joints for which routine CR is recommended. When available, MRI should be performed instead of, or in addition to, CR. If CR is performed, either an antero-posterior or a frog leg view is recommended, to visualise both hip joints and to allow the detection of bone erosions and/or avascular necrosis.

Discussion

CR is the most widely available imaging procedure worldwide. In paediatric patients, this advantage should be weighed against the heightened risks of radiation exposure and difficulty in interpreting joint radiographs before skeletal maturity is achieved. In addition, in JIA, radiographically visible joint damage takes time to develop, limiting the usefulness of CR. Specific recommendations about CR in paediatric patients are therefore needed, a fact that prompted the present work.

Obstacles to the development of recommendations about CR in JIA included the paucity of strong evidence about structural disease progression in JIA and the pooling of JIA subtypes in many studies. The low incidence of JIA contributes to explain the dearth of data. To maximise the usefulness of our recommendations to all physicians caring for patients with JIA, we focussed on CR and separated the five non-systemic, non-undifferentiated subtypes of JIA. Importantly, these recommendations are based not only on recently published data, but also, in many cases, on expert opinion, due to the paucity of paediatric studies. As a result, many of our recommendations are low grade, and in some cases obtaining guidance from recommendations for adults would seem to be the only option. However, the level of agreement among the multidisciplinary experts sitting on our panel was high.

Structural damage requires evaluation in JIA, especially in pJIA and extended oJIA, which carry the highest risk of adverse outcomes. In the treatment plans for pJIA developed by the CARRA, CR changes are considered an important outcome and their yearly assessment is suggested [55]. However, the risk associated with exposure to ionising radiation during CR is of major concern, as pointed out by the representative of the patient organisation during our study. Little evidence is available on which to base an objective quantification of this risk. Our experts considered that the risk was substantial for CR of the pelvis and lumbar spine but was too small at peripheral sites to constitute an argument against using CR. To minimise radiation exposure, the experts recommended having CR performed at centres with expertise in paediatric radioprotection.

Research is needed in a broad range of areas to fill the knowledge gaps we identified when developing our recommendations (Box 2). More specifically, most paediatric clinical trials failed to assess potential treatment effects on structural damage. Also, data on structural damage just before the transition to adult healthcare are needed, since treatment recommendations for adults are based on structural damage.

Box 2: Research agenda

-
- Follow-up of a cohort of patients with recent-onset RF/ACPA-positive polyarticular JIA, with annual CR for 10 years to identify predictors of structural joint damage
 - Comparison of radiographic disease progression in oligoarticular JIA in patients with and without antinuclear antibodies
 - Comparison of joint MRI, US, and CR as tools for detecting structural damage in patients younger than 5 years of age
 - Evaluation of joint damage at the transition from paediatric to adult healthcare in each JIA subtype
 - Improvement of the definition of juvenile psoriatic arthritis, to obtain homogeneous populations for studies of imaging techniques
-

We considered neither MRI nor US, both of which are under evaluation in JIA. Both are non-irradiating, and US is also widely available and inexpensive, although it requires specific training. US is now performed almost routinely in adults with joint disease. In paediatric patients, however, differentiating normal from abnormal findings by MRI and US can be challenging [100, 103]. Furthermore, very few physicians are specifically trained in paediatric US. The OMERACT and Health-e-Child Radiology groups are currently working together to standardise MRI protocols and interpretation in JIA [104–106].

In conclusion, CR still appears relevant in many situations in patients with JIA. CR is a widely available and inexpensive investigation that has an acceptable safety profile and can provide essential information about the structural course of the disease. Until validation studies of other imaging techniques, such as MRI and US, are completed, CR will remain

the investigation of reference for assessing structural joint damage in patients with JIA.

Acknowledgements The authors would like to acknowledge : Dr Bouchra Amine (Salé, Morocco), Prof. Nathalie Boutry (Lille, France), Prof. Rolando Cimaz (Florence, Italy), Prof. Bernard Combe (Montpellier, France), Dr Véronique Despert (Rennes, France), M William Fahy (KOURIR, non-profit organisation, France), Dr Laurence Goumy (Angers, France), Prof. Michael Hofer (Lausanne, Switzerland), Dr Laëtitia Houx (Brest, France), Dr Sylvie Jean (Rennes, France), Dr Valérie Merzoug (Paris, France), Mme Céline Obert (KOURIR), Prof. Michel Panuel (Marseille, France), Prof. Samira Rostom (Salé, Morocco), Prof. Jean Sibilia (Strasbourg, France); and Pr Hubert Ducou Le Pointe, (French Society for Pediatric Radiology).

Funding This study has received funding by the Société Française de Rhumatologie (French Society for Rheumatology).

Compliance with ethical standards

Guarantor The scientific guarantor of this publication is Prof Valérie Devauchelle-Pensec.

Conflict of interest The authors of this manuscript declare no relationships with any companies.

Statistics and biometry No complex statistical methods, were necessary for this paper.

Ethical approval Institutional Review Board approval was not required; the methodology entirely relies on literature review and expert opinion.

Informed consent Informed consent was not required because no human subjects were involved.

Methodology

- Retrospective
- Literature review, and expert consensus seeking through a Delphi process
- Performed at one institution

Open Access This article is distributed under the terms of the Creative Commons Attribution 4.0 International License (<http://creativecommons.org/licenses/by/4.0/>), which permits unrestricted use, distribution, and reproduction in any medium, provided you give appropriate credit to the original author(s) and the source, provide a link to the Creative Commons license, and indicate if changes were made.

References

1. Prakken B, Albani S, Martini A (2011) Juvenile idiopathic arthritis. *Lancet Lond Engl* 377:2138–2149
2. Petty RE, Southwood TR, Manners P et al (2004) International League of Associations for Rheumatology classification of juvenile idiopathic arthritis: second revision, Edmonton, 2001. *J Rheumatol* 31:390–392
3. Martini A (2012) It is time to rethink juvenile idiopathic arthritis classification and nomenclature. *Ann Rheum Dis* 71:1437–1439
4. Deslandre C (2016) Juvenile idiopathic arthritis: Definition and classification. *Arch Pediatr* 23(4):437–41

5. Mason T, Reed AM, Nelson AM, Thomas KB (2005) Radiographic progression in children with polyarticular juvenile rheumatoid arthritis: a pilot study. *Ann Rheum Dis* 64:491–493
6. Ravelli A, Martini A (2003) Early predictors of outcome in juvenile idiopathic arthritis. *Clin Exp Rheumatol* 21:S89–S93
7. Southwood T (2008) Juvenile idiopathic arthritis: clinically relevant imaging in diagnosis and monitoring. *Pediatr Radiol* 38(Suppl 3):S395–S402
8. Breton S, Jousse-Joulin S, Finel E et al (2012) Imaging approaches for evaluating peripheral joint abnormalities in juvenile idiopathic arthritis. *Semin Arthritis Rheum* 41:698–711
9. Nielsen S, Ruperto N, Gerloni V et al (2008) Preliminary evidence that etanercept may reduce radiographic progression in juvenile idiopathic arthritis. *Clin Exp Rheumatol* 26:688–692
10. Harel L, Wagner-Weiner L, Poznanski AK et al (1993) Effects of methotrexate on radiologic progression in juvenile rheumatoid arthritis. *Arthritis Rheum* 36:1370–1374
11. Ravelli A, Viola S, Ramenghi B et al (1998) Radiologic progression in patients with juvenile chronic arthritis treated with methotrexate. *J Pediatr* 133:262–265
12. Devauchelle-Pensec V, Josseume T, Samjee I et al (2008) Ability of oblique foot radiographs to detect erosions in early arthritis: results in the ESPOIR cohort. *Arthritis Rheum* 59:1729–1734
13. Gaujoux-Viala C, Gossec L, Cantagrel A et al (2014) Recommendations of the French Society for Rheumatology for managing rheumatoid arthritis. *Jt Bone Spine Rev Rhum* 81:287–297
14. Colebatch AN, Edwards CJ, Østergaard M et al (2013) EULAR recommendations for the use of imaging of the joints in the clinical management of rheumatoid arthritis. *Ann Rheum Dis* 72:804–814
15. Brožek JL, Akl EA, Compalati E et al (2011) Grading quality of evidence and strength of recommendations in clinical practice guidelines part 3 of 3. The GRADE approach to developing recommendations. *Allergy* 66:588–595
16. GRADE, GRADE home. Available via <http://www.gradeworkinggroup.org/>. Accessed 19 May 2016
17. Dougados M, Betteridge N, Burmester GR et al (2004) EULAR standardised operating procedures for the elaboration, evaluation, dissemination, and implementation of recommendations endorsed by the EULAR standing committees. *Ann Rheum Dis* 63:1172–1176
18. van der Heijde D, Aletaha D, Carmona L et al (2015) 2014 Update of the EULAR standardised operating procedures for EULAR-endorsed recommendations. *Ann Rheum Dis* 74:8–13
19. Stoll ML, Bhole R, Dempsey-Robertson M, Punaro M (2010) Spondyloarthritis in a pediatric population: risk factors for sacroiliitis. *J Rheumatol* 37:2402–2408
20. Pagnini I, Savelli S, Matucci-Cerinic M et al (2010) Early predictors of juvenile sacroiliitis in enthesitis-related arthritis. *J Rheumatol* 37:2395–2401
21. Oxford Centre for Evidence Based Medicine Levels of Evidence (2009). Available via <http://www.cebm.net>. Acced 19th May 2016
22. Chan MO, Petty RE, Guzman J, ReACCh-Out Investigators (2016) A Family History of Psoriasis in a First-degree Relative in Children with JIA: to Include or Exclude? *J Rheumatol* 43:944–947
23. Ravelli A, Consolaro A, Schiappapietra B, Martini A (2015) The conundrum of juvenile psoriatic arthritis. *Clin Exp Rheumatol* 33: S40–S43
24. Ravelli A, Varnier GC, Oliveira S et al (2011) Antinuclear antibody-positive patients should be grouped as a separate category in the classification of juvenile idiopathic arthritis. *Arthritis Rheum* 63:267–275
25. Kavanaugh A, van der Heijde D, Beutler A et al (2016) Radiographic Progression of Patients With Psoriatic Arthritis Who Achieve Minimal Disease Activity in Response to Golimumab Therapy: Results Through 5 Years of a Randomized, Placebo-Controlled Study. *Arthritis Care Res* 68: 267–274
26. Poznanski AK (1991) Useful measurements in the evaluation of hand radiographs. *Hand Clin* 7:21–36
27. Lipinska J, Brózik H, Stanczyk J, Smolewska E (2012) Anticitrullinated protein antibodies and radiological progression in juvenile idiopathic arthritis. *J Rheumatol* 39:1078–1087
28. Selvaag AM, Flatø B, Dale K et al (2006) Radiographic and clinical outcome in early juvenile rheumatoid arthritis and juvenile spondyloarthropathy: a 3-year prospective study. *J Rheumatol* 33:1382–1391
29. van Rossum MAJ, Boers M, Zwinderman AH et al (2005) Development of a standardized method of assessment of radiographs and radiographic change in juvenile idiopathic arthritis: introduction of the Dijkstra composite score. *Arthritis Rheum* 52:2865–2872
30. Flatø B, Smerdel A, Johnston V et al (2002) The influence of patient characteristics, disease variables, and HLA alleles on the development of radiographically evident sacroiliitis in juvenile idiopathic arthritis. *Arthritis Rheum* 46:986–994
31. van Rossum MAJ, Zwinderman AH, Boers M et al (2003) Radiologic features in juvenile idiopathic arthritis: a first step in the development of a standardized assessment method. *Arthritis Rheum* 48:507–515
32. Rodriguez-Lozano A-L, Giancane G, Pignataro R et al (2014) Agreement among musculoskeletal pediatric specialists in the assessment of radiographic joint damage in juvenile idiopathic arthritis. *Arthritis Care Res* 66:34–39
33. Rossi F, Di Dia F, Galipò O et al (2006) Use of the Sharp and Larsen scoring methods in the assessment of radiographic progression in juvenile idiopathic arthritis. *Arthritis Rheum* 55:717–723
34. Tafaghodi F, Aghighi Y, Rokni Yazdi H et al (2009) Predictive plain X-ray findings in distinguishing early stage acute lymphoblastic leukemia from juvenile idiopathic arthritis. *Clin Rheumatol* 28:1253–1258
35. Guillaume S, Prieur AM, Coste J, Job-Deslandre C (2000) Long-term outcome and prognosis in oligoarticular-onset juvenile idiopathic arthritis. *Arthritis Rheum* 43:1858–1865
36. Al-Matar MJ, Petty RE, Tucker LB et al (2002) The early pattern of joint involvement predicts disease progression in children with oligoarticular (pauciarticular) juvenile rheumatoid arthritis. *Arthritis Rheum* 46:2708–2715
37. Oen K, Malleson PN, Cabral DA et al (2003) Early predictors of longterm outcome in patients with juvenile rheumatoid arthritis: subset-specific correlations. *J Rheumatol* 30:585–593
38. Oen K, Reed M, Malleson PN et al (2003) Radiologic outcome and its relationship to functional disability in juvenile rheumatoid arthritis. *J Rheumatol* 30:832–840
39. Oen K (2002) Long-term outcomes and predictors of outcomes for patients with juvenile idiopathic arthritis. *Best Pract Res Clin Rheumatol* 16:347–360
40. Bowyer SL, Roettcher PA, Higgins GC et al (2003) Health status of patients with juvenile rheumatoid arthritis at 1 and 5 years after diagnosis. *J Rheumatol* 30:394–400
41. Bertilsson L, Andersson-Gäre B, Fasth A, Forsblad-d’Elia H (2012) A 5-year prospective population-based study of juvenile chronic arthritis: onset, disease process, and outcome. *Scand J Rheumatol* 41:379–382
42. Bertilsson L, Andersson-Gäre B, Fasth A et al (2013) Disease course, outcome, and predictors of outcome in a population-based juvenile chronic arthritis cohort followed for 17 years. *J Rheumatol* 40:715–724
43. Giancane G, Pederzoli S, Norambuena X et al (2014) Frequency of radiographic damage and progression in individual joints in

- children with juvenile idiopathic arthritis. *Arthritis Care Res* 66: 27–33
44. Gilliam BE, Chauhan AK, Low JM, Moore TL (2008) Measurement of biomarkers in juvenile idiopathic arthritis patients and their significant association with disease severity: a comparative study. *Clin Exp Rheumatol* 26:492–497
 45. Doria AS, de Castro CC, Kiss MHB et al (2003) Inter- and intrareader variability in the interpretation of two radiographic classification systems for juvenile rheumatoid arthritis. *Pediatr Radiol* 33:673–681
 46. Maldonado-Cocco JA, García-Morteo O, Spindler AJ et al (1980) Carpal ankylosis in juvenile rheumatoid arthritis. *Arthritis Rheum* 23:1251–1255
 47. Habib HM, Mosaad YM, Youssef HM (2008) Anti-cyclic citrullinated peptide antibodies in patients with juvenile idiopathic arthritis. *Immunol Investig* 37:849–857
 48. Elhai M, Bazeli R, Freire V et al (2013) Radiological peripheral involvement in a cohort of patients with polyarticular juvenile idiopathic arthritis at adulthood. *J Rheumatol* 40:520–527
 49. Mason T, Reed AM, Nelson AM et al (2002) Frequency of abnormal hand and wrist radiographs at time of diagnosis of polyarticular juvenile rheumatoid arthritis. *J Rheumatol* 29: 2214–2218
 50. Flatø B, Lien G, Smerdel A et al (2003) Prognostic factors in juvenile rheumatoid arthritis: a case-control study revealing early predictors and outcome after 14.9 years. *J Rheumatol* 30:386–393
 51. Magni-Manzoni S, Rossi F, Pistorio A et al (2003) Prognostic factors for radiographic progression, radiographic damage, and disability in juvenile idiopathic arthritis. *Arthritis Rheum* 48: 3509–3517
 52. Ozawa R, Inaba Y, Mori M et al (2012) Definitive differences in laboratory and radiological characteristics between two subtypes of juvenile idiopathic arthritis: systemic arthritis and polyarthritis. *Mod Rheumatol Jpn Rheum Assoc* 22:558–564
 53. Omar A, Abo-Elyoun I, Hussein H et al (2013) Anti-cyclic citrullinated peptide (anti-CCP) antibody in juvenile idiopathic arthritis (JIA): correlations with disease activity and severity of joint damage (a multicenter trial). *Jt Bone Spine Rev Rhum* 80: 38–43
 54. Williams RA, Ansell BM (1985) Radiological findings in seropositive juvenile chronic arthritis (juvenile rheumatoid arthritis) with particular reference to progression. *Ann Rheum Dis* 44: 685–693
 55. Ringold S, Weiss PF, Colbert RA et al (2014) Childhood Arthritis and Rheumatology Research Alliance consensus treatment plans for new-onset polyarticular juvenile idiopathic arthritis. *Arthritis Care Res* 66:1063–1072
 56. Chen H-A, Chen C-H, Liao H-T et al (2012) Clinical, functional, and radiographic differences among juvenile-onset, adult-onset, and late-onset ankylosing spondylitis. *J Rheumatol* 39:1013–1018
 57. Rostom S, Amine B, Bensabbah R et al (2008) Hip involvement in juvenile idiopathic arthritis. *Clin Rheumatol* 27:791–794
 58. Flatø B, Hoffmann-Vold A-M, Reiff A et al (2006) Long-term outcome and prognostic factors in enthesitis-related arthritis: a case-control study. *Arthritis Rheum* 54:3573–3582
 59. Jadon DR, Ramanan AV, Sengupta R (2013) Juvenile versus adult-onset ankylosing spondylitis – clinical, radiographic, and social outcomes. a systematic review. *J Rheumatol* 40:1797–1805
 60. Lin Y-C, Liang T-H, Chen W-S, Lin H-Y (2009) Differences between juvenile-onset ankylosing spondylitis and adult-onset ankylosing spondylitis. *J Chin Med Assoc JCMA* 72:573–580
 61. Jaremko JL, Liu L, Winn NJ et al (2014) Diagnostic utility of magnetic resonance imaging and radiography in juvenile spondyloarthritis: evaluation of the sacroiliac joints in controls and affected subjects. *J Rheumatol* 41:963–970
 62. Butbul YA, Tyrrell PN, Schneider R et al (2009) Comparison of patients with juvenile psoriatic arthritis and nonpsoriatic juvenile idiopathic arthritis: how different are they? *J Rheumatol* 36:2033–2041
 63. Flatø B, Lien G, Smerdel-Ramoya A, Vinje O (2009) Juvenile psoriatic arthritis: longterm outcome and differentiation from other subtypes of juvenile idiopathic arthritis. *J Rheumatol* 36:642–650
 64. Huemer C, Malleson PN, Cabral DA et al (2002) Patterns of joint involvement at onset differentiate oligoarticular juvenile psoriatic arthritis from pauciarticular juvenile rheumatoid arthritis. *J Rheumatol* 29:1531–1535
 65. Stoll ML, Nigrovic PA, Gotte AC, Punaro M (2011) Clinical comparison of early-onset psoriatic and non-psoriatic oligoarticular juvenile idiopathic arthritis. *Clin Exp Rheumatol* 29:582–588
 66. Stoll ML, Punaro M (2011) Psoriatic juvenile idiopathic arthritis: a tale of two subgroups. *Curr Opin Rheumatol* 23:437–443
 67. Weiss PF, Xiao R, Biko DM, Chauvin NA (2016) Assessment of Sacroiliitis at Diagnosis of Juvenile Spondyloarthritis by Radiography, Magnetic Resonance Imaging, and Clinical Examination. *Arthritis Care Res* 68:187–194
 68. Tsitsami E, Bozzola E, Magni-Manzoni S et al (2003) Positive family history of psoriasis does not affect the clinical expression and course of juvenile idiopathic arthritis patients with oligoarthritis. *Arthritis Rheum* 49:488–493
 69. Elhai M, Wipff J, Bazeli R et al (2013) Radiological cervical spine involvement in young adults with polyarticular juvenile idiopathic arthritis. *Rheumatol Oxf Engl* 52:267–275
 70. Laiho K, Savolainen A, Kautiainen H et al (2002) The cervical spine in juvenile chronic arthritis. *Spine J Off J North Am Spine Soc* 2:89–94
 71. Endén K, Laiho K, Kautiainen H et al (2009) Subaxial cervical vertebrae in patients with juvenile idiopathic arthritis—something special? *Jt Bone Spine Rev Rhum* 76:519–523
 72. Kjellberg H, Pavlou I (2011) Changes in the cervical spine of children with juvenile idiopathic arthritis evaluated with lateral cephalometric radiographs: a case control study. *Angle Orthod* 81:447–452
 73. Twilt M, Mobergs SMLM, Arends LR et al (2004) Temporomandibular involvement in juvenile idiopathic arthritis. *J Rheumatol* 31:1418–1422
 74. Abramowicz S, Simon LE, Susarla HK et al (2014) Are panoramic radiographs predictive of temporomandibular joint synovitis in children with juvenile idiopathic arthritis? *J Oral Maxillofac Surg Off J Am Assoc Oral Maxillofac Surg* 72:1063–1069
 75. Abramowicz S, Susarla HK, Kim S, Kaban LB (2013) Physical findings associated with active temporomandibular joint inflammation in children with juvenile idiopathic arthritis. *J Oral Maxillofac Surg Off J Am Assoc Oral Maxillofac Surg* 71: 1683–1687
 76. Arvidsson LZ, Smith H-J, Flatø B, Larheim TA (2010) Temporomandibular joint findings in adults with long-standing juvenile idiopathic arthritis: CT and MR imaging assessment. *Radiology* 256:191–200
 77. Müller L, Kellenberger CJ, Cannizzaro E et al (2009) Early diagnosis of temporomandibular joint involvement in juvenile idiopathic arthritis: a pilot study comparing clinical examination and ultrasound to magnetic resonance imaging. *Rheumatol Oxf Engl* 48:680–685
 78. Cedström A-L, Andlin-Sobocki A, Berntson L et al (2013) Temporomandibular signs, symptoms, joint alterations and disease activity in juvenile idiopathic arthritis - an observational study. *Pediatr Rheumatol Online J* 11:37
 79. Górska A, Przystupa W, Rutkowska-Sak L et al (2014) Temporomandibular joint dysfunction and disorders in the development of the mandible in patients with juvenile idiopathic

- arthritis - preliminary study. *Adv Clin Exp Med Off Organ Wroclaw Med Univ* 23:797–804
80. Koos B, Gassling V, Bott S et al (2014) Pathological changes in the TMJ and the length of the ramus in patients with confirmed juvenile idiopathic arthritis. *J Cranio-Maxillo-fac Surg Off Publ Eur Assoc Cranio-Maxillo-fac Surg* 42:1802–1807
 81. Koos B, Twilt M, Kyank U et al (2014) Reliability of clinical symptoms in diagnosing temporomandibular joint arthritis in juvenile idiopathic arthritis. *J Rheumatol* 41:1871–1877
 82. Billiau AD, Hu Y, Verdonck A et al (2007) Temporomandibular joint arthritis in juvenile idiopathic arthritis: prevalence, clinical and radiological signs, and relation to dentofacial morphology. *J Rheumatol* 34:1925–1933
 83. Helenius LMJ, Tervahartiala P, Helenius I et al (2006) Clinical, radiographic and MRI findings of the temporomandibular joint in patients with different rheumatic diseases. *Int J Oral Maxillofac Surg* 35:983–989
 84. Pedersen TK, Kùseler A, Gelineck J, Herlin T (2008) A prospective study of magnetic resonance and radiographic imaging in relation to symptoms and clinical findings of the temporomandibular joint in children with juvenile idiopathic arthritis. *J Rheumatol* 35:1668–1675
 85. Cannizzaro E, Schroeder S, Müller LM et al (2011) Temporomandibular joint involvement in children with juvenile idiopathic arthritis. *J Rheumatol* 38:510–515
 86. Kristensen KD, Stoustrup P, Kùseler A et al (2016) Clinical predictors of temporomandibular joint arthritis in juvenile idiopathic arthritis: A systematic literature review. *Semin Arthritis Rheum* 45:717–732
 87. Colebatch-Bourn AN, Edwards CJ, Collado P et al (2015) EULAR-PreS points to consider for the use of imaging in the diagnosis and management of juvenile idiopathic arthritis in clinical practice. *Ann Rheum Dis* 74:1946–1957
 88. Jadon DR, Sengupta R, Nightingale A et al (2016) Axial Disease in Psoriatic Arthritis study: defining the clinical and radiographic phenotype of psoriatic spondyloarthritis. *Ann Rheum Dis*. <https://doi.org/10.1136/annrheumdis-2016-209853>
 89. Ravelli. (2014) A11: Assessment of Radiographic Progression in Patients With Polyarticular-Course Juvenile Idiopathic Arthritis Treated With Tocilizumab: 2-Year Data From CHERISH - Arthritis & Rheumatology - Wiley Online Library. Available via <http://onlinelibrary.wiley.com/enhanced/doi/10.1002/art.38422>. Accessed 19 May 2016
 90. French Society for Radiology, French Society for Nuclear Medicine (2013) Guide du bon usage des examens d'imagerie médicale. Available via <http://www.sfrnet.org/sfr/professionnels/5-referentiels-bonnes-pratiques/guides/guide-bon-usage-examens-imagerie-medicale/index.phtml>. Accessed 30 Mar 2016
 91. Laor T, Clarke JP, Yin H (2016) Development of the long bones in the hands and feet of children: radiographic and MR imaging correlation. *Pediatr Radiol* 46:551–561
 92. Wallace CA, Giannini EH, Huang B et al (2011) American College of Rheumatology provisional criteria for defining clinical inactive disease in select categories of juvenile idiopathic arthritis. *Arthritis Care Res* 63:929–936
 93. McErlane F, Beresford MW, Baildam EM et al (2013) Validity of a three-variable Juvenile Arthritis Disease Activity Score in children with new-onset juvenile idiopathic arthritis. *Ann Rheum Dis* 72:1983–1988
 94. Consolaro A, Ruperto N, Bazso A et al (2009) Development and validation of a composite disease activity score for juvenile idiopathic arthritis. *Arthritis Rheum* 61:658–666
 95. Brown AK, Quinn MA, Karim Z et al (2006) Presence of significant synovitis in rheumatoid arthritis patients with disease-modifying antirheumatic drug-induced clinical remission: evidence from an imaging study may explain structural progression. *Arthritis Rheum* 54:3761–3773
 96. Foster HE, Minden K, Clemente D et al (2016) EULAR/PreS standards and recommendations for the transitional care of young people with juvenile-onset rheumatic diseases. *Ann Rheum Dis*. <https://doi.org/10.1136/annrheumdis-2016-210112>
 97. Rayen BS, Chapman A (2005) Monoarthritis: remember to ask the child. *Arch Dis Child* 90:69
 98. Joaquim AF, Ghizoni E, Tedeschi H et al (2015) Radiological evaluation of cervical spine involvement in rheumatoid arthritis. *Neurosurg Focus* 38:E4
 99. Kottke R, Saurenmann RK, Schneider MM et al (2015) Contrast-enhanced MRI of the temporomandibular joint: findings in children without juvenile idiopathic arthritis. *Acta Radiol Stockh Swed* 56:1145–1152
 100. Ma GMY, Amirabadi A, Inarejos E et al (2015) MRI thresholds for discrimination between normal and mild temporomandibular joint involvement in juvenile idiopathic arthritis. *Pediatr Rheumatol Online J* 13:53
 101. Farronato G, Garagiola U, Carletti V et al (2010) Change in condylar and mandibular morphology in juvenile idiopathic arthritis: Cone Beam volumetric imaging. *Minerva Stomatol* 59:519–534
 102. Melchiorre D, Falcini F, Kaloudi O et al (2010) Sonographic evaluation of the temporomandibular joints in juvenile idiopathic arthritis(). *J Ultrasound* 13:34–37
 103. Ording Muller L-S, Boavida P, Avenarius D et al (2013) MRI of the wrist in juvenile idiopathic arthritis: erosions or normal variants? A prospective case-control study. *Pediatr Radiol* 43:785–795
 104. Nusman CM, Rosendahl K, Maas M (2016) MRI Protocol for the Assessment of Juvenile Idiopathic Arthritis of the Wrist: Recommendations from the OMERACT MRI in JIA Working Group and Health-e-Child. *J Rheumatol* 43:1257–1258
 105. Nusman CM, Ording Muller L-S, Hemke R et al (2016) Current Status of Efforts on Standardizing Magnetic Resonance Imaging of Juvenile Idiopathic Arthritis: Report from the OMERACT MRI in JIA Working Group and Health-e-Child. *J Rheumatol* 43:239–244
 106. Roth J, Ravagnani V, Backhaus M et al (2016) Preliminary definitions for the sonographic features of synovitis in children. *Arthritis Care Res*. <https://doi.org/10.1002/acr.23130>