



HAL
open science

Diffuse T1-MRI White Matter Volume Decrease in Patients with Sickle Cell Disease

Soyoung Choi, Adam Bush, Matt Borzage, Anand Joshi, Vidya Rajagopalan, Julie Coloigner, Natasha Lepore, Thomas D. Coates, John Wood

► **To cite this version:**

Soyoung Choi, Adam Bush, Matt Borzage, Anand Joshi, Vidya Rajagopalan, et al.. Diffuse T1-MRI White Matter Volume Decrease in Patients with Sickle Cell Disease. 21sy Annual meeting of the Organization for Human Brain Mapping, Apr 2015, Honolulu, HI, United States. . hal-01792279

HAL Id: hal-01792279

<https://hal.science/hal-01792279>

Submitted on 15 May 2018

HAL is a multi-disciplinary open access archive for the deposit and dissemination of scientific research documents, whether they are published or not. The documents may come from teaching and research institutions in France or abroad, or from public or private research centers.

L'archive ouverte pluridisciplinaire **HAL**, est destinée au dépôt et à la diffusion de documents scientifiques de niveau recherche, publiés ou non, émanant des établissements d'enseignement et de recherche français ou étrangers, des laboratoires publics ou privés.


See discussions, stats, and author profiles for this publication at: <https://www.researchgate.net/publication/317640199>


Diffuse T1-MRI White Matter Volume Decrease in Patients with Sickle Cell Disease

Presentation June 2015
DOI: 10.1093/ajph.2015.05.008



CITATIONS
0

9 authors, including


 Seung Eun Choi
University of Southern California
21 PUBLICATIONS 89 CITATIONS
[SEE PROFILE](#)


 David A. Judd
University of Southern California
114 PUBLICATIONS 1,078 CITATIONS
[SEE PROFILE](#)

Some of the authors of this publication are also working on these related projects:

-  Early Brain Development [View project](#)
-  SCD and Brain [View project](#)

READ
7

 Adam Rubin
Stanford University
29 PUBLICATIONS 104 CITATIONS
[SEE PROFILE](#)


 Vijay Rajagopalan
Children's Hospital Los Angeles
22 PUBLICATIONS 373 CITATIONS
[SEE PROFILE](#)

Diffuse T1-MRI White Matter Volume Decrease in Patients with Sickle Cell Disease

Soyoung Choi^{1,3}, Adam Bush¹, Matt Borzage², Anand Joshi³,
Vidya Rajagopalan⁴, Julie Coloigner⁴, Natasha Lepore⁴,
Thomas D Coates⁵, and John C Wood¹



¹Department of Pediatrics and Radiology, Children's Hospital Los Angeles USC, Los Angeles, CA
²Biomedical Engineering, University of Southern California, Los Angeles, CA
³Signal and Image Processing Institution, University of Southern California, Los Angeles, CA
⁴Department of Radiology, Children's Hospital Los Angeles, Los Angeles, CA
⁵Hematology/Oncology, Children's Hospital Los Angeles, Los Angeles, CA



Introduction

Sickle cell disease (SCD) is a genetic blood disorder associated with anemia, chronic vascular damage, overt stroke, silent cerebral infarctions, and early mortality.^{1,2} Patients with SCD have increased cerebral blood flow to compensate for their anemia but nevertheless exhibit regional cerebral hypo-perfusion and neurocognitive decline.^{1,3,4}

Previous volumetric studies in SCD have shown delayed growth, gray matter (GM) loss, white matter (WM) loss, and decreased cortical thickness compared with control subjects.⁵⁻⁸ Diffusion-tensor imaging have demonstrated compromised WM integrity in major fiber pathways diffusely throughout the brain.^{9,10} Further regional investigations of structural outcome could potentially help expand our understanding of the neurobiology of SCD.

Subjects

T1-weighted MRI was obtained on 23 subjects on a 3T Philips Achieva as part of a study on sickle cell disease and neurological outcome. All patients were recruited with informed consent or assent; the study was approved by the Institutional Review Board at Children's Hospital Los Angeles (CCI#11-00083). 14 clinically asymptomatic SCD patients (age=21.6 ± 4.8; F=8, M=6) were compared against 9 ethnically matched control subjects (age=23.0 ± 3.7; F=6, M=3). Exclusion criteria included pregnancy, previous overt stroke, acute chest or pain crisis hospitalization within one month.

Methods

T1-weighted images were processed using BrainSuite (brainsuite.org) in a semi-automated fashion with limited manual correction of the cortical boundaries—minimizing extraneous inclusion of meninges or exclusion of cortex—to extract, classify tissue types, and render 3D-surfaces of the inner and pial cortices. Surface-Volume Registration (SVReg) was used to automatically segment the brain into two separate segmentation schemes. The first segmentation divided the cerebrum into 4 lobes and the second segmentation divided the brain into 90 regions of interest (ROI). (Figure 1) Average cortical thickness, GM volume, and WM volume were calculated for all ROIs. Group comparisons were made using t-tests (p<0.05) using JMP statistical software (Version 10.0, SAS, Cary, North Carolina).

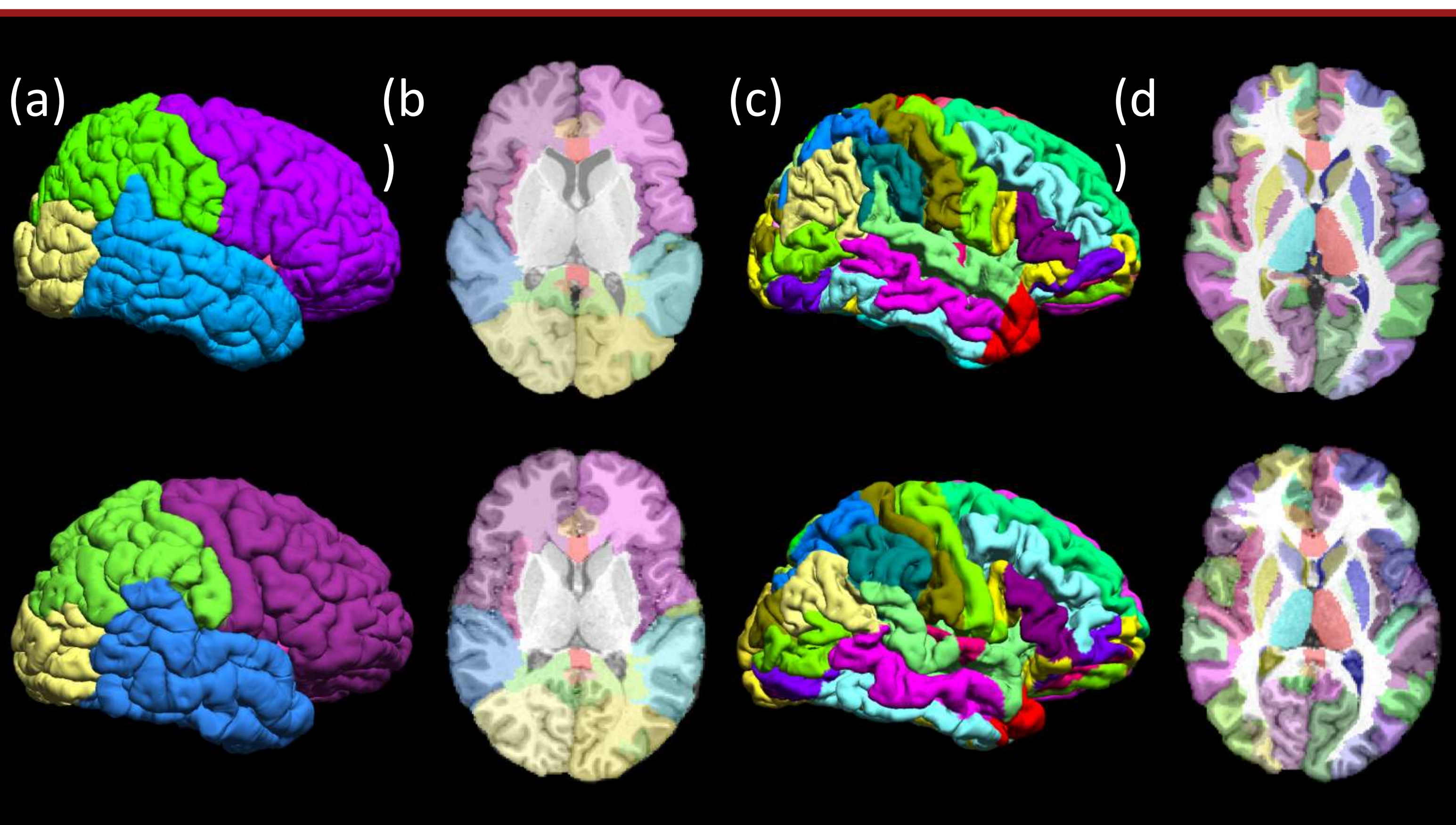


Figure 1. Displays segmentation schemes on atlas brain (top row) and subject registration results of a representative SCD subject (bottom row). (a) Pial surface segmentation of the right hemisphere into 4 lobes. (b) Single trans-axial slice of the brain segmented into 4 lobes, corpus callosum, and insula with exclusion of the subcortex, ventricles, and extracerebral structures. (c) Pial surface segmentation of the right hemisphere into 90 ROIs. (d) Single trans-axial slice of the brain segmented into 90 ROIs. Gyral WM boundary is limited by two opposing sulcal edges of the gyrus from the coronal view.

Results

6 SCD patients had one or more silent infarcts identified on T2 images. Volumetric comparisons showed no differences between SCD patients with silent infarcts and those without.

Brain lobe comparisons: SCD patients showed WM volume loss in comparison to control subjects bilaterally in the frontal, parietal, and temporal lobes, and cerebrum while sparing the occipital lobe. Total volume loss was seen in the right frontal and occipital lobes, and bilaterally in the parietal lobes. SCD patients had greater cortical thickness in the right temporal lobe in comparison to controls but GM volume was not significantly different. (Table 1)

Subparcellated region comparisons: SCD patients exhibited diffuse gyral WM loss in 28 out of 68 cortical regions, located primarily in the frontal, parietal, and temporal lobes. Left insula was the only cortical region where WM volume was greater in SCD patients against control subjects. Of the 20 non-cortical and extra-cerebral regions, WM volume was significantly lower in the left hippocampus, bilateral caudate, and right putamen in SCD patients. GM volume in these regions showed no differences. (Figure 2)

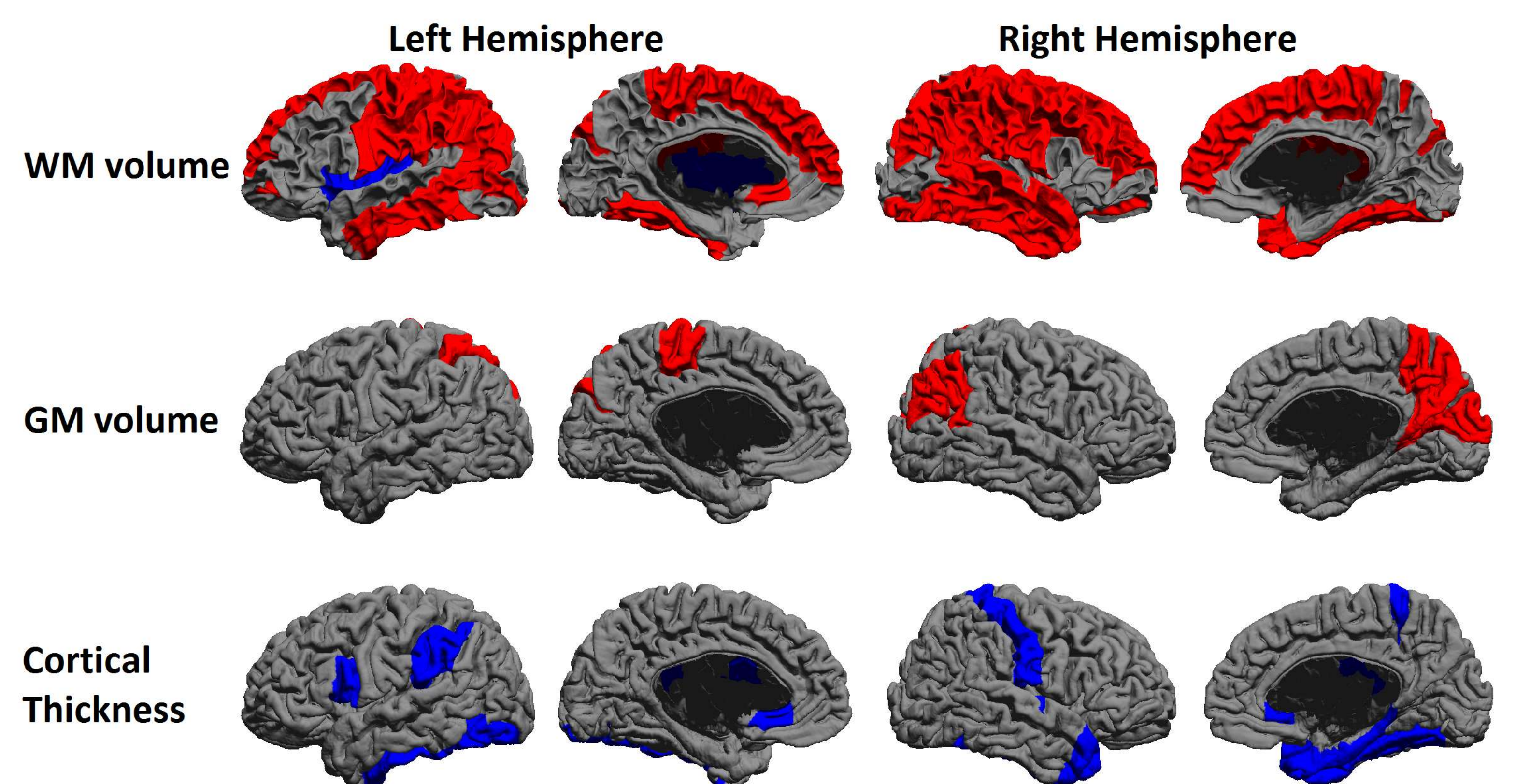


Figure 2: Significant changes in WM volume, GM volume, and cortical thickness displayed on lateral and mesial views of both hemispheres of the atlas template. Red indicates significantly lower values of SCD patients against controls (p<0.05); Blue indicates significantly higher values of SCD patients against controls (p<0.05).

Region	Total volume		GM Volume		WM Volume		Cortical Thickness	
	R	L	R	L	R	L	R	L
Whole Brain	-6.7%				-10.8%	-9.7%		
Frontal					-15.7%	-11.3%		
Parietal	-9.0%	-8.7%			11.0%	-11.0%		
Temporal					-14.8%	-10.2%	+4.6%	+5.0%
Occipital	-9.3%							

Table 1: % difference of significant results (p<0.05) of volume and cortical thickness in SCD patients compared to controls. Lobe ROIs exclude areas of the cingulate, insula, corpus callosum, and subcortex. Whole brain: refers to the cerebrum and excludes the brain stem and cerebellum; R: right; L: left; Red indicates significantly lower values of SCD patients compared to controls; Blue indicates significantly higher.

Conclusions

In SCD, silent cerebral infarcts primarily involve the frontal lobe, followed by the parietal lobe, subcortical nuclei, and temporal lobe, with very few lesions reported in the occipital lobe or cerebellum.^{2,8} We observed a nearly identical pattern for WM volume loss, even though WM volumes were no different in patients with or without silent cerebral infarction. Although we did not identify GM volume loss, our patient population was significantly older than cohorts for whom GM volume loss has been previously described. Further investigation of brain morphological abnormalities in SCD patients will provide insight into disease mechanisms and progression.

References

- Platt OS, Brambilla DJ, Rosse WF, et al. Mortality in sickle cell disease. Life expectancy and risk factors for early death. *N Engl J Med*. 1994;330(23):1639-44. doi:10.1056/NEJM199406093302303.
- DeBaun MR, Armstrong FD, McKinstry RC, Ware RE, Vichinsky E, Kirkham FJ. Silent cerebral infarcts: a review on a prevalent and progressive cause of neurologic injury in sickle cell anemia. *Blood*. 2012;119(20):4587-96. doi:10.1182/blood-2011-02-272682.
- Schatz J, Finke RL, Kellett JM, Kramer JH. Cognitive functioning in children with sickle cell disease: a meta-analysis. *J Pediatr Psychol*. 2002;27(8):739-48. doi:10.1093/jpepsy/27.8.739.
- Rodgers GP, Clark CM, Larson SM, Rapoport SI, Nienhuis AW, Schechter AN. Brain glucose metabolism in neurologically normal patients with sickle cell disease. Regional alterations. *Arch Neurol*. 1988;45(1):78-82. doi:10.1001/archneur.1988.00520250084025.
- Steen RG, Emdinughe T, Hunte M, et al. Brain volume in pediatric patients with sickle cell disease: evidence of volumetric growth delay? *AJNR Am J Neuroradiol*. 2005;26(3):455-462.
- Kirk GR, Haynes MR, Palasis S, et al. Regionally specific cortical thinning in children with sickle cell disease. *Cereb Cortex*. 2009;19(7):1549-56. doi:10.1093/cercor/bhn193.
- Chen R, Arkuszewski M, Krejza J, Zimmerman RA, Herskovits EH, Melhem ER. A Prospective Longitudinal Brain Morphometry Study of Children with Sickle Cell Disease. *AJNR Am J Neuroradiol*. 2014;30(6):509-17.
- Pegelow CH, Macklin E, Moser FG, et al. Longitudinal changes in brain magnetic resonance imaging findings in children with sickle cell disease. *Blood*. 2002;99(8):3014-8.
- Sun B, Brown RC, Hayes L, et al. White matter damage in asymptomatic patients with sickle cell anemia: screening with diffusion tensor imaging. *AJNR Am J Neuroradiol*. 2012;33(11):2043-9. doi:10.3174/ajnr.A3135.
- Balci A, Karazincir S, Beyoglu Y, et al. Quantitative brain diffusion-tensor MRI findings in patients with sickle cell disease. *AJR Am J Roentgenol*. 2012;198(5):1167-74. doi:10.2214/AJR.11.7404.

