



**HAL**  
open science

## **Amebaborne Attilina massiliensis Keratitis, France**

Alexandre Battaini, Bernard La Scola, Gaelle Ho Wang Yin, Louis Hoffart,  
Michel Drancourt

► **To cite this version:**

Alexandre Battaini, Bernard La Scola, Gaelle Ho Wang Yin, Louis Hoffart, Michel Drancourt. Amebaborne Attilina massiliensis Keratitis, France. *Emerging Infectious Diseases*, 2018, 24 (2), pp.387-389. 10.3201/eid2402.170541 . hal-01791632

**HAL Id: hal-01791632**

**<https://hal.science/hal-01791632v1>**

Submitted on 22 Aug 2018

**HAL** is a multi-disciplinary open access archive for the deposit and dissemination of scientific research documents, whether they are published or not. The documents may come from teaching and research institutions in France or abroad, or from public or private research centers.

L'archive ouverte pluridisciplinaire **HAL**, est destinée au dépôt et à la diffusion de documents scientifiques de niveau recherche, publiés ou non, émanant des établissements d'enseignement et de recherche français ou étrangers, des laboratoires publics ou privés.

This project was funded by the One Health Institute and the Wildlife Health Center of University of California, Davis.

### About the Author

Miss Vogel is a veterinary student at University of California Davis School of Veterinary Medicine and works as a laboratory intern in J.F.'s laboratory. Her research interest is the ecology of emerging vectorborne diseases.

### References

1. Parola P, Paddock CD, Socolovschi C, Labruna MB, Mediannikov O, Kernif T, et al. Update on tick-borne rickettsioses around the world: a geographic approach. *Clin Microbiol Rev*. 2013;26:657–702. <http://dx.doi.org/10.1128/CMR.00032-13>
2. Fiorello CV, Straub MH, Schwartz LM, Liu J, Campbell A, Kownacki AK, et al. Multiple-host pathogens in domestic hunting dogs in Nicaragua's Bosawas Biosphere Reserve. *Acta Trop*. 2017;167:183–90. <http://dx.doi.org/10.1016/j.actatropica.2016.12.020>
3. Voltzit OV. A review of neotropical *Amblyomma* species (Acari: Ixodidae). *Acarina*. 2007;15:3–134 [cited 2016 Nov 23]. <http://bibliotecavirtual.minam.gob.pe/biam/bitstream/handle/minam/890/BIV00727.pdf?sequence=1&isAllowed=y>
4. Stephenson N, Blaney A, Clifford D, Gabriel M, Wengert G, Foley P, et al. Diversity of rickettsiae in a rural community in northern California. *Ticks Tick Borne Dis*. 2017;8:526–31. <http://dx.doi.org/10.1016/j.ttbdis.2017.02.014>
5. Roux V, Fournier P-E, Raoult D. Differentiation of spotted fever group rickettsiae by sequencing and analysis of restriction fragment length polymorphism of PCR-amplified DNA of the gene encoding the protein rOmpA. *J Clin Microbiol*. 1996;34:2058–65.
6. Parola P, Vestris G, Martinez D, Brochier B, Roux V, Raoult D. Tick-borne rickettsiosis in Guadeloupe, the French West Indies: isolation of *Rickettsia africae* from *Amblyomma variegatum* ticks and serosurvey in humans, cattle, and goats. *Am J Trop Med Hyg*. 1999;60:888–93. <http://dx.doi.org/10.4269/ajtmh.1999.60.888>
7. Eldin C, Mediannikov O, Davoust B, Cabre O, Barré N, Raoult D, et al. Emergence of *Rickettsia africae*, Oceania. *Emerg Infect Dis*. 2011;17:100–2. <http://dx.doi.org/10.3201/eid1701.101081>
8. Labruna MB, Camargo LMA, Terrasini FA, Ferreira F, Schumaker TT, Camargo EP. Ticks (Acari: Ixodidae) from the state of Rondônia, western Amazon, Brazil. *Syst Appl Acarol*. 2005;10:17–32. <http://dx.doi.org/10.11158/saa.10.1.4>
9. Nunes EC, Vizzoni VF, Navarro DL, Iani FC, Durães LS, Daemon E, et al. *Rickettsia amblyommii* infecting *Amblyomma sculptum* in endemic spotted fever area from southeastern Brazil. *Mem Inst Oswaldo Cruz*. 2015;110:1058–61. <http://dx.doi.org/10.1590/0074-02760150266>
10. Blanco CM, Teixeira BR, da Silva AG, de Oliveira RC, Strecht L, Ogrzewalska M, et al. Microorganisms in ticks (Acari: Ixodidae) collected on marsupials and rodents from Santa Catarina, Paraná and Mato Grosso do Sul states, Brazil. *Ticks Tick Borne Dis*. 2017;8:90–8. <http://dx.doi.org/10.1016/j.ttbdis.2016.10.003>

Address for correspondence: Janet Foley, University of California, Department of Medicine and Epidemiology, 1320 Tupper Hall, Davis, CA 95616, USA; email: jefoley@ucdavis.edu

## Amebaborne *Attilina massiliensis* Keratitis, France

Alexandre Battaini, Bernard La Scola, Gaëlle Ho Wang Yin, Louis Hoffart, Michel Drancourt

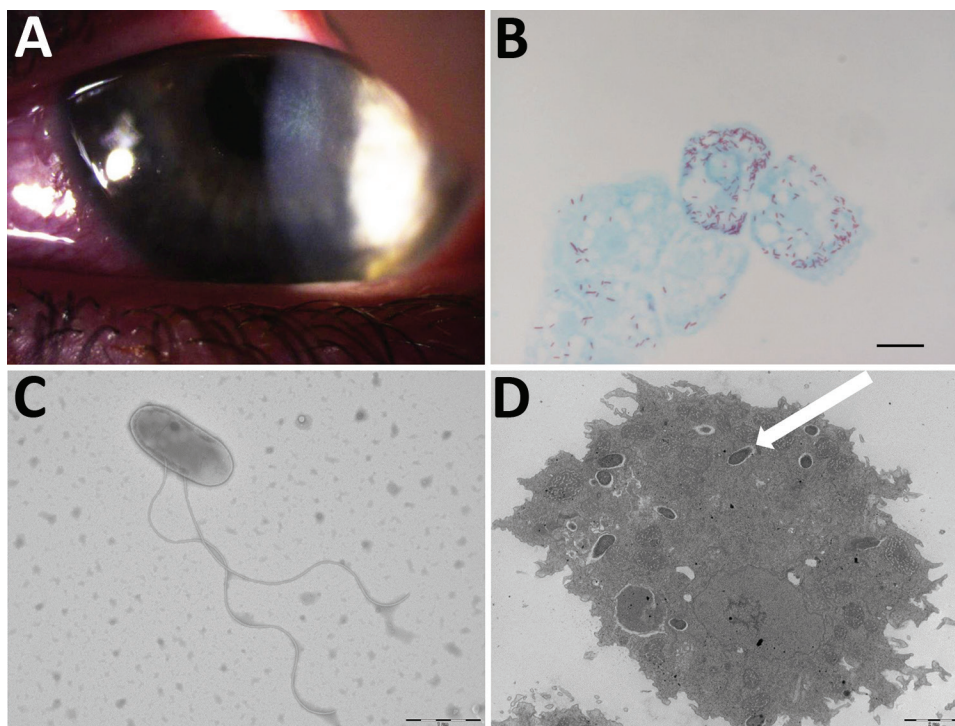
Author affiliations: Aix Marseille Université, Marseille, France (A. Battaini, B. La Scola, M. Drancourt); Aix-Marseille University–APHM, Hôpital de la Timone, Marseille (G.H.W. Yin, L. Hoffart)

DOI: <https://doi.org/10.3201/eid2402.170541>

We report a case of *Acanthamoeba castellanii* keratitis in a person who wore contact lenses. The amoebae hosted an amoeba-resistant bacterial symbiont, provisionally named “*Attilina massiliensis*,” a yet undescribed  $\alpha$ -Proteobacterium.

Amebal keratitis is an aggressive ocular infection that can lead to blindness (1). It is usually associated with wearing soft contact lenses; Dart et al. documented that in countries with a high prevalence of contact lens wear, 85%–88% of *Acanthamoeba* keratitis cases occurred in contact lens users (1). These amoebae host amoeba-resistant bacteria, and increase their pathogenicity to the host (2). Amoeba hosting intra-amebal microorganisms have been rarely documented in cases originating in contaminated contact lenses (3) and never in mixed keratitis. We report a case of mixed amoeba–amebal-resistant bacterial keratitis.

A 17-year-old woman who wore contact lenses consulted the ophthalmology department of the clinic associated with Hôpital de la Timone, Marseille, France, in July 2016, after experiencing 1 month of keratoconjunctivitis symptoms related to an undocumented clinical diagnosis of herpes virus keratitis of the left eye. The patient had been prescribed a 1-week treatment with valacyclovir (3×/d) and a corneal dressing. Examination of the left eye showed 4/10 visual acuity; the right eye was normal. Slit-lamp examination showed a central radial keratoneuritis, central corneal edema, central diffuse infiltrate, and a punctate superficial keratitis with no predescemetic precipitates and no satellite lesions (Figure). The patient was admitted to the hospital and was administered hourly topical treatments of polyhexamethylene biguanide eye drops, hexamidine, and 1% atropine. The patient, whose diagnosis was early-stage *Acanthamoeba* keratitis infection, was discharged after 5 days of treatment; a corneal swab sample at discharge was negative for herpes virus, varicella zoster virus, adenovirus, enterovirus, cytomegalovirus, and *Chlamydia trachomatis*. Follow-up 7 days later yielded reduced symptoms. We followed up on the patient biweekly and slowly tapered drugs over 4 months; the previously negative



**Figure.** Results of testing for a 17-year-old woman with keratoconjunctivitis symptoms, Marseille, France, July 2016. A) Slit-lamp optic microscopic photograph of left eye infected with pseudo-dendritic keratitis associated with *Acanthamoeba castellanii*-*Attilina massiliensis* ocular infection. B) Microscopic aspect of *A. castellanii* ameba infected by "*A. massiliensis*" from corneal swab sample. Scale bar indicates 1  $\mu$ m. C) Optic microscopy image of flagellated, free-living "*A. massiliensis*" from swab sample. Scale bar indicates 1  $\mu$ m. D) Electron microscopy image of the ameba containing the "*A. massiliensis*" endosymbiont, stained by using Gimenez staining (white arrow). Scale bar indicates 2  $\mu$ m.

pathogen tests remained negative. However, culture yielded *Corynebacterium ureicelerivorans*, identified on the basis of a 98.7% partial *rpoB* gene sequence similarity with the reference sequence (GenBank accession no. FJ392018.1), *Acanthamoeba castellanii*, identified on the basis of a 99% 18S rRNA gene sequence similarity with reference genotype T4 (GenBank accession no. U07416.1). Further culture of the amebal isolate in sterile peptone-yeast-extract-glucose broth (Culture-Top, Courtaboeuf, France) by using both optic microscopy and electron microscopy (Figure) yielded an intra-amebal *Holosporaceae* bacterium observed in the cytoplasm of the ameba. This symbiont, a yet undescribed  $\alpha$ -Proteobacterium of the family of *Holosporaceae* that had been provisionally named "*Attilina massiliensis*," was identified on the basis of a 100% 16S rRNA gene similarity with the reference sample (GenBank HM138368). After subculture, this "*A. massiliensis*" isolate was shown to be flagellated and highly mobile. Moreover, it was shown to lyse the *A. castellanii* Neff strain (ATCC 30010), an observation suggesting motility-linked pathogenicity. Culturing the lens storage case yielded *Serratia liquefaciens* and *Stenotrophomonas maltophilia*, identified by matrix-assisted laser desorption/ionization time-of-flight mass spectrometry (4).

In this patient, mixed *C. ureicelerivorans*, *A. castellanii*, and "*A. massiliensis*" keratitis was firmly documented by the isolation and culture of the pathogens identified by using appropriate controls and validated protocols. The fact that we had never documented such an infection in our laboratory excludes mere false-positive results caused by contamination.

*C. ureicelerivorans* has mainly been reported to cause septicemia, not ophthalmologic infections (5,6). Its sources and potential relationships with waterborne amoebae are unknown. *Acanthamoeba* spp. amoebae cause severe keratitis, which may cause visual loss (1). *Acanthamoeba* spp. amoebae are ubiquitous in tap water (7). Tap water could be a source of contamination of contact lenses through the wearer's handwashing habit before lens manipulation (8). Wide varieties of amoebae have been documented in contaminated contact lenses, eventually leading to amebal keratitis outbreaks (9).

Culturing an *A. castellanii* ameba isolated from a diseased cornea yielded "*A. massiliensis*," which we isolated once 8 years ago from an *Acanthamoeba polyphaga* ameba collected from a contact lens storage case that belonged to a patient unrelated to the case-patient we report here. The potential for this emerging ameba-resistant bacterium to cause keratitis remains to be analyzed, but we observed that this mobile symbiont lysed the reference amebal strain, demonstrating its cytopathogenicity. Also, ameba-resistant organisms do comprise acknowledged opportunistic pathogens (2), and corneal toxicity was previously reported as significantly higher for *Acanthamoeba*-hosting endosymbionts (10). This investigation illustrates that amoebae present in cases of keratitis may shelter organisms that should be provisionally regarded as potential opportunistic pathogens under these circumstances.

This study was supported by IHU Méditerranée Infection, Marseille, France.

## About the Author

Dr. Battaini is a laboratory resident at Aix Marseille University, Marseille, France, with particular interest in the prevention of corneal infection in contact lens wearers.

## References

1. Dart JK, Saw VP, Kilvington S. *Acanthamoeba keratitis*: diagnosis and treatment update 2009. *Am J Ophthalmol*. 2009;148:487–499. e2. <http://dx.doi.org/10.1016/j.ajo.2009.06.009>
2. Greub G, Raoult D. Microorganisms resistant to free-living amoebae. *Clin Microbiol Rev*. 2004;17:413–33. <http://dx.doi.org/10.1128/CMR.17.2.413-433.2004>
3. Cohen G, Hoffart L, La Scola B, Raoult D, Drancourt M. Ameba-associated keratitis, France. *Emerg Infect Dis*. 2011;17(7):1306–1308. <https://dx.doi.org/10.3201/eid1707.100826>
4. Seng P, Drancourt M, Gouriet F, La Scola B, Fournier PE, Rolain JM, et al. Ongoing revolution in bacteriology: Routine identification of bacteria by matrix-assisted laser desorption ionization time-of-flight mass spectrometry. *Clin Infect Dis*. 2009;49:543–51. <http://dx.doi.org/10.1086/600885>
5. Yassin AF. *Corynebacterium ureicelerivorans* sp. nov., a lipophilic bacterium isolated from blood culture. *Int J Syst Evol Microbiol*. 2007;57:1200–3. <http://dx.doi.org/10.1099/ijs.0.64832-0>
6. Fernández-Natal MI, Sáez-Nieto JA, Valdezate S, Rodríguez-Pollán RH, Lapeña S, Cachón F, et al. Isolation of *Corynebacterium ureicelerivorans* from normally sterile sites in humans. *Eur J Clin Microbiol Infect Dis*. 2009;28:677–81. <http://dx.doi.org/10.1007/s10096-008-0677-1>
7. Thomas V, Loret JF, Jousset M, Greub G. Biodiversity of amoebae and amoebae-resisting bacteria in a drinking water treatment plant. *Environ Microbiol*. 2008;10:2728–45. <http://dx.doi.org/10.1111/j.1462-2920.2008.01693.x>
8. Bonilla-Lemus P, Ramírez-Bautista GA, Zamora-Muñoz C, Ibarra-Montes MR, Ramírez-Flores E, Hernández-Martínez MD. *Acanthamoeba* spp. in domestic tap water in houses of contact lens wearers in the metropolitan area of Mexico City. *Exp Parasitol*. 2010;126:54–8. <http://dx.doi.org/10.1016/j.exppara.2009.11.019>
9. Bouchoucha I, Aziz A, Hoffart L, Drancourt M. Repertory of free-living protozoa in contact lens solutions. *Cornea*. 2017. <http://dx.doi.org/10.1186/s12886-016-0370-6>
10. Iovieno A, Ledee DR, Miller D, Alfonso EC. Detection of bacterial endosymbionts in clinical acanthamoeba isolates. *Ophthalmology*. 2010;117:445–52, 452.e1–3. <http://dx.doi.org/10.1016/j.jophtha.2009.08.033>

Address for correspondence: Michel Drancourt, URMITE, UMR CNRS 7278, IRD 198, INSERM U1095 IHU Méditerranée Infection, 19-21 Bd Jean Moulin 13005 Marseille, France; email: [michel.drancourt@univ-amu.fr](mailto:michel.drancourt@univ-amu.fr)

## Influenza D Virus in Cattle, Ireland

Orla Flynn, Clare Gallagher, Jean Mooney, Claire Irvine, Mariette Ducatez, Ben Hause, Guy McGrath, Eoin Ryan

Author affiliations: Department of Agriculture, Food, and Marine Laboratory Services, Celbridge, Ireland (O. Flynn, C. Gallagher, J. Mooney, C. Irvine, E. Ryan); École Nationale Vétérinaire de Toulouse, Toulouse, France (M. Ducatez); Kansas State University College of Veterinary Medicine, Manhattan, Kansas, USA (B. Hause); University College Dublin, Dublin, Ireland (G. McGrath)

DOI: <https://doi.org/10.3201/eid2402.170759>

We detected influenza D virus in 18 nasal swab samples from cattle in Ireland that were clinically diagnosed with respiratory disease. Specimens were obtained from archived samples received for routine diagnosis during 2014–2016. Sequencing showed that virus from Ireland clustered with virus sequences obtained in Europe within the D/swine/OK/1334/2011 clade.

Influenza D virus is a recently characterized addition to the family *Orthomyxoviridae*. This virus was originally detected in pigs in the United States (1); however, cattle are now believed to be the main reservoir species (2). Evidence suggests that this virus plays a role in bovine respiratory disease, although experimentally, it caused only mild disease by itself (3). Influenza D virus has been found to be associated with respiratory disease in feedlot cattle (4).

The zoonotic potential of influenza D virus remains unclear; this virus can replicate in ferrets (a model for human influenza infection), and a seroprevalance of 91% was found in persons working closely with cattle (5). However, a study of 3,300 human respiratory samples from Scotland did not detect any influenza D virus–positive samples (6). This virus has been detected in bovine samples in several other countries, including France (7), Italy (8), Japan, and China (9).

Cattle are a major part of the economy in Ireland, where there are ≈7 million (10). To determine whether influenza D virus was present in cattle in Ireland and to investigate epidemiologic factors that might be related to this virus, we conducted a cross-sectional study by using 320 nasal swab specimens from cattle with respiratory disease that were submitted to the Central Veterinary Research Laboratory (Celbridge, Ireland) for routine bovine viral pathogen testing during 2014–2016.

We tested swab specimens by using real-time PCR for influenza D virus as described (1). We selected samples