



HAL
open science

AN UNCOMMON FORM OF A COMMON DISEASE

Nawal El Houmami, Samuel Vernaz, Philippe Minodier, Jean-Luc Jouve,
Didier Raoult, Pierre-Edouard Fournier

► **To cite this version:**

Nawal El Houmami, Samuel Vernaz, Philippe Minodier, Jean-Luc Jouve, Didier Raoult, et al.. AN UNCOMMON FORM OF A COMMON DISEASE. *Journal of Paediatrics and Child Health*, 2017, 53 (7), pp.727-728. 10.1111/jpc.13552 . hal-01774687

HAL Id: hal-01774687

<https://hal.science/hal-01774687v1>

Submitted on 7 May 2018

HAL is a multi-disciplinary open access archive for the deposit and dissemination of scientific research documents, whether they are published or not. The documents may come from teaching and research institutions in France or abroad, or from public or private research centers.

L'archive ouverte pluridisciplinaire **HAL**, est destinée au dépôt et à la diffusion de documents scientifiques de niveau recherche, publiés ou non, émanant des établissements d'enseignement et de recherche français ou étrangers, des laboratoires publics ou privés.

bearing was allowed on the left leg post-operatively, with partial weight bearing on the right leg due to the initial varus angulation. The patient progressed well with physiotherapy and his symptoms of thyrotoxicosis were controlled with pharmacotherapy.

A bone mineral density (BMD) scan was performed post-operatively. BMD was measured at the lumbar spine (0.660 g/cm^2 , Z score -2.4), total body (0.759 g/cm^2 , Z score -3.1) and right radius (0.369 g/cm^2). The patient's chronological age was 13 years 11 months, while a bone age between 14 and 15 years was determined by bilateral hand radiographs per the Greulich and Pyle standards. The patient weighed 43 kg, his height was 167.5 cm, with a body mass index of 15.3.

The effects of thyroid hormones on bone remodelling are well described in adults, with increased bone resorption, decreased BMD and an increased incidence of hip and long bone fractures.^{1–3} However, for children, fragility fractures secondary to Graves' disease are a rare occurrence. The literature describing such fractures in children is limited to two case reports, including a distal radius fracture³ and an oblique non-displaced femur fracture.⁴ Both reports describe a mechanism of injury consistent with the isolated injury, while the patient presented here sustained these fractures after minimal trauma, having fallen from standing height. Of note, 3 months following bilateral neck of femur fractures, the patient also sustained a fracture of the right distal tibia when transferring from a wheelchair, again a mechanism of low energy. This report highlights the significant risk of insufficiency fractures in paediatric patients with Graves' disease even with minimal trauma. We recommend that all paediatric patients with Graves' disease be assessed by their endocrinologist with regards to their risk of insufficiency fracture and that a high index of suspicion for fracture be maintained even for seemingly minor musculoskeletal complaints.

Dr Roseanna Hoswell¹

Dr Matthew L Broadhead^{1,2}

Dr Sandeep Tewari¹

¹Department of Orthopaedics
John Hunter Hospital

²School of Medicine and Public Health
Faculty of Health and Medicine
University of Newcastle
Newcastle, New South Wales
Australia

Conflict of interest: None declared.

References

- Lucidarme N, Ruiz JC, Czernichow P, Leger J. Reduced bone mineral density at diagnosis and bone mineral recovery during treatment in children with Graves' disease. *J. Pediatr.* 2000; **137**: 56–62.
- Numbenjapon N, Costin G, Gilsanz V, Pitukcheewanont P. Low cortical bone density measured by computed tomography in children and adolescents with untreated hyperthyroidism. *J. Pediatr.* 2007; **150**: 527–30.
- Sarezky MD, Corwin DJ, Harrison VS, Jacobstein C. Hyperthyroidism presenting with pathologic fractures. *Pediatrics* 2016; **137**: e20150169.
- Cheruvu S, Alverson BK, Quintos JB. Femoral fracture as a rare presentation of prepubertal graves disease. *J. Pediatr.* 2013; **162**: 429–30.

Dear Editor,

AN UNCOMMON FORM OF A COMMON DISEASE

An 18-month-old boy was referred to our tertiary institution with a 2-month history of a left-sided intermittent painful limp. He had been living on Mayotte, an island located in the Indian Ocean, where he had been vaccinated with *Bacillus Calmette-Guérin* at birth. Physical examination showed no fever, mild tenderness and swelling of the left knee, slightly limited in range of motion. Routine laboratory tests were within normal ranges. Plain radiographs showed a lytic lesion in the epiphysis of the distal femur (Fig. 1a) with no chest abnormality. Magnetic resonance imaging confirmed a large empty signal area within the epiphyseal ossification centre with no transphyseal spread (Fig. 1b). Suspecting a primary subacute epiphyseal osteomyelitis,¹ open surgical drainage and curettage of the osseous lesion were performed. Given the patient's age, bone specimens were inoculated in Bactec PED Plus (Becton Dickinson, Sparks, NV, USA) culture vials to

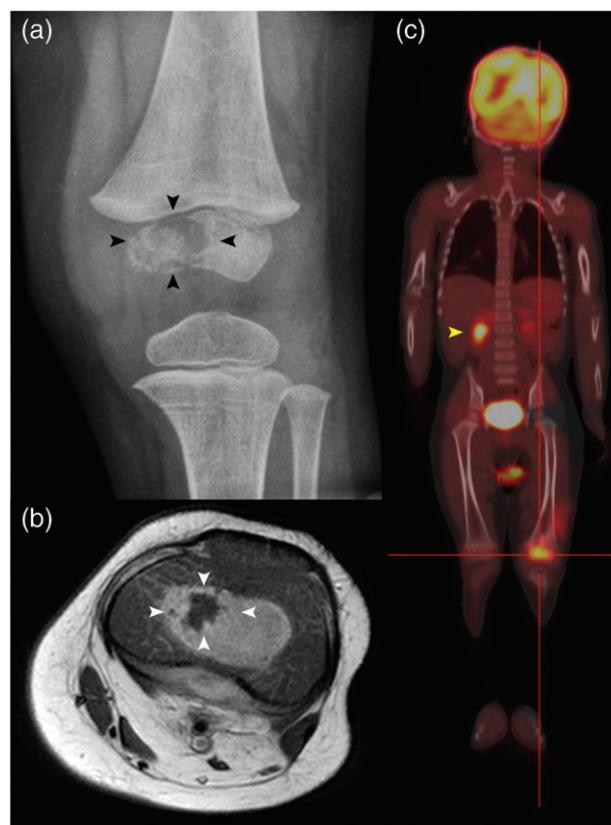


Fig. 1 (a) Plain anteroposterior radiograph of the left knee shows an osteolytic lesion (black arrowheads) at the medial condyle of femoral epiphysis. (b) Axial T1-weighted magnetic resonance image of the left knee shows a large empty signal area in the epiphysis (white arrowheads) surrounded by oedema, and enlarged popliteal nodes. (c) Whole-body ^{18}F -fluorodeoxy-D-glucose (FDG)-hybrid positron emission tomography-computed tomography shows an increased accumulation of FDG in the left distal femoral epiphysis (red target lines) and right adrenal gland area (yellow arrowhead).

search for *Kingella kingae* in addition to routine microbiological cultures.² Broad-spectrum polymerase chain reaction (PCR) targeting the universal 16S rRNA gene and real-time PCR targeting the *cpn60* gene of *K. kingae* were also performed from fresh bone materials. As Mayotte is an endemic tuberculosis area, the search for mycobacteria was done by streaking bone specimens onto specific medium and by using real-time PCR assays targeting *Mycobacterium* species.³ Of these testings, the real-time PCR assay targeting *M. tuberculosis* was positive. Histologically, lesion specimens showed a non-specific inflammatory granuloma. The tuberculin skin test and Interferon-gamma release assay were not contributive. Human immunodeficiency virus antibody testing was negative. A whole-body 18F-fluorodeoxy-D-glucose-hybrid positron emission tomography-computed tomography revealed a disseminated mycobacterial disease spread to the left popliteal, inguinal lymph nodes and right adrenal gland area (Fig. 1c). Subsequently, the patient progressively improved with rifampicin, isoniazid, pyrazinamide and ethambutol for 3 months, followed by rifampicin and isoniazid for 9 months. Three years later, complete healing of the tuberculous lesions with no growth disturbance was observed.

Childhood tuberculosis is a growing public health issue worldwide.⁴ The current shifting in population migration led to the re-emergence of uncommon forms of tuberculosis that are poorly recognised in toddlers, especially in low tuberculosis burden areas where *K. kingae* is the leading cause of osteoarticular infections in children aged 6–36 months.^{2,3} An increase of awareness of clinicians and the use of appropriate imaging and molecular tools are required to establish the diagnosis of tuberculosis at an early stage and avoid long-term complications.

Informed consent was obtained from the child's parents who authorised us to report the case.

Dr Nawal El Houmami^{1,2}

Dr Samuel Vernaz³

Dr Philippe Minodier⁴

Professor Jean-Luc Jouve²

Professor Didier Raoult¹

Professor Pierre-Edouard Fournier¹

¹Aix-Marseille University, Research Unit on Emerging and Infectious Diseases (URMITE), UMR 63, INSERM 1095, CNRS 7278, IRD 198, IHU Mediterranean Infection, Public Hospitals of Marseille

²Department of Pediatric Orthopedics

La Timone Children's Hospital

⁴Department of Pediatric Emergency Medicine

University North Hospital

Marseille and ³Department of Pediatrics

Mamoudzou Hospital

Mayotte

France

Conflict of interest: None declared.

References

- 1 Yoo WJ, Choi IH, Yun YH *et al.* Primary epiphyseal osteomyelitis caused by mycobacterium species in otherwise healthy toddlers. *J. Bone Joint Surg. Am.* 2014; **96**: e145.
- 2 Yagupsky P. *Kingella kingae*: From medical rarity to an emerging paediatric pathogen. *Lancet Infect. Dis.* 2004; **4**: 358–67.
- 3 El Houmami N, Minodier P, Bouvier C *et al.* Primary subacute epiphyseal osteomyelitis caused by *Mycobacterium* species in young children: A modern diagnostic approach. *Eur. J. Clin. Microbiol. Infect. Dis.* 2017; **36**: 771–7.
- 4 Dodd PJ, Gardiner E, Coghlan R, Seddon JA. Burden of childhood tuberculosis in 22 high-burden countries: A mathematical modelling study. *Lancet Glob. Health* 2014; **2**: e453–9.