



**HAL**  
open science

## Case Report: *Arthrocladium fulminans* Arthritis and Osteomyelitis

Abdoulahy Diallo, Céline Michaud, Souandou Tabibou, Maxime Raz, Carla Fernandez, Hubert Lepidi, Pierre-Edouard Fournier, Andreas Stein, Stephane Ranque, Piseth Seng

► **To cite this version:**

Abdoulahy Diallo, Céline Michaud, Souandou Tabibou, Maxime Raz, Carla Fernandez, et al.. Case Report: *Arthrocladium fulminans* Arthritis and Osteomyelitis. *American Journal of Tropical Medicine and Hygiene*, 2017, 96 (3), pp.698-700. 10.4269/ajtmh.16-0185 . hal-01774350

**HAL Id: hal-01774350**

**<https://hal.science/hal-01774350>**

Submitted on 1 Jun 2018

**HAL** is a multi-disciplinary open access archive for the deposit and dissemination of scientific research documents, whether they are published or not. The documents may come from teaching and research institutions in France or abroad, or from public or private research centers.

L'archive ouverte pluridisciplinaire **HAL**, est destinée au dépôt et à la diffusion de documents scientifiques de niveau recherche, publiés ou non, émanant des établissements d'enseignement et de recherche français ou étrangers, des laboratoires publics ou privés.

## Case Report: *Arthrocladium fulminans* Arthritis and Osteomyelitis

Abdoulahy Diallo,<sup>1</sup> Céline Michaud,<sup>1</sup> Souandou Tabibou,<sup>1</sup> Maxime Raz,<sup>2</sup> Carla Fernandez,<sup>3</sup> Hubert Lepidi,<sup>4</sup> Pierre-Edouard Fournier,<sup>4</sup> Andreas Stein,<sup>4,5,6</sup> Stéphane Ranque,<sup>7,8</sup> and Piseth Seng<sup>4,5,6\*</sup>

<sup>1</sup>Service de Médecine Polyvalente, Centre Hospitalier de Mayotte, Mamoudzou, Mayotte; <sup>2</sup>Laboratoire de Biologie Médicale, Centre Hospitalier de Mayotte, Mamoudzou, Mayotte; <sup>3</sup>Service d'Anatomie Pathologique, CHU Félix-Guyon, Saint-Denis, Réunion; <sup>4</sup>Aix Marseille Université, INSERM 1095, CNRS 7278, IRD 198, URMITE, Marseille, France; <sup>5</sup>Assistance Publique–Hôpitaux de Marseille (APHM), Service de Maladies Infectieuses, Centre Hospitalier Universitaire de la Conception, Marseille, France; <sup>6</sup>Centre de Référence des Infections Ostéo-Articulaires (CRIOA) Interrégional Sud-Méditerranée, Hôpital de la Conception, Marseille, France; <sup>7</sup>IP-TPT UMR MD3, Aix Marseille Université, Marseille, France; <sup>8</sup>Parasitologie and Mycologie, Hôpital de la Timone, Assistance Publique–Hôpitaux de Marseille, Marseille, France

**Abstract.** *Arthrocladium fulminans* is the only species in the *Arthrocladium* genus that has been involved in a previous human infection. To date, only one case of *A. fulminans* infection in a patient with GATA-2 immunodeficiency has been reported. We here report the second human case and the first case of septic arthritis and osteomyelitis due to *A. fulminans* in an immunocompetent patient, living in Mayotte, a French island in western Indian Ocean. He was successfully treated with surgical debridement and 6 months of antifungal treatment. This second observation of human invasive disease caused by *A. fulminans* is an additional argument for the pathogenicity of this rare species.

### INTRODUCTION

We report the first case of septic arthritis and osteomyelitis due to *Arthrocladium fulminans* in a previously healthy man. *Arthrocladium fulminans* is the only species in the *Arthrocladium* genus that has been involved in a previous human infection. One case of *A. fulminans* infection in a patient with GATA-2 immunodeficiency has been reported to date.<sup>1</sup>

### CASE PRESENTATION

A 64-year-old man living in Mayotte was admitted to the hospital center in Mayotte, France, for right shoulder joint pain that had lasted 2 months. He had experienced no trauma and his medical history was unremarkable. He is a farmer and bricklayer's assistant, and often carries fair-sized strips of wood on his shoulder. Upon arrival in our center, he did not have a fever and presented an indurated mass with purulent discharge on the right shoulder joint (Figure 1) and enlarged right cervical lymph nodes. The limit of normal anteflexion was approximately 45°. Laboratory tests revealed a normal leukocyte count of  $4.2 \times 10^9/L$  and a normal C-reactive protein level of 6 mg/L. Human immunodeficiency virus serology was negative. Laboratory tests, including complement and immunoglobulin analysis, did not find immunodeficiency. A computed tomography scan of the shoulder showed a soft tissue abscess with joint effusion and an osteolytic lesion of the right acromioclavicular joint (Figure 2). Surgical lavage and debridement were performed, which showed an inflamed synovium, grossly thickened, with areas of bone necrosis. Pathological analysis revealed multiple granulomas with numerous giant cells and characteristic sclerotic bodies in the tissue (Figure 3). Bacterial cultures and 16s rRNA gene sequencing of surgical deep samples were negative. Mycological culture on Sabouraud–chloramphenicol–

gentamicin medium yielded a pure culture of a dematiaceous mold. Microscopic features showed irregular melanized hyphae, but no characteristic fruiting bodies (Figure 4A and B).<sup>2</sup> *Arthrocladium fulminans* was identified by analyzing the internal transcribed spacer 2 (ITS2) regions and the D1-D2 variable regions of the large subunit of the rRNA gene sequence, as previously described.<sup>3</sup> The isolate shared 100% and 99% identity with the gblKT337439.1 and gblKT337444.1 sequences of the *A. fulminans* CBS 136243 strain, respectively. Antifungal susceptibility testing using the E-test assay for this *A. fulminans* isolate showed low minimum inhibitory concentrations (MICs) for itraconazole (0.19 mg/L), voriconazole (0.094 mg/L), and posaconazole (0.032 mg/L), and a relatively higher MIC for amphotericin B (6 mg/L). The patient was treated with oral terbinafine (500 mg/day) combined with itraconazole (200 mg/day) for 6 months. He recovered, the purulent drainage stopped at 7 days, and the skin fistula healed at 4 weeks from the beginning of antifungal treatment. The patient was treated for 6 months and he recovered fully, with normal mobility of the right shoulder without sequelae at the 6-month follow-up.

### DISCUSSION AND CONCLUSION

This article presents the first case of osteoarticular chromoblastomycosis caused by *A. fulminans* in a man living in the French overseas region and department of Mayotte, located in the Comoros Islands and situated in the Indian Ocean off the coast of southeast Africa, between northwestern Madagascar and northeastern Mozambique. Chromoblastomycosis is a subcutaneous mycosis due to pigmented (black) fungi in the dematiaceous group, which is common in tropical climates in different regions of Africa and in the western tropical Indian Ocean.<sup>4,5</sup> These fungi are natural saprophytes and are filamentous, and they can be isolated from dead wood, thorns, and soil. Transmission is direct, usually after trauma from wood debris or plants. It is a disease of adult humans, often arising in farmers or loggers who walk barefoot, and three-quarters of cases occur in the feet and legs.<sup>4,5</sup> The route of transmission of osteoarticular chromoblastomycosis in our case may be direct inoculation, because the patient often carries fair-sized

\*Address correspondence to Piseth Seng, Centre de Référence des Infections Ostéo-Articulaires Interrégional Sud-Méditerranée, Hôpital de la Conception, 147, Boulevard Baille, Marseille, France. E-mail: sengpiseth@yahoo.fr

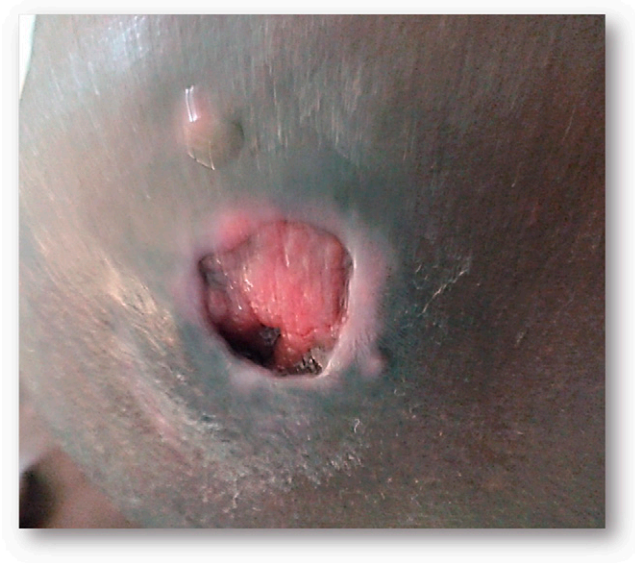

FIGURE 1. An indurated mass with purulent discharge next to the right shoulder joint.

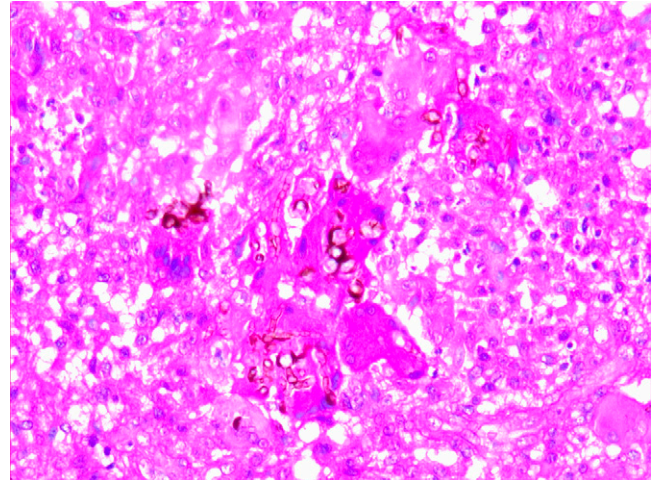


FIGURE 3. Pathological features revealed a significant inflammatory infiltrate with numerous macrophages and multinucleated giant cells. Note *Arthrocladium fulminans* within giant cells of the lesion (hematoxylin–eosin, original magnification  $\times 200$ ).

strips of wood on his shoulder. No bacteremia, no secondary or concomitant infected site was found in our case.

The diagnosis of chromoblastomycosis is based on direct examination, culture, and histopathology. Three infectious agents that are often involved in chromoblastomycosis are *Fonsecaea pedrosoi*, *Phialophora verrucosa*, and *Cladophialophora carrionii*.<sup>4</sup> Identification of etiological agents of chromoblastomycosis from culture of surgical bone biopsies with antifungal susceptibility testing is crucial

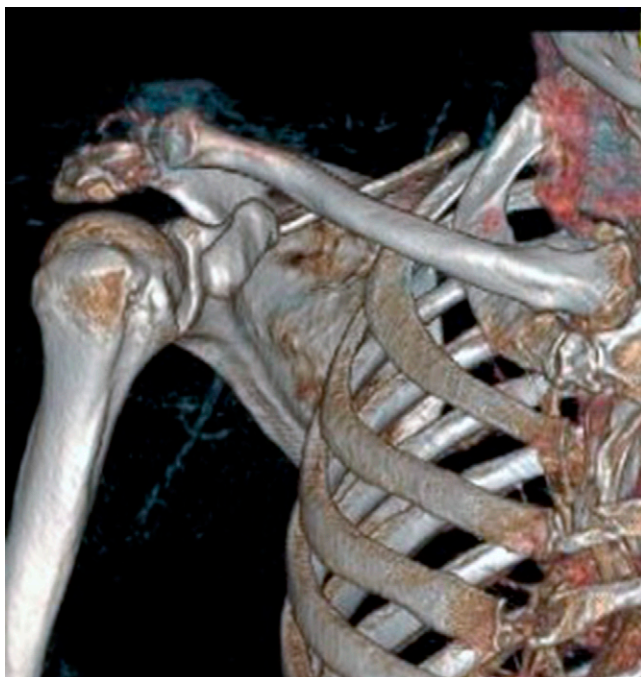
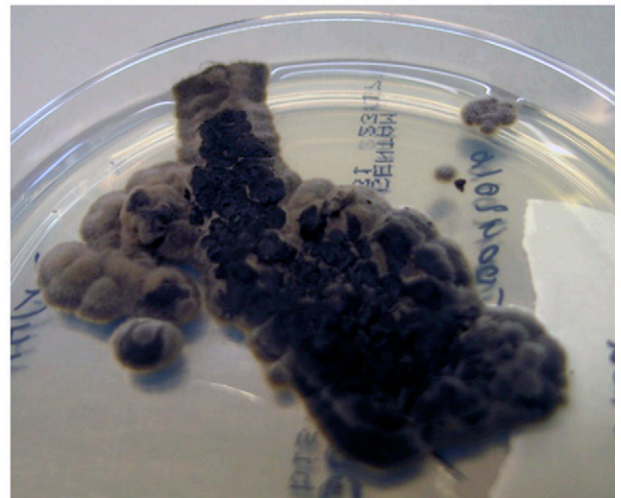
FIGURE 2. A computed tomography scan of the shoulder showing a purulent mass in contact with the acromioclavicular joint, with an osteolytic lesion of the right acromioclavicular articulation.

A



B

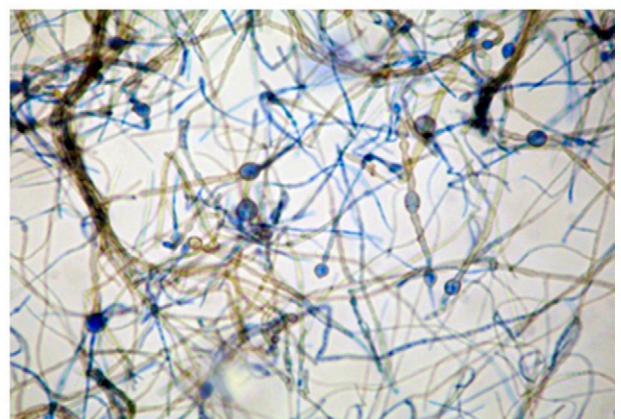


FIGURE 4. (A) Relatively restricted olivaceous colonies on Sabouraud medium. (B) Septate melanized hyphae (Mycetblue™ stain [SRB, Paris, France], original magnification  $\times 400$ ).



to cure these infections, which are difficult to cure and have a high relapse rate.<sup>4</sup> We believe that precise identification of fungi species using molecular identification such as the ITS regions in fungal DNA analysis is necessary for epidemiological purposes and to identify strains with significant virulence to humans.

To our knowledge, few cases of osteoarticular chromoblastomycosis have been reported in the literature, including two cases of arthritis and osteomyelitis caused by *F. pedrosoi*,<sup>6,7</sup> two cases of foot osteomyelitis caused by *P. verrucosa*,<sup>8,9</sup> and one case of nasal osteomyelitis.<sup>10</sup> The combination of surgical debridement and itraconazole therapy has been used to treat cases of *F. pedrosoi* osteomyelitis.<sup>6,7</sup> In a few reported cases, terbinafine was used at high dosage or combined with itraconazole to treat cases of chromoblastomycosis refractory to antifungal treatment.<sup>11</sup> The combination of terbinafine and voriconazole was synergistic in vitro on the *Fonsecaea monophora* strain of refractory chromoblastomycosis.<sup>12</sup>

The genus *Arthrocladium* refers to nonsporulating dematiaceous (black) fungi of the Trichomeriaceae (Chaetothyriales) family. It includes four species: *Arthrocladium caudatum*, *Arthrocladium tropicale*, and *Arthrocladium tardum*, which are rotten wood saprophytes, and the single known strain of the *A. fulminans* species, which was involved in a fatal infection in an immunocompromised patient.<sup>1</sup> We here report the second human case and the first case of septic arthritis and osteomyelitis due to *A. fulminans* in an immunocompetent patient, successfully treated with surgical debridement and 6 months of antifungal treatment. This second observation of human invasive disease caused by *A. fulminans* is an additional argument in favor of the particular pathogenicity of this relatively rare species.

#### CONSENT

Written informed consent was obtained from the patient for publication of this case report and any accompanying images. A copy of the written consent is available for review by the editor-in-chief of this journal.

Received March 8, 2016. Accepted for publication October 18, 2016.

Published online January 9, 2017.

Acknowledgment: We thank Livia Klembarova for his assistance with patient management.

Authors' addresses: Abdoulaye Diallo, Céline Michaud, and Souandou Tabibou, Service de Médecine Polyvalente, Centre Hospitalier de Mayotte, Mamoudzou, Mayotte, E-mails: am.diallo@chmayotte.fr, celine.michaud@chmayotte.fr, and souandou.tabibou@chmayotte.fr. Maxime Raz, Laboratoire de Biologie Médicale, Centre Hospitalier de Mayotte, Mamoudzou, Mayotte, E-mail: maxime.raz@chmayotte.fr. Carla Fernandez, Service d'Anatomie Pathologique, Centre Hospitalier Universitaire de la Réunion, Saint-Denis, Réunion, E-mail: carla.fernandez@chu-reunion.fr. Hubert Lepidi and Pierre-

Edouard Fournier, Aix Marseille Université, INSERM 1095, CNRS 7278, IRD 198, URMITE, Marseille, France, E-mails: hubert.lepidi@ap-hm.fr and pierre-edouard.fournier@univ-amu.fr. Andreas Stein and Piseth Seng, Aix Marseille Université, INSERM 1095, CNRS 7278, IRD 198, URMITE, Marseille, France, Assistance Publique-Hôpitaux de Marseille, Service de Maladies Infectieuses, Centre Hospitalier Universitaire de la Conception, Marseille, France, and Centre de Référence des Infections Ostéo-Articulaires (CRIOA) Interrégional Sud-Méditerranée, Hôpital de la Conception, Marseille, France, E-mails: andreas.stein@ap-hm.fr and sengpiseth@yahoo.fr. Stéphane Ranque, IP-TPT UMR MD3, Aix Marseille Université, Marseille, France, E-mail: stephane.ranque@ap-hm.fr.

#### REFERENCES

- Egenlauf B, Schuhmann M, Giese T, Junghanss T, Kapaun A, Tintelnot K, de Hoog S, Greil J, Richter E, Vehreschild M, Heußel C, Herth F, Kreuter M, 2015. Disseminierte mykose mit *Arthrocladium* species gefährdet patientin mit GATA-2 defekt. *Pneumologie* 69: P111.
- Nascimento MMF, Selbmann L, Sharifynia S, Al-Hatmi AMS, Voglmayr H, Vicente VA, Deng S, Kargl A, Moussa TAA, Al-Zahrani HS, Almaghrabi OA, de Hoog GS, 2016. *Arthrocladium*, an unexpected human opportunist in Trichomeriaceae (Chaetothyriales). *Fungal Biol* 120: 207–218.
- de Hoog GS, Nishikaku AS, Fernandez-Zeppenfeldt G, Padin-González C, Burger E, Badali H, Richard-Yegres N, van den Ende AHGG, 2007. Molecular analysis and pathogenicity of the *Cladophialophora carrionii* complex, with the description of a novel species. *Stud Mycol* 58: 219–234.
- Krzyściak PM, Pindycka-Piaszczyńska M, Piaszczyński M, 2014. Chromoblastomycosis. *Postepy Dermatol Alergol* 31: 310–321.
- Queiroz-Telles F, 2015. Chromoblastomycosis: a neglected tropical disease. *Rev Inst Med Trop Sao Paulo* 57 (Suppl 19): 46–50.
- De Guzman L, Perlman DC, Hubbard CE, 2012. Septic arthritis and osteomyelitis due to the chromoblastomycosis agent *Fonsecaea pedrosoi*. *Am J Orthop* 41: 328–331.
- Karuppall R, Kumaran CM, Marthya A, Manoj Kumar CV, Narayanan MP, Raman RV, Thomas S, 2009. Tibial osteomyelitis due to *Fonsecaea pedrosoi* in an immunocompetent patient: case report. *J Foot Ankle Surg* 48: 569–572.
- El Mouhaddab M, Basraoui D, Ousehal A, Galuia F, 2010. Chronic fistula of the forefoot in a Moroccan man: bone chromomycosis due to *Phialophora verrucosa* [in French]. *Médecine Trop Rev Corps Santé Colon* 70: 181–183.
- Ohashi T, Ohtsuka M, Kikuchi N, Nishiyama K, Suzutani T, Yamamoto T, 2015. A case of chromoblastomycosis caused by *Fonsecaea pedrosoi* in a patient with rheumatoid arthritis. *Int J Rheum Dis* 18: 580–581.
- Penjor D, Khizuan AK, Chong AW, Wong KT, 2014. A case of nasal chromoblastomycosis causing epistaxis. *J Laryngol Otol* 128: 1117–1119.
- Silva-Rocha WP, Cardoso FJR, Colalto W, Melo ASA, Chaves GM, 2013. Clinical improvement of chromoblastomycosis refractory to itraconazole successfully treated with high dose of terbinafine. *J Dermatol* 40: 775–776.
- Daboit TC, Magagnin CM, Heidrich D, Castrillón MR, Mendes SDC, Vettorato G, Valente P, Scroferneker ML, 2013. A case of relapsed chromoblastomycosis due to *Fonsecaea monophora*: antifungal susceptibility and phylogenetic analysis. *Mycopathologia* 176: 139–144.