



HAL
open science

Experimental Assessment of Physician Modified Proximal Scalloped Stent Graft to Extend Proximal Landing Zone in the Aortic Arch

Elsa Madeleine Faure, Ilya Khantaline, P. A. Peyron, L. Canaud, C. Marty-Ané, Pierre Alric

► **To cite this version:**

Elsa Madeleine Faure, Ilya Khantaline, P. A. Peyron, L. Canaud, C. Marty-Ané, et al.. Experimental Assessment of Physician Modified Proximal Scalloped Stent Graft to Extend Proximal Landing Zone in the Aortic Arch. *European Journal of Vascular and Endovascular Surgery*, 2017, 54 (2), pp.150–156. 10.1016/j.ejvs.2017.04.019 . hal-01760707

HAL Id: hal-01760707

<https://hal.science/hal-01760707>

Submitted on 8 Apr 2020

HAL is a multi-disciplinary open access archive for the deposit and dissemination of scientific research documents, whether they are published or not. The documents may come from teaching and research institutions in France or abroad, or from public or private research centers.

L'archive ouverte pluridisciplinaire **HAL**, est destinée au dépôt et à la diffusion de documents scientifiques de niveau recherche, publiés ou non, émanant des établissements d'enseignement et de recherche français ou étrangers, des laboratoires publics ou privés.

Experimental Assessment of Physician Modified Proximal Scalloped Stent Graft to Extend Proximal Landing Zone in the Aortic Arch

E.M. Faure ^{a,b,*}, I. Khantaline ^a, P.A. Peyron ^c, L. Canaud ^{a,b}, C. Marty-Ané ^a, P. Alric ^{a,b}

^a Department of Vascular and Thoracic Surgery, Arnaud de Villeneuve Hospital, Montpellier, France

^b INSERM U1046, University of Montpellier 1, CHRU of Montpellier, France

^c Legal Department, Lapeyronie Hospital Montpellier, Montpellier, France

WHAT THIS PAPER ADDS

A unique model of physician modified scalloped stent graft for one, two, or three supra-aortic trunks and its accuracy of placement over the supra-aortic vessel origins on human cadaveric aorta placed on a benchtop closed system pulsatile flow model was assessed. This model could provide an endovascular alternative to transposition with expansion of the proximal landing zone in zone 2, 1, or 0 for emergency cases with either short proximal zone 3 neck or injuries located at the inner circumference of the aortic arch.

Objective/Background: The aim of the study was to assess a model of physician modified scalloped stent graft (PMSG) on currently available thoracic aortic devices to extend the proximal landing zone in either zone 2, 1 or 0 of the aortic arch while preserving flow in the supra-aortic vessels on human cadaveric aorta.

Methods: Fresh human aortas were harvested at autopsy from adult subjects. A proximal scallop was made on the stent grafts based on direct measurements on the aortas to extend the proximal landing zone in zone 0 ($n = 5$), zone 1 ($n = 5$), and zone 2 ($n = 5$). A previously described benchtop closed system pulsatile flow model was used to mimic flow and pressure conditions in the aorta to deploy the stent graft as close to physiological conditions as possible. Deployment accuracy of the scallop opposite the aortic arch branch ostia was assessed by completion angiography and post-procedural analysis of the aortas.

Results: Fifteen proximal scalloped stent grafts were deployed in the aortic arch of 15 human cadaveric aortas under fluoroscopy. The expected proximal landing zone was achieved in all cases (zone 2 = 5; zone 1 = 5; zone 0 = 5). Post-procedural angiography and direct visual analysis showed supra-aortic vessel patency and deployment of the scallop opposite the aortic arch branch ostia in all cases.

Conclusion: PMSG to extend the proximal landing zone in zone 2, 1, or 0 in order to treat urgent diseases of the proximal descending aorta or the inner circumference of the aortic arch by a totally endovascular approach while preserving flow in the supra-aortic trunks is experimentally feasible.

Keywords: Acute aortic syndrome, Aortic arch, Scallop, Thoracic stent graft

INTRODUCTION

Despite considerable advances in endovascular techniques over the last decade and the introduction of fenestrated and branched stent grafts to treat the entire abdominal aorta, treatment of the aortic arch remains one of the last barriers to providing patients with a total endovascular treatment option. Nowadays, hybrid techniques have commonly replaced open repair of the aortic arch. However, there are still significant morbidity and mortality rates with

these less invasive approaches, especially in acute thoracic aortic syndrome.¹ In emergency endovascular repair of the thoracic aorta, expansion of the proximal landing zone in zone 2, 1, or 0 is necessary to achieve a proximal seal in up to 50% of patients.² To date, there is a shortage of commercially available devices to offer these patients endovascular treatment.³ Proximal scalloped stent grafts have been manufactured by companies to overcome neck issues in the arch.⁴ However, construction of these custom made devices can take as long as 6–12 weeks. Patients who present with acute thoracic aortic syndrome cannot be treated with the current modified thoracic stent graft technology, while they are probably the ones who would benefit most from this new approach. Based on the concept of a physician modified fenestrated stent graft to treat an emergency aneurysm involving the visceral aorta,⁴ use of a

* Corresponding author. Service de Chirurgie Vasculaire et Thoracique, Hôpital Arnaud de Villeneuve, 191 av Doyen Gaston Giraud 34090, Montpellier, France.

E-mail address: elsafaure@hotmail.com (E.M. Faure).

physician modified proximal scalloped stent graft (PMSG) to extend the proximal landing zone in zone 2 have been reported in small case series with promising results.⁶

Enlargement of the physician modified scallop to include one, two, or three supra-aortic trunks could provide an endovascular alternative to transposition for emergency cases with either a short proximal zone 3 neck or in specific cases with aortic arch injuries located on the inner circumference of the aortic arch.

However, appropriate sizing of the scallop based on the targeted supra-aortic vessel origins and placement accuracy of the scallop over them should first be experimentally assessed. The aim of the pilot study was to assess a model of physician-modified scalloped stent-graft for one, two or three supra-aortic trunks and its accuracy of placement in front of the supra-aortic vessels on human cadaveric aorta.

METHODS

The study was approved by the authors' institutional review committee and the ethics committee.

Harvesting and preparation of aortas

With the permission of the department involved and in accordance with French regulations, 15 fresh human aortas were harvested at autopsy from adult subjects who had died a maximum of 4 days previously.

The aortas were procured from above the aortic valve to the coeliac trunk. The brachiocephalic artery (BCA), the left common carotid artery (LCCA) and the left subclavian artery (LSA) were harvested for their maximum length (from 2 cm to > 5 cm). The aortas were immediately placed in ice and maintained at 4 °C. Experiments were performed within 2 h of harvesting. Sections of the aortas were sent to the Department of Pathology for analysis (stained with haematoxylin and eosin) to ensure the presence of a three layer aortic wall comparable to a fresh aorta.

Bench test model

A previously described benchtop closed system pulsatile flow model was used to mimic flow and pressure conditions in the aorta to deploy the stent graft as close to physiological conditions as possible.^{7,8} The pump rate was maintained at 60 beats/minute and systolic/diastolic pressure at 100/60 mmHg. The benchtop pulsatile flow model simulated an aortic arch whose angulations were variable according to the position of the distal aortic connection. Common angulation of the aortic arch of 90° and extreme angulation of 140° were used to assess whether the deployment accuracy of the scallop was modified by the aortic arch angulation.

Experimental set-up

Aorta preparation. After aortic harvest, the BCA, LCCA, and LSA diameters were measured using a ruler, as well as the distance between each supra-aortic vessel. Then an 8 mm knitted Dacron graft was anastomosed to the distal end of

each of the supra-aortic arteries (BCA, LCCA, and LSA). The distal end of each graft was then connected to the closed circuit to ensure an antegrade circulation into the supra-aortic vessels during the experimental set-up. A 20 mm diameter, 30 cm long knitted Dacron graft was anastomosed to the distal end of the aorta to connect the aorta to the closed circuit and to extend the distal part of the aorta in order to reproduce the clinical catheterisation length of access to the aortic arch. Aortic arch curvature was reproduced using an external knob to create a 90° of curvature as previously reported.⁷ The intercostal and lumbar arteries were oversewn (Fig. 1).

Device preparation. The stent graft used was the Valiant Captivia (Medtronic, Minneapolis, MN, USA).

The stent graft was unsheathed for its four first stents. The first uncovered stent and tip capture was tightly surrounded by a surgical loop and put into a 2 mL needle (Fig. 2A). The size of the scallop was based on direct measurements on the aorta: 30% oversizing of the widest supra-aortic trunk diameter included in the scallop was applied to determine the width of the scallop, and the length of the scallop was determined by the measured length between the distal end of the LSA and the proximal end of the first supra-aortic vessel included in the scallop.

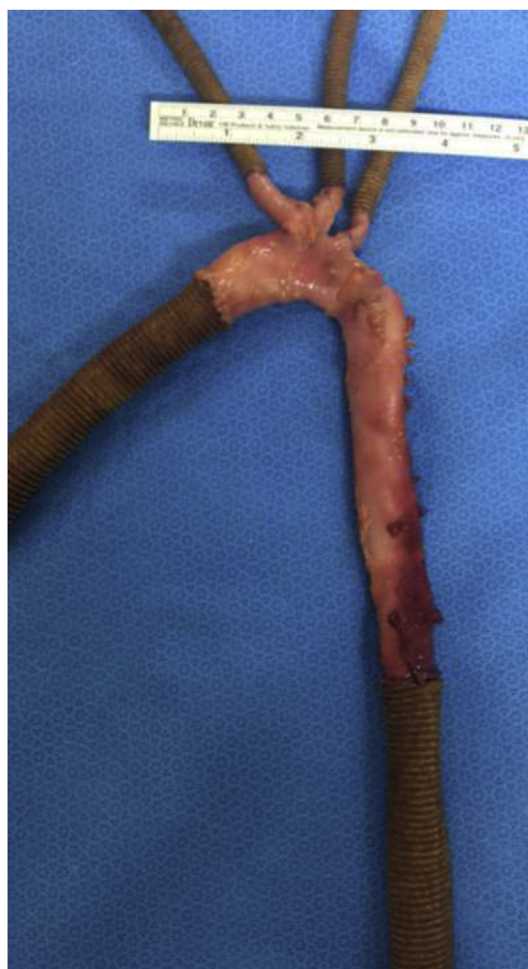

Figure 1. Model of human cadaveric aorta preparation.

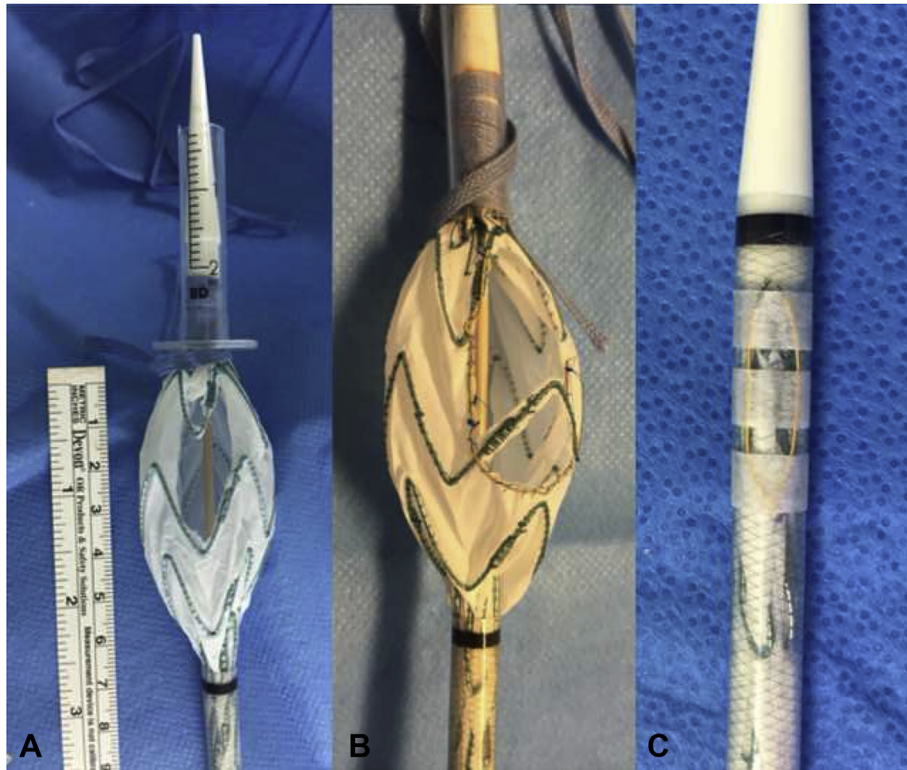


Figure 2. Surgeon modified stent graft procedural details. (A) Creation of the scallop on the graft unsheathed on its four first stents. The first uncovered stent and tip capture surrounded by a surgical loop and put into a 2 mL needle. (B) Gold plated 15 mm tungsten loop reinforces and mark the sides of the scallop. (C) Reloaded graft with gold plated 15 mm tungsten loop on the sheath tied with Steri-Strip and transparent sterile hydrofilm.

Minor adjustments were made in the localisation of the scallop to allow for maximum usage of strut free fenestration when possible.

An ophthalmic Bovie cautery device (Medtronic) was used to burn the Dacron fabric to create the scallops and thus avoid fabric fraying. Gold plated 15 mm tungsten loop One Snares (Merit Medical System Inc., South Jordan, UT, USA) were then used to reinforce and mark the sides of the scallop. These were hand sewn into place using 5-0 Prolene suture in a 360° running fashion. A typical final PMSG device is shown in Fig. 2B.

The entire graft was then reloaded into the existing sheath using a surgical loop to tightly surround the stent graft. Location of the scallop within the sheath was marked on the sheath using the gold plated 15 mm tungsten loop, and tied with Steri-Strip and transparent sterile hydrofilm (Fig. 2C).

PMSG procedural details. The procedures were performed in a modern angiography suite using a portable imaging unit (BV Endura Mobile C-arm; Philips Healthcare, Surrey, UK). Aortas were connected to the benchtop closed system pulsatile flow model. The distal connector was moved into the rail to give an aortic arch angulation of 90° or 140°. The angle formed by the BCA, LCCA, and LSA with the aortic arch was between 30° and 90°.

A double curved extra stiff wire (Lunderquist; Cook Medical Inc., Bloomington, IN, USA) was inserted into the aorta through the distal 20 mm knitted Dacron graft. The

distal end of the wire was placed into the first centimetres of the proximal Dacron graft sutured to the ascending aorta with the curve part of the wire located within the arch to mimic usual navigation. The PMSG was inserted into the aorta over the extra stiff wire and the stent graft delivered up into position near the supra-aortic trunks. An aortogram was performed with the PMSG in place to mark the supra-aortic trunks. Proper orientation of the graft (scallop upper) was performed by rotating the graft clockwise under fluoroscopy. The proximal scallop markers were located on the top of the graft (Fig. 3). The graft was then carefully deployed under direct fluoroscopic visualisation, and tip capture was released.

Assessment of deployment accuracy of the scallop to the aortic arch branch ostia was performed by digital subtraction angiography (DSA) on completion of each procedure. Deployment accuracy was defined as the distance between the actual and intended device implantation locations, and supra-aortic trunk patency measured from DSA images and by direct visual examination at the end of the procedure by cutting the supra-aortic trunks. Partial ostial coverage by the stent graft was then assessed. If the covered part of the stent graft was seen on the ostium, it was measured and the percentage of the covering was then calculated and considered as a stenosis. A branch stenosis $\geq 30\%$, as well as a distance ≥ 4 mm from the end of the most distal branch included in the scallop to the end of the scallop, was considered inaccurate.

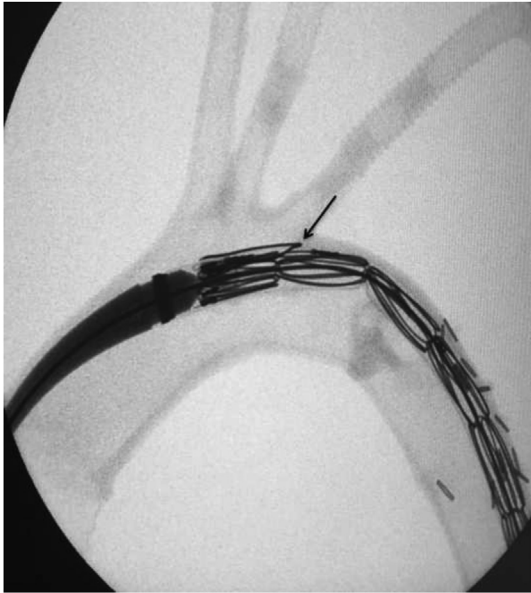

Figure 3. Radiological image during navigation. The arrow shows the outer marker.

RESULTS

Macroscopic analysis of the aortas

A total of 15 cadaveric aortas were harvested. The mean ascending aortic diameter measured at BCA level was 34 mm.

According to the scoring system of Malina et al., for macroscopic classification of the cadaveric aortic wall,⁹ the disease in the 15 cadaveric aortas was classified as grade I (non-atherosclerotic; $n = 8$), grade II (soft intimal thickening; $n = 5$), and grade III (calcified plaques engaging part of the aortic circumference; $n = 2$).

Mean BCA, LCCA, and LSA diameters were 14.25 mm, 11.75, and 11.25, respectively. The mean distance was 9 mm between the BCA and LCCA, and 9.4 mm between the LCCA and the LSA.

Device preparation

Fifteen stent grafts were modified. The graft diameter ranged from 38 to 42 mm.

Five stent grafts were scalloped for the LSA (proximal landing zone in zone 2), five were scalloped for the LSA and the LCCA (zone 1) and five were scalloped for the LSA, the LCCA, and the BCA (zone 0).

Graft modification times averaged 22 min (range 17–33 min). Mean \pm SD scallop width was 15 ± 2.5 mm.

Mean \pm SD scallop length was 34 ± 13 mm. Mean proximal scallop width and length according to the proximal landing zone are shown Table 1.

PMSG procedural details

Fifteen PMSGs were deployed in 15 human cadaveric aortas.

For each proximal landing zone, four PMSGs were deployed at an aortic arch curvature angle of 90° and one PMSG was deployed at an aortic arch curvature angle of 140° .

The mean procedure time was 17 min (range 13–22 min).

Accurate placement of the PMSG was observed in all cases on completion DSA (Fig. 4A and B) and direct visual post-procedural analysis of the aortas (Fig. 5A and B). Proximal anchoring was in the expected zone, the distance between the end of the most distal branch included in the scallop and the end of the scallop was <4 mm in all cases, and there was no branch stenosis $\geq 30\%$.

DISCUSSION

The correction of aortic arch pathology remains the last frontier for endovascular treatment; left subclavian artery coverage is necessary to achieve proximal seal in up to 50% of patients treated by thoracic endovascular aneurysm repair.² Hybrid repairs constituting a bridge from surgery to an endovascular approach have been described as safe and less invasive in high risk patients.^{1,10–12} However, there remain relevant adverse consequences, with peri-operative mortality and stroke rates ranging from 0% to 25%.¹³

In recent years, a variety of endovascular approaches have been developed in order to achieve complete endovascular treatment of the aortic arch, such as the chimney technique. This technique is less challenging than fenestrated and branched endografting,¹⁴ and can be used with a variety of stents, making it applicable in urgent situations. However, the incidence of endoleaks and strokes during the peri-operative period are 21.6% and 7.8%, respectively.¹⁵ A limitation is that the stents may become obstructed, resulting in stenosis and a requirement for a catheter procedure in the aortic arch. Future studies should evaluate long-term graft durability and techniques for fixation to the aortic arch.

Proximal scalloped and branched endografts currently available for the aortic arch are custom made devices designed according to each patient's anatomy and manufactured under medical prescription. These devices may

Table 1. Scallop sizes and supra-aortic trunk patency after stent graft deployment according to the proximal landing zone.

Proximal landing zone	Scallop width (mm)	Scallop length (mm)	LSA/LCCA/BCA patency after SG deployment (%)	Max. stenosis (%)
2 ($n = 5$)	13.8 ± 1.3	20 ± 1.9	100	0
1 ($n = 5$)	15.0 ± 1.4	32 ± 1.9	100	10
0 ($n = 5$)	17.6 ± 3.0	49 ± 5.6	100	10

Note. Data are mean \pm SD unless otherwise indicated. LSA = left subclavian artery; LCCA = left common carotid artery; BCA = brachiocephalic artery; SG = stent graft.

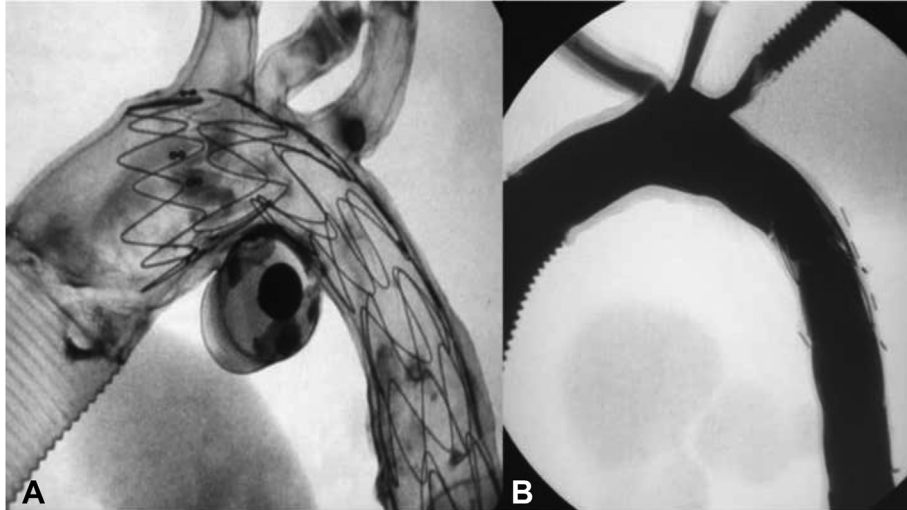


Figure 4. Procedural detail. (A) Deployment of a scalloped stent graft in zone 0 under fluoroscopy. (B) Preserved patency of all the aortic arch branches after deployment of the scalloped stent graft in zone 0 confirmed by completion angiography.

allow total endovascular treatment for aortic arch disease for elective surgery with promising results.^{3,4,16–18} However, the manufacturing process requires about 2–3 weeks and these devices cannot be used for aortic arch emergencies.

Currently, for emergency injuries of the proximal descending thoracic aorta with a short (<2 cm) proximal landing zone the LSA is usually covered without revascularisation.¹⁹ However, LSA coverage without revascularisation has been reported to be associated with an increased risk of stroke, paraplegia, and arm ischaemia.²⁰ Even systematic LSA revascularisation remains under debate; it is assumed that in these emergency settings, the risk of paraplegia is increased as a result of haemodynamic instability. Regarding urgent aortic arch injuries when zone 1 or

0 stent graft proximal anchoring is needed, either open surgery or a hybrid procedure with supra-aortic trunk debranching is performed, with not insignificant morbidity and mortality.^{21,22}

Based on the PMSG technique described for thoraco-abdominal aortic emergencies,⁵ herein a technique is reported for a physician modified thoracic stent graft to create a proximal scallop using an “off the shelf” thoracic stent graft to extend the proximal landing zone to zone 2, 1, or 0 with preservation of flow in the aortic arch branches.

One of the limitations of these devices is a possible lack of deployment accuracy in the diseased arch. The present experimental study shows 100% scallop deployment accuracy over the supra-aortic trunk ostia, without any LSA stenosis on completion angiography or direct visual

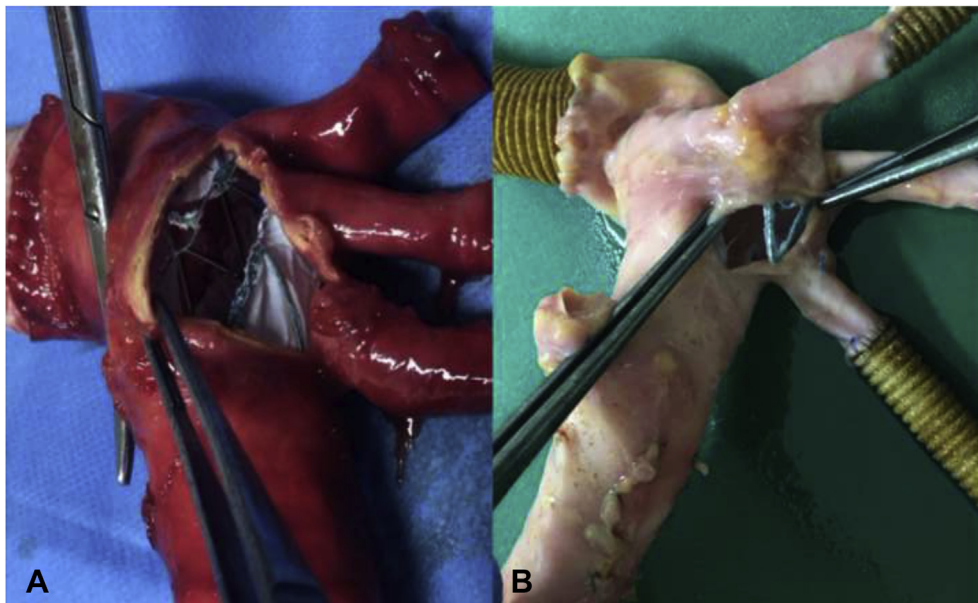


Figure 5. Direct visual post-procedural analyses of the aortas. (A) Confirmed location of the scallop opposite the left subclavian artery, left common carotid artery, and the brachiocephalic artery ostia. (B) Confirmed location of the scallop over the left subclavian artery ostium.

evaluation, with a 30% diameter oversizing of the scallop compared with the widest ostium diameter included in the scallop. Although the model does not reproduce exact vessel access anatomical characteristics such as iliac angulation, the aortic arch angulation, the distance to the femoral access vessels, and the pulsatile flow in the aortic arch are reproduced to bring the model as close as possible to clinical practice. In this experimental study an extreme aortic arch curvature angle of 140° did not alter the deployment accuracy of the scallop.

The valuable contribution of an outer marker on the sheath to allow accurate placement of the scallop in front of the LSA ostium under fluoroscopy with a mobile C-arm fluoroscopic X-ray system was observed during this experimental study. However, the authors have started to test the PMSG in real clinical cases with the large fixed angiographic systems currently available in the hybrid operating room, and have noted that with the improvement of image quality the outer marker is no longer necessary.

Another issue to be mentioned is the incidence of type I endoleak due to inadequate sealing with the modified stent graft, especially with a scalloped and fenestrated stent graft. A recent study compared the outcomes of branched versus fenestrated custom made endografts for endovascular repair of aortic arch lesions without a higher rate of endoleak in the fenestrated group.¹⁸ To reduce the risk of type I endoleak the present model of PMSG should be used in cases of aortic arch injuries located on the inner circumference of the aortic arch, such as complicated acute type B aortic dissection with proximal entry tear on the inner circumference, penetrating aortic arch ulcer, or traumatic rupture of the aortic isthmus. The outer circumference of the aortic arch should be safe enough to achieve a good seal with optimal and complete apposition of the modified stent graft on the scallop side. The model should not be used in cases of circumferential aneurysmal degeneration of the aortic arch or chronic dissecting aneurysm; in these cases, bridging stents are required owing to the distance between the scallop and the target vessel. In combination with the strong pulsation of the arch, they would be exposed to mechanical stress that would compromise the seal at the scallop. Branched arch devices are probably more suitable for these cases.¹⁸

The time taken for the device customisation is another potential limitation. Modification of a stent graft to produce the scallop, constrain the device, and resheath it varies (in the authors' experience) from 17 to 33 min, with a mean device modification time of 23 min. This represents the major drawback of this technique for managing thoracic aortic emergencies in haemodynamically unstable patients. Nevertheless, considering that the preparation of the graft can begin independently of the procedure (as soon as the computed tomography scan is available) and the measurements are made, this time often coincides with the preparation of the patient by the anaesthetic team and femoral artery exposure and access. Furthermore, this time is relatively short if it is compared with the time for supra-aortic trunk transposition performed in hybrid procedures.

PMSG offers a quickly available and reproducible option for extending the proximal landing zone to zone 2, 1, or even 0 for emergency aortic arch injuries. This technique allows matching of the variability of the origins of the supra-aortic trunks in an emergency with an "off the shelf" thoracic stent graft device. The procedure does not require aortic arch branch catheterisation, which increases the potential for prolonged catheter and guidewire manipulation in the aortic arch and risk of cerebral embolic events or stroke.

Limitations

This was an experimental study and the PMSGs were used in non-pathological aortic arches. It would be interesting to assess the efficiency of the scalloped stent graft to exclude aneurysm/primary entry tear in aneurysmal or dissected aorta arising from a real three dimensionally printed pathological aortic arch. However, the flexibility, elasticity, and strength of three dimensionally printed aortas are different from real aortas, and assessment of the accurate placement of the scallop under fluoroscopy in real aortas would probably be more appropriate. Furthermore, there exists an obvious legal risk to modifying an existing Food and Drug Administration approved medical device, involving product liability and durability. However, PMSG have been used for several years to treat aortic thoraco-abdominal aneurysms without any problems of device deterioration, with up to four homemade fenestrations,⁵ and these favourable results could be extrapolated to one thoracic stent graft. However, this technique needs to be clinically assessed on pathological aortic arch.

CONCLUSION

PMSGs to extend the proximal landing zones to zones 2, 1, or 0 were feasible in an experimental model with cadaveric aortas. In this experimental study the accuracy of stent graft and scallop deployment over aortic arch branch ostia under fluoroscopy with a 30% oversizing is demonstrated. Its use for total endovascular repair of urgent aortic arch diseases needs to be further investigated.

CONFLICT OF INTEREST

None.

FUNDING

The study was funded by the Société de Chirurgie Vasculaire et Endovasculaire de Langue Française.

REFERENCES

- 1 Cao P, De Rango P, Czerny M, Evangelista A, Fattori R, Nienaber C, et al. Systematic review of clinical outcomes in hybrid procedures for aortic arch dissections and other arch diseases. *J Thorac Cardiovasc Surg* 2012;**144**:1286–300.
- 2 Peterson BG, Eskandari MK, Gleason TG, Morasch MD. Utility of left subclavian artery revascularization in association with endoluminal repair of acute and chronic thoracic aortic pathology. *J Vasc Surg* 2006;**43**:433–9.

- 3 Haulon S, Greenberg RK, Spear R, Eagleton M, Abraham C, Lioupis C, et al. Global experience with an inner branched arch endograft. *J Thorac Cardiovasc Surg* 2014;**148**:1709–16.
- 4 Ben Abdallah I, El Batti S, Sapoval M, Abou Rjeili M, Fabiani JN, Julia P, et al. Proximal scallop in thoracic endovascular aortic aneurysm repair to overcome neck issues in the arch. *Eur J Vasc Endovasc Surg* 2016;**51**(3):343–9.
- 5 Georgiadis GS, van Herwaarden JA, Antoniou GA, Hazenberg CE, Giannoukas AD, Lazarides MK, et al. Systematic review of off-the-shelf or physician-modified fenestrated and branched endografts. *J Endovasc Ther* 2016;**23**(1):98–109.
- 6 Canaud L, Gandet T, Khantalin I, Ozdemir BA, Marty-Ané CH, Alric P. Homemade proximal scalloped stent graft for thoracic endovascular aortic repair of zone 2 acute aortic syndrome. *J Thorac Cardiovasc Surg* 2016;**152**:1301–6.
- 7 Canaud L, Alric P, Laurent M, Baum TP, Branchereau P, Marty-Ané CH, et al. Proximal fixation of thoracic stent-grafts as a function of oversizing and increasing aortic arch angulation in human cadaveric aorta. *J Endovasc Ther* 2008;**15**(3):326–34.
- 8 Faure EM, Canaud L, Cathala P, Serres I, Marty-Ané C, Alric P. Human ex-vivo model of Stanford type B aortic dissection. *J Vasc Surg* 2014 Sep;**60**(3):767–75.
- 9 Malina M, Lindblad B, Ivancev K, Lindh M, Malina J, Brunkwall J. Endovascular AAA exclusion: will stents with hooks and barbs prevent stent-graft migration? *J Endovasc Surg* 1998;**5**:310–7.
- 10 Faure EM, Canaud L, Marty-Ané C, Alric P. Hybrid aortic arch repair for dissecting aneurysm. *J Thorac Cardiovasc Surg* 2016;**152**:162–8.
- 11 Canaud L, Hireche K, Berthet JP, Branchereau P, Marty-Ané C, Alric P. Endovascular repair of aortic arch lesions in high-risk patients or after previous aortic surgery: midterm results. *J Thorac Cardiovasc Surg* 2010;**140**:52–8.
- 12 Milewski RK, Szeto WY, Pochettino A, Moser GW, Moeller P, Bavaria JE. Have hybrid procedures replaced open aortic arch reconstruction in high-risk patients? A comparative study of elective open arch debranching with endovascular stent graft placement and conventional elective open total and distal aortic arch reconstruction. *J Thorac Cardiovasc Surg* 2010;**140**:590–7.
- 13 Chiesa R, Melissano G, Tshomba Y, Civilini E, Marone EM, Bertoglio L, et al. Ten years of endovascular aortic arch repair. *J Endovasc Ther* 2010;**17**:1–11.
- 14 Amiot S, Haulon S, Becquemin JP, Magnan PE, Lermusiaux P, Goueffic Y, et al. Fenestrated endovascular grafting: the French multicentre experience. *Eur J Vasc Endovasc Surg* 2010;**39**:537–44.
- 15 Yang J, Xiong J, Liu X, Jia X, Zhu Y, Guo W. Endovascular chimney technique of aortic arch pathologies: a systematic review. *Ann Vasc Surg* 2012;**26**:1014–21.
- 16 Alsafi A, Bicknell CD, Rudarakanchana N, Kashef E, Gibbs RG, Cheshire NJ, et al. Endovascular treatment of thoracic aortic aneurysms with a short proximal landing zone using scalloped endografts. *J Vasc Surg* 2014;**60**:1499–506.
- 17 Spear R, Haulon S, Ohki T, Tsilimparis N, Kanaoka Y, Milne CPE, et al. Subsequent results for arch aneurysm repair with inner branched endografts. *Eur J Vasc Endovasc Surg* 2016;**51**:380–5.
- 18 Tsilimparis N, Debus ES, Von Kodolitsch Y, Wipper S, Rohlfes F, Detter C, et al. Branched versus fenestrated endografts for endovascular repair of aortic arch lesions. *J Vasc Surg* 2016;**64**:592–9.
- 19 Hajibandeh S, Hajibandeh S, Antoniou SA, Torella F, Antoniou GA. Meta-analysis of left subclavian artery coverage with and without revascularization in thoracic endovascular aortic repair. *J Endovasc Ther* 2016;**23**:634–41.
- 20 Cooper DG, Walsh SR, Sadat U, Noorani A, Hayes PD, Boyle JR. Neurological complications after left subclavian artery coverage during thoracic endovascular aortic repair: a systematic review and meta-analysis. *J Vasc Surg* 2009;**49**:1594–601.
- 21 Geisbusch P, Kotelis D, Eschner MM, Hyhlik-Durr A, Bockler D. Complications after aortic arch hybrid repair. *J Vasc Surg* 2011;**53**:935–41.
- 22 Cochenec F, Tresson P, Cross J, Desgranges P, Allaire E, Becquemin JP. Hybrid repair of aortic arch dissections. *J Vasc Surg* 2013;**57**:1560–7.

physician modified proximal scalloped stent graft (PMSG) to extend the proximal landing zone in zone 2 have been reported in small case series with promising results.⁶

Enlargement of the physician modified scallop to include one, two, or three supra-aortic trunks could provide an endovascular alternative to transposition for emergency cases with either a short proximal zone 3 neck or in specific cases with aortic arch injuries located on the inner circumference of the aortic arch.

However, appropriate sizing of the scallop based on the targeted supra-aortic vessel origins and placement accuracy of the scallop over them should first be experimentally assessed. The aim of the pilot study was to assess a model of physician-modified scalloped stent-graft for one, two or three supra-aortic trunks and its accuracy of placement in front of the supra-aortic vessels on human cadaveric aorta.

METHODS

The study was approved by the authors' institutional review committee and the ethics committee.

Harvesting and preparation of aortas

With the permission of the department involved and in accordance with French regulations, 15 fresh human aortas were harvested at autopsy from adult subjects who had died a maximum of 4 days previously.

The aortas were procured from above the aortic valve to the coeliac trunk. The brachiocephalic artery (BCA), the left common carotid artery (LCCA) and the left subclavian artery (LSA) were harvested for their maximum length (from 2 cm to > 5 cm). The aortas were immediately placed in ice and maintained at 4 °C. Experiments were performed within 2 h of harvesting. Sections of the aortas were sent to the Department of Pathology for analysis (stained with haematoxylin and eosin) to ensure the presence of a three layer aortic wall comparable to a fresh aorta.

Bench test model

A previously described benchtop closed system pulsatile flow model was used to mimic flow and pressure conditions in the aorta to deploy the stent graft as close to physiological conditions as possible.^{7,8} The pump rate was maintained at 60 beats/minute and systolic/diastolic pressure at 100/60 mmHg. The benchtop pulsatile flow model simulated an aortic arch whose angulations were variable according to the position of the distal aortic connection. Common angulation of the aortic arch of 90° and extreme angulation of 140° were used to assess whether the deployment accuracy of the scallop was modified by the aortic arch angulation.

Experimental set-up

Aorta preparation. After aortic harvest, the BCA, LCCA, and LSA diameters were measured using a ruler, as well as the distance between each supra-aortic vessel. Then an 8 mm knitted Dacron graft was anastomosed to the distal end of

each of the supra-aortic arteries (BCA, LCCA, and LSA). The distal end of each graft was then connected to the closed circuit to ensure an antegrade circulation into the supra-aortic vessels during the experimental set-up. A 20 mm diameter, 30 cm long knitted Dacron graft was anastomosed to the distal end of the aorta to connect the aorta to the closed circuit and to extend the distal part of the aorta in order to reproduce the clinical catheterisation length of access to the aortic arch. Aortic arch curvature was reproduced using an external knob to create a 90° of curvature as previously reported.⁷ The intercostal and lumbar arteries were oversewn (Fig. 1).

Device preparation. The stent graft used was the Valiant Captivia (Medtronic, Minneapolis, MN, USA).

The stent graft was unsheathed for its four first stents. The first uncovered stent and tip capture was tightly surrounded by a surgical loop and put into a 2 mL needle (Fig. 2A). The size of the scallop was based on direct measurements on the aorta: 30% oversizing of the widest supra-aortic trunk diameter included in the scallop was applied to determine the width of the scallop, and the length of the scallop was determined by the measured length between the distal end of the LSA and the proximal end of the first supra-aortic vessel included in the scallop.

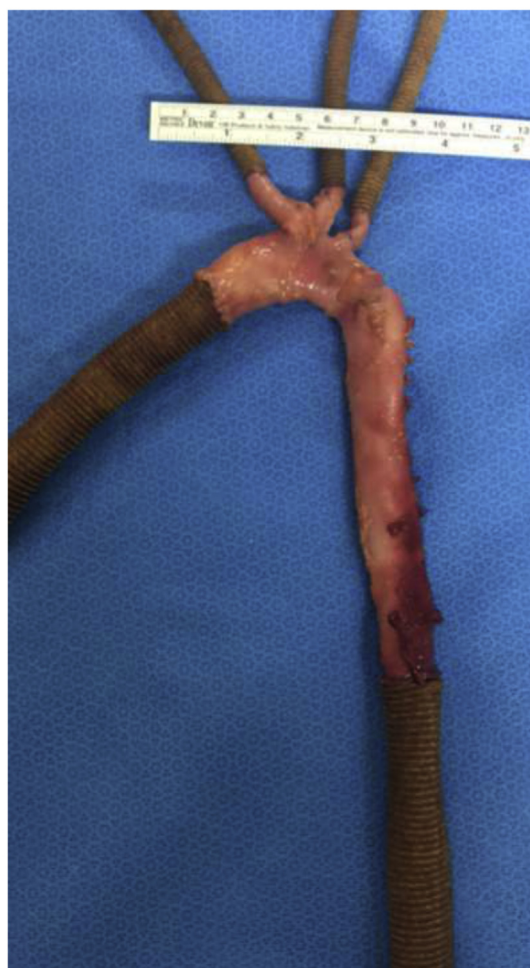

Figure 1. Model of human cadaveric aorta preparation.

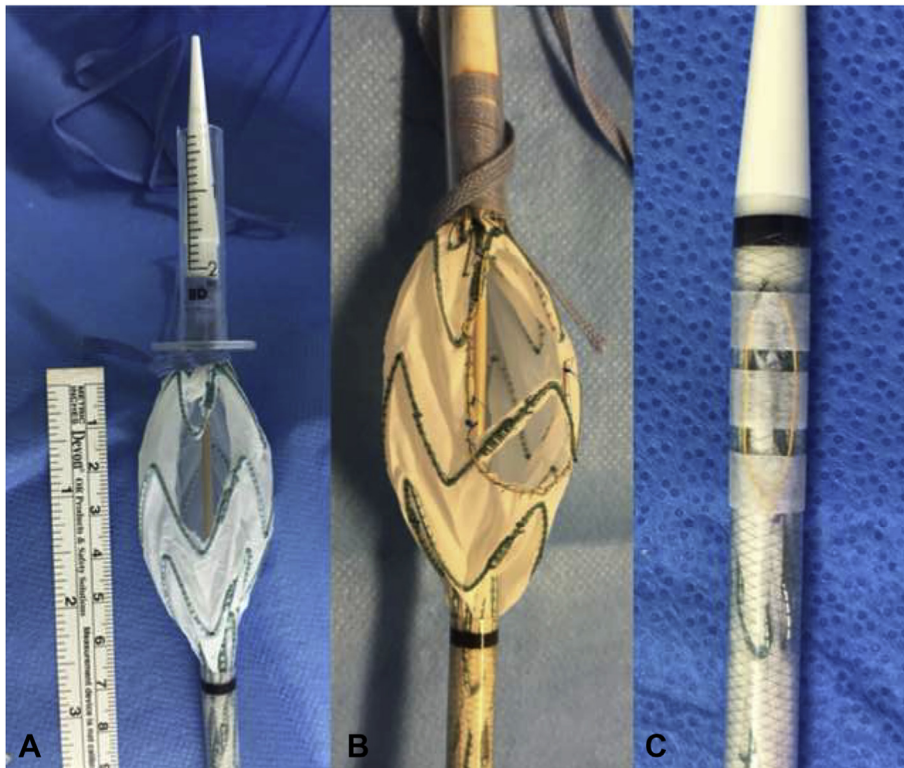


Figure 2. Surgeon modified stent graft procedural details. (A) Creation of the scallop on the graft unsheathed on its four first stents. The first uncovered stent and tip capture surrounded by a surgical loop and put into a 2 mL needle. (B) Gold plated 15 mm tungsten loop reinforces and mark the sides of the scallop. (C) Reloaded graft with gold plated 15 mm tungsten loop on the sheath tied with Steri-Strip and transparent sterile hydrofilm.

Minor adjustments were made in the localisation of the scallop to allow for maximum usage of strut free fenestration when possible.

An ophthalmic Bovie cautery device (Medtronic) was used to burn the Dacron fabric to create the scallops and thus avoid fabric fraying. Gold plated 15 mm tungsten loop One Snares (Merit Medical System Inc., South Jordan, UT, USA) were then used to reinforce and mark the sides of the scallop. These were hand sewn into place using 5-0 Prolene suture in a 360° running fashion. A typical final PMSG device is shown in Fig. 2B.

The entire graft was then reloaded into the existing sheath using a surgical loop to tightly surround the stent graft. Location of the scallop within the sheath was marked on the sheath using the gold plated 15 mm tungsten loop, and tied with Steri-Strip and transparent sterile hydrofilm (Fig. 2C).

PMSG procedural details. The procedures were performed in a modern angiography suite using a portable imaging unit (BV Endura Mobile C-arm; Philips Healthcare, Surrey, UK). Aortas were connected to the benchtop closed system pulsatile flow model. The distal connector was moved into the rail to give an aortic arch angulation of 90° or 140°. The angle formed by the BCA, LCCA, and LSA with the aortic arch was between 30° and 90°.

A double curved extra stiff wire (Lunderquist; Cook Medical Inc., Bloomington, IN, USA) was inserted into the aorta through the distal 20 mm knitted Dacron graft. The

distal end of the wire was placed into the first centimetres of the proximal Dacron graft sutured to the ascending aorta with the curve part of the wire located within the arch to mimic usual navigation. The PMSG was inserted into the aorta over the extra stiff wire and the stent graft delivered up into position near the supra-aortic trunks. An aortogram was performed with the PMSG in place to mark the supra-aortic trunks. Proper orientation of the graft (scallop upper) was performed by rotating the graft clockwise under fluoroscopy. The proximal scallop markers were located on the top of the graft (Fig. 3). The graft was then carefully deployed under direct fluoroscopic visualisation, and tip capture was released.

Assessment of deployment accuracy of the scallop to the aortic arch branch ostia was performed by digital subtraction angiography (DSA) on completion of each procedure. Deployment accuracy was defined as the distance between the actual and intended device implantation locations, and supra-aortic trunk patency measured from DSA images and by direct visual examination at the end of the procedure by cutting the supra-aortic trunks. Partial ostial coverage by the stent graft was then assessed. If the covered part of the stent graft was seen on the ostium, it was measured and the percentage of the covering was then calculated and considered as a stenosis. A branch stenosis $\geq 30\%$, as well as a distance ≥ 4 mm from the end of the most distal branch included in the scallop to the end of the scallop, was considered inaccurate.

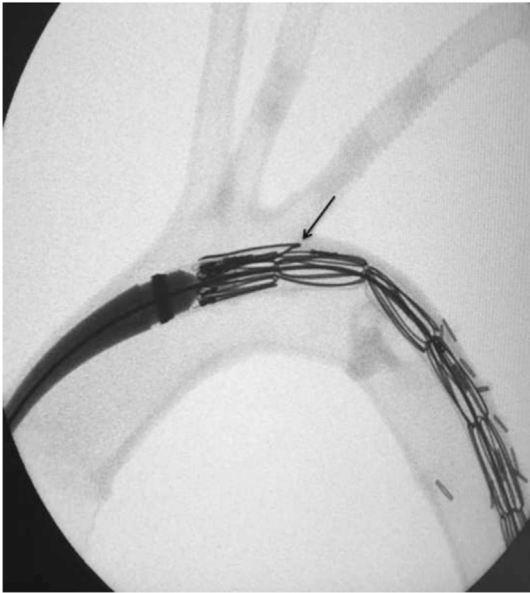

Figure 3. Radiological image during navigation. The arrow shows the outer marker.

RESULTS

Macroscopic analysis of the aortas

A total of 15 cadaveric aortas were harvested. The mean ascending aortic diameter measured at BCA level was 34 mm.

According to the scoring system of Malina et al.,⁹ for macroscopic classification of the cadaveric aortic wall, the disease in the 15 cadaveric aortas was classified as grade I (non-atherosclerotic; $n = 8$), grade II (soft intimal thickening; $n = 5$), and grade III (calcified plaques engaging part of the aortic circumference; $n = 2$).

Mean BCA, LCCA, and LSA diameters were 14.25 mm, 11.75, and 11.25, respectively. The mean distance was 9 mm between the BCA and LCCA, and 9.4 mm between the LCCA and the LSA.

Device preparation

Fifteen stent grafts were modified. The graft diameter ranged from 38 to 42 mm.

Five stent grafts were scalloped for the LSA (proximal landing zone in zone 2), five were scalloped for the LSA and the LCCA (zone 1) and five were scalloped for the LSA, the LCCA, and the BCA (zone 0).

Graft modification times averaged 22 min (range 17–33 min). Mean \pm SD scallop width was 15 ± 2.5 mm.

Mean \pm SD scallop length was 34 ± 13 mm. Mean proximal scallop width and length according to the proximal landing zone are shown [Table 1](#).

PMSG procedural details

Fifteen PMSGs were deployed in 15 human cadaveric aortas.

For each proximal landing zone, four PMSGs were deployed at an aortic arch curvature angle of 90° and one PMSG was deployed at an aortic arch curvature angle of 140° .

The mean procedure time was 17 min (range 13–22 min).

Accurate placement of the PMSG was observed in all cases on completion DSA ([Fig. 4A](#) and [B](#)) and direct visual post-procedural analysis of the aortas ([Fig. 5A](#) and [B](#)). Proximal anchoring was in the expected zone, the distance between the end of the most distal branch included in the scallop and the end of the scallop was <4 mm in all cases, and there was no branch stenosis $\geq 30\%$.

DISCUSSION

The correction of aortic arch pathology remains the last frontier for endovascular treatment; left subclavian artery coverage is necessary to achieve proximal seal in up to 50% of patients treated by thoracic endovascular aneurysm repair.² Hybrid repairs constituting a bridge from surgery to an endovascular approach have been described as safe and less invasive in high risk patients.^{1,10–12} However, there remain relevant adverse consequences, with peri-operative mortality and stroke rates ranging from 0% to 25%.¹³

In recent years, a variety of endovascular approaches have been developed in order to achieve complete endovascular treatment of the aortic arch, such as the chimney technique. This technique is less challenging than fenestrated and branched endografting,¹⁴ and can be used with a variety of stents, making it applicable in urgent situations. However, the incidence of endoleaks and strokes during the peri-operative period are 21.6% and 7.8%, respectively.¹⁵ A limitation is that the stents may become obstructed, resulting in stenosis and a requirement for a catheter procedure in the aortic arch. Future studies should evaluate long-term graft durability and techniques for fixation to the aortic arch.

Proximal scalloped and branched endografts currently available for the aortic arch are custom made devices designed according to each patient's anatomy and manufactured under medical prescription. These devices may

Table 1. Scallop sizes and supra-aortic trunk patency after stent graft deployment according to the proximal landing zone.

Proximal landing zone	Scallop width (mm)	Scallop length (mm)	LSA/LCCA/BCA patency after SG deployment (%)	Max. stenosis (%)
2 ($n = 5$)	13.8 ± 1.3	20 ± 1.9	100	0
1 ($n = 5$)	15.0 ± 1.4	32 ± 1.9	100	10
0 ($n = 5$)	17.6 ± 3.0	49 ± 5.6	100	10

Note. Data are mean \pm SD unless otherwise indicated. LSA = left subclavian artery; LCCA = left common carotid artery; BCA = brachiocephalic artery; SG = stent graft.

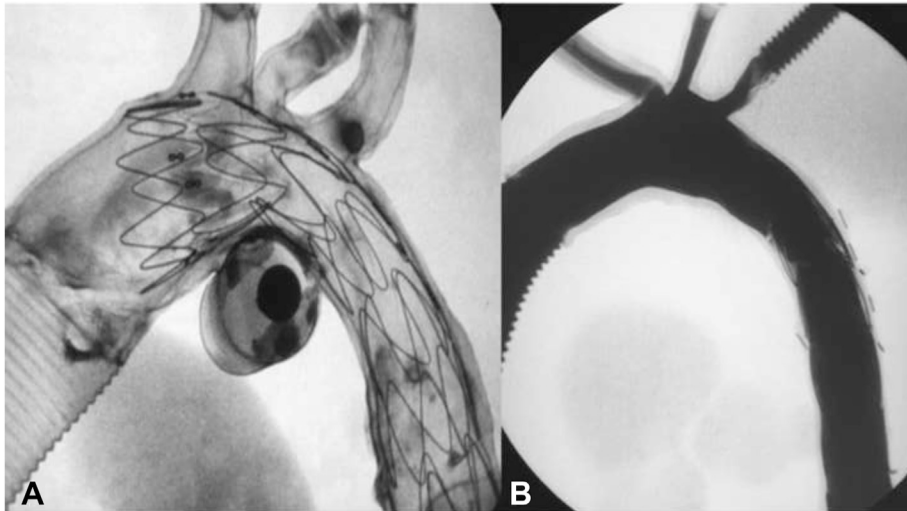


Figure 4. Procedural detail. (A) Deployment of a scalloped stent graft in zone 0 under fluoroscopy. (B) Preserved patency of all the aortic arch branches after deployment of the scalloped stent graft in zone 0 confirmed by completion angiography.

allow total endovascular treatment for aortic arch disease for elective surgery with promising results.^{3,4,16–18} However, the manufacturing process requires about 2–3 weeks and these devices cannot be used for aortic arch emergencies.

Currently, for emergency injuries of the proximal descending thoracic aorta with a short (<2 cm) proximal landing zone the LSA is usually covered without revascularisation.¹⁹ However, LSA coverage without revascularisation has been reported to be associated with an increased risk of stroke, paraplegia, and arm ischaemia.²⁰ Even systematic LSA revascularisation remains under debate; it is assumed that in these emergency settings, the risk of paraplegia is increased as a result of haemodynamic instability. Regarding urgent aortic arch injuries when zone 1 or

0 stent graft proximal anchoring is needed, either open surgery or a hybrid procedure with supra-aortic trunk debranching is performed, with not insignificant morbidity and mortality.^{21,22}

Based on the PMSG technique described for thoraco-abdominal aortic emergencies,⁵ herein a technique is reported for a physician modified thoracic stent graft to create a proximal scallop using an “off the shelf” thoracic stent graft to extend the proximal landing zone to zone 2, 1, or 0 with preservation of flow in the aortic arch branches.

One of the limitations of these devices is a possible lack of deployment accuracy in the diseased arch. The present experimental study shows 100% scallop deployment accuracy over the supra-aortic trunk ostia, without any LSA stenosis on completion angiography or direct visual

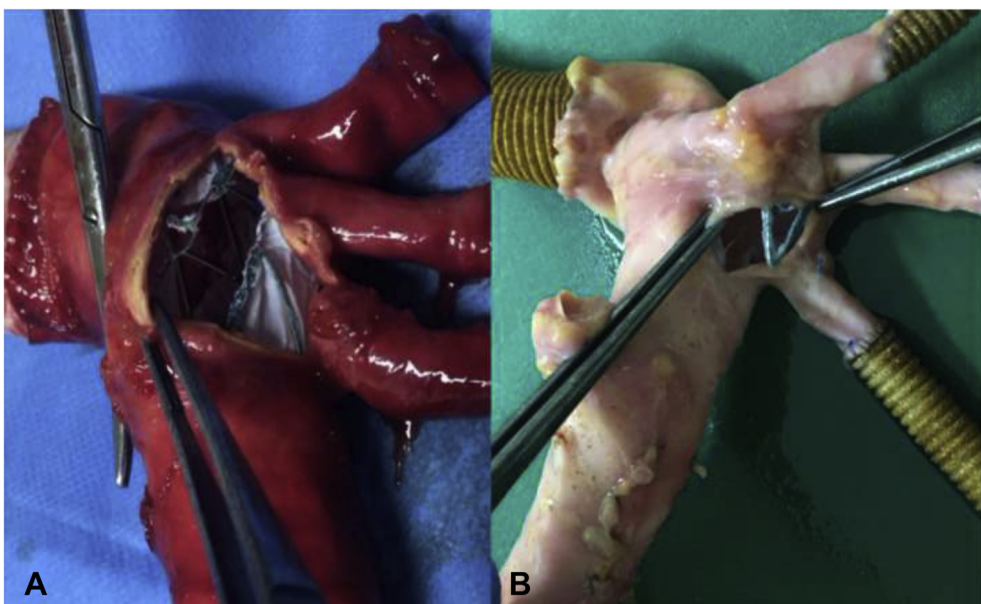


Figure 5. Direct visual post-procedural analyses of the aortas. (A) Confirmed location of the scallop opposite the left subclavian artery, left common carotid artery, and the brachiocephalic artery ostia. (B) Confirmed location of the scallop over the left subclavian artery ostium.

evaluation, with a 30% diameter oversizing of the scallop compared with the widest ostium diameter included in the scallop. Although the model does not reproduce exact vessel access anatomical characteristics such as iliac angulation, the aortic arch angulation, the distance to the femoral access vessels, and the pulsatile flow in the aortic arch are reproduced to bring the model as close as possible to clinical practice. In this experimental study an extreme aortic arch curvature angle of 140° did not alter the deployment accuracy of the scallop.

The valuable contribution of an outer marker on the sheath to allow accurate placement of the scallop in front of the LSA ostium under fluoroscopy with a mobile C-arm fluoroscopic X-ray system was observed during this experimental study. However, the authors have started to test the PMSG in real clinical cases with the large fixed angiographic systems currently available in the hybrid operating room, and have noted that with the improvement of image quality the outer marker is no longer necessary.

Another issue to be mentioned is the incidence of type I endoleak due to inadequate sealing with the modified stent graft, especially with a scalloped and fenestrated stent graft. A recent study compared the outcomes of branched versus fenestrated custom made endografts for endovascular repair of aortic arch lesions without a higher rate of endoleak in the fenestrated group.¹⁸ To reduce the risk of type I endoleak the present model of PMSG should be used in cases of aortic arch injuries located on the inner circumference of the aortic arch, such as complicated acute type B aortic dissection with proximal entry tear on the inner circumference, penetrating aortic arch ulcer, or traumatic rupture of the aortic isthmus. The outer circumference of the aortic arch should be safe enough to achieve a good seal with optimal and complete apposition of the modified stent graft on the scallop side. The model should not be used in cases of circumferential aneurysmal degeneration of the aortic arch or chronic dissecting aneurysm; in these cases, bridging stents are required owing to the distance between the scallop and the target vessel. In combination with the strong pulsation of the arch, they would be exposed to mechanical stress that would compromise the seal at the scallop. Branched arch devices are probably more suitable for these cases.¹⁸

The time taken for the device customisation is another potential limitation. Modification of a stent graft to produce the scallop, constrain the device, and resheath it varies (in the authors' experience) from 17 to 33 min, with a mean device modification time of 23 min. This represents the major drawback of this technique for managing thoracic aortic emergencies in haemodynamically unstable patients. Nevertheless, considering that the preparation of the graft can begin independently of the procedure (as soon as the computed tomography scan is available) and the measurements are made, this time often coincides with the preparation of the patient by the anaesthetic team and femoral artery exposure and access. Furthermore, this time is relatively short if it is compared with the time for supra-aortic trunk transposition performed in hybrid procedures.

PMSG offers a quickly available and reproducible option for extending the proximal landing zone to zone 2, 1, or even 0 for emergency aortic arch injuries. This technique allows matching of the variability of the origins of the supra-aortic trunks in an emergency with an "off the shelf" thoracic stent graft device. The procedure does not require aortic arch branch catheterisation, which increases the potential for prolonged catheter and guidewire manipulation in the aortic arch and risk of cerebral embolic events or stroke.

Limitations

This was an experimental study and the PMSGs were used in non-pathological aortic arches. It would be interesting to assess the efficiency of the scalloped stent graft to exclude aneurysm/primary entry tear in aneurysmal or dissected aorta arising from a real three dimensionally printed pathological aortic arch. However, the flexibility, elasticity, and strength of three dimensionally printed aortas are different from real aortas, and assessment of the accurate placement of the scallop under fluoroscopy in real aortas would probably be more appropriate. Furthermore, there exists an obvious legal risk to modifying an existing Food and Drug Administration approved medical device, involving product liability and durability. However, PMSG have been used for several years to treat aortic thoraco-abdominal aneurysms without any problems of device deterioration, with up to four homemade fenestrations,⁵ and these favourable results could be extrapolated to one thoracic stent graft. However, this technique needs to be clinically assessed on pathological aortic arch.

CONCLUSION

PMSGs to extend the proximal landing zones to zones 2, 1, or 0 were feasible in an experimental model with cadaveric aortas. In this experimental study the accuracy of stent graft and scallop deployment over aortic arch branch ostia under fluoroscopy with a 30% oversizing is demonstrated. Its use for total endovascular repair of urgent aortic arch diseases needs to be further investigated.

CONFLICT OF INTEREST

None.

FUNDING

The study was funded by the Société de Chirurgie Vasculaire et Endovasculaire de Langue Française.

REFERENCES

- 1 Cao P, De Rango P, Czerny M, Evangelista A, Fattori R, Nienaber C, et al. Systematic review of clinical outcomes in hybrid procedures for aortic arch dissections and other arch diseases. *J Thorac Cardiovasc Surg* 2012;**144**:1286–300.
- 2 Peterson BG, Eskandari MK, Gleason TG, Morasch MD. Utility of left subclavian artery revascularization in association with endoluminal repair of acute and chronic thoracic aortic pathology. *J Vasc Surg* 2006;**43**:433–9.

- 3 Haulon S, Greenberg RK, Spear R, Eagleton M, Abraham C, Lioups C, et al. Global experience with an inner branched arch endograft. *J Thorac Cardiovasc Surg* 2014;**148**:1709–16.
- 4 Ben Abdallah I, El Batti S, Sapoval M, Abou Rjeili M, Fabiani JN, Julia P, et al. Proximal scallop in thoracic endovascular aortic aneurysm repair to overcome neck issues in the arch. *Eur J Vasc Endovasc Surg* 2016;**51**(3):343–9.
- 5 Georgiadis GS, van Herwaarden JA, Antoniou GA, Hazenberg CE, Giannoukas AD, Lazarides MK, et al. Systematic review of off-the-shelf or physician-modified fenestrated and branched endografts. *J Endovasc Ther* 2016;**23**(1):98–109.
- 6 Canaud L, Gandet T, Khantaline I, Ozdemir BA, Marty-Ané CH, Alric P. Homemade proximal scalloped stent graft for thoracic endovascular aortic repair of zone 2 acute aortic syndrome. *J Thorac Cardiovasc Surg* 2016;**152**:1301–6.
- 7 Canaud L, Alric P, Laurent M, Baum TP, Branchereau P, Marty-Ané CH, et al. Proximal fixation of thoracic stent-grafts as a function of oversizing and increasing aortic arch angulation in human cadaveric aorta. *J Endovasc Ther* 2008;**15**(3):326–34.
- 8 Faure EM, Canaud L, Cathala P, Serres I, Marty-Ané C, Alric P. Human ex-vivo model of Stanford type B aortic dissection. *J Vasc Surg* 2014 Sep;**60**(3):767–75.
- 9 Malina M, Lindblad B, Ivancev K, Lindh M, Malina J, Brunkwall J. Endovascular AAA exclusion: will stents with hooks and barbs prevent stent-graft migration? *J Endovasc Surg* 1998;**5**:310–7.
- 10 Faure EM, Canaud L, Marty-Ané C, Alric P. Hybrid aortic arch repair for dissecting aneurysm. *J Thorac Cardiovasc Surg* 2016;**152**:162–8.
- 11 Canaud L, Hireche K, Berthet JP, Branchereau P, Marty-Ané C, Alric P. Endovascular repair of aortic arch lesions in high-risk patients or after previous aortic surgery: midterm results. *J Thorac Cardiovasc Surg* 2010;**140**:52–8.
- 12 Milewski RK, Szeto WY, Pochettino A, Moser GW, Moeller P, Bavaria JE. Have hybrid procedures replaced open aortic arch reconstruction in high-risk patients? A comparative study of elective open arch debranching with endovascular stent graft placement and conventional elective open total and distal aortic arch reconstruction. *J Thorac Cardiovasc Surg* 2010;**140**:590–7.
- 13 Chiesa R, Melissano G, Tshomba Y, Civilini E, Marone EM, Bertoglio L, et al. Ten years of endovascular aortic arch repair. *J Endovasc Ther* 2010;**17**:1–11.
- 14 Amiot S, Haulon S, Becquemin JP, Magnan PE, Lermusiaux P, Goueffic Y, et al. Fenestrated endovascular grafting: the French multicentre experience. *Eur J Vasc Endovasc Surg* 2010;**39**:537–44.
- 15 Yang J, Xiong J, Liu X, Jia X, Zhu Y, Guo W. Endovascular chimney technique of aortic arch pathologies: a systematic review. *Ann Vasc Surg* 2012;**26**:1014–21.
- 16 Alsafi A, Bicknell CD, Rudarakanchana N, Kashef E, Gibbs RG, Cheshire NJ, et al. Endovascular treatment of thoracic aortic aneurysms with a short proximal landing zone using scalloped endografts. *J Vasc Surg* 2014;**60**:1499–506.
- 17 Spear R, Haulon S, Ohki T, Tsilimparis N, Kanaoka Y, Milne CPE, et al. Subsequent results for arch aneurysm repair with inner branched endografts. *Eur J Vasc Endovasc Surg* 2016;**51**:380–5.
- 18 Tsilimparis N, Debus ES, Von Kodolitsch Y, Wipper S, Rohlfes F, Detter C, et al. Branched versus fenestrated endografts for endovascular repair of aortic arch lesions. *J Vasc Surg* 2016;**64**:592–9.
- 19 Hajibandeh S, Hajibandeh S, Antoniou SA, Torella F, Antoniou GA. Meta-analysis of left subclavian artery coverage with and without revascularization in thoracic endovascular aortic repair. *J Endovasc Ther* 2016;**23**:634–41.
- 20 Cooper DG, Walsh SR, Sadat U, Noorani A, Hayes PD, Boyle JR. Neurological complications after left subclavian artery coverage during thoracic endovascular aortic repair: a systematic review and meta-analysis. *J Vasc Surg* 2009;**49**:1594–601.
- 21 Geisbusch P, Kotelis D, Eschner MM, Hyhlik-Durr A, Bockler D. Complications after aortic arch hybrid repair. *J Vasc Surg* 2011;**53**:935–41.
- 22 Cochennec F, Tresson P, Cross J, Desgranges P, Allaire E, Becquemin JP. Hybrid repair of aortic arch dissections. *J Vasc Surg* 2013;**57**:1560–7.