



HAL
open science

Histological study of the interface of calcium phosphate bioceramics and soft tissue in humans.

Patrick Frayssinet, Jacques Fages

► **To cite this version:**

Patrick Frayssinet, Jacques Fages. Histological study of the interface of calcium phosphate bioceramics and soft tissue in humans.. cellular engineering, 1997, 2 (3), pp.117-120. hal-01740280

HAL Id: hal-01740280

<https://hal.science/hal-01740280>

Submitted on 21 Mar 2018

HAL is a multi-disciplinary open access archive for the deposit and dissemination of scientific research documents, whether they are published or not. The documents may come from teaching and research institutions in France or abroad, or from public or private research centers.

L'archive ouverte pluridisciplinaire **HAL**, est destinée au dépôt et à la diffusion de documents scientifiques de niveau recherche, publiés ou non, émanant des établissements d'enseignement et de recherche français ou étrangers, des laboratoires publics ou privés.

Histological study of the interface of calcium phosphate bioceramics and soft tissue in humans

P. Frayssinet^{1,3} J. Fages²

¹ Bioland 132 Rte d'Espagne, 31100 Toulouse, France

² Ecole des mines d'Albi, Albi, France

³ Laboratoire du Tissu Osseux et des Pathologies Ostéarticulaires, Université Paul Sabatier, Toulouse, France

Abstract—*The differentiation of mesenchymal tissue into bone tissue when in contact with different forms of calcium phosphate ceramics implanted within extraskelatal sites in different animals has been reported. The osteogenic effects of calcium phosphate ceramics have been demonstrated in several animal species. Four biopsies from HA-ceramics were obtained, implanted in bony sites of humans, which failed to be osteointegrated for more than one year. Two kinds of ceramics with different characteristics were studied. A histological analysis of the soft tissue/ceramic interface was carried out. The ceramics were embedded in an identical connective tissue. The interface with the ceramic consisted of collagen bundles parallel to the ceramic surface. Certain ceramics showed at their surface, a tissue matrix with the staining ability of bone, although no evidence of osteogenic cells or osteoid was found at the matrix surface. The pores were filled with a hyaline tissue containing a few cells dispersed within the hyaline matrix. Although this study could not be performed under the same conditions as in animals, no bone formation was induced by these ceramics implanted in the connective tissue suggesting that, in humans, the osteogenic effect of this material is inconstant, or related to specific characteristics.*

Keywords—osteinduction, osteogenicity, calcium phosphate ceramics, bone

1 Introduction

Porous hydroxyapatite ceramics and, more generally, calcium phosphate ceramics are used as bone substitutes or as carriers for hybrid materials. Such materials are considered to be bioactive and osteoconductive. Bioactivity would be due to epitaxial nucleation of carbonated apatite crystals at the surface of ceramic grains (HEUGHEBAERT *et al.*, 1988). Their integration into the newly formed bone generally consists of a biological process that can be divided into several stages (FRAYSSINET *et al.*, 1993): (i) invasion by loose connective tissue once the post-operative haematoma has been removed (ii) differentiation of osteoblasts from fibroblast-like cells in the loose connective tissue at the material surface (iii) synthesis of an immature bone matrix at the material surface (iv) remodelling of the bone and implanted materials leading to slow replacement of the material by mature bone.

The osteoconductive properties of the material imply that, for osseointegration, the material must be implanted in a site supplying osteogenic stem or pre-determined cells which ensure its integration.

Some recent reports have described bone formation in porous calcium phosphate ceramics when implanted in ectopic sites in rodents, dogs and monkeys (RIPAMONTI *et al.*, 1991, 1992, 1993; YAMASAKI *et al.*, 1992; TOTH *et al.*, 1993; KLEIN *et al.*, 1994; YANG *et al.*, 1996). The characteristics of the

ceramics used in these experiments were different as were the sites and the animals in which they were implanted.

YANG *et al.* (1996) reported the implantation of materials with identical characteristics in various tissues of dogs, pigs, goats, rabbits and rats. Bone formation could be detected in a few pores of some specimens harvested from dogs and pigs after 45 days when implanted in muscles. After 60 and 90 days, bone formation could be observed in all intramuscularly implanted specimens in dogs and pigs. An extensive amount of mainly trabecular bone had developed in the pore regions after 120 days. Unlike the results in dogs and pigs, no histologically detectable bone differentiation was found in any intramuscularly and subcutaneously implanted specimen in rabbits, goats or rats until 120 days.

Several authors have demonstrated that in humans, calcium phosphate ceramics with a very large range of characteristics are integrated when implanted in bone tissue (CARRANZA *et al.*, 1987; STAHL *et al.*, 1987; INOUE *et al.*, 1993; NICHOLAS and LANGE, 1994; OGUSCHI *et al.*, 1995). NUNERY *et al.* (1993) have shown that ocular implants, made of HA-ceramics, retrieved from seven human patients five to seven months after insertion in the anophthalmic socket had bone and marrow within the porous spaces.

The aim of this study was to histologically evaluate the osteogenic potential of calcium phosphate ceramics with different characteristics implanted in humans. The biopsies

were taken from non-integrated bone substitutes when the osteosynthesis material was surgically removed. The material chosen for this examination was implanted in bone sites which did not show any ingrowth from the edge of the implanted bone sites to the porous material, on X-ray pictures, suggesting that the material was implanted within a loose connective tissue.

2 Materials and methods

All the biopsies were obtained with the patient's agreement during surgical removal of the osteosynthesis material.

2.1 Characteristics of the implanted ceramics

Two different ceramics were studied:

- 3–5 mm porous ceramic granules. The X-ray diffraction pattern of the granules showed that they were composed of hydroxyapatite (HA), 15.5% of β -TCP, and <2% of CaO. The mean pore size was 70 μ m and due to the manufacturing process with a porogenous agent, the pores were not interconnected. The porosity was 60% and the mean grain size 15 μ m. The trace elements, and Ca/P ratio were not specified.
- Parallelepiped (10×10×20 mm) porous ceramics composed of 75% HA and 25% β -TCP. The pore size ranged between 500–2000 μ m, the porosity was 70% and the pores were interconnected. The mean grain size was 15 μ m. The heavy metal content was within the range specified by the ASTM standard.

2.2 Clinical cases

Case 1: arthrodesis beneath the astragalus in the middle of the tarsus as an aftermath to a fracture of the calcaneum. The bone site was cleaned and all the available space filled with granules. The biopsy was carried out 12 months later when the osteosynthesis material was removed. The grains were embedded in material with the appearance of connective tissue.

Case 2: a sus-condylar bone cyst was filled with HA-granules for 20 months. The biopsy was carried out during removal of the osteosynthesis material.

Case 3: tibial plateau bone cyst filled with HA-granules for 12 months.

Case 4: open fracture of the upper and intercondylar regions which, 18 months later, required filling with ceramics due to the presence of a defect in the anterior-lateral face of the distal femur. Implantation time was nine months.

2.3 Section preparation

The biopsies were fixed in a 4% formaldehyde solution or absolute ethanol for 12 h. They were then dehydrated in increasing ethanol solutions and embedded in polymethylmethacrylate or in hydroxyethylmethacrylate (HEMA). 7 μ m sections were obtained with a calcified tissue microtome (Reichert type E). The methylmethacrylate was then dissolved in xylol and the sections stained either with Masson's trichrome, fucsin-toluidine or by Von Kossa method to reveal the mineralised tissues. Serial sections were performed to check that no osteoconductivity had occurred at the ceramic surface.

Detection of acid phosphatase and alkaline phosphatase was performed on HEMA sections. Substituted naphthol AS phosphates in conjunction with either diazonium salt were used to reveal the alkaline (Sigma kit 86) and tartrate resistant acid (Sigma kit 387) phosphatase activity (TRAP).

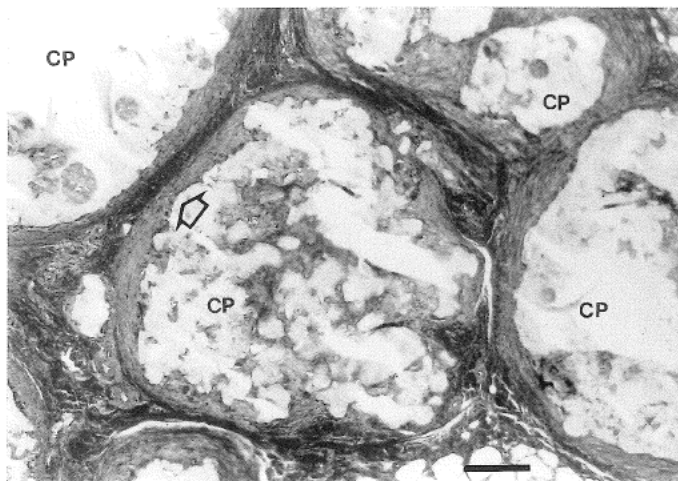


Fig. 1 Section of biopsy from Case 1. The porous calcium phosphate granules (CP) are embedded within connective tissue. Collagen bundles (\Rightarrow) surround the implant surface and a small number of cells can be found in the vicinity of the ceramic. Toluidine blue. Bar: 500 μ m.

3 Results

Case 1: No trabeculae were found in the connective tissue passing from the implanted bone to the ceramic. The granules were embedded in a dense connective tissue surrounding the material with ingrowth into the ceramic pores (Figs 1 and 2). Large zones of the connective tissue were hyalinised. Histiocytes were found within the connective tissue between the collagen bundles. Most of them contained TRAP+ granules. Condensation of collagen had occurred at the material contact. The small region stained blue by Masson's trichrome at the ceramic contact suggested a bone matrix formation. However, no osteoblasts or osteocytes could be evidenced by the detection of alkaline phosphatase activity and the Von Kossa staining showed it to be unmineralised tissue.

Case 2: No bone was evidenced in the connective tissue surrounding the material. The granules were included in a fibrillar tissue containing a small number of mainly fibroblast-like cells which did not show any alkaline or acid phosphatase activity. Some layers of blue stained tissue were visible in contact with the granules. No osteoblasts, or osteoid could be found at their surface. Very few cells were detected in these

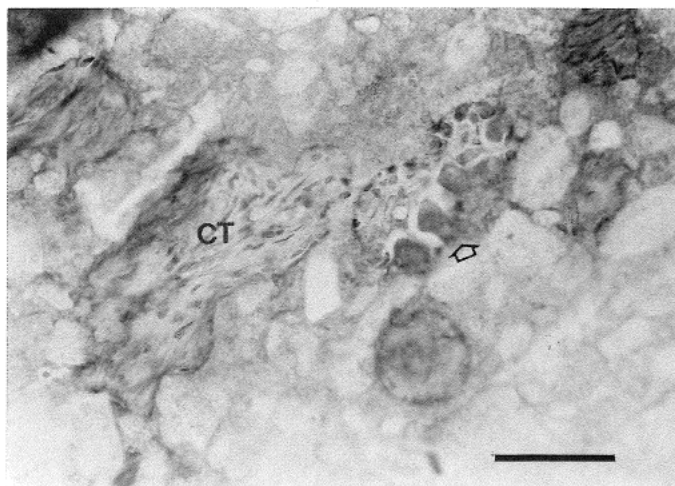


Fig. 2 Pores generally contain a connective tissue (CT) composed of collagen and fibroblasts. At the material surface, some TRAP+ mono or multinucleated cells are present (\Rightarrow). Acid phosphatase staining and toluidine blue. Bar: 200 μ m.

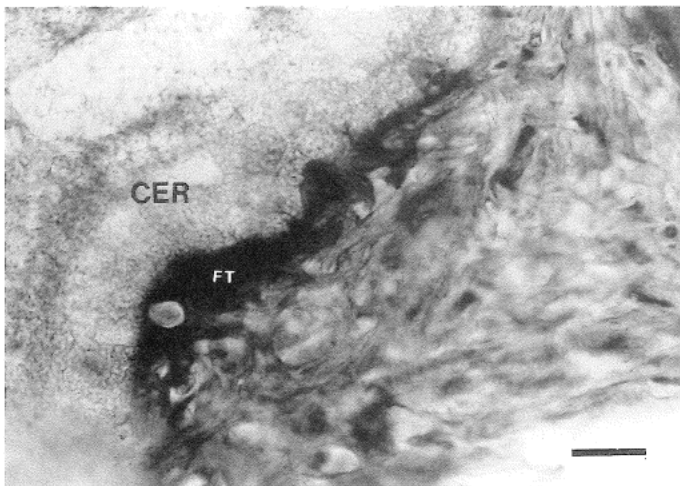


Fig. 3 A bone-like matrix (FT) can be detected at the surface of some granules (CER). However this matrix is unmineralized and no osteoid or osteoblast covering the tissue can be found. The cells shown in this matrix are alkaline phosphatase negative. Toluidine blue. Bar: 50 μm .

layers.

Case 3: No bone could be demonstrated in the tissue around the granules. The pores were filled with dense connective tissue containing cells resembling osteocytes but no osteoblasts or osteoid could be found (Fig. 3). Many histiocytes based on their TRAP activity could be detected between these collagen condensations.

Case 4: No bone bridging the recipient bone walls to the material was apparent. The ceramic pores were filled with stromal tissue surrounding small vessels. Multinucleated TRAP+ cells were visible at the ceramic surface when the ceramic walls were free of collagen (Fig. 4). Most of the surface was coated by collagen in parallel to the pore wall surface. This collagen coating sometimes formed bridges over the pore centre, and was sometimes covered by a cell layer osteoblast lining cells which did not show any phosphatase activity. This collagen layer was never mineralised however, and the cells on its surface synthesised an extracellular matrix which looked like osteoid tissue.

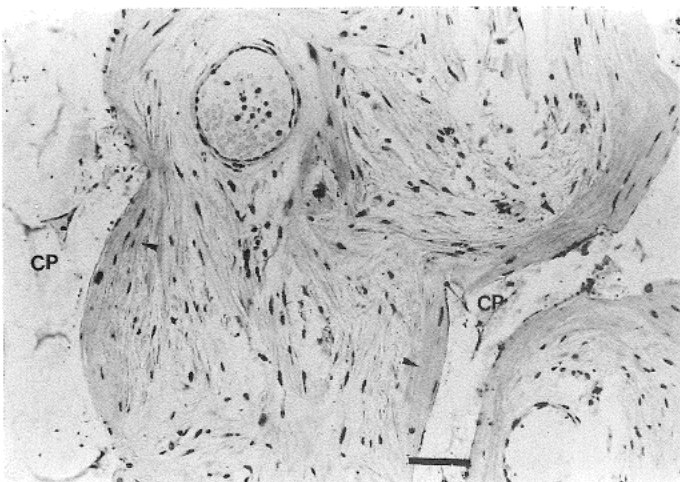


Fig. 4 Section of biopsy from case 4. There is a coating of collagen layers (\Rightarrow) at the calcium phosphate surface (CP) that mimics the deposition of a bone matrix. The collagen coating was not mineralised, and no osteoid is apparent. Toluidine blue. Bar: 100 μm .

4 Discussion

This histological study was carried out for a much longer period than that required to evidence an osteogenic effect in animals (YANG *et al.*, 1996). The connective tissue that had invaded the bone defect did not contain pre-determined osteogenic cells in any of the cases as no bone link existed between the defect walls and the material, and no alkaline phosphatase activity was detected in the cell membranes. The foreign body reaction occurring at the ceramic contact, as shown by the detection of cell TRAP activity was mild.

We did not find any bone formation in contact with these materials. The peculiar connective tissue pattern at the material contact could not be mistaken for bone tissue as no osteoid or osteoblasts could be detected. Furthermore, none of these formations was mineralised. The characteristics of the ceramics observed in this study were different to those which provoked osteogenic differentiation in animals. However, as several types of ceramic induced bone development at their contact when implanted in animals, it seems that one of the most important characteristics of an osteogenic material would be the calcium phase composition. Bone formation was obtained by KLEIN *et al.* (1994) using ceramics made of HA and α -TCP with a very large range of porosity and pore size. YAMASAKI and SAKAI (1992) obtained a bone formation with ceramic composed of pure HA with very small pore size (2–10 μm). In experiments on calcium phosphate ceramic implantation in heterotopic sites in the baboon, bone was only found in porous HA in block configuration. Bone did not form in identical porous HA in particulate configuration (VAN EEDEN and RIPAMONTI, 1994). Earlier experiments using hydroxylapatite ceramics pretreated with BMPs in heterotopic sites in the rat demonstrated that expression of the osteogenic phenotype was solely confined to porous HA in block configuration (REDDI, 1992). Bone morphogenetic proteins did not induce bone differentiation when combined with granules of porous HA with identical pore dimensions. No bone was formed at the contact of dense granules implanted in various sites in different animals (KLEIN *et al.*, 1994, YAMASAKI and SAKAI, 1992). It results from these different reports that, to be osteogenic, ceramics must be made of HA associated with α or β -TCP in a range of 0 to 40% and their pore size must be within a range of 5 to 500 μm . The interconnection is not necessary.

Moreover, osteogenesis could be dependent, as has been demonstrated by YANG *et al.*, (1996) on the species of animal implanted. This effect of species role is, however, difficult to assess as in rodents for example, bone formation has been both reported or refuted.

The results published by NUNERY *et al.* (1993) on histological analysis of hydroxyapatite spheres in the anophthalmic sockets showed that osteoinduction may occur in human beings in certain circumstances. No characteristics of the implanted ceramics were given. The histological pictures revealed that the ceramics were porous with a pore size of several hundred μm and that the pores were interconnected.

It has been hypothesised that the osteogenic effect of the calcium phosphate shown in animals results from adsorption of BMPs produced by kidneys. This protein family shows an affinity for calcium phosphate compounds and when associated with calcium phosphate ceramics, these proteins induce extracellular ossification (URIST *et al.*, 1983, 1984; RIPAMONTI 1991; RIPAMONTI *et al.* 1992, 1993). It is difficult to explain why this is not the case for all mammal species as no difference in BMPs biology has ever been demonstrated in such species. Furthermore, bone formation would be proportional to the surface area of the ceramic as the amount of adsorbed protein is related to the surface area. This was not shown in the papers

reporting ceramic osteogenic properties in animals. Bone formation was not homogeneously distributed throughout the ceramic although there were signs of vascularisation in the pores containing connective tissue. Bone formation preferentially occurred in internal pores in some samples implanted in dogs (YANG *et al.*, 1996).

Another explanation for bone formation could be the constitution of a micro-environment within the ceramic pores in which certain autocrine or paracrine factors would be able to attain the critical concentration necessary for osteoblast differentiation. The necessity for a special micro-environment for bone formation has already been demonstrated *in vitro* using the tissue culture method (TENENBAUM and HEERSCHE, 1986). This hypothesis could explain the preferential bone formation within calcium phosphate ceramic pores rather than in the external pores.

5 Conclusions

No osteogenic effect could be demonstrated at the surface of two kinds of porous calcium phosphate ceramics, as had previously been reported in some mammal species and once in humans. The integration failure of the ceramics examined indicates that specific characteristics have to be present to obtain an osteogenic effect. Calcium phosphate ceramics seem to be appropriate materials for use as carriers for osteogenic stem cells in bioartificial bone as they are able to induce bone formation in certain cases.

References

- CARRANZA, F. A., KENNEY, E. B., LEKOVIC, V., TALAMANTE, E., VALENCIA, J. and DIMITRIJEVIC, B. (1987): 'Histologic study of healing of human periodontal defects after placement of porous hydroxyapatite implants', *J. Periodontol*, **58**, pp. 682-688
- FRAYSSINET, P., TROUILLET, J. L., ROUQUET, N., AZIMUS, E. and AUTEFAGE, A. (1993): 'Osseointegration of macroporous calcium phosphate ceramics having a different chemical composition', *Biomaterials*, **14**, pp. 423-429.
- HEUGHEBAERT, M., LEGEROS, R. Z., GINESTE, M., GUILHEM, A. and BONEL, G. (1988): 'Physicochemical characterization of deposits associated with HA-ceramics implanted in non-osseous sites', *J. Biomed. Mater. Res.*, **22**, pp. 257-268.
- INOUE, O., IBARAKI, K., SHIMABUKURO, H., SHINGAKI, Y. (1993): 'Packing with high-porosity hydroxyapatite cubes alone for the treatment of simple bone cyst', *Clin. Orthop. Rel. Res.* **293**, pp. 287-292.
- KLEIN, C., DE GROOT, K., CHEN, W., LI, Y. and ZHANG, X. (1994): 'Osseous substance formation induced in porous calcium phosphate ceramics in soft tissues', *Biomaterials*, **15**, pp. 31-34.
- NICHOLAS, R. W. and LANGE, T. A. (1994): 'Granular tricalcium phosphate grafting of cavitory lesions in human bone', *Clin. Orthop. Rel. Res.* **306**, pp. 197-203.
- NUNERY, W. R., HEINZ, G. W., BONNIN, J. M., MARTIN, R. T. and CEPELA, M. A. (1993): 'Exposure rates of hydroxyapatite spheres in the anophthalmic socket: histopathological correlation and comparison with silicone sphere implants', *Ophthalmic Plastic Reconstructive Surg.* **9**, pp. 96-104.
- OGUSHI, H., ISHIKAWA, K., MIZOUE, K., SETO, K., EGUSHI, G. (1995): 'Long-term histological evaluation of hydroxyapatite ceramics in humans', *Biomaterials*, **16**, pp. 33-38.
- REDDI, A. H. (1992): 'The critical role of geometry of porous hydroxyapatite delivery system in induction of bone by osteogenin, a bone morphogenetic protein', *Matrix*, **12**, pp. 202-212.
- RIPAMONTI, U. (1991): 'The morphogenesis of bone in replicas of porous hydroxyapatite from conversion of calcium carbonate exoskeletons of coral', *J. Bone Joint Surg.* **73A**, pp. 692-703.
- RIPAMONTI, U., MA, S. S. and REDDI, A. H. (1992): 'Induction of bone in composites of osteogenin and porous hydroxyapatite in baboons', *Plast. Reconstruct. Surg.*, **89**, pp. 731-740.
- RIPAMONTI, U., VAN DEN HEEVER, B. and VAN WIGK, J. (1993): 'Expression of the osteogenic phenotype in porous hydroxyapatite implanted extraskeletally in baboons', *Matrix*, **13**, pp. 491-502.
- STAHL, S. S. and FROUM, S. J. (1987): 'Histologic and clinical responses to porous hydroxyapatite implants in human periodontal defects', *J. Periodontol*, **58**, pp. 689-695.
- TENENBAUM, H. C. and HEERSCHE, J. N. M. (1986): 'Differentiation of osteoid-producing cells *in vitro*: possible evidence for the requirement of a microenvironment', *Calcif. Tissue Int.*, **38**, pp. 262-267.
- TOTH, J. M., LYNCH, K. L. and HACKBARTH, D. A. (1993): 'Ceramic-induced osteogenesis following subcutaneous implantation of calcium phosphates' in DUCHEYNE, P. and CHRISTIANSEN, O. (Eds): 'Bioceramic. Vol 6' (Butterworth-Heinemann, New York) pp. 9-14.
- URIST, M. R., DELANGE, R. M. and FINERMAN, G. A. M. (1983): 'Bone cell differentiation and growth factors', *Science*, **220**, pp. 680-686.
- URIST, M. R., LIETZE, A. and DAWSON, E. (1984): ' β -tricalcium phosphate delivery system for bone morphogenetic protein', *Clin. Orthop. Rel. Res.* **187**, pp. 277-280.
- VAN EEDEN, S. P. and RIPAMONTI, U. (1994): 'Bone differentiation in porous hydroxyapatite in baboons is regulated by the geometry of the substratum: implications for reconstructive craniofacial surgery', *Plast. Reconstr. Surg.* **93**, pp. 959-966.
- YAMASAKI, H. and SAKAI, H. (1992): 'Osteogenic response to porous hydroxyapatite ceramics under the skin of dogs', *Biomaterials*, **13**, pp. 308-312.
- YANG, Z., YUAN, H., TONG, W., ZOU, P., CHEN, W. and ZHANG, X. (1996): 'Osteogenesis in extraskeletally implanted porous calcium phosphate ceramics: variability among different kinds of animals', *Biomaterials*, **17**, pp. 2131-2137.