



**HAL**  
open science

**Coxiella burnetii Multilevel Disk Space Infection,  
Epidural Abscess, and Vertebral Osteomyelitis  
Secondary to Contiguous Spread From Infected  
Abdominal Aortic Aneurysm or Graft: Report of 4  
Cases Acquired in the US and Review of the Literature**

Abinash Virk, Maryam Mahmood, Manju Kalra, Thomas C. Bower, Douglas  
R. Osmon, Elie F. Berbari, Didier Raoult

► **To cite this version:**

Abinash Virk, Maryam Mahmood, Manju Kalra, Thomas C. Bower, Douglas R. Osmon, et al.. Coxiella burnetii Multilevel Disk Space Infection, Epidural Abscess, and Vertebral Osteomyelitis Secondary to Contiguous Spread From Infected Abdominal Aortic Aneurysm or Graft: Report of 4 Cases Acquired in the US and Review of the Literature. Open Forum Infectious Diseases, 2017, 4 (4), 10.1093/ofid/ofx192. hal-01730983

**HAL Id: hal-01730983**

**<https://hal.science/hal-01730983v1>**

Submitted on 24 Apr 2018

**HAL** is a multi-disciplinary open access archive for the deposit and dissemination of scientific research documents, whether they are published or not. The documents may come from teaching and research institutions in France or abroad, or from public or private research centers.

L'archive ouverte pluridisciplinaire **HAL**, est destinée au dépôt et à la diffusion de documents scientifiques de niveau recherche, publiés ou non, émanant des établissements d'enseignement et de recherche français ou étrangers, des laboratoires publics ou privés.

# *Coxiella burnetii* Multilevel Disk Space Infection, Epidural Abscess, and Vertebral Osteomyelitis Secondary to Contiguous Spread From Infected Abdominal Aortic Aneurysm or Graft: Report of 4 Cases Acquired in the US and Review of the Literature

Abinash Virk,<sup>1</sup> Maryam Mahmood,<sup>1</sup> Manju Kalra,<sup>2</sup> Thomas C. Bower,<sup>2</sup> Douglas R. Osmon,<sup>1</sup> Elie F. Berbari,<sup>1</sup> and Didier Raoult<sup>3</sup>

<sup>1</sup>Division of Infectious Diseases, Department of Medicine, <sup>2</sup>Division of Vascular Surgery, Department of Surgery, Mayo Clinic, Rochester, Minnesota; <sup>3</sup>Universit  de la Mediterranee, Marseille, France

**Background.** Chronic *Coxiella burnetii* infections such as vertebral osteomyelitis caused by contiguous spread from an infected abdominal aortic graft or aneurysm have been rarely reported and are associated with significant morbidity and mortality.

**Methods.** We present the first four reported US acquired cases of *Coxiella burnetii* vertebral osteomyelitis caused by contiguous spread from an infected abdominal aortic graft or aneurysm.

**Results.** Presenting symptoms included progressive back pain, malaise, and weight loss with recent or remote animal exposure. Typical imaging findings demonstrated a peri-aortic collection with extension to the paraspinal muscles and vertebrae. Antibiotic regimens included doxycycline with either hydroxychloroquine or a quinolone for at least 2 years or as chronic suppression.

**Conclusions.** *C. burnetii* vertebral osteomyelitis is rare and can occur by contiguous spread from an abdominal aneurysm or vascular graft infection. It should be suspected in patients where pre-antibiotic cultures are negative with animal/farming exposure.

**Keywords.** *Coxiella burnetii*; infected abdominal aortic aneurysm; Q fever; vascular graft; vertebral osteomyelitis.

*Coxiella burnetii* infections occur sporadically worldwide and are more common near farming communities or communities with animal exposure. Although most infections go unnoticed, chronic infections, such as infective endocarditis, cause significant morbidity. Other noncardiac endovascular involvement such as vascular aneurysm and/or graft infections have rarely been reported from other countries. We report 4 cases of *C. burnetii* multilevel disc space infection and vertebral osteomyelitis caused by contiguous spread from infected abdominal aortic grafts and/or mycotic aneurysm and review the literature of noncardiac endovascular and osteoarticular chronic infections.

## METHODS

We conducted a retrospective review of all *C. burnetii* abdominal aortic aneurysm or aortic graft infections with associated vertebral osteomyelitis presenting at our institution from January

2007 to July 2017. A real-time polymerase chain reaction (PCR) assay, which rapidly detects *C. burnetii* DNA by targeting a sequence of the shikimate dehydrogenase gene (*aroE*) unique to *C. burnetii*, was used to confirm infection from tissue and blood specimens unless otherwise stated. Blinded clinical validation of this PCR assay demonstrated 100% sensitivity and specificity when used on cardiac valve tissue [1]. Indirect immunofluorescence testing for *C. burnetii* IgG and IgM antibodies was performed on a Focus Diagnostics assay (package inserts: Q fever IFA IgG Focus Diagnostics, Inc., Cypress, California; Q fever IFA IgM, Focus Diagnostics, Inc., Cypress, California).

A systematic literature search for additional reported cases of noncardiac endovascular and osteoarticular chronic *C. burnetii* infections was performed with the assistance of a specialist medical librarian, guided by the authors. The search was restricted to English-language publications from January 1966 to July 2017; findings from conference proceedings were excluded.

## Case 1

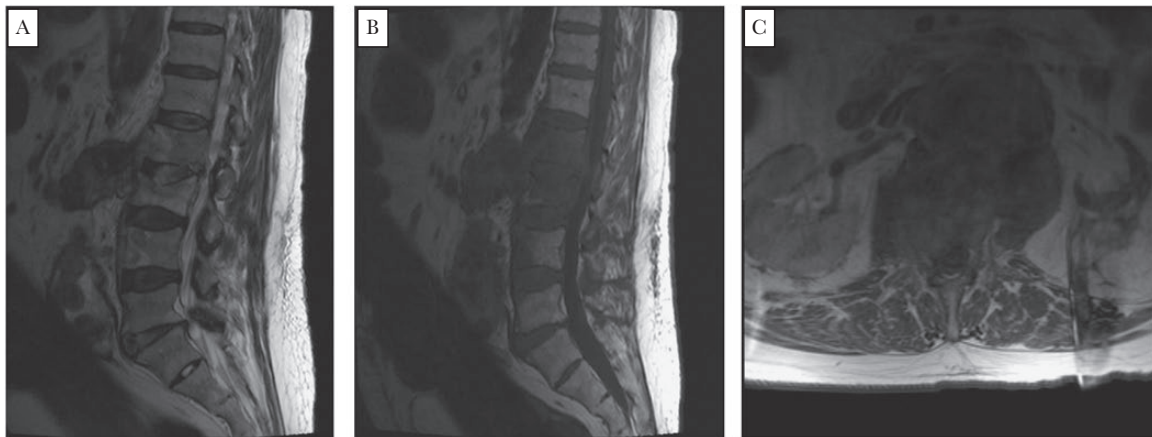
A 74-year-old male farmer from Iowa with a history of hypertension and coronary artery disease underwent a bifurcated aorto-iliac Dacron graft repair of an abdominal aortic aneurysm (AAA) in May 2005. In early 2006, he was treated for a methicillin-resistant *Staphylococcus aureus* (MRSA) superficial surgical site infection of an abdominal wall hernia repair. There was no documented MRSA blood stream infection; additional details about this infection are not known. The

Received 12 April 2017; editorial decision 27 August 2017; accepted 31 August 2017.

Correspondence: A. Virk, MD, Division of Infectious Diseases, Department of Medicine, Mayo Clinic, 200 1st Street SW, Rochester, MN 55905 (Virk.Abinash@mayo.edu).

## Open Forum Infectious Diseases®

© The Author 2017. Published by Oxford University Press on behalf of Infectious Diseases Society of America. This is an Open Access article distributed under the terms of the Creative Commons Attribution-NonCommercial-NoDerivs licence (<http://creativecommons.org/licenses/by-nc-nd/4.0/>), which permits non-commercial reproduction and distribution of the work, in any medium, provided the original work is not altered or transformed in any way, and that the work is properly cited. For commercial re-use, please contact [journals.permissions@oup.com](mailto:journals.permissions@oup.com)  
DOI: 10.1093/ofid/ofx192



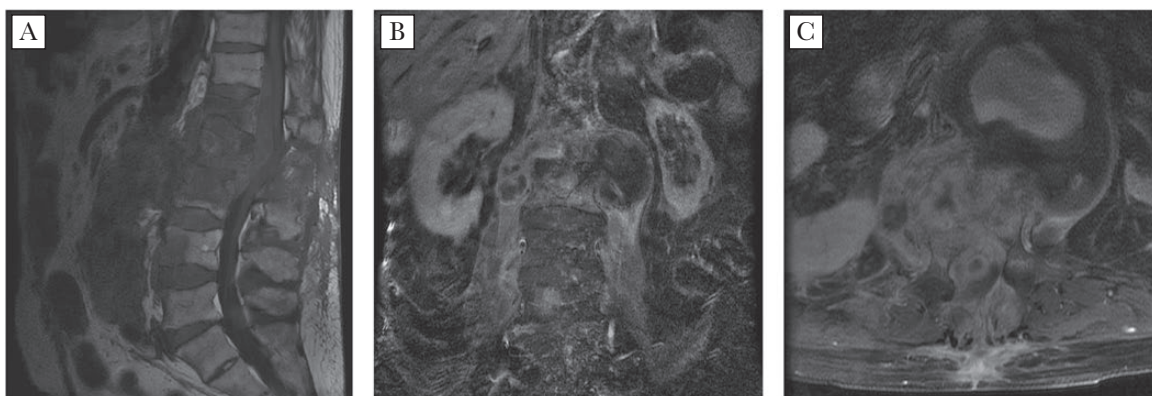
**Figure 1.** Lumbar spine MRI with psoas muscle and T10 to L3 epidural abscess, L1, L2, and L3 osteomyelitis. Images: (A) sagittal T2, (B) sagittal T1, and (C) axial.

patient remained well until January 2007, when he developed progressive back pain. An MRI in mid-March 2007 (Figure 1) showed a left psoas muscle and T10-L3 epidural abscess with L1-L3 osteomyelitis. An open debridement of the lumbar vertebrae and epidural abscess was performed. All obtained surgical cultures were negative for bacterial (aerobic and anaerobic), fungal, and mycobacterial organisms at 6 weeks of incubation. The patient did not receive any antimicrobial therapy prior to culture ascertainment. A tuberculin skin test (TST), Brucella, and Bartonella serologies were also negative. He completed a 6-week course of empiric vancomycin without improvement in back pain. The patient denied fevers, chills, sweats, abdominal pain, or new neurologic symptoms. He denied overseas travel. Exposures included deer hunting, raising livestock, and drinking unpasteurized milk within the past year. Due to persistent symptoms, he was transferred to our institution on May 29, 2007. On examination at admission, his temperature was 36.9°C, BP was 131/94 mmHg, and pulse was 89/min. He was nontoxic-appearing and had a soft 1/6 systolic murmur and tenderness on lumbar spinal percussion. Laboratory tests showed

a hemoglobin of 10 g/dL, WBC of  $6.4 \times 10^9/L$ , platelets of  $107 \times 10^9/L$ ; serum Cr of 1.4 mg/dL, sedimentation rate of 53 mm/h, C-reactive protein (CRP) of 3.6 mg/dL (normal reference range  $< 0.8$  mg/dL), and normal liver function tests.

Computerized tomography (CT) of the abdomen and pelvis and magnetic resonance imaging (MRI) of the thoracolumbar spine (Figure 2) in May 2007 showed diffuse enhancement of L1, L2, and L3 and the disk spaces of L5-S1 and L2-L3, an epidural abscess extending from T11 to L3, and an L2 fracture with destruction of the body. Paraspinal soft tissues and psoas muscles were thickened and enhanced bilaterally with a new right psoas muscle abscess. There was enhancement of the abdominal aortic graft from T10 to the level of proximal common iliac arteries and an area of aneurysmal dilatation above the graft that was worrisome for a mycotic aneurysm.

Additional serologic testing performed in May 2007 noted negative blood cultures obtained off antimicrobial therapy. Fungal, *Francisella tularensis*, Brucella, Bartonella serologies, TST, and tuberculosis interferon-gamma release assay (TB-IGRA) were all negative. The *C. burnetii* IgG phase 1 titer was 1:1024, and the



**Figure 2.** Thoracolumbar spine MRI with diffuse enhancement of L1-L3, epidural abscess extending from T11 to L3, L2 fracture, paraspinal soft tissue and psoas muscles thickening and enhancement, and right psoas muscle abscess. Images: (A) sagittal T2, (B) sagittal T1, and (C) axial.

IgM phase 1 titer was  $\geq 1:16$ . The phase 2 titers of IgG 1:256, and IgM  $< 1:16$  was consistent with a chronic infection. A transesophageal echocardiogram (TEE) showed no valvular abnormalities.

On June 1, 2007, the patient underwent a temporary axillo-femoral bypass; explantation of the infected graft and mycotic aneurysm; insertion of rifampin-soaked Dacron aorto-bi-iliac, celiac, superior mesenteric, and right renal grafts nested away from the infected field; and soft tissue and L1, L2 debridement (Figure 3). Histopathologic examination of explanted tissue revealed granulomas with neutrophilic inflammation. Aortic and vertebral tissues were sent for cultures and were negative for bacteria, fungi, and mycobacteria. *C. burnetii* DNA PCR assay using the *htpAB*-associated element was positive from aortic aneurysm tissue and vertebral body tissue; in addition, *C. burnetii* was able to be cultured from shell-vial cultures using human embryonic lung fibroblasts inoculated by aortic aneurysm tissue and vertebral body tissue (Figure 4) at a specialist research laboratory (Unité des Rickettsies, Université de la Méditerranée, Marseille, France) [2, 3]. The patient was started on doxycycline and ciprofloxacin; the latter was subsequently replaced with hydroxychloroquine. His course was complicated by an acute myocardial infarction, congestive heart failure, bowel perforation, and an intra-abdominal abscess with sepsis. After a prolonged hospitalization and discussions with family, life support was withdrawn 55 days after surgery.

#### Case 2

A 60-year-old female from North Dakota underwent an urgent repair for a leaking abdominal aneurysm using an aorto-bi-iliac polyester graft in July 2009. After her aneurysm repair, she developed progressive back pain, unintentional weight loss, and gait instability. Her medical history included hypertension, hyperlipidemia, chronic obstructive pulmonary disease, coronary artery disease, and pulmonary carcinoid status post-wedge resection. She lived on a farm with animal exposure 20 years ago; there was no other known animal exposure or international travel.

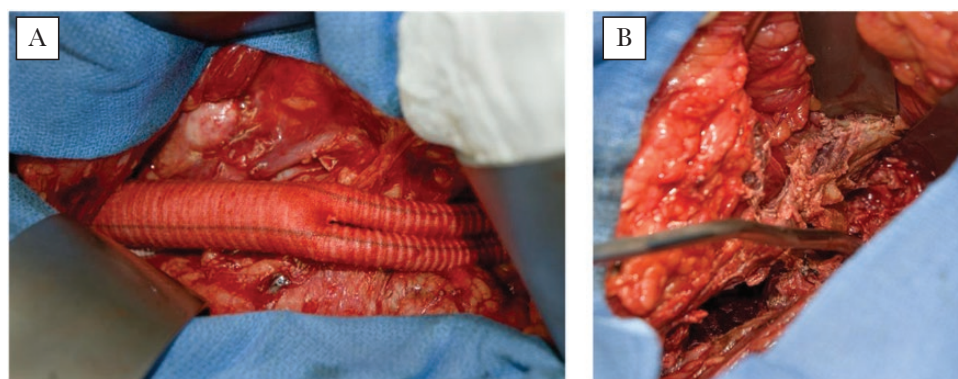
A CT of the lumbar spine showed erosive L2-L4 vertebral changes with complex L2-L3 fractures. Fluid and air were noted

around the aortic graft, with a paraspinal phlegmon along the psoas muscle. A CT-guided aspiration and L3 vertebral body biopsy tissue were negative for bacterial, fungal, and mycobacterial growth (off antimicrobials).

Transthoracic echocardiography was negative for evidence of endocarditis. A 2-staged surgery was performed, the first for the spine debridement and stabilization with hardware fixation. Tissue and bone cultures remained negative. Pathology noted chronic inflammation, giant cell reaction, calcification, and focal necrosis. Five days later, she underwent resection of the infected aorto-bi-iliac graft, debridement of the aneurysm sac and peri-aortic tissues, and insertion of a rifampin-soaked Hemashield aorto-bi-iliac graft wrapped with omentum. Postoperation, she was placed on empiric vancomycin and meropenem. Operative cultures remained negative. Pathology showed necrotizing granulomatous inflammation with negative stains for bacteria, fungi, and mycobacteria. TB-IGRA, fungal and Bartonella serologies, and urine fungal antigen testing were negative. *C. burnetii* serologies were an IgG phase 1 titer of 1:1024 and an IgM phase 1 titer of  $< 1:16$ . The phase 2 titers were an IgG of 1:256 and an IgM of  $< 1:16$ . PCR for *C. burnetii* was positive from the aortic graft and bone. Antibiotics were changed to ciprofloxacin and doxycycline, which she continued to date with anticipated chronic indefinite suppression. Her serologies at 4.5 years postsurgery were an IgG phase 1 titer of 1:1024 and phase 2 IgG titers of 1:128. She was clinically stable from the infection perspective at last follow-up, 6.5 years after surgery.

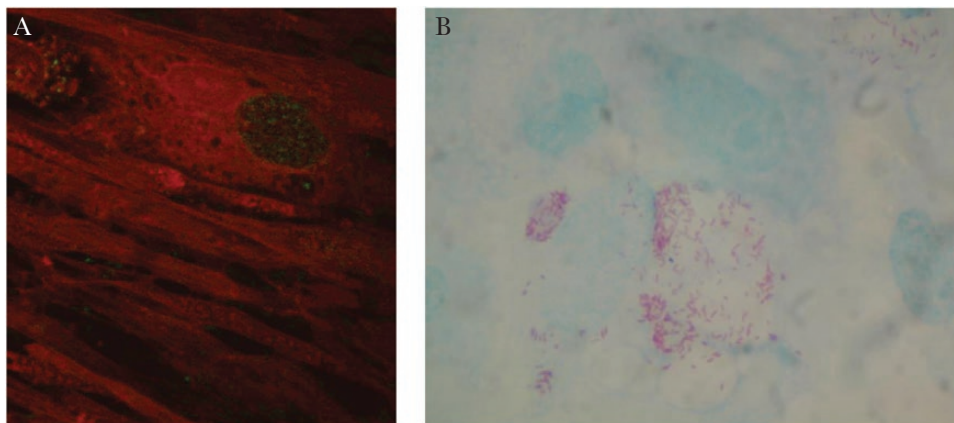
#### Case 3

A 57-year-old female from South Dakota with a known 3.6 cm AAA was diagnosed with metastatic colon adenocarcinoma in March 2009, for which she underwent diverting ileostomy and bowel resection. She completed chemotherapy with fluorouracil, folinic acid, oxaliplatin, and bevacizumab in April 2010. In July 2010, a CT screen of the abdomen showed a fluid collection consistent with hematoma surrounding the distal aorta with stable aneurysm size. She had no intervention at that time. In January 2011, a repeat CT of the abdomen/pelvis showed



**Figure 3.** (A) Vascular debridement and reconstruction with rifampin-soaked graft. (B) Debridement of the vertebrae.





**Figure 4.** (A) Direct immunofluorescence staining with anti-*Coxiella* polyclonal antiserum used to confirm growth of *C. burnetii* in human fibroblast cells inoculated with aortic aneurysm tissue. Green fluorescent areas indicate the presence of *Coxiella burnetii*. (B) Presence of *C. burnetii* by Gimenez staining in human fibroblast cells inoculated with aortic aneurysm tissue.

a 4.3 cm × 4 cm AAA with considerable intraluminal thrombus, thickening of the anterior and posterolateral walls, and an irregularly shaped infiltrative-appearing structure between the aorta and left psoas muscle. Erosive changes of the anterior margins of multiple vertebral bodies were increased compared with July 2010. The patient underwent extensive retroperitoneal debridement, repair of the juxtarenal mycotic aneurysm with a rifampin-soaked InterGard Dacron aorto-bi-iliac graft, and debridement of L2-L4. Histopathology of tissue revealed dense fibrosis with chronic inflammation, with no evidence of fungal or mycobacterial organisms on special stains. Cultures for bacteria, fungi, and mycobacteria were negative. TB-IGRA, Brucella, and fungal serologies were negative. *C. burnetii* IgG phase 1 titer was 1:2048, and IgM phase 1 titer was <1:16. The phase 2 titers were IgG 1:4096 and IgM <1:16. *C. burnetii* cultures and PCR were positive from the lumbar spine and aorta. A TEE did not show evidence for endocarditis. She had spent time at a cattle and sheep ranch in Texas shortly before the onset of infection and lived in a rural community with surrounding livestock. She was started on ciprofloxacin and doxycycline; due to persistent nausea, her regimen was changed to hydroxychloroquine and delayed-release doxycycline. She completed 1 year of therapy with hydroxychloroquine and doxycycline and was transitioned to chronic suppressive doxycycline therapy. Colon cancer treatment was re-initiated in 2012 due to metastatic disease with infusional fluorouracil and bevacizumab therapy followed by folinic acid (leucovorin)-fluorouracil-irinotecan plus cetuximab therapy. She remained stable from the infection perspective until November 2016, when she passed away from metastatic colon cancer.

#### Case 4

A 67-year-old male from Minnesota underwent an endovascular aortic stent graft repair of an AAA in November 2014. The patient remained well until November 2015, when he

developed right-sided hip pain and malaise. A CT angiogram demonstrated a large hyperdense collection consistent with an abscess extending from the posterior portion of the aneurysm sac to the psoas and iliopsoas muscles; no leak from the endoluminal graft was noted. CT-guided aspiration of this intra-abdominal collection yielded no growth on bacterial, fungal, and mycobacterial cultures. No antimicrobial therapy was initiated at that time. Over the next 6 months, he developed low back pain, sweats, and malaise. Repeat CT in June 2016 demonstrated an enlarging 4 cm × 2.1 cm × 5.5 cm collection extending from the posterior portion of the aneurysm sac, with L2-L3 vertebral osteomyelitis. Repeat CT-guided aspiration of this intra-abdominal collection again yielded negative cultures. He remained off antimicrobial therapy throughout.

Notable exposures included residing in a rural area with surrounding livestock, regularly drinking unpasteurized goat milk from a nearby farm for 12–18 months prior to onset of symptoms, hunting wild game, and spending his childhood on a dairy farm. He had never traveled overseas.

On examination in June 2016, his temperature was 36.3°C, BP was 128/84 mmHg, and pulse was 97/min. He was nontoxic, appearing with unremarkable cardiac examination. No spinal tenderness was present; however, pain was elicited on right hip flexion. Laboratory tests showed a hemoglobin of 15.3 g/dL, WBC of  $9.5 \times 10^9/L$ , platelets of  $227 \times 10^9/L$ , serum Cr of 1.0 mg/dL, sedimentation rate of 20 mm/h, CRP of 27.9 mg/dL (normal reference range < 0.8 mg/dL), and normal liver function tests.

CT of the abdomen and pelvis and a lumbar spine MRI in June 2016 showed a multiloculated abscess extending from the aneurysm sac into the prevertebral space and along the left iliopsoas muscle, contiguous with erosions of L2-L3 vertebrae. Enhancement and edema through L2-L3 and bilateral psoas muscle thickening and enhancement were noted. Indium-111 tagged white blood cell scan noted no increased uptake. He underwent explantation of the aortic endograft with placement

of an aorto bi-iliac cryopreserved allograft; a copious amount of cheese-like material was debrided from the aneurysm sac and psoas muscle. The L2-L3 disc space was also debrided. Aortic tissue and abscess cultures were negative for bacterial, fungal, and mycobacterial growth. Operative pathology noted inflammation with negative stains for bacteria, fungi, and mycobacteria.

He completed a 6-week course of empiric vancomycin, cefepime, and metronidazole without significant clinical improvement. Repeat inflammatory markers were elevated, with a sedimentation rate of 73 mm/h and CRP 75.8 mg/dL. *C. burnetii* IgG phase 1 titer was 1:1634, and IgM phase 1 titer was <1:16; the phase 2 titers were IgG 1:8192 and IgM <1:16, consistent with a chronic infection. TEE showed no valvular abnormalities. He was started on doxycycline and hydroxychloroquine for an intended minimum 24-month course.

## DISCUSSION

Q fever is a zoonotic infection that occurs worldwide. About 120–170 cases are reported annually in the United States, with an incidence of approximately 0.38 cases per million persons per year [4, 5]. *C. burnetii* is a fastidious obligate intracellular rickettsial microorganism [6, 7]. Its ability to form a hardy spore-like state allows it to resist desiccation, extreme temperatures, and common chemical disinfectants and enables it to persist in the environment for long periods of time [8, 9]. *C. burnetii*'s virulence, potential for aerosolization, and resistant environmental state have led it to be classified as a Category B bioterrorism organism by the US Centers for Disease Control [10, 11].

Transmission is primarily by inhalation of small droplets or dust containing aerosolized organisms or by ingestion of contaminated dairy products [7, 10]. Less commonly, human-to-human transmission has been reported through blood transfusion, specimen handling by laboratory workers, and sexual contact [12–15]. In addition, multiple tick species have been shown to be competent vectors of *C. burnetii*, with rare reported cases of possible human transmission [16–18]. It can form reservoirs in mammals, arthropods, and birds, with the primary reservoirs being cattle, sheep, and goats [5, 19]. Animals are usually asymptomatic but shed the bacteria in reproductive secretions, milk, urine, or feces [20]. Conventionally, *C. burnetii* was recognized as an infection affecting farmers, agricultural or abattoir workers, veterinarians, or those who have contact with parturient animals [10]. Most cases in the United States, however, had no reported exposures to sheep, cattle, or goats [5]. In Europe and North America, outbreaks and isolated cases have been reported without recognized exposure to animals or animal products. These are thought to be due to airborne spread of *Coxiella* spores from farmland to residential and urban areas [21–24].

*C. burnetii* infections may present acutely or as a chronic infection. Around 50% of acute infections are mild or asymptomatic.

Symptomatic acute infections present as nonspecific febrile illness, pneumonia, hepatitis, or other organ involvement [19].

Chronic infections occur in less than 5% of acutely infected patients and may manifest more than 6 months after exposure. *C. burnetii* endocarditis accounts for 60–70% of all chronic infections. Risk factors for chronic infection include immunosuppression and pregnancy, with a mortality risk of 5–40% [6, 19].

### *Coxiella burnetii* Osteoarticular Infections

Osteoarticular *C. burnetii* infections are rare, reported in 7 of 313 (2%) patients with chronic *C. burnetii* in 1 study [19]. These include osteomyelitis of the long bones, sternum, and vertebrae, or multifocal osteomyelitis [19, 25–31]. *C. burnetii* native joint infection has been reported in 6 cases, half of which were monoarticular, involving the hip or knee. Joint aspiration often shows a mononuclear predominance. A prosthetic knee joint infection was recently reported by our group [32].

### *Coxiella burnetii* Vascular Aneurysms or Vascular Graft Infections

*C. burnetii* infections of vascular aneurysms or grafts have been reported from countries other than the United States [33–39]. A compilation of 30 cases [34, 40] of *C. burnetii*-infected aortic aneurysms (52.5%) or vascular grafts (47.5%) showed that most patients have some environmental exposure such as residing in rural areas, ingesting unpasteurized dairy products, and contact with livestock or domestic animals. The most common location of infection is the infrarenal portion of the aorta [41]. The most common symptoms were fever (82.5%), weight loss and abdominal pain (52.5% each), and fatigue (27.5%) [34].

### *Coxiella burnetii* Vascular Aneurysms or Graft Infections With Contiguous Spread to the Vertebrae

Table 1 summarizes all reported cases of *C. burnetii*-infected vascular aneurysms or grafts with contiguous spread to the vertebrae. In the review by Botelho-Nevers et al., 23.3% (7/30) of patients with *C. burnetii*-infected vascular aneurysms or grafts had contiguous vertebral involvement [34]. Prior to our report, none have been reported as acquired in the United States. Of these 24 cases, 8 were infected abdominal aortic vascular grafts whereas the rest were aortic aneurysmal infections. The predominant location of these vascular infections was the infrarenal aorta while only 1 was a thoracic aortic aneurysm. Where information was available, surgical intervention was performed in all cases except for 1 [42]. There was no incident of contiguous vertebral osteomyelitis complicating any of the 122 cases of vascular aneurysm or graft *C. burnetii* infections in a recent report from the Netherlands [39].

Diagnosis of *C. burnetii* infection requires a high index of suspicion. It should be suspected when bacterial fungal and mycobacterial cultures are negative in the absence of prior antimicrobial exposure as this is a common cause of lack of growth in cultures. Histopathologic examination of infected tissue demonstrates noncaseating, occasionally necrotizing

**Table 1. Cases of Reported *Coxiella burnetii*-Infected Vascular Aneurysm or Graft Infection With Contiguous Spread to Vertebrae**

Case Number	Reference	Age/Sex/Location	Presentation	Exposures	Aneurysm/Graft	Vascular Surgery	Vertebral Debridement	Outcomes
1	Case 1	74/M/US	Back pain	Deer, livestock, unpasteurized milk	Infrarenal aortic graft	Yes	Yes	Died of secondary complications
2	Case 2	60/F/US	Back pain, weight loss	Remote farming exposure	Juxtarenal aortic graft	Yes	Yes	Well at 6.5 years postsurgery
3	Case 3	57/F/US	Asymptomatic— <i>noted on staging CT for cancer</i>	Cattle & sheep farm exposure, rural residence	Infrarenal aortic aneurysm	Yes	Yes	Well at 6 years postsurgery, passed away due to malignancy
4	Case 4	67/M/US	Back pain, sweats, malaise	Unpasteurized goat milk, rural residence	Infrarenal aortic graft	Yes	Yes	Well 6 at months postsurgery
5	[46]	67/M/Canada	Back & abdominal pain, increasing pseudoaneurysm size, positive serology, positive PCR from aorta	Unknown	Infrarenal aortic graft	Redo aortic graft		Died at 18 months—PE, decreasing titers
6	[47]	64/M/France	Back pain, malaise, positive serology, positive PCR from psoas abscess	Unknown	Infrarenal aortic graft			
7	[48]	57/M/Jordan	Back pain, fever, positive serology, positive PCR on vertebrae	Remote unpasteurized milk	Infrarenal aortic aneurysm	Yes	Yes	Doing well at 3 months postsurgery
8	[49]	91/M/France	Fever, back pain, positive serology	Unknown	Infrarenal ruptured aortic aneurysm	Aortic allograft	No	Cured (20 months)
9	[50]	92/M/France	Back pain, positive serology	Unknown	Infrarenal aortic aneurysm	Aortic allograft		Lost to follow-up at 6 months
10	[51]	54/M/Israel	Back pain, positive serology	Unknown	Infrarenal aortic aneurysm	Dacron graft, extra-anatomic bypass + stent graft		Unknown
11	[52]	77/M/Netherlands	Increasing aneurysm size on surveillance, positive serology, positive PCR from blood and aortic tissue	Unknown	Infrarenal aortic aneurysm	Spiral vein reconstruction		Died postoperatively—ischemic colon
12	[31]	72/M/France	Back pain, weight loss, positive serology	Goat cheese	Aortobiliac endograft	Graft explantation, extra-anatomic bypass		Improved titers at 6 months
13	[42]	66/M/France	Lumbar pain, fever, positive serology, positive PCR from psoas abscess	Sporadic farm animal contact	Infrarenal aortic aneurysm	No	No	Doxycycline + hydroxychloroquine for 3 years, cured
14	[42]	65/M/France	Weight loss, back pain, positive serology, positive PCR from psoas abscess	Unknown	Infrarenal aortic aneurysm	Yes		
15–21	[34]	France	Unknown	Unknown	Infrarenal aneurysm (5), graft (1), thoracic aortic aneurysm (1)	Unknown	Unknown	Died (1), cured (7)
22	[40]	70/M/France	Fever, lumbar pain, aneurysm rupture, positive serology, positive culture & PCR from aorta	Rural residence	Infrarenal aortic aneurysm	Dacron graft	Unknown	Died
23	[53]	70/M/France	Lumbar pain, aneurysm rupture, positive serology, positive culture from aorta	Unknown	Infrarenal aortic aneurysm	Dacron graft		Cured
24	[54]	67/M/France	Lumbar pain, weight loss, positive serology, positive PCR & culture from aorta/vertebrae	Rural residence	Infrarenal aortobifemoral Dacron graft	Graft explantation, extra-anatomic bypass	Yes	Cured

Abbreviations: CT, computerized tomography; PE, pulmonary embolism; PCR, polymerase chain reaction.

granulomas, often with characteristic doughnut-shaped ring granuloma surrounded by fibroblasts. Diagnosis of *C. burnetii* infection is usually confirmed with serologic testing and real-time *C. burnetii* DNA PCR on blood or serum. The serologic response is biphasic. Phase 1 positive titers (IgG, IgM) of  $\geq 1:800$  represent chronic infections while phase 2 (IgG, IgM) positive titers are seen with acute infections. Confirmation can also be made with the use of DNA amplification techniques and special cultures. DNA amplification from tissue is more sensitive than blood [43]. *C. burnetii* can be grown in a shell-vial of human embryonic lung fibroblast cells. Direct immunofluorescence can be used to confirm the presence of *C. burnetii* (Figure 4). For 3 of our 4 patients, surgical tissue samples were sent to the French National Reference Center for Rickettsial Diseases in Marseille, France, for molecular testing and cultures.

Management of infected vascular aneurysms or grafts with contiguous vertebral spread requires a combined surgical and medical approach. As outlined in Table 1, all patients for whom details are available except 1 underwent vascular and/or orthopedic debridement with or without reconstructive surgery. Antimicrobial treatment with doxycycline along with hydroxychloroquine or fluoroquinolones or rifampin is recommended for chronic *C. burnetii* infection. Measurement of doxycycline concentration in serum may be helpful in the management of severe infections [44]. Duration of antibiotic therapy for severe infections is at least 18–36 months; however, most cases involving prosthetic material require long-term suppressive therapy. Response to therapy should be assessed by measuring serial serological titers with the goal of phase 1 titers being less than  $\leq 1:200$  [45]. Persistence of high titers is associated with a high relapse rate. *C. burnetii* may survive for prolonged periods in monocytes and macrophages, which may in part explain their resistance to antimicrobial therapy.

Overall, of the 20 reported patients whose outcomes are known, 14 of 20 (70%) were cured or doing well and 6 (30%) died. In previous reports, an overall mortality of 25% have been reported among patients with *C. burnetii*-infected aneurysms or vascular grafts (including patients with contiguous vertebral spread) [34, 40]. Surgical intervention is associated with improved outcome [34, 40]. Among our 4 patients, 1 died from multiple complications unrelated to the *C. burnetii* infection and another passed away from metastatic malignancy 6 years after the diagnosis of *C. burnetii* infection. The other 2 patients were still alive during the preparation of this manuscript. Patient 2 is stable at 6.5 years of follow-up; we anticipate lifelong suppressive therapy. Successful management of infected blood vessels, mycotic aneurysms, or vascular grafts requires a combination of medical and surgical therapy [34]. Ideally, the infected vascular material should be excised and circulation re-established using a bypass graft in an extra-anatomic position (Case 1). If this is not technically feasible, the infected material should be excised with meticulous debridement to clean tissue margins

with placement of an interposition vascular graft. In these latter cases, after control of initial infection, lifelong suppressive antimicrobial therapy may be necessary.

## CONCLUSIONS

*C. burnetii* infections of abdominal aortic aneurysms or vascular grafts, with or without spread to contiguous structures, occur in the United States and other countries where *C. burnetii* is endemic. Although *C. burnetii* infections are uncommon in the United States, noncardiac endovascular infections do occur and may be under-recognized. Patients may present with nonspecific symptoms or symptoms related to vertebral extension. Diagnosis is dependent on elucidating the exposure history, recent or remote, and rigorously excluding other microbial etiologies prior to administering antimicrobial therapy. Withholding antimicrobial therapy prior to obtaining vertebral or vascular tissue cultures in cases where the diagnosis is unclear optimizes yield from cultures, allowing for identification of pathogens. Receiving antimicrobial therapy prior to cultures can confound the clinical picture as it is unclear if growth in a culture of common organisms has been compromised by the antimicrobial therapy or if the true pathogen is a fastidious organism. Therefore, whenever it is safe to do so, we advocate withholding antimicrobial therapy until microbiologic diagnosis can be established through culture, molecular, or serologic methods. In our cases, extensive deep surgical routine cultures were negative; the withholding of antimicrobial therapy was an important factor for the “true culture-negative” work-up, which ultimately yielded the diagnosis. Understandably, withholding antimicrobial therapy may not be feasible in critically ill patients. Without surgery and removal of infected foreign material, prognosis is likely poor. Surgical intervention requires a multidisciplinary approach with vascular and orthopedic surgical teams. These patients require initial multidrug therapy to control infection, followed by, usually, lifelong suppressive therapy together with close follow-up to monitor response.

## Acknowledgements

**Funding sources.** None.

**Potential conflicts of interest.** All authors: no reported conflicts of interest. All authors have submitted the ICMJE Form for Disclosure of Potential Conflicts of Interest. Conflicts that the editors consider relevant to the content of the manuscript have been disclosed.

## References

1. Patel P, Tuke P, Tettmar K, et al. No evidence of transfusion transmission of adenovirus and Epstein-Barr virus infections in paediatric recipients post-bone marrow transplant. *Vox Sang* 2015; 109:95–7.
2. Gouriet E, Fenollar F, Patrice JY, et al. Use of shell-vial cell culture assay for isolation of bacteria from clinical specimens: 13 years of experience. *J Clin Microbiol* 2005; 43:4993–5002.
3. Fournier PE, Raoult D. Comparison of PCR and serology assays for early diagnosis of acute Q fever. *J Clin Microbiol* 2003; 41:5094–8.
4. Anonymous. Q fever epidemiology in the US. 2016. Available at: <http://www.bt.cdc.gov/agent/qfever/clinicians/epidemiology.asp>. Accessed 24 February 2016.



5. Dahlgren FS, McQuiston JH, Massung RF, Anderson AD. Q fever in the United States: summary of case reports from two national surveillance systems, 2000–2012. *Am J Trop Med Hyg* **2015**; 92:247–55.
6. Raoult D, Marrie T, Mege J. Natural history and pathophysiology of Q fever. *Lancet Infect Dis* **2005**; 5:219–26.
7. Million M, Raoult D. Recent advances in the study of Q fever epidemiology, diagnosis and management. *J Infect* **2015**; 71(Suppl 1):S2–9.
8. Scott GH, Williams JC. Susceptibility of *Coxiella burnetii* to chemical disinfectants. *Ann N Y Acad Sci* **1990**; 590:291–6.
9. McCaul TF, Williams JC. Developmental cycle of *Coxiella burnetii*: structure and morphogenesis of vegetative and sporogenic differentiations. *J Bacteriol* **1981**; 147:1063–76.
10. Madariaga MG, Rezaei K, Trenholme GM, Weinstein RA. Q fever: a biological weapon in your backyard. *Lancet Infect Dis* **2003**; 3:709–21.
11. Anderson A, Bijlmer H, Fournier PE, et al. Diagnosis and management of Q fever—United States, 2013: recommendations from CDC and the Q fever working group. *MMWR Recomm Rep* **2013**; 62:1–30.
12. Spicknall CG, Huebner RJ. Report on an outbreak of Q fever at the National Institute of Health; clinical features. *Ann Intern Med* **1947**; 27:28–40.
13. Kruszezwska D, Lembowicz K, Tylewska-Wierzbanska S. Possible sexual transmission of Q fever among humans. *Clin Infect Dis* **1996**; 22:1087–8.
14. Anonymous. Q-fever transmitted by blood transfusion—United States. CDC public health notes. *Can Dis Wkly Rep* **1977**; 3:210.
15. Milazzo A, Hall R, Storm PA, et al. Sexually transmitted Q fever. *Clin Infect Dis* **2001**; 33:399–402.
16. Duron O, Sidi-Boumedine K, Rousset E, et al. The importance of ticks in Q fever transmission: what has (and has not) been demonstrated? *Trends Parasitol* **2015**; 31:536–52.
17. Graves SR, Stenos J. Tick-borne infectious diseases in Australia. *Med J Aust* **2017**; 206:320–4.
18. Beaman MH, Hung J. Pericarditis associated with tick-borne Q fever. *Aust N Z J Med* **1989**; 19:254–6.
19. Raoult D, Tissot-Dupont H, Foucault C, et al. Q fever 1985–1998. Clinical and epidemiologic features of 1,383 infections. *Medicine (Baltimore)* **2000**; 79:109–23.
20. Maurin M, Raoult D. Q fever. *Clin Microbiol Rev* **1999**; 12:518–53.
21. Hawker JI, Ayres JG, Blair I, et al. A large outbreak of Q fever in the West Midlands: windborne spread into a metropolitan area? *Commun Dis Public Health* **1998**; 1:180–7.
22. Gilsdorf A, Kroh C, Grimm S, et al. Large Q fever outbreak due to sheep farming near residential areas, Germany, 2005. *Epidemiol Infect* **2008**; 136:1084–7.
23. Commandeur M, Jeurissen L, van der Hoek W, et al. Spatial relationships in the Q fever outbreaks 2007–2010 in the Netherlands. *Int J Environ Health Res* **2014**; 24:137–57.
24. Gyuranecz M, Sulyok K, Balla E. Q fever epidemic in Hungary, April to July 2013. *Euro Surveill* **2014**; 19.
25. Costa PS, Brigatte ME, Greco DB. Questing one Brazilian query: reporting 16 cases of Q fever from Minas Gerais, Brazil. *Rev Inst Med Trop Sao Paulo* **2006**; 48:5–9.
26. Ellis ME, Smith CC, Moffat MA. Chronic or fatal Q-fever infection: a review of 16 patients seen in North-East Scotland (1967–80). *Q J Med* **1983**; 52:54–66.
27. Marrie TJ, Raoult D. Update on Q fever, including Q fever endocarditis. *Curr Clin Top Infect Dis* **2002**; 22:97–124.
28. Cottalorda J, Jouve JL, Bollini G, et al. Osteoarticular infection due to *Coxiella burnetii* in children. *J Pediatr Orthop B* **1995**; 4:219–21.
29. Landais C, Fenollar F, Constantin A, et al. Q fever osteoarticular infection: four new cases and a review of the literature. *Eur J Clin Microbiol Infect Dis* **2007**; 26:341–7.
30. Nourse C, Allworth A, Jones A, et al. Three cases of Q fever osteomyelitis in children and a review of the literature. *Clin Infect Dis* **2004**; 39:e61–6.
31. Merhej V, Cammilleri S, Piquet P, et al. Relevance of the positron emission tomography in the diagnosis of vascular graft infection with *Coxiella burnetii*. *Comp Immunol Microbiol Infect Dis* **2012**; 35:45–9.
32. Tande AJ, Cunningham SA, Raoult D, et al. A case of Q fever prosthetic joint infection and description of an assay for detection of *Coxiella burnetii*. *J Clin Microbiol* **2013**; 51:66–9.
33. Senn L, Francioli M, Raoult D, et al. *Coxiella burnetii* vascular graft infection. *BMC Infect Dis* **2005**; 5:109.
34. Botelho-Nevers E, Fournier PE, Richet H, et al. *Coxiella burnetii* infection of aortic aneurysms or vascular grafts: report of 30 new cases and evaluation of outcome. *Eur J Clin Microbiol Infect Dis* **2007**; 26:635–40.
35. Bendermacher BL, Peppelenbosch AG, Daemen JW, et al. Q fever (*Coxiella burnetii*) causing an infected thoracoabdominal aortic aneurysm. *J Vasc Surg* **2011**; 53:1402–4.
36. Aerts PD, van Zitteren M, Van Kasteren ME, et al. Report of two in situ reconstructions with a saphenous spiral vein graft of *Coxiella burnetii*-infected aneurysms of the abdominal aorta. *J Vasc Surg* **2013**; 57:234–7.
37. González-Del Vecchio M, Vena A, Valerio M, et al. *Coxiella burnetii* infection in hemodialysis and other vascular grafts. *Medicine (Baltimore)* **2014**; 93:364–71.
38. Maor Y, Sternik L, Orlov B, et al. *Coxiella burnetii* endocarditis and aortic vascular graft infection: an underrecognized disease. *Ann Thorac Surg* **2016**; 101:141–5.
39. Broos PB, Hagenaars JC, Kampschreur LM, et al. Vascular complications and surgical interventions after world's largest Q fever outbreak. *J Vasc Surg* **2015**; 62:1273–80.
40. Fournier PE, Casalta JP, Piquet P, et al. *Coxiella burnetii* infection of aneurysms or vascular grafts: report of seven cases and review. *Clin Infect Dis* **1998**; 26:116–21.
41. Sessa C, Vokri L, Porcu P, et al. Abdominal aortic aneurysm and *Coxiella burnetii* infection: report of three cases and review of the literature. *J Vasc Surg* **2005**; 42:153–8.
42. Breton G, Yahiaoui Y, Deforges L, et al. Psoas abscess: an unusual manifestation of Q fever. *Eur J Intern Med* **2007**; 18:66–8.
43. Maltezou HC, Raoult D. Q fever in children. *Lancet Infect Dis* **2002**; 2:686–91.
44. Lecaillet A, Mallet MN, Raoult D, Rolain JM. Therapeutic impact of the correlation of doxycycline serum concentrations and the decline of phase I antibodies in Q fever endocarditis. *J Antimicrob Chemother* **2009**; 63:771–4.
45. Landais C, Fenollar F, Thuny F, Raoult D. From acute Q fever to endocarditis: serological follow-up strategy. *Clin Infect Dis* **2007**; 44:1337–40.
46. Stokes W, Janvier J, Vaughan S. Chronic Q fever in Alberta: a case of *Coxiella burnetii* mycotic aneurysm and concomitant vertebral osteomyelitis. *Can J Infect Dis Med Microbiol* **2016**; 2016:7456157.
47. Michel M, Cesini J, Michon J, et al. Vertebral fractures and abdominal aortic aneurysm revealing Q fever. *Joint Bone Spine* **2016**; 83:241–2.
48. Leahey PA, Tahan SR, Kasper EM, Albrecht M. Chronic Q-fever (*Coxiella burnetii*) causing abdominal aortic aneurysm and lumbar osteomyelitis: a case report. *Open Forum Infect Dis*. doi:10.1093/ofid/ofv185.
49. Jayet J, Raux M, Allaire E, et al. Treatment of an abdominal aortic aneurysm infected by *Coxiella burnetii* using a cryopreserved allograft. *Ann Vasc Surg* **2016**; 33:227.e9–227.e12.
50. Galy A, Decousser JW, El-Anbassi S, et al. Psoas abscess and chronic Q fever: a contiguous or hematogenous complication? A case report and literature review. *Infect Dis (Lond)* **2016**; 48:626–31.
51. Heldenberg E, Rabin I, Peer A, et al. A creative approach to mycotic abdominal aortic aneurysm secondary to *Coxiella burnetii* infection. *Isr Med Assoc J* **2015**; 17:385–6.
52. Aerts PD, van Zitteren M, Van Kasteren ME, et al. Report of two in situ reconstructions with a saphenous spiral vein graft of *Coxiella burnetii*-infected aneurysms of the abdominal aorta. *J Vasc Surg* **2013**; 57:234–7.
53. Fournier PE, Casalta JP, Piquet P, et al. *Coxiella burnetii* infection of aneurysms or vascular grafts: report of seven cases and review. *Clin Infect Dis* **1998**; 26:116–21.
54. Piquet P, Raoult D, Tranier P, Mercier C. *Coxiella burnetii* infection of pseudoaneurysm of an aortic bypass graft with contiguous vertebral osteomyelitis. *J Vasc Surg* **1994**; 19:165–8.