



**HAL**  
open science

## Stricturing Crohn's disease-like colitis in a patient treated with belatacept

Anne Bozon, Guillaume Jeantet, Benjamin Rivière, Natalie Funakoshi, Gaspard Dufour, Roman Combes, Jean-Christophe Valats, Sylvie Delmas, Jean Emmanuel Serre, Michael Bismuth, et al.

### ► To cite this version:

Anne Bozon, Guillaume Jeantet, Benjamin Rivière, Natalie Funakoshi, Gaspard Dufour, et al.. Stricturing Crohn's disease-like colitis in a patient treated with belatacept. World Journal of Gastroenterology, 2017, 23 (48), pp.8660–8665. 10.3748/wjg.v23.i48.8660 . hal-01724131

HAL Id: hal-01724131

<https://hal.science/hal-01724131v1>

Submitted on 13 Jan 2022

**HAL** is a multi-disciplinary open access archive for the deposit and dissemination of scientific research documents, whether they are published or not. The documents may come from teaching and research institutions in France or abroad, or from public or private research centers.

L'archive ouverte pluridisciplinaire **HAL**, est destinée au dépôt et à la diffusion de documents scientifiques de niveau recherche, publiés ou non, émanant des établissements d'enseignement et de recherche français ou étrangers, des laboratoires publics ou privés.



Distributed under a Creative Commons Attribution - NonCommercial 4.0 International License

# World Journal of *Gastroenterology*

*World J Gastroenterol* 2017 December 28; 23(48): 8439-8678





### EDITORIAL

- 8439 Serum levels of angiotensin converting enzyme as a biomarker of liver fibrosis  
*Miranda AS, Simões e Silva AC*

### MINIREVIEWS

- 8443 Mechanisms of autophagy activation in endothelial cell and their targeting during normothermic machine liver perfusion  
*Boteon YL, Laing R, Mergental H, Reynolds GM, Mirza DF, Afford SC, Bhogal RH*

### ORIGINAL ARTICLE

#### Basic Study

- 8452 Human small intestine is capable of restoring barrier function after short ischemic periods  
*Schellekens DH, Hundscheid IH, Leenarts CA, Grootjans J, Lenaerts K, Buurman WA, Dejong CH, Derikx JP*
- 8465 Stable gastric pentadecapeptide BPC 157 in treatment of colitis and ischemia and reperfusion in rats: New insights  
*Duzel A, Vlainic J, Antunovic M, Malekinusic D, Vrdoljak B, Samara M, Gojkovic S, Krezic I, Vidovic T, Bilic Z, Knezevic M, Sever M, Lojo N, Kokot A, Kolovrat M, Drmic D, Vukojevic J, Kralj T, Kasnik K, Siroglavic M, Seiwerth S, Sikiric P*
- 8489 Exploring pathogenesis of primary biliary cholangitis by proteomics: A pilot study  
*Deng CW, Wang L, Fei YY, Hu CJ, Yang YJ, Peng LY, Zeng XF, Zhang FC, Li YZ*
- 8500 Influence of TBX21 T-1993C variant on autoimmune hepatitis development by Yin-Yang 1 binding  
*Sun W, Wu HY, Chen S*
- 8512 Astragaloside IV inhibits pathological functions of gastric cancer-associated fibroblasts  
*Wang ZF, Ma DG, Zhu Z, Mu YP, Yang YY, Feng L, Yang H, Liang JQ, Liu YY, Liu L, Lu HW*

#### Retrospective Cohort Study

- 8526 Prevalence and outcomes of pancreatic cystic neoplasms in liver transplant recipients  
*Liu K, Joshi V, van Camp L, Yang QW, Baars JE, Strasser SI, McCaughan GW, Majumdar A, Saxena P, Kaffes AJ*

#### Retrospective Study

- 8533 Analysis of 12 variants in the development of gastric and colorectal cancers  
*Cavalcante GC, Amador MA, Ribeiro dos Santos AM, Carvalho DC, Andrade RB, Pereira EE, Fernandes MR, Costa DF, Santos NP, Assumpção PP, Ribeiro dos Santos Á, Santos S*

- 8544** Childhood-onset inflammatory bowel diseases associated with mutation of Wiskott-Aldrich syndrome protein gene

*Ohya T, Yanagimachi M, Iwasawa K, Umetsu S, Sogo T, Inui A, Fujisawa T, Ito S*

- 8553** Comparison of totally laparoscopic total gastrectomy using an endoscopic linear stapler with laparoscopic-assisted total gastrectomy using a circular stapler in patients with gastric cancer: A single-center experience

*Gong CS, Kim BS, Kim HS*

- 8562** Prognostic significance of pretreatment serum carcinoembryonic antigen levels in gastric cancer with pathological lymph node-negative: A large sample single-center retrospective study

*Xiao J, Ye ZS, Wei SH, Zeng Y, Lin ZM, Wang Y, Teng WH, Chen LC*

- 8570** Fecal microbiota transplantation induces remission of infantile allergic colitis through gut microbiota re-establishment

*Liu SX, Li YH, Dai WK, Li XS, Qiu CZ, Ruan ML, Zou B, Dong C, Liu YH, He JY, Huang ZH, Shu SN*

- 8582** Prognostic value of lymph node metastasis in patients with T1-stage colorectal cancer from multiple centers in China

*Sun ZQ, Ma S, Zhou QB, Yang SX, Chang Y, Zeng XY, Ren WG, Han FH, Xie X, Zeng FY, Sun XT, Wang GX, Li Z, Zhang ZY, Song JM, Liu JB, Yuan WT*

**Clinical Trial Study**

- 8591** Association between acute pancreatitis and small intestinal bacterial overgrowth assessed by hydrogen breath test

*Zhang M, Zhu HM, He F, Li BY, Li XC*

**Observational Study**

- 8597** Endoscopic papillary large balloon dilatation with sphincterotomy is safe and effective for biliary stone removal independent of timing and size of sphincterotomy

*Aujla UI, Ladep N, Dwyer L, Hood S, Stern N, Sturgess R*

- 8605** Person-centered endoscopy safety checklist: Development, implementation, and evaluation

*Dubois H, Schmidt PT, Creutzfeldt J, Bergenmar M*

**Randomized Clinical Trials**

- 8615** Multicenter, randomized study to optimize bowel preparation for colon capsule endoscopy

*Kastenber D, Burch WC, Romeo DP, Kashyap PK, Pound DC, Papageorgiou N, Fernández-Urien Sainz I, Sokach CE, Rex DK*

**SYSTEMATIC REVIEWS**

- 8626** *Fusobacterium's* link to colorectal neoplasia sequenced: A systematic review and future insights

*Hussan H, Clinton SK, Roberts K, Bailey MT*

- 8651** Psychiatric morbidity after surgery for inflammatory bowel disease: A systematic review

*Zangenberg MS, El-Hussuna A*

**CASE REPORT**

- 8660** Stricturing Crohn's disease-like colitis in a patient treated with belatacept

*Bozon A, Jeantet G, Rivière B, Funakoshi N, Dufour G, Combes R, Valats JC, Delmas S, Serre JE, Bismuth M, Ramos J, Le Quintrec M, Blanc P, Pineton de Chambrun G*

- 8666** Emphysematous pancreatitis associated with penetrating duodenal ulcer

*Tana C, Silingardi M, Giamberardino MA, Cipollone F, Meschi T, Schiavone C*

- 8671** Infiltrative xanthogranulomatous cholecystitis mimicking aggressive gallbladder carcinoma: A diagnostic and therapeutic dilemma

*Nacif LS, Hessheimer AJ, Rodríguez Gómez S, Montironi C, Fondevila C*

**ABOUT COVER**

Editorial board member of *World Journal of Gastroenterology*, Paola Iovino, MD, Associate Professor, Lecturer, Department of Medicine and Surgery, AOU San Giovanni di Dio e Ruggi di Aragona, Salerno 84131, Italy

**AIMS AND SCOPE**

*World Journal of Gastroenterology* (*World J Gastroenterol*, *WJG*, print ISSN 1007-9327, online ISSN 2219-2840, DOI: 10.3748) is a peer-reviewed open access journal. *WJG* was established on October 1, 1995. It is published weekly on the 7<sup>th</sup>, 14<sup>th</sup>, 21<sup>st</sup>, and 28<sup>th</sup> each month. The *WJG* Editorial Board consists of 1375 experts in gastroenterology and hepatology from 68 countries.

The primary task of *WJG* is to rapidly publish high-quality original articles, reviews, and commentaries in the fields of gastroenterology, hepatology, gastrointestinal endoscopy, gastrointestinal surgery, hepatobiliary surgery, gastrointestinal oncology, gastrointestinal radiation oncology, gastrointestinal imaging, gastrointestinal interventional therapy, gastrointestinal infectious diseases, gastrointestinal pharmacology, gastrointestinal pathophysiology, gastrointestinal pathology, evidence-based medicine in gastroenterology, pancreatology, gastrointestinal laboratory medicine, gastrointestinal molecular biology, gastrointestinal immunology, gastrointestinal microbiology, gastrointestinal genetics, gastrointestinal translational medicine, gastrointestinal diagnostics, and gastrointestinal therapeutics. *WJG* is dedicated to become an influential and prestigious journal in gastroenterology and hepatology, to promote the development of above disciplines, and to improve the diagnostic and therapeutic skill and expertise of clinicians.

**INDEXING/ABSTRACTING**

*World Journal of Gastroenterology* (*WJG*) is now indexed in Current Contents<sup>®</sup>/Clinical Medicine, Science Citation Index Expanded (also known as SciSearch<sup>®</sup>), Journal Citation Reports<sup>®</sup>, Index Medicus, MEDLINE, PubMed, PubMed Central and Directory of Open Access Journals. The 2017 edition of Journal Citation Reports<sup>®</sup> cites the 2016 impact factor for *WJG* as 3.365 (5-year impact factor: 3.176), ranking *WJG* as 29<sup>th</sup> among 79 journals in gastroenterology and hepatology (quartile in category Q2).

**FLYLEAF**

**I-IX** Editorial Board

**EDITORS FOR THIS ISSUE**

**Responsible Assistant Editor:** *Xiang Li*  
**Responsible Electronic Editor:** *Yu-Jie Ma*  
**Proofing Editor-in-Chief:** *Lian-Sheng Ma*

**Responsible Science Editor:** *Ze-Mao Gong*  
**Proofing Editorial Office Director:** *Jin-Lei Wang*

**NAME OF JOURNAL**  
*World Journal of Gastroenterology*

**ISSN**  
 ISSN 1007-9327 (print)  
 ISSN 2219-2840 (online)

**LAUNCH DATE**  
 October 1, 1995

**FREQUENCY**  
 Weekly

**EDITORS-IN-CHIEF**  
**Damian Garcia-Olmo, MD, PhD, Doctor, Professor, Surgeon**, Department of Surgery, Universidad Autonoma de Madrid; Department of General Surgery, Fundacion Jimenez Diaz University Hospital, Madrid 28040, Spain

**Stephen C Strom, PhD, Professor**, Department of Laboratory Medicine, Division of Pathology, Karolinska Institutet, Stockholm 141-86, Sweden

**Andrzej S Tarnawski, MD, PhD, DSc (Med), Professor of Medicine, Chief Gastroenterology**, VA Long Beach Health Care System, University of California, Irvine, CA, 5901 E. Seventh Str., Long Beach,

CA 90822, United States

**EDITORIAL BOARD MEMBERS**  
 All editorial board members resources online at <http://www.wjgnet.com/1007-9327/editorialboard.htm>

**EDITORIAL OFFICE**  
 Jin-Lei Wang, Director  
 Ze-Mao Gong, Vice Director  
*World Journal of Gastroenterology*  
 Baishideng Publishing Group Inc  
 7901 Stoneridge Drive, Suite 501,  
 Pleasanton, CA 94588, USA  
 Telephone: +1-925-2238242  
 Fax: +1-925-2238243  
 E-mail: [editorialoffice@wjgnet.com](mailto:editorialoffice@wjgnet.com)  
 Help Desk: <http://www.f6publishing.com/helpdesk>  
<http://www.wjgnet.com>

**PUBLISHER**  
 Baishideng Publishing Group Inc  
 7901 Stoneridge Drive, Suite 501,  
 Pleasanton, CA 94588, USA  
 Telephone: +1-925-2238242  
 Fax: +1-925-2238243  
 E-mail: [bpgoffice@wjgnet.com](mailto:bpgoffice@wjgnet.com)  
 Help Desk: <http://www.f6publishing.com/helpdesk>  
<http://www.wjgnet.com>

**PUBLICATION DATE**  
 December 28, 2017

**COPYRIGHT**  
 © 2017 Baishideng Publishing Group Inc. Articles published by this Open-Access journal are distributed under the terms of the Creative Commons Attribution Non-commercial License, which permits use, distribution, and reproduction in any medium, provided the original work is properly cited, the use is non commercial and is otherwise in compliance with the license.

**SPECIAL STATEMENT**  
 All articles published in journals owned by the Baishideng Publishing Group (BPG) represent the views and opinions of their authors, and not the views, opinions or policies of the BPG, except where otherwise explicitly indicated.

**INSTRUCTIONS TO AUTHORS**  
 Full instructions are available online at <http://www.wjgnet.com/bpg/gerinfo/204>

**ONLINE SUBMISSION**  
<http://www.f6publishing.com>

## Stricturing Crohn's disease-like colitis in a patient treated with belatacept

Anne Bozon, Guillaume Jeantet, Benjamin Rivière, Natalie Funakoshi, Gaspard Dufour, Roman Combes, Jean-Christophe Valats, Sylvie Delmas, Jean Emmanuel Serre, Michael Bismuth, Jeanne Ramos, Moglie Le Quintrec, Pierre Blanc, Guillaume Pineton de Chambrun

Anne Bozon, Natalie Funakoshi, Gaspard Dufour, Roman Combes, Jean-Christophe Valats, Michael Bismuth, Pierre Blanc, Guillaume Pineton de Chambrun, Gastroenterology Department, Saint-Eloi Hospital, Montpellier University Hospital, Montpellier 34000, France

Guillaume Jeantet, Sylvie Delmas, Jean Emmanuel Serre, Moglie Le Quintrec, Nephrology Department, Lapeyronie Hospital, Montpellier University Hospital, Montpellier 34000, France

Benjamin Rivière, Jeanne Ramos, Pathology Department, Guy de Chauliac Hospital, Montpellier University Hospital, Montpellier 34000, France

ORCID number: Anne Bozon (0000-0001-5445-9704); Guillaume Jeantet (0000-0002-8822-1136); Benjamin Rivière (0000-0002-0597-5400); Natalie Funakoshi (0000-0001-6241-993X); Gaspard Dufour (0000-0001-5523-809X); Roman Combes (0000-0001-5515-7046); Jean-Christophe Valats (0000-0002-9357-7014); Sylvie Delmas (0000-0003-4423-0820); Jean Emmanuel Serre (0000-0002-0978-0248); Michael Bismuth (0000-0002-6850-1763); Jeanne Ramos (0000-0002-6528-461X); Moglie Le Quintrec (0000-0002-2031-7764); Pierre Blanc (0000-0001-6467-7342); Guillaume Pineton de Chambrun (0000-0003-1368-1936).

Author contributions: Bozon A, Jeantet G, Rivière B, Dufour G, Combes R, Valats JC, Bismuth M, Le Quintrec M, Blanc P, and Pineton de Chambrun G searched literature and designed study; Bozon A, Jeantet G, Dufour G, Combes R, Delmas S, Serre JE, and Pineton de Chambrun G collection data; Bozon A, Jeantet G, Rivière B, Ramos J, Le Quintrec M, and Pineton de Chambrun G analysis data and interpretation; Bozon A, Jeantet G, Rivière B, Ramos J, and Pineton de Chambrun G Writing and figures; Rivière B, Funakoshi N, Dufour G, Combes R, Valats JC, Delmas S, Serre JE, Bismuth M, and Ramos J, Le Quintrec M, Blanc P critical review of the manuscript.

Informed consent statement: All study participants provided

informed consent prior to study enrolment.

Conflict-of-interest statement: Authors declare no conflict of interest for this article.

Open-Access: This article is an open-access article which was selected by an in-house editor and fully peer-reviewed by external reviewers. It is distributed in accordance with the Creative Commons Attribution Non Commercial (CC BY-NC 4.0) license, which permits others to distribute, remix, adapt, build upon this work non-commercially, and license their derivative works on different terms, provided the original work is properly cited and the use is non-commercial. See: <http://creativecommons.org/licenses/by-nc/4.0/>

Manuscript source: Unsolicited manuscript

Correspondence to: Guillaume Pineton de Chambrun, MD, PhD, Assistant Professor, Department of Gastroenterology, Saint-Eloi Hospital, Montpellier University Hospital, 80 avenue Augustin Fliche, Montpellier 34000, France. [gpinetondechambrun@yahoo.fr](mailto:gpinetondechambrun@yahoo.fr)  
Telephone: +33-467-337397  
Fax: +33-467-337694

Received: July 28, 2017

Peer-review started: July 28, 2017

First decision: August 30, 2017

Revised: September 15, 2017

Accepted: October 17, 2017

Article in press: October 17, 2017

Published online: December 28, 2017

### Abstract

Cytotoxic T-lymphocyte-associated antigen 4 (CTLA-4) modifying agents have been involved in the development of intestinal inflammation, especially therapeutic

monoclonal antibodies directed against CTLA-4. Here we report the appearance of a severe stricturing Crohn's disease-like colitis in a patient with a kidney allograft who was treated with belatacept, a recombinant CTLA-4-Ig fusion protein.

**Key words:** Crohn's disease; Colitis; Belatacept; HHV-6; Inflammatory bowel disease

© **The Author(s) 2017.** Published by Baishideng Publishing Group Inc. All rights reserved.

**Core tip:** Belatacept is a cytotoxic T-lymphocyte-associated antigen 4 Ig fusion protein used for kidney transplant rejection prophylaxis. We report the appearance of a severe stricturing Crohn's disease-like colitis in a patient who was treated with belatacept. After belatacept withdrawal, complete mucosal healing was observed with the persistence of a non-ulcerated left-sided colonic stricture which did not allow passage of the colonoscope. So, in patients treated with belatacept who develop digestive symptoms such as diarrhea or intestinal bleeding, we recommend performing early colonoscopy and considering belatacept withdrawal in case of suggestive endoscopic and histologic findings in order to avoid colonic sequela.

Bozon A, Jeantet G, Rivière B, Funakoshi N, Dufour G, Combes R, Valats JC, Delmas S, Serre JE, Bismuth M, Ramos J, Le Quintrec M, Blanc P, Pineton de Chambrun G. Stricturing Crohn's disease-like colitis in a patient treated with belatacept. *World J Gastroenterol* 2017; 23(48): 8660-8665 Available from: URL: <http://www.wjgnet.com/1007-9327/full/v23/i48/8660.htm> DOI: <http://dx.doi.org/10.3748/wjg.v23.i48.8660>

## INTRODUCTION

Belatacept is a cytotoxic T-lymphocyte-associated antigen 4 (CTLA-4) Ig fusion protein mostly used for kidney transplant rejection prophylaxis, in association with steroids and mycophenolate mofetil<sup>[1]</sup>. Belatacept selectively inhibits T cell activation and was recently demonstrated to be superior to cyclosporin in patients with renal transplants in terms of renal function with equivalent survival<sup>[2]</sup>. Frequent adverse events associated with belatacept are anemia, disturbance of bowel habits and infections, especially urinary tract infections, with no need to stop treatment in most of cases. Here, we report a case of severe stricturing Crohn's disease (CD)-like colitis due to belatacept administration in a renal transplant recipient.

## CASE REPORT

We report the case of a 62-year-old man who received a first kidney allograft from a deceased donor in September 2013. His end-stage renal disease was

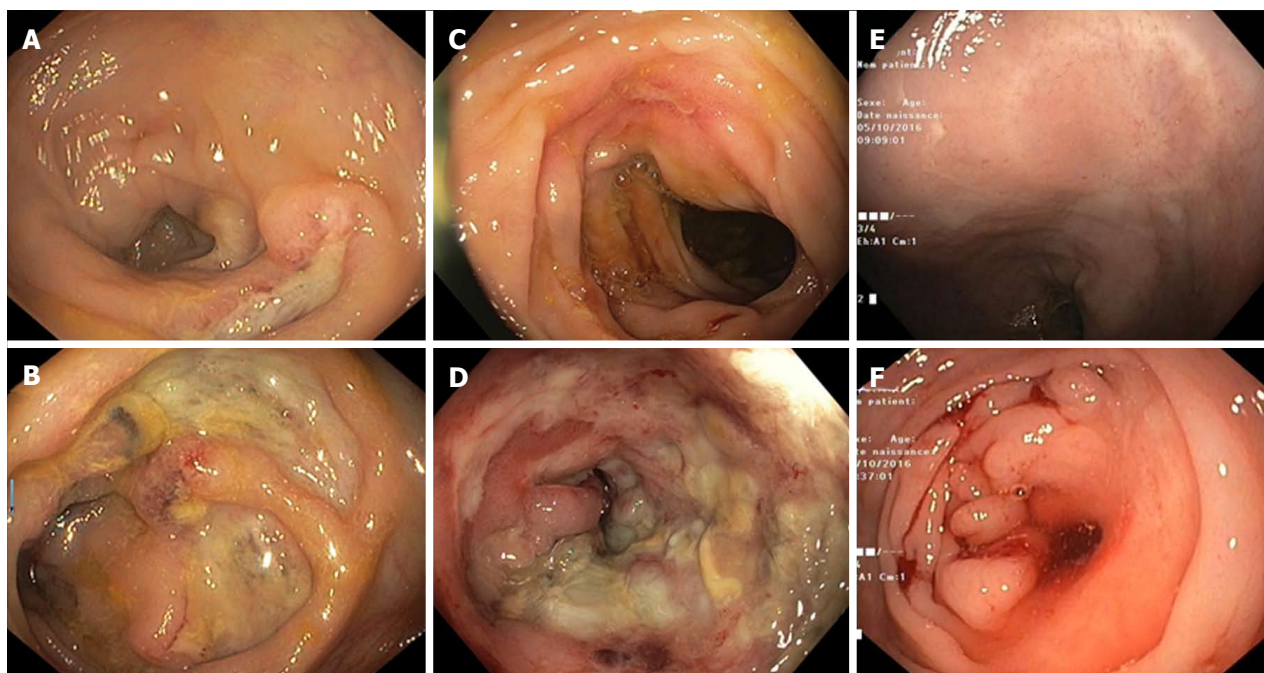
attributed to chronic glomerulonephritis. After an induction treatment by thymoglobulin and methylprednisolone pulses, the immunosuppression regimen consisted of tacrolimus, mycophenolate mofetil and steroids. There was no immediate complication after transplantation and the nadir of serum creatinin was 2.24 mg/dL. Rapidly, after two months, tacrolimus was withdrawn due to nephrotoxicity (histologically proven) and replaced with everolimus which was also stopped due to development of lymphocele and proteinuria. In February 2014, belatacept was started at a dose of 5 mg/kg intravenously every month in association with mycophenolate mofetil in order to decrease corticosteroids to the level of 10 mg/d.

From the start of mycophenolate mofetil treatment, the patient had anorexia and diarrhea, with liquid stools without blood. He underwent in March 2014 an upper gastrointestinal endoscopy and a colonoscopy which showed no mucosal abnormalities. Duodenal biopsies demonstrated normal mucosal histology. In October 2015, because of worsening of the diarrhea, a stool culture was performed which was positive for *Campylobacter jejuni*. Antibiotics course was prescribed with some efficacy but the diarrhea persisted.

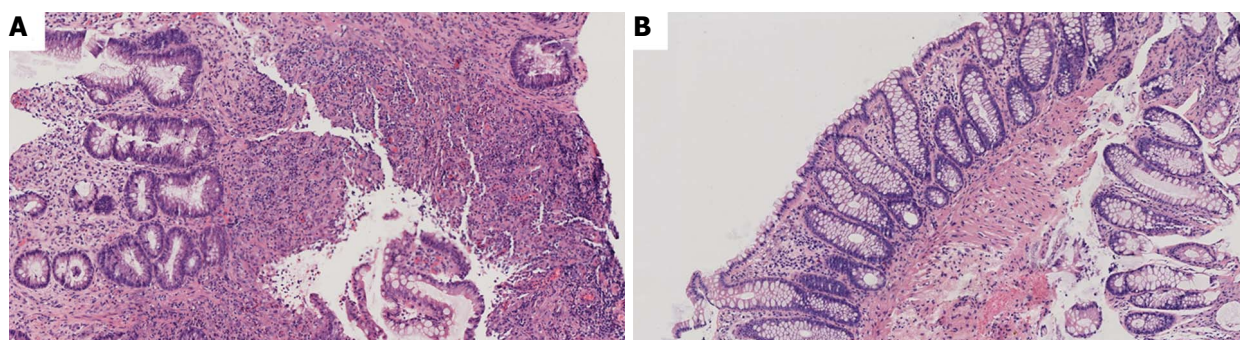
In February 2016, the patient was hospitalized for bloody stools with anemia and abdominal pain for which blood transfusion was necessary. A colonoscopy was rapidly performed showing large round shaped deep ulcers with normal surrounding mucosa. These ulcers were located in the caecum, transverse colon, left colon and sigmoid colon and were compatible with the diagnosis of CD (Figure 1). The terminal ileum and rectum were normal. Histologic examination of the colonic biopsies showed acute colitis with ulcerations, crypt abscesses, lymphocytes and neutrophil polymorphonuclear leukocyte infiltration. Neither crypt dystrophy nor granuloma was found (Figure 2). A small bowel wireless capsule endoscopy was also performed without mucosal abnormalities.

Due to suspicion of mycophenolate mofetil involvement in the acute colitis, this treatment was withdrawn in March 2016, but belatacept was pursued with an increase of steroid therapy to 20 mg/d. A follow-up colonoscopy was performed in June 2016 which showed persistence of the large ulcers previously described and the appearance of a passable ulcerated inflammatory stricture at the left colonic flexure (Figure 1). Histologic examination showed acute colitis without signs of chronic inflammation (Figure 2). No signs of cytomegalovirus colitis were found on histology, such as owl's eye inclusion bodies. Polymerase chain reaction (PCR) analysis of colonic biopsies was positive for human herpes virus 6 (HHV-6) and negative for cytomegalovirus and herpes simplex virus. Also, PCR analysis for cytomegalovirus in the blood was negative. Belatacept was therefore withdrawn in June 2016 and the patient was treated with low dose tacrolimus for





**Figure 1 Endoscopic finding before and after withdrawal of belatacept.** The first colonoscopy showed the presence of disseminated ulcers on the colonic mucosa (A) with more severe lesions at the left colonic flexure (B). The patient was still on mycophenolate mofetil and belatacept. After mycophenolate withdrawal and continuation of belatacept, the second colonoscopy showed the persistence of disseminated ulcerations (C) and a worsening of lesions at the left colonic flexure with appearance of an inflammatory ulcerated stricture (D). Five months after belatacept withdrawal, follow up colonoscopy showed complete healing of disseminated ulcerations in the left colon (transverse and right colon were not visualized due to the stricture, (E) and healing of the left colonic flexure with persistence of a non-inflammatory stenosis (F) which did not allow passage of the colonoscope.



**Figure 2 Histologic findings of belatacept-induced colitis.** A: Histologic examination of colonic biopsies showed acute colitis with ulcerations, crypt abscesses, lymphocytes and neutrophil polymorphonuclear leukocyte infiltration. Neither crypt dystrophy nor granuloma was found; B: After belatacept withdrawal, colonic biopsies showed complete healing of the mucosa with no signs of chronic mucosal inflammation.

prevention of allograft rejection and an increased dose of steroids to treat colonic inflammation. In October 2016, the patient was free from diarrhea but described left-sided abdominal pain with partial obstructive symptoms probably due to the colonic stricture. The colonoscopy performed four months after belatacept withdrawal showed a complete healing of the ulcers in the left colon and a non-inflammatory stricture of the left colonic flexure which could not be passed (Figure 1). The stricture was not dilated as clinical symptoms were mild. PCR for HHV-6 was negative on colonic biopsies and only slightly positive on biopsies targeted to the colonic stricture. At the last clinical outpatient visit in January 2017 the patient was asymptomatic with no

signs of acute renal rejection.

## DISCUSSION

We have described here for the first time the case of a severe stricturing CD-like colitis occurring in a patient with a kidney allograft treated with belatacept. Gastrointestinal side effects are well known in renal transplant recipients receiving immunosuppressive therapy, especially mycophenolate mofetil (MMF). Indeed, MMF has multiple side effects and those affecting the gastrointestinal tract mostly occur during the first 6 mo after the onset of treatment<sup>[3]</sup>. These side effects include nausea, vomiting, abdominal pain,

**Table 1** Case reports of colitis induced by cytotoxic T-lymphocyte-associated antigen 4-Ig fusion proteins

	Type of CTLA-4-Ig fusion protein	Delay between CTLA-4-Ig introduction and colitis (mo)	Endoscopic findings	Histological findings	CTLA-4-Ig withdrawal	Colitis treatment	Evolution of the colitis
Amezcu-Guerra <i>et al</i> <sup>[7]</sup> Gut 2005	Abatacept	15	UC-like colitis	Lymphoplasmocytic infiltration/cryptitis/ Intraluminal abscesses	Yes	Mesalazine	Clinical remission
Motohashi <i>et al</i> <sup>[8]</sup> Case 1 <i>Scand J Gastroenterol</i> 2014	Abatacept	25	UC-like colitis	Neutrophil infiltration/crypt abscesses	Yes	Infliximab + Mesalazine	NA
Motohashi <i>et al</i> <sup>[8]</sup> Case 2 <i>Scand J Gastroenterol</i> 2014	Abatacept	5	UC-like colitis	Neutrophil infiltration/crypt abscesses	Yes	Mesalazine + Prednisolone + Granulocytapheresis	NA
Present case	Belatacept	23	CD-like colitis	Ulcerations/crypt abscesses/ lymphocytes and neutrophil infiltration	Yes	Prednisolone	Clinical and endoscopic remission

CD: Crohn's disease; CTLA-4: Cytotoxic T-lymphocyte-associated antigen 4; NA: Not available; UC: Ulcerative colitis.

and diarrhea, whereas bleeding is less reported. A recent retrospective study investigated endoscopic findings in patients treated with MMF having diarrhea. In most of the cases the colonic mucosa was normal and the common lesion was simple erythema without deep ulcer or stricture<sup>[3]</sup>. Our patient had diarrhea after introduction of MMF with liquid stools but no bleeding, and this diarrhea improved after MMF withdrawal. Although acute colitis was first thought to be due to MMF, appearance of bleeding, large ulcers without erythema at colonoscopy and worsening of endoscopic lesions after MMF withdrawal led us to suspect the involvement of belatacept.

Ipilimumab and tremelimumab, two therapeutic monoclonal antibodies against CTLA-4 and prescribed in cancer patients, have previously been implicated in the development of severe and extensive forms of inflammatory bowel disease with colonic ulcerations<sup>[4]</sup>. CTLA-4 is a homologue of CD28 that binds CD80 and CD86 with higher affinity, and thereby down-regulates T cell activation. Anti CTLA-4 monoclonal antibodies block its interaction with CD80 and CD86 and favour CD28 engagement and consequently T cell activation and proliferation. The overactivation of the immune system in patients treated with anti CTLA-4 antibodies associated with a specific gut microflora may explain the development of treatment-mediated CD-like colitis<sup>[5]</sup>. Abatacept and belatacept are two recombinant fusion proteins comprising a fragment of the Fc domain of human IgG1 and the extracellular domain of human CTLA-4. Similar to CTLA-4, abatacept and belatacept compete with CD28 for CD80 and CD86 binding to block co-stimulatory signaling, thus selectively modulating T-cell activation. In comparison to abatacept, belatacept confers higher affinity for CD 80/86 ligands and has a slower dissociation rates. It could also alter regulatory T cell development, which plays an important part in intestinal inflammation. Abatacept is effective for rheumatoid arthritis and juvenile idiopathic arthritis<sup>[6]</sup>, and belatacept is currently

used for kidney transplant rejection prophylaxis<sup>[1]</sup>. It has been showed that abatacept was not effective for the treatment of active ulcerative colitis and CD<sup>[6]</sup>. It may be surprising that belatacept induces CD-like colitis given it has the opposite effect from anti-CTLA-4 antibodies. However, cases of colitis have been also described in patients treated with abatacept (Table 1). A first case of ulcerative colitis was reported in 2006 in a 55 year old male patient treated with abatacept for rheumatoid arthritis<sup>[7]</sup>. The diagnosis of ulcerative colitis was made 15 mo after start of abatacept and digestive symptoms improved after abatacept withdrawal and mesalamine treatment. Two other cases of ulcerative colitis developing five and 23 mo after abatacept introduction in rheumatoid arthritis patients were reported. The first one was treated with mesalamine and infliximab and the second one with prednisolone and mesalamine<sup>[8]</sup>. Similarly to these case reports, the severe colitis occurred 23 mo after belatacept introduction in our patient. Macroscopically, the endoscopic lesions were more in favor of CD compared to abatacept-induced colitis, and the large deep ulcerations were similar to anti CTLA-4 enterocolitis. The histological findings in our patients described acute colitis with polymorph leucocyte infiltration and crypt abscesses without atrophy, distortion, branching or budding of crypts. These findings were also described in abatacept and anti CTLA-4 colitis. The most striking finding in our case is the development on belatacept treatment of an inflammatory stricture of the left colon. After belatacept withdrawal and prednisolone treatment, we observed complete healing of colonic lesions, but with persistence of a non-inflammatory colonic stricture which could be passed.

Although belatacept seems to be involved in the development of colitis in our patient, the exact mechanisms of this colitis are unclear. It may be a direct effect of belatacept, which could alter the development of regulatory T cells, and therefore lead to uncontrolled intestinal inflammation. Another hypothesis may be an

indirect effect of belatacept which confers a profound immunosuppression leading to the development of infectious colitis. Cytomegalovirus colitis was ruled out by careful histologic examination and negative PCR analyses in the blood and in colonic biopsies. PCR in biopsies was however, strongly positive for HHV-6. HHV-6 reactivation in patients with solid organ or hematopoietic stem cell transplantation has been reported to be associated with intestinal disease<sup>[9,10]</sup>. Moreover, HHV-6 was found in colonic mucosa of inflammatory bowel disease patients in 44% of the cases and associated with disease activity and use of immunosuppressive therapy<sup>[11]</sup>. HHV-6 intensity also correlated with endoscopic severity in ulcerative colitis. After belatacept withdrawal and mucosal healing, PCR for HHV-6 in colonic biopsies was found to be negative or slightly positive in our patient.

Thus, we report here a case of CD-like colitis in a patient treated with belatacept. Despite belatacept withdrawal, the patient developed a severe colonic stricture which may impact quality of life and necessitate subsequent colonic surveillance. Therefore in patients treated with belatacept who develop digestive symptoms such as diarrhea or intestinal bleeding, we recommend performing early colonoscopy and considering belatacept withdrawal in case of suggestive endoscopic and histologic findings.

## COMMENTS

### Case characteristics

A 62-year-old man with kidney allograft treated with belatacept and mycophenolate mofetil presented a diarrhea with rectal bleeding and abdominal pain.

### Clinical diagnosis

Abdominal tenderness associated to liquid stools and rectal bleeding.

### Differential diagnosis

Diarrhea associated to mycophenolate mofetil, viral enterocolitis, bacterial enterocolitis, Crohn's disease or ulcerative colitis.

### Laboratory diagnosis

Normal stool cultures and blood tests ruled out opportunistic infections.

### Imaging diagnosis

Colonoscopy showed large colonic ulcers with normal surrounding mucosa disseminated along the colonic tract and a passable ulcerated inflammatory stricture at the left colonic flexure.

### Pathological diagnosis

Histologic examination of the colonic biopsies showed acute colitis with ulcerations, crypt abscesses, lymphocytes and neutrophil polymorphonuclear leukocyte infiltration. Neither crypt dystrophy nor granuloma was found. No signs of cytomegalovirus colitis were found on histology, such as owl's eye inclusion bodies.

### Treatment

Withdrawal of belatacept and corticosteroid therapy.

## Related reports

Previous cases of colitis in patients treated with abatacept, another Cytotoxic T-lymphocyte-associated antigen 4 (CTLA-4) Ig fusion protein, have been also described.

## Term explanation

Drug-induced colitis is described with numerous agents, especially mycophenolate mofetil or antibodies against CTLA-4. Pathophysiological mechanisms are not fully understood. Endoscopic and histologic findings are not specific showing acute colitis and withdrawal of the drug which leads to complete resolution in most of the cases, confirms the diagnosis.

## Experiences and lessons

In patients treated with belatacept who develop digestive symptoms such as diarrhea or intestinal bleeding, early colonoscopy should be performed and belatacept withdrawal should be considered in case of suggestive endoscopic and histologic findings in order to avoid colonic sequela.

## Peer-review

The report has high novelty, clinically important information, which is relevant in therapeutic settings.

## REFERENCES

- 1 **Grinyó JM**, Del Carmen Rial M, Alberu J, Steinberg SM, Manfro RC, Nainan G, Vincenti F, Jones-Burton C, Kamar N. Safety and Efficacy Outcomes 3 Years After Switching to Belatacept From a Calcineurin Inhibitor in Kidney Transplant Recipients: Results From a Phase 2 Randomized Trial. *Am J Kidney Dis* 2017; **69**: 587-594 [PMID: 27889299 DOI: 10.1053/j.ajkd.2016.09.021]
- 2 **Vincenti F**, Charpentier B, Vanrenterghem Y, Rostaing L, Bresnahan B, Darji P, Massari P, Mondragon-Ramirez GA, Agarwal M, Di Russo G, Lin CS, Garg P, Larsen CP. A phase III study of belatacept-based immunosuppression regimens versus cyclosporine in renal transplant recipients (BENEFIT study). *Am J Transplant* 2010; **10**: 535-546 [PMID: 20415897 DOI: 10.1111/j.1600-6143.2009.03005.x]
- 3 **Calmet FH**, Yarur AJ, Pukazhendhi G, Ahmad J, Bhamidimarri KR. Endoscopic and histological features of mycophenolate mofetil colitis in patients after solid organ transplantation. *Ann Gastroenterol* 2015; **28**: 366-373 [PMID: 26126799]
- 4 **Marthey L**, Mateus C, Mussini C, Nachury M, Nancey S, Grange F, Zallot C, Peyrin-Biroulet L, Rahier JF, Bourdier de Beaugrand M, Mortier L, Coutzac C, Soularue E, Lanoy E, Kapel N, Planchard D, Chaput N, Robert C, Carbonnel F. Cancer Immunotherapy with Anti-CTLA-4 Monoclonal Antibodies Induces an Inflammatory Bowel Disease. *J Crohns Colitis* 2016; **10**: 395-401 [PMID: 26783344 DOI: 10.1093/ecco-jcc/ijv227]
- 5 **Chaput N**, Lepage P, Coutzac C, Soularue E, Le Roux K, Monot C, Boselli L, Routier E, Cassard L, Collins M, Vaysse T, Marthey L, Eggermont A, Asvatourian V, Lanoy E, Mateus C, Robert C, Carbonnel F. Baseline gut microbiota predicts clinical response and colitis in metastatic melanoma patients treated with ipilimumab. *Ann Oncol* 2017; **28**: 1368-1379 [PMID: 28368458 DOI: 10.1093/annonc/mdx108]
- 6 **Sandborn WJ**, Colombel JF, Sands BE, Rutgeerts P, Targan SR, Panaccione R, Bressler B, Geboes K, Schreiber S, Aranda R, Gujrahi S, Luo A, Peng Y, Salter-Cid L, Hanauer SB. Abatacept for Crohn's disease and ulcerative colitis. *Gastroenterology* 2012; **143**: 62-69.e4 [PMID: 22504093 DOI: 10.1053/j.gastro.2012.04.010]
- 7 **Amezua-Guerra LM**, Hernández-Martínez B, Pineda C, Bojalil R. Ulcerative colitis during CTLA-4Ig therapy in a patient with rheumatoid arthritis. *Gut* 2006; **55**: 1059-1060 [PMID: 16766771 DOI: 10.1136/gut.2006.095539]
- 8 **Motohashi R**, Ikeuchi H, Hiromura K, Ohishi Y, Sakurai N, Sakairi T, Kaneko Y, Maeshima A, Nojima Y. Two cases of

- ulcerative colitis developing in rheumatoid arthritis patients during abatacept therapy. *Scand J Gastroenterol* 2014; **49**: 1270-1271 [PMID: 25115461 DOI: 10.3109/00365521.2014.946087]
- 9 **Hentrich M**, Oruzio D, Jäger G, Schlemmer M, Schleuning M, Schiel X, Hiddemann W, Kolb HJ. Impact of human herpesvirus-6 after haematopoietic stem cell transplantation. *Br J Haematol* 2005; **128**: 66-72 [PMID: 15606551 DOI: 10.1111/j.1365-2141.2004.05254.x]
- 10 **Lamoth F**, Jayet PY, Aubert JD, Rotman S, Mottet C, Sahli R, Lautenschlager I, Pascual M, Meylan P. Case report: human herpesvirus 6 reactivation associated with colitis in a lung transplant recipient. *J Med Virol* 2008; **80**: 1804-1807 [PMID: 18712834 DOI: 10.1002/jmv.21268]
- 11 **Sipponen T**, Turunen U, Lautenschlager I, Nieminen U, Arola J, Halme L. Human herpesvirus 6 and cytomegalovirus in ileocolonic mucosa in inflammatory bowel disease. *Scand J Gastroenterol* 2011; **46**: 1324-1333 [PMID: 21879802 DOI: 10.3109/00365521.2011.605466]

**P- Reviewer:** Kim KJ, Saniabadi AR **S- Editor:** Qi Y **L- Editor:** A  
**E- Editor:** Huang Y





Published by **Baishideng Publishing Group Inc**  
7901 Stoneridge Drive, Suite 501, Pleasanton, CA 94588, USA  
Telephone: +1-925-223-8242  
Fax: +1-925-223-8243  
E-mail: [bpgooffice@wjgnet.com](mailto:bpgooffice@wjgnet.com)  
Help Desk: <http://www.f6publishing.com/helpdesk>  
<http://www.wjgnet.com>



ISSN 1007-9327

