



HAL
open science

BOLD delay times using group delay in sickle cell disease

Julie Coloigner, Chau Vu, Adam Bush, Matt Borzage, Vidya Rajagopalan,
Natasha Leporé, John Wood

► **To cite this version:**

Julie Coloigner, Chau Vu, Adam Bush, Matt Borzage, Vidya Rajagopalan, et al.. BOLD delay times using group delay in sickle cell disease. SPIE Medical Imaging, Feb 2016, San Diego, United States. 10.1117/12.2217263 . hal-01710721

HAL Id: hal-01710721

<https://hal.science/hal-01710721>

Submitted on 15 May 2018

HAL is a multi-disciplinary open access archive for the deposit and dissemination of scientific research documents, whether they are published or not. The documents may come from teaching and research institutions in France or abroad, or from public or private research centers.

L'archive ouverte pluridisciplinaire **HAL**, est destinée au dépôt et à la diffusion de documents scientifiques de niveau recherche, publiés ou non, émanant des établissements d'enseignement et de recherche français ou étrangers, des laboratoires publics ou privés.

BOLD delay times using group delay in sickle cell disease

Julie Coloigner^{a,b}, Chau Vu^{a,b}, Adam Bush^d, Matt Borzage^{a,c,d}, Vidya Rajagopalan^{a,b,e},
Natasha Lepore^{a,b}, and John Wood^d

^a Department of Radiology, Children’s Hospital, Los Angeles

^b CIBORG laboratory, Department of Radiology, Children’s Hospital, Los Angeles

^c Department of Neonatology, Children’s Hospital Los Angeles

^d Department of Cardiology, Childrens Hospital, Los Angeles

^e Rudi Schulte Research Institute, Santa Barbara CA

ABSTRACT

Sickle cell disease (SCD) is an inherited blood disorder that effects red blood cells, which can lead to vasoocclusion, ischemia and infarct. This disease often results in neurological damage and strokes, leading to morbidity and mortality. Functional Magnetic Resonance Imaging (fMRI) is a non-invasive technique for measuring and mapping the brain activity. Blood Oxygenation Level-Dependent (BOLD) signals contain also information about the neurovascular coupling, vascular reactivity, oxygenation and blood propagation. Temporal relationship between BOLD fluctuations in different parts of the brain provides also a mean to investigate the blood delay information. We used the induced desaturation as a label to profile transit times through different brain areas, reflecting oxygen utilization of tissue. In this study, we aimed to compare blood flow propagation delay time between these patients and healthy subjects in areas vascularized by anterior, middle and posterior cerebral arteries. At first, BOLD changes in these areas were almost simultaneous and shorter in the SCD patients, because of their increased brain blood flow. Secondly, the analysis of a patient with a stenosis on the anterior cerebral artery indicated that signal of the area vascularized by this artery lagged the MCA signal. These findings suggested that sickle cell disease causes blood propagation modifications, and these changes could be used as a biomarker of vascular damage.

Keywords: Functional magnetic resonance imaging, desaturation, group delay, sickle cell disease

1. INTRODUCTION

Sickle cell disease (SCD) is a chronic blood disorder caused by a mutation in the hemoglobin beta gene that affects millions of people throughout the world, particularly descendants of Sub-Saharan African.¹ Red blood cells are poorly deformable and rupture easily, leading to vasoocclusion,² chronic vascular damage, cerebral ischemia and stroke.³ Patients are also chronically anemic, leading to high cerebral blood flow,⁴ decreased cerebrovascular reserve and impaired autoregulation. Previous studies have shown that SCD patients have low resting cerebral oxygen saturation values,⁵ and have frequent nocturnal desaturation episodes; these nocturnal desaturations are associated with increased risk of stroke.⁶ In this study, we investigate the effect of a single induced desaturation on the SCD brain. During this state, there are systematic autonomic cerebrovascular responses, such as vasodilation and increases in respiration rate, heart rate, cerebral blood volume, and cerebral blood flow (CBF), to compensate for reduced inspired oxygen.^{7,8}

Functional Magnetic Resonance Imaging (fMRI) is a non-invasive technique for measuring and mapping the brain activity. Spontaneous low frequency fluctuations in Blood Oxygenation Level-Dependent (BOLD) signals have been observed during rest and the synchronicity between the signals in spatially distinct regions have been used to detect resting state functional networks (such as default mode, sensorimotor or visual networks).⁹ Among them, the default mode network (DMN) comprising mainly the posterior cingulate cortex/precuneus (PCC/PCu), medial prefrontal cortex (mPFC), and the angular/lateral parietal cortex, reflects baseline brain activation in the absence of external stimuli.¹⁰ While resting-state BOLD is typical used for evaluating the brain functional connectivity alterations in various disease, fMRI signal contain information about the neurovascular coupling, vascular reactivity, oxygenation and blood propagation. Indeed, temporal relationship between BOLD fluctuations in different parts of the brain provides also a mean to investigate the blood delay information.¹¹

Moreover, this time delay approach may provide pathophysiological information comparable to that provided by parameters of contrast-based perfusion MRI and thus serve as a useful diagnostic tool for identifying strokes¹¹ or stenosis¹² without the need for the application of a contrast agent.

In this study, we analyzed blood flow propagation delay time in patients with SCD. Indeed, this cerebrovascular disease is associated with higher CBF, suggesting that may underlie the pathophysiology of ischemic stroke. Moreover, we used the induced desaturation as a label to profile transit times through different brain areas, reflecting oxygen utilization of tissue. We calculated blood flow propagation delays using a Group Delay method,¹³ based on Fourier analysis to estimate the harmonic phase differences between the BOLD signals in the frequency domain. Moreover, we evaluated magnetic resonance angiography (MRA) scans of the SCD patients to identify large-vessel pathologies, which can have an impact on the arterial circulation. In the results, we compared the delay time of the tissue areas between patients with SCD and healthy subjects and determined the impact of vascular damage on the arteriovenous delay time.

2. MATERIALS AND METHODS

2.1 Dataset

This study was approved by institutional review board and conducted at Children’s Hospital Los Angeles (CHLA) between January 2012 and August 2015. We restricted our population to adolescents and young adults without strokes. 12 SCD patients (age= 17.1 ± 4.2) and 9 control subjects (age= 22.2 ± 1.8) were included in this analysis. The patient groups were matched in terms of sex and ethnically.

MRI data were acquired on a 1.5 Tesla, eight channel head coil, Achieva Philips Scanner. A 3D T1-weighted image was acquired covering the whole brain (160 sagittal slices) with TR = 8.20 s, TE = 3.77 ms, flip angle = 8, in-plane resolution = 256×256 , FOV = 256 mm \times 224 mm and thickness/gap = 1.0/0 mm). During resting-state fMRI scanning, subjects were instructed to close their eyes, keep still as much as possible, not to think of anything systematically and not to fall asleep. The functional images were acquired with the following parameters: TR = 2000 ms, TE = 50 ms, flip angle = 90, in-plane resolution = 96×96 , FOV = 220 mm \times 220 mm, 26 axial slices, thickness/gap = 5/0 mm. A total of the 150 volumes were collected in 6 minutes.

Brain MRA was performed using three-dimensional time-of-flight angiography of the circle of Willis with maximal intensity projection (MIP) reconstruction. Sequence parameters used were TR = 23ms, TE = 3.5 ms, 150 slices, 0.7 mm thick and a directional field of view of 10.5 cm.

All patients breathed through a scuba mouthpiece in order to control the oxygen level during the experiment in the fMRI; nasal airflow was occluded. The subjects performed a scan in which they breathed 1) room air for 50 s, 2) 100 % N₂ for 5 breaths and 3) room during 5 minutes. The typical length of hypoxia is 5 breaths or 20 seconds for patients with irregular breathing patterns.

2.2 Preprocessing steps

Functional data were preprocessed using the FMRIB Software Library (FSL), with standard steps. The first 2 volumes from each subject were discarded to allow the signal to reach equilibrium and to allow the participant to adapt to the scanning noise. The remaining 148 images were motion-corrected using a rigid 6 degrees of freedom transformation, with FSLs MCFLIRT, to remove physiological motion such as high-frequency respiratory and cardiac noise. For each subject, the mean fMRI images were normalized to the structural images. Then, the registered fMRI volumes were normalized and smoothed with a Gaussian kernel of 8mm \times 8 mm \times 8mm full-width at half maximum (FWHM). Finally, 3D T1-weighted image was linearly transformed to the Montreal Neurological Institute (MNI) template space, using the FLIRT and FNIRT algorithms of FSL. By concatenating two coregistration transformations, each fMRI volume was normalized into the MNI template.

The MRA data was aligned to the 3D T1-weighted image using the rigid registration tool FLIRT. Using the transformation of 3D T1-weighted image, the image was registered into the MNI template.

To analyze the impact of the desaturation in BOLD signals, we selected 3 areas, each representing an tissue territory vascularized by a cerebral artery. As displayed in Figure 1, Regions Of Interest (ROI) are used: 1) area (shown in red) vascularized by posterior cerebral artery [MNI: Z=3], 2) area (shown in red) vascularized by

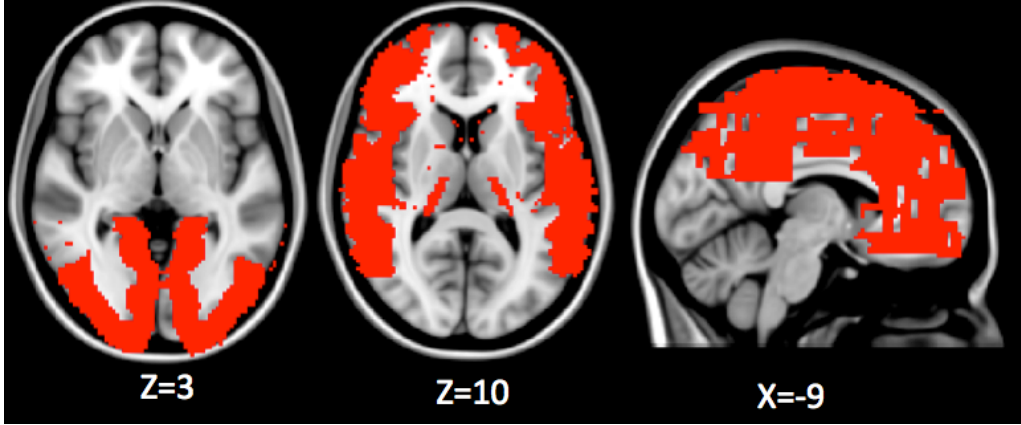


Figure 1. Anatomical locations of the 3 seed regions in the MNI template, indicated by arrows:1) area (shown in red) vascularized by posterior cerebral artery [MNI: Z=3], 2) area (shown in red) vascularized by anterior cerebral artery [MNI: Z=10], and 3) area (shown in red) vascularized by anterior cerebral artery [MNI: X=-9].

anterior cerebral artery [MNI: Z=10], and 3) area (shown in red) vascularized by middle cerebral artery [MNI: X=-9]. A time series were generated by extracting the mean signal within the ROI. The reference time series were determined from a average signal of 4.5cm-radius spheres centered on the center of the brain [MNI:-1,-23,29], as an approximation of whole brain. A filtering step is applied on every signal in order to reduce the oscillations before and after the desaturation.

2.3 Delay time calculation

The delay time, called Δt , is the time shift between the reference time course and the time serie for each ROI, $x(t)$ and $y(t)$, respectively. A well-known method is the voxel-wise cross-correlation for measuring time delay estimation, used in various studies.¹¹ The analysis was performed shifting the time course signal for each ROI between $-3TR$ to $+3TR$ to determine the offset associated with the highest correlation coefficient with the reference signal. Note that the blood takes about 7 seconds to propagate through the brain. Given the long TR (2s), interpolation techniques applied to the cross correlation function have proved to improve temporal discrimination prior to Δt assessment. However, in practice if the signals are corrupted with noise, other signal processing techniques are considered more robust.

In this paper, we improve the technique of measuring the delay time, by using the phase-offset as a function of frequency for fMRI data. Meloni et. al.¹³ proposed a group delay (GD) method to estimate aortic pulse wave delay time in cardiovascular magnetic resonance. This method have been shown to be more robust to low temporal resolution as in fMRI. We propose to apply a group delay (GD) method, based on Fourier analysis to estimate the harmonic phase differences between the reference time course and the BOLD signal for every ROI.

We model the reference signal, $x(t)$ as an input passing through a discrete-component filter, producing an output $y(t)$, which represents a time series of a voxel. The GD of that filter represents the average time-delay across frequency bands of a given signal, by differentiating the phase response with respect to $\omega = 2\pi f$, with f is the frequency:

$$GD = -\frac{\partial \angle X(\omega)}{\partial \omega} \quad (1)$$

where $\angle X$ denotes the unwrapped phase of X , which is the Fourier transform of the transfer function as a ratio between $x(t)$ and $y(t)$ in the frequency domain.

The Δt is given by:

$$\Delta t = \frac{|X|^2 \times GD}{\sum |X|^2} \quad (2)$$

where $|X|$ is its magnitude of the transfer function. The delay time is expressed in seconds.

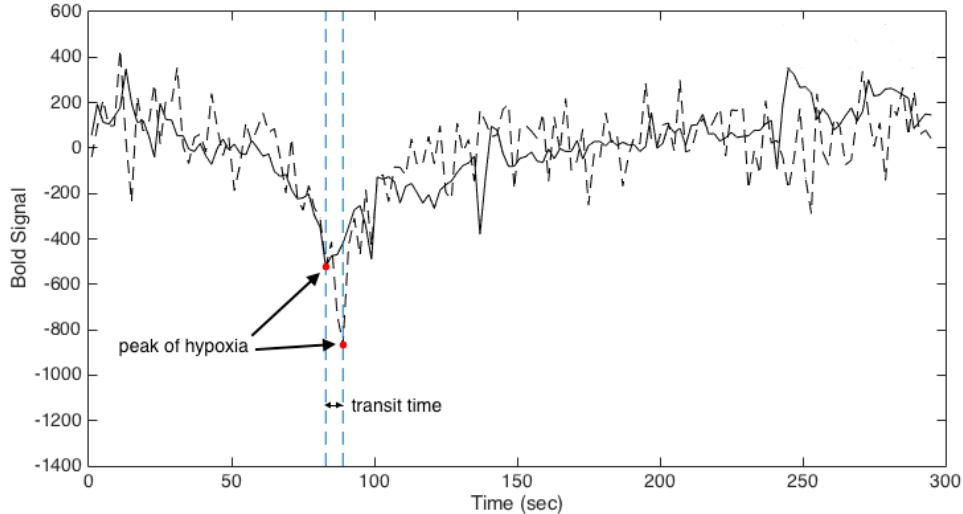


Figure 2. Representation of BOLD signals of the ACA-territory and a reference signal. The desaturation part is observed between 50 and 70 seconds. The delay time, which corresponds to the time shift between two signals is indicated by an arrow.

Cerebral region	Control group	SCD group
ACA-territory	0.68	0.58
MCA-territory	0.85	0.67
PCA-territory	0.94	0.82

Table 1. Delay times between the reference and average signals of areas vascularized by ACA, MCA and PCA, for the control and SCD groups

3. RESULTS

Cerebral angiograms were performed in 12 patients with SCD. The maximum intensity projection MR angiography image was normal in 11 patients. As shown on Figure 3, one patient had abnormalities in the anterior cerebral artery, which was stenosed. Patients with sickle cell disease have a reported incidence of cerebral vascular occlusive disease as high as 15%. It is estimated that for 64% of those the anterior cerebral artery was involved.² At first, the patient with cerebrovascular abnormality was excluded from the analysis. Indeed, this stenosis has an impact on the arterio-venous transit time in the frontal lobe.

Table 1 illustrates the results of group delay method for these 3 regions between control subjects and SCD patients without cerebrovascular abnormality. We found that the delays are positive, indicating that BOLD signal in those regions lagged the average brain BOLD response to hypoxia.

Desaturation appeared first in the area vascularized by ACA. The MCA-territories were the next region to exhibit BOLD decrease, followed by the PCA-territory. But the difference of the delay times between the 3 territories was very small, about 0.25 seconds. This findings were almost in accordance with the results from arterial spin labeling experiments, which suggested a similar arterial transit times in the ACA, MCA and PCA vascular distribution.¹⁴

Moreover, BOLD changes in the areas vascularized by ACA, MCA and PCA were likely shorter in the SCD patients because of their increased brain blood velocity and flow.

Concerning the patient affected by a stenosis of ACA (see Figure 3), the arteriovenous delay times were modified. Indeed, the delay times of ACA-, MCA- and PCA-territories were 0.724, 0.284 and 0.293, respectively. The average signal of the ACA-territories lagged the MCA signal by 0.4 seconds. This method was capable of depicting abnormal time delay in the area vascularized by the stenosed artery, that could be employed to identify cerebrovascular damage.

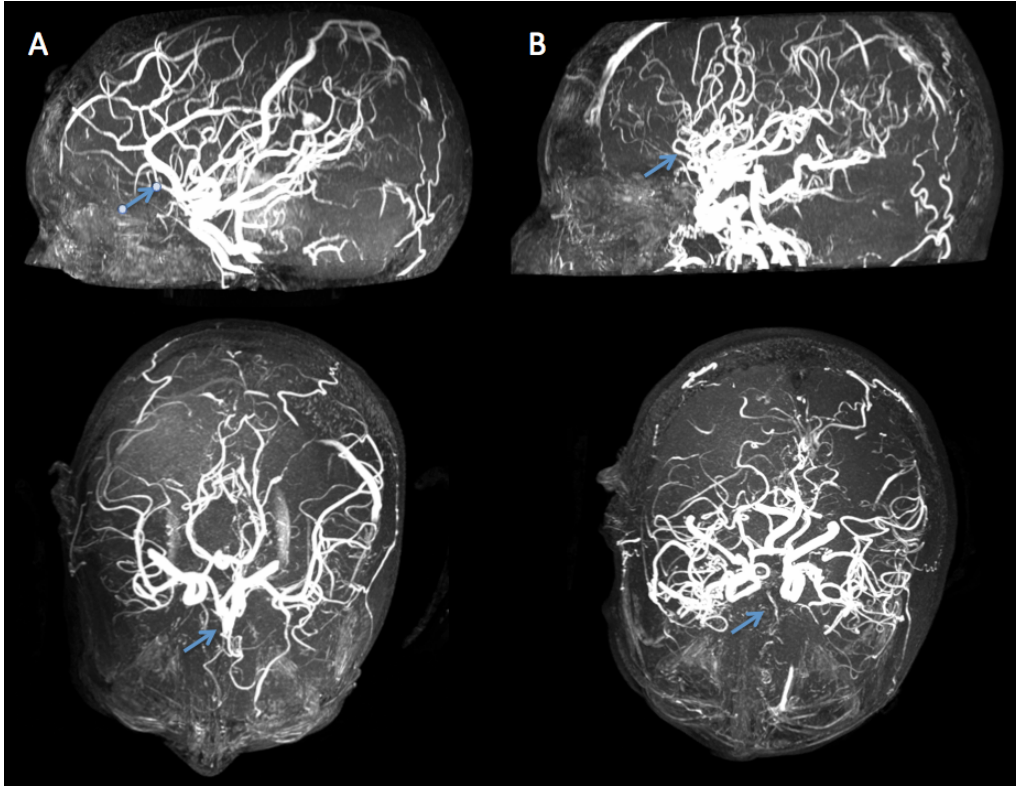


Figure 3. The maximum intensity projection MR angiography image of a control subject (images A) and a sickle cell disease patient (images B) with a very thin ACA, as indicated by the arrows in the sagittal views.

4. CONCLUSION

In this paper, we use the induced desaturation as a label to profile arterio-venous transit times through different brain areas. A group delay method uses to profile transit times through the dominant vascular territories, reflecting oxygen utilization of tissue. Arterio-venous delays were also markedly similar in the ACA, MCA and PCA distributions, as found from arterial spin labeling experiments. Moreover, the delay times of the ACA-, MCA and PCA-territories were shorter in SCD patients, likely secondary to increased cerebral blood flow. The analysis of a patient with a stenosis on the ACA indicated that arterio-venous delay was abnormal in the ACA-territory. These findings suggested that sickle cell disease causes blood propagation modifications, and these abnormalities of time delay could be used as a biomarker of vascular damage.

REFERENCES

- [1] Rees, D., Williams, T. N., and Gladwin, M. T., "Sickle-cell disease," *The Lancet* **376**(9757), 2018–2031 (2010).
- [2] Gerald, B., Sebes, J. I., and Langston, J., "Cerebral infarction secondary to sickle cell disease: arteriographic findings," *American Journal of Neuroradiology* **1**(2), 149–152 (1980).
- [3] DeBaun, M., Armstrong, F., McKinstry, R., Ware, R., Vichinsky, E., and Kirkham, F., "Silent cerebral infarcts: a review on a prevalent and progressive cause of neurologic injury in sickle cell anemia," *Blood* **119**(20), 4587–4596 (2012).
- [4] Borzage, M. T., Bush, A., Choi, S., Nederveen, A., Vaclavu, L., Coates, T., and Wood, J., "Predictors of cerebral blood flow in patients with and without anemia," *Journal of Applied Physiology*, DOI: 10.1152/jap-physiol.00994.2015 (2016).
- [5] Nahavandi, M., Nichols, J., Hassan, M., Gandjbakhche, A., and Kato, G., "Near-infrared spectra absorbance of blood from sickle cell patients and normal individuals," *Hematology* **14**(1), 46–48 (2009).

- [6] Kirkham, F., Hewes, D., Prengler, M., Wade, A., Lane, R., and Evans, J., “Nocturnal hypoxaemia and central-nervous-system events in sickle-cell disease,” *The Lancet* **357**(9269), 1656–1659 (2001).
- [7] Duong, T., “Cerebral blood flow and bold fmri responses to hypoxia in awake and anesthetized rats,” *Brain research* **1135**, 186–194 (2007).
- [8] Poublanc, J., Han, J., Mandell, D., Conklin, J., Stainsby, J., Fisher, J. A., Mikulis, D., and Crawley, A., “Vascular steal explains early paradoxical blood oxygen level-dependent cerebrovascular response in brain regions with delayed arterial transit times,” *Cerebrovascular diseases extra* **3**(1), 55–64 (2013).
- [9] Damoiseaux, J., Rombouts, S., Barkhof, F., Scheltens, P., Stam, C., Smith, S., and Beckmann, C., “Consistent resting-state networks across healthy subjects,” *Proceedings of the national academy of sciences* **103**(37), 13848–13853 (2006).
- [10] Raichle, M., MacLeod, A., Snyder, A., Powers, W., Gusnard, D., and Shulman, G., “A default mode of brain function,” *Proc Natl Acad Sci* **98**(2) (2001).
- [11] Christen, T., Jahanian, H., Ni, W. W., Qiu, D., Moseley, M. E., and Zaharchuk, G., “Noncontrast mapping of arterial delay and functional connectivity using resting-state functional mri: A study in moyamoya patients,” *Journal of Magnetic Resonance Imaging* **41**(2), 424–430 (2015).
- [12] Lv, Y., Margulies, D. S., Cameron Craddock, R., Long, X., Winter, B., Gierhake, D., Endres, M., Villringer, K., Fiebach, J., and Villringer, A., “Identifying the perfusion deficit in acute stroke with resting-state functional magnetic resonance imaging,” *Annals of neurology* **73**(1), 136–140 (2013).
- [13] Meloni, A., Zymeski, H., Pepe, A., Lombardi, M., and Wood, J. C., “Robust estimation of pulse wave transit time using group delay,” *Journal of Magnetic Resonance Imaging* **39**(3), 550–558 (2014).
- [14] Wang, J., Alsop, D., Song, H., Maldjian, J., Tang, K., Salvucci, A., and Detre, J., “Arterial transit time imaging with flow encoding arterial spin tagging (feast),” *Magnetic resonance in medicine* **50**(3), 599–607 (2003).