



HAL
open science

Interventional planning and assistance for ascending aorta dissections

Christophe Lohou, Pawel Lubniewski, Nawel Fetnaci, Bruno Miguel, Laurent Sarry

► **To cite this version:**

Christophe Lohou, Pawel Lubniewski, Nawel Fetnaci, Bruno Miguel, Laurent Sarry. Interventional planning and assistance for ascending aorta dissections. Colloque Recherche en Imagerie et Technologies pour la Santé - RITS 2013, Apr 2013, Bordeaux, France. hal-01706143

HAL Id: hal-01706143

<https://hal.science/hal-01706143>

Submitted on 10 Feb 2018

HAL is a multi-disciplinary open access archive for the deposit and dissemination of scientific research documents, whether they are published or not. The documents may come from teaching and research institutions in France or abroad, or from public or private research centers.

L'archive ouverte pluridisciplinaire **HAL**, est destinée au dépôt et à la diffusion de documents scientifiques de niveau recherche, publiés ou non, émanant des établissements d'enseignement et de recherche français ou étrangers, des laboratoires publics ou privés.

Interventional planning and assistance for ascending aorta dissections

Christophe Lohou¹, Paweł Lubniewski^{1,2}, Nawel Fetnaci¹, Bruno Miguel^{1,3}, Laurent Sarry¹

1. Clermont Université, Université d'Auvergne, ISIT-UMR 6284 UdA-CNRS, BP 10448, F-63000 Clermont-Ferrand (France)
2. Cardinal Stefan Wyszyński University, Faculty of Mathematics and Natural Sciences, Warsaw (Poland)
3. CHU Gabriel Montpied, Service de Chirurgie Cardio-Vasculaire, Pôle Cardiologie, 58 rue Montalembert, BP69, F-63003 Clermont-Ferrand (France)

Abstract— In this paper, we present our actual works concerning interventional planning and assistance for ascending aorta dissections.

The first part is about aortic dissection retrieval in Computed Tomography Angiography (CTA) images. It is based on fast marching segmentation, mathematical morphology and digital topology frameworks.

The second part is about the registration of the outer aortic wall onto X-ray fluoroscopic angiographic images. It is based on either Digital Reconstructed Radiographs (DRRs) or parametric model projection, then on image transformation descriptors (ITDs) computing.

Our motivation is first to give 3D views of dissecting aorta in peroperative step to assess the dissection, then to augment the current angiographic view by registering aortic dissection features during the intraoperative step to assist clinicians.

Keywords

aortic dissections, segmentation, 3D/2D registration, augmented reality

I. INTRODUCTION

Aortic dissections are caused by one or more aortal tissue perforation(s) because of tissue weakness and blood pressure. That consists of one or several *intimal tear(s)* (Fig. 1 (left)) and a clear separation between layers of the aortic media, resulting in two separate blood flow channels : the *true lumen* (the normal bed of blood in the aorta) and the *false lumen* (a channel entirely within the media which appears during an aortic dissection). The layer of detached aorta tissues between lumens is called *intimal flap*.

To deal with aortic dissections, physicians require preoperative 3D Computed Tomography Angiography (CTA) images (Fig. 1 (right)), then intraoperative 2D X-ray (here fluoroscopic, by a monoplane C-arm system) angiographic images (Fig. 3).

Our works consist in segmenting 3D CTA images to retrieve aortic dissection features, and to register them to X-ray images.

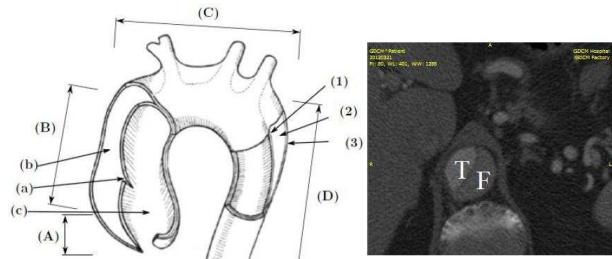


FIGURE 1 – (left) (1), (2) and (3) respectively intima, media and adventitia layers; (a) an intimal tear, (b) the false lumen; (c) the true lumen. (right) 2D grayscale Computed Tomography Angiography slice (T : true lumen, F : false lumen).

II. SEGMENTATION

In this section, we summarize our different works related to aortic dissection features extraction. They are schematized in Fig. 2.

Preprocessing. Let us consider an initial CT aortic dissection image : I_1 . We perform a crop to accelerate image processing : I_2 .

Lumens retrieval. Fast marching method (FM in the following) is an efficient implementation of level set deformable models. We initialize FM by defining a single voxel inside a lumen. Is it possible to limit the number of iterations of the evolution process to avoid the propagation to other arteries (collateral arteries) but the 3D propagation front reaches the heart : I_3 . By using a morphological opening, we may cut that part of heart : we obtain the image of the two interconnected lumens I_4 .

By modifying the speed function of FM, and using an intermediate labelling image (of points in the neighborhood of the intimal flap [dark grayscale]), we succeed in separating the two lumens[2] : I_5 and I_6 .

Lumens distinction. By using the fact that grayscale value of blood is higher inside the true lumen, a quick operator (mean intensity inside each lumen) allowed us to distinguish between the true lumen and the false lumen, obtaining thus the false lumen image I_7 and the true lumen image I_8 .

Intimal flap retrieval. A two-step procedure (a se-

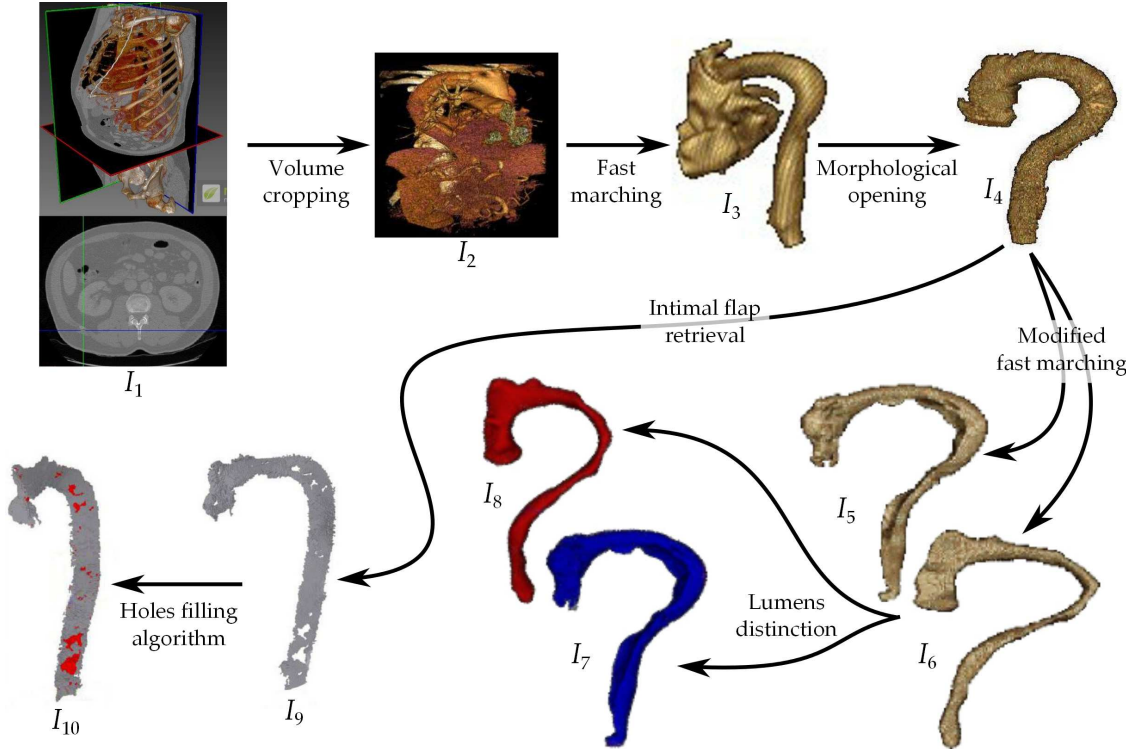


FIGURE 2 – Aortic dissection segmentation : I_7 false lumen, I_8 true lumen, I_9 intimal flap, I_{10} entry tears in red.

quel of n morphological dilations followed by a sequel of n morphological erosions) gives the image of the intimal flap : I_9 .

Intimal tears materializing. The first challenge of our works was to obtain the entry tears from a CT. Because they do not correspond to physical tissues or organs, such a segmentation cannot be direct. Intimal tears may be considered as 3D holes in the intimal flap. Therefore, we used a holes filling algorithm proposed in Digital Topology framework[1] : the surfaces filling holes in I_9 are shown in red in I_{10} ; they correspond to the location of intimal tears.

III. REGISTRATION

The main goal of our registration framework is to provide an alignment of pre- and intra-operational medical images (see Fig. 3).

Source image for registration. See the top row of Fig. 3. The reference image is a 2D *X-ray fluoroscopic angiography* sequence, acquired directly in the interventional room. In order to augment the aorta visibility, a filtering technique has been applied on the whole set of angiographic frames, to yield a single 2D image called *Amplification image*. Binarizing the previous image, we obtain the *Binarized amplification*, which is the fixed input for the *Registration algorithm*.

Target image for registration. The *Segmented*

aorta (issued from a *CTA 3D image*) plays the role of the (moving) target to establish the 3D/2D correspondence.

Now, we give three ways to compute a 2D model of that target :

- One way [center row of Fig. 3] is to compute a *Digitally Reconstructed Radiograph (DRR)* from the aorta interior ; the projection parameters are computed in the registration process.
- Another alternative solution [bottom row of Fig. 3] is to define an aorta parametric model (by interactive construction[3]) and to generate its *Rapid model projection*.
- The parametric model reconstruction issued from the segmentation image could also be considered (* on Fig. 3).

Both *Binarized DRR* and *Model projection* images are the alternative moving inputs for the registration algorithm.

Initial 3D pose computing. A novel *ITD registration* technique of rapid 3D/2D alignment is applied[4]. It computes directly the spatial correspondence between projections, using image transformation descriptors (ITDs), such as moments, area ... Then, the volume *3D pose estimation* is achieved.

Accurate registration. The last stage of the pipeline is a *Precise 3D/2D registration technique*, well initialized by the previously described algorithm. We will consider one of the iconic methods with mul-

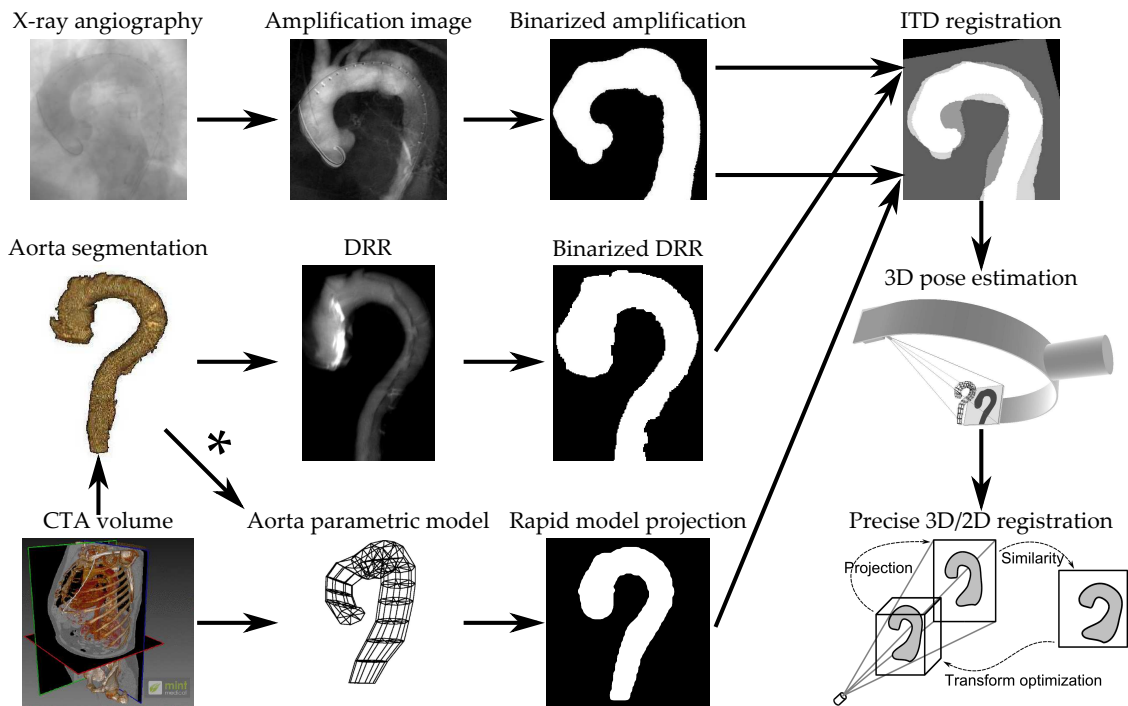


FIGURE 3 – 3D/2D registration framework.

timodal similarity measure (correlation or entropy based).

IV. CONCLUSION

In this paper, we presented our actual works concerning aortic dissection features extraction from a CTA image, and the registration of a segmented outer aortic wall on a X-ray fluoroscopic image. We have distinguished the two lumens (Fig. 4 (a)), augmented CTA slices with these data (Fig. 4 (b)), proposed a virtual angioscopy (Fig. 4 (c)).

Our future works consist in registering the whole set of features extraction (intimal tears, intimal flap, true lumen, false lumen) on fluoroscopic angiographic images; a sketch is given in Fig. 4 (d).

REFERENCES

- [1] C. Lohou and B. Miguel. Detection of the aortic intimal tears by using 3D digital topology. SPIE Electronic Imaging 2011.
- [2] N. Fetnaci, P. Lubniewski, B. Miguel and C. Lohou. 3D segmentation of the true and false lumens on CT aortic dissection images. SPIE Electronic Imaging 2013.
- [3] P. Lubniewski, B. Miguel, V. Sauvage and C. Lohou. Interactive 3D segmentation by tubular envelope model for the aorta treatment. SPIE Electronic Imaging 2011.
- [4] P. Lubniewski, L. Sarry, B. Miguel and C. Lohou. 3D/2D image registration by image transformation descriptors (ITDs) for thoracic aorta imaging. SPIE Electronic Imaging 2013.

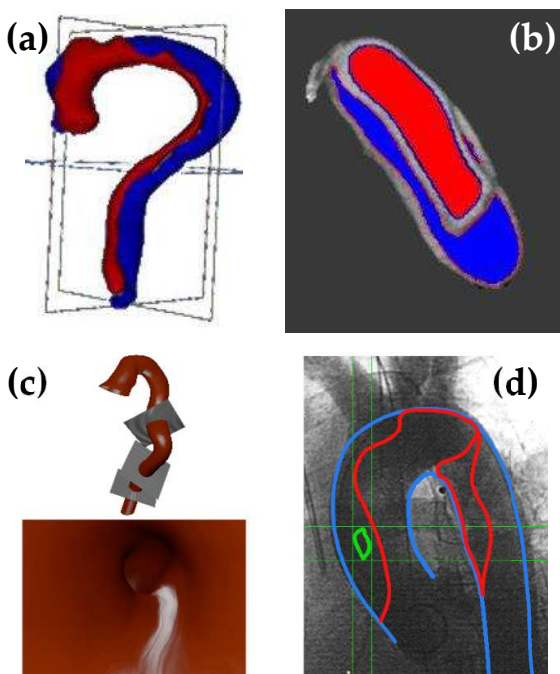


FIGURE 4 – Virtual reality : (a) 3D view of the two lumens, (b) virtual angioscopy. Augmented reality (c) on CTA-images, (d) on X-ray images.