



HAL
open science

Aorta Lumens Centerlines Extraction and possible Entry Tears Location in the case of Aortic Dissections, based on a 3D Image Topological Analysis

Christophe Lohou, B Miguel

► **To cite this version:**

Christophe Lohou, B Miguel. Aorta Lumens Centerlines Extraction and possible Entry Tears Location in the case of Aortic Dissections, based on a 3D Image Topological Analysis. *International Journal of Computer Assisted Radiology and Surgery*, 2011, 6 (1), pp.S312. 10.1007/s11548-011-0613-1 . hal-01704919

HAL Id: hal-01704919

<https://hal.science/hal-01704919>

Submitted on 8 Feb 2018

HAL is a multi-disciplinary open access archive for the deposit and dissemination of scientific research documents, whether they are published or not. The documents may come from teaching and research institutions in France or abroad, or from public or private research centers.

L'archive ouverte pluridisciplinaire **HAL**, est destinée au dépôt et à la diffusion de documents scientifiques de niveau recherche, publiés ou non, émanant des établissements d'enseignement et de recherche français ou étrangers, des laboratoires publics ou privés.

Aorta Lumens Centerlines Extraction and possible Entry Tears Location in the case of Aortic Dissections, based on a 3D Image Topological Analysis

C. LOHOU¹, B. MIGUEL²

¹ Clermont Université, Université d'Auvergne,
Image Science for Interventional Techniques (ISIT),
BP 10448, F-63000 Clermont-Ferrand, France

Correspondance:

Institut Universitaire de Technologie du Puy-en-Velay, Dépt Informatique,
8, rue Jean-Baptiste Fabre, BP 70 219, F-43000 Le Puy-en-Velay, France

² Clermont Université, Université d'Auvergne,
CHU Clermont-Ferrand, Service Chirurgie Cardio-Vasculaire,
F-63003 Clermont-Ferrand, France

Keywords: 3D topological analysis, centerlines retrieval, aortic intimal tears segmentation, cardiovascular surgery

Purpose

The thoracic aorta is composed of three segments: the *ascending aorta*, the *aortic arch*, and the *descending aorta*. This artery is made up of three layers: the *intima* (in direct contact with the blood flow), the *media* and the *adventitia* (farthest from blood flow).

An aortic dissection -- a medical emergency which can quickly lead to death -- is characterized by the presence of an *entry tear* (or *intimal tear*) in the intima and a clear separation between layers of the aortic media, resulting in two separate blood flow channels, *i.e.*, the *true lumen* (the normal bed of blood) and the *false lumen* (a channel entirely within the media). Separating the false lumen from the true lumen is a layer of intimal tissue known as the *intimal flap* [1].

In this study, we use algorithms of digital topology [2, 3] and graph theory to extract data from computed tomography (CT) scans acquired after an aortic dissection. After image volume preprocessing, a curve thinning algorithm is performed; the obtained object (called *skeleton*) is a network of interconnected curves. By applying a structure of graph on the obtained skeleton, we extract two main curves (centerlines). One of them corresponds to the true lumen; the other one corresponds to the false lumen. These centerlines are used as trajectories for an assisted navigation. Moreover, by segmenting the obtained skeleton, it is possible to localize possible blood connections (intimal tears) between the two lumens, through the intimal flap; as far as we know, this is the first time that such a proposal is made although being crucial for cardiac surgeons.

Methods

Centerlines may be considered as curves: in this study, we have chosen to obtain them by first performing a curve thinning algorithm. Our choice has been to use the parallel curve thinning algorithm for 3D binary images, proposed by Lohou and Bertrand [4], for which the properties of well-centeredness of obtained skeletons and of topology preservation have been proved. In a second time, when the curve skeleton is obtained, we extract centerlines by using a graph theory algorithm.

Then, instead of only focus our attention on centerlines as other existing studies, we also obtain the data of possible blood connections -- entry tears -- between lumens (up to errors of segmentation), which are very difficult to detect by the single examination of 2D grayscale slices.

As far as we know, this is the first time that an assisted 3D location of entry tears is performed, moreover by a quasi-automatic topological segmentation of a skeleton.

Results

The sequel of processing is illustrated in Fig.1, from the initial CT scans (a) to the retrieval of the centerlines and connections between them (possible intimal tears).

Conclusion

This study, mainly based on a 3D topological image analysis (more precisely on the notion of topological numbers), extract centerlines from the skeleton of blood in aorta. Due to the graph structure, it is possible to perform an assisted navigation: for instance, from an end point to the next junction point along the edge (made of curve points); the surgeon has to indicate if he want to go on the same centerline or cross the flap towards the other centerline through a possible entry tear in order to evaluate its position, its size, its state.

Our actual works consist in trying to automatically found real entry tears (and eliminate segmentation errors) by using additional clinical data.

References

- [1] Fleischmann, D., Miller, D.: Diseases of the Heart, Chest and Breast, chap. Clinical 3D and 4D Imaging of the thoracic aorta, pp. 119-130. Springer (2007)
- [2] Kong, T., Rosenfeld, A.: Digital Topology: Introduction and Survey. Comput. Vis., Graph. and Image Process. 48, 357-393 (1989)
- [3] Bertrand, G.: Simple points, topological numbers and geodesic neighborhoods in cubic grids. Pattern Recognit. Lett. 15, 1003-1011 (1994)
- [4] Lohou, C., Bertrand, G.: Two symmetrical thinning algorithms for 3D binary images, based on P-simple points. Pattern Recognit. 40, 2301-2314 (2007)

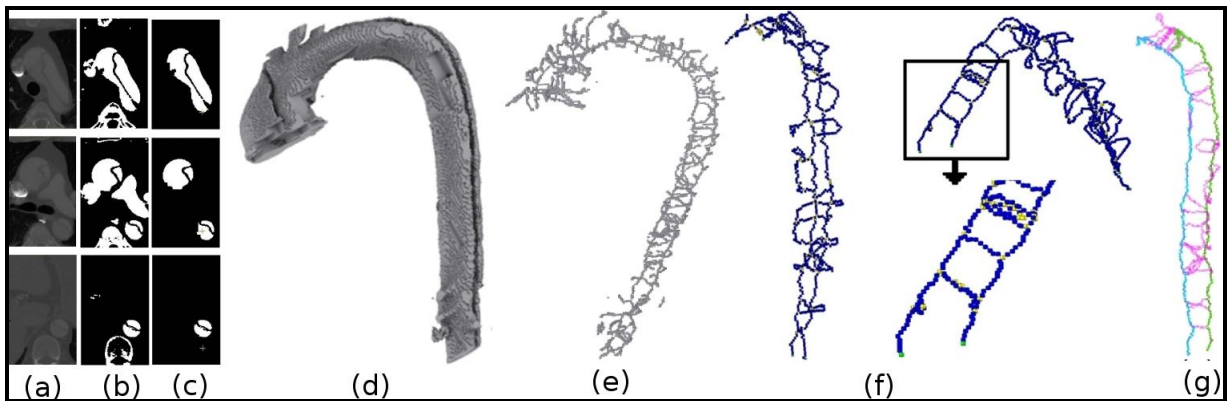


Fig. 1. (a) Three cropped slices of the initial grayscale data volume (#216, #196 and #88). (b) The binarized image of (a). (c) The image obtained by a manual segmentation of (b). (d) 3D reconstruction of (b). (e) The curve skeleton obtained by the used curve thinning algorithm on the object depicted in (d). (f) Results of the topological classification on the filtered object of (e). In blue: curve points; in yellow: curves junction points; in green: end points. (g) The two centerlines are depicted in blue and green. The remaining curves are depicted in pink. They mainly correspond to blood connections (entry points) between the two lumens (up to errors of segmentation).