



HAL
open science

Indicators for lumens distinction on 3D CT aortic dissection images

Nawel Fetnaci, Pawel Łubniewski, Bruno Miguel, Christophe Lohou

► **To cite this version:**

Nawel Fetnaci, Pawel Łubniewski, Bruno Miguel, Christophe Lohou. Indicators for lumens distinction on 3D CT aortic dissection images. *International Journal of Computer Assisted Radiology and Surgery*, 2013, 8 (1), pp.S271-S273. hal-01704915

HAL Id: hal-01704915

<https://hal.science/hal-01704915>

Submitted on 8 Feb 2018

HAL is a multi-disciplinary open access archive for the deposit and dissemination of scientific research documents, whether they are published or not. The documents may come from teaching and research institutions in France or abroad, or from public or private research centers.

L'archive ouverte pluridisciplinaire **HAL**, est destinée au dépôt et à la diffusion de documents scientifiques de niveau recherche, publiés ou non, émanant des établissements d'enseignement et de recherche français ou étrangers, des laboratoires publics ou privés.

Indicators for lumens distinction on 3D CT aortic dissection images

Nawel Fetnaci¹, Paweł Łubniewski¹, Bruno Miguel^{1,2}, Christophe Lohou¹

¹ Clermont Université, Université d'Auvergne, ISIT UMR 6284 CNRS UDA, BP 10448, F-63000 Clermont-Ferrand, France

² CHU Gabriel Montpied, Service de Chirurgie Cardio-Vasculaire, Pôle Cardiologie, 58 rue Montalembert, B.P. 69, 63003 Clermont-Ferrand Cedex 1, France

Keywords: aortic dissection, lumens distinction, segmentation, CT aortic images.

Purpose

Our works are related to the planning and assistance to manage aortic dissections during interventions. Aortic dissection is a life-threatening medical emergency associated with high rates of morbidity and mortality. It consists in one or several tears which begin in the intima allowing blood to travel through a diseased media layer. This process cleaves the normal bed of blood into two lumens (*true lumen* and *false lumen*) separated by an intimal membrane also called *flap* (Fig. 1(a)). See Fig. 1(b) and (c) for a 2D slice retrieved from one of our CT images.

Recently, we have proposed a segmentation of the true and false lumens separately on 3D CT aortic dissection images [1] (see Tab. 1(b)). Our aim was to provide a 3D view of the lumens that we can difficultly obtain either by volume rendering or by another visualization tool which only directly gives the outer contour of the aorta; or by other segmentation methods because they mainly directly segment either only the outer contour of the aorta or other connected arteries and organs both. This segmentation was realized by modifying the speed term of the classical fast marching method. More particularly, the front propagation stops around intimal tears by dealing with intensity values (gradient).

Our works consist in registering the segmented results from a CT aortic dissection image onto an angiographic sequence in order to assist clinicians during their interventions. An automatic lumen distinction allows us to propose a better control for endoprosthesis landing: the stent-graft trajectory must remain only inside the true lumen and not to pass through the false lumen.

In this paper, we present two indicators to easily distinguish true and false lumens in our segmented results. More precisely, these indicators are also based on intensity.

Methods

Mainly, there exist two types of aortic dissections: Type B when the ascending aorta is not dissected, Type A when the ascending aorta is dissected [2].

In case of a Type B dissection, the true lumen can be determined in the following way: we first consider an image cross-section immediately above the heart showing the two lumens; the lumen with smaller cross-sectional area is necessarily the false one, as it ends close to this cross-section. However, for patients with Type A dissection, this rule cannot be used. In the following, we only consider Type A case.

Usually, the image intensity is higher in the true lumen. Therefore, we define our first indicator (*ind1*) as the mean intensity of a given segmented lumen. Sometimes, there is no significant intensity difference between the two lumens: thus we propose a second indicator (*ind2*) to take into account both the mean intensity and the voxels distribution. This indicator is based on Bayesian probability [3]:

$$ind2 = \frac{P * P_1}{P_2},$$

where, P denotes the mean intensity of the current lumen, P_1 denotes voxels distribution in the current lumen, P_2 denotes voxels distribution in the other lumen. All these values belong to $[0, 1]$.

As far as we know, there is only a single work about lumens distinction: this is Kovács work [4] based on cross-sectional area. This method requires the flap segmentation. Flap retrieval is difficult due to the small thickness of such membrane and sometimes to the low resolution of images. Our indicators computing does not require flap segmentation.

Note that although calcifications only appear in true lumens; we do not take into account such a case because they are not systematic in each dissection.

Results

Our processing method is constituted of the two following steps: the first one is the classical fast marching method to delineate the volume of interest around the aorta (Tab. 1(a)); the second one is our adapted fast marching method which allows us to obtain the two separated lumens (Tab. 1(b)). In Tab. 1(c) and (d) are given indicators values.

In these three images, we have the highest intensities values of *ind1* for the true lumens, with a mean intensity of 219 for a true lumen, 145 for the false one and 74 for the deviation. We have the lowest values of *ind2* for the true lumen with a mean value of 0.627 for a true lumen, 0.753 for the false one and 0.126 for the mean deviation. In Tab. 1(f) are given the 3D reconstruction of the final results, in blue is rendered the true lumen and in red is rendered the false lumen.

Conclusion

Due to our segmentation of the two lumens separately, it was relatively easy to propose two indicators to distinguish lumens. Our future works consists in testing our indicators in a larger dataset and also taking into account specific collateral arteries birth. This study will also assist clinicians during endoprosthesis landing by a registration of this distinction onto angiographic sequences.

References

- [1] Fetnaci N, Łubniewski P, Miguel B, Lohou C (2013) 3D segmentation of the true and false lumens on CT aortic dissection images. SPIE Electronic Imaging.
- [2] Erbel R, Alfonso F, Boileau C, Dirsch O, Eber B, Haverich A, Rakowski H, Struyven J, Radegran K, Sechtem U, Taylor J, Zollikofer, C (2001) Diagnosis and management of aortic dissection. *European Heart Journal* 22, 1642–1681.
- [3] Jaynes, E.T (1986) Bayesian Methods: General Background. An introductory tutorial. In *Proceedings of Maximum entropy and Bayesian Methods in Applied Statistics*, 1-25.
- [4] Kovács T, Cattin P, Alkhadi H, Wildermuth S, Székely G (2006) Automatic segmentation of the Vessel Lumen from 3D CTA Images of Aortic Dissection. In *Proceedings of Bildverarbeitung für die Medizin*, 161-165.
- [5] Center for Aortic Diseases, “Aortic dissection”, The University of Chicago Medicine. <http://www.ucaorta.org/aortic-dissection.html>.

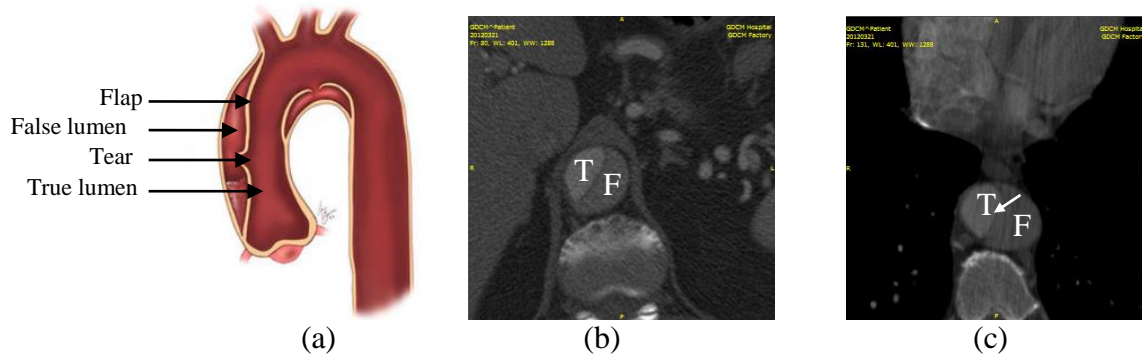














Fig. 1. (a) Schematic representation of an aortic dissection [5], (b) 2D grayscale slice without tear, (c) 2D grayscale slice with one tear (white arrow); T means true lumen, F means false lumen.

Aorta volume rendering	Lumens volume rendering	Ind1	Ind2	Decision	3D reconstruction with the marching cubes algorithm
 Patient 1		236	0.643	True	
		138	0.778	False	
 Patient 2		220	0.599	True	
		142	0.801	False	
 Patient 3		200	0.632	True	
		154	0.681	False	
(a)	(b)	(c)	(d)	(e)	(f)

Tab. 1. Segmentation results and indicator values for our CT aortic dissection images.