



HAL
open science

Treatment of gastric eosinophilia by epicutaneous immunotherapy in piglets sensitized to peanuts

L. Mondoulet, N. Kalach, V. Dhelft, Thibaut Larcher, C. Delayre-Orthez, P. H. Benhamou, J. Spergel, H. A. Sampson, Celine Dupont

► **To cite this version:**

L. Mondoulet, N. Kalach, V. Dhelft, Thibaut Larcher, C. Delayre-Orthez, et al.. Treatment of gastric eosinophilia by epicutaneous immunotherapy in piglets sensitized to peanuts. *Clinical and Experimental Allergy*, 2017, 47 (12), pp.1640-1647. 10.1111/cea.13037 . hal-01701597

HAL Id: hal-01701597

<https://hal.science/hal-01701597v1>

Submitted on 27 May 2020

HAL is a multi-disciplinary open access archive for the deposit and dissemination of scientific research documents, whether they are published or not. The documents may come from teaching and research institutions in France or abroad, or from public or private research centers.

L'archive ouverte pluridisciplinaire **HAL**, est destinée au dépôt et à la diffusion de documents scientifiques de niveau recherche, publiés ou non, émanant des établissements d'enseignement et de recherche français ou étrangers, des laboratoires publics ou privés.




Distributed under a Creative Commons Attribution - NonCommercial - NoDerivatives 4.0 International License

ORIGINAL ARTICLE

Experimental Models of Allergic Disease

Treatment of gastric eosinophilia by epicutaneous immunotherapy in piglets sensitized to peanuts

L. Mondoulet¹  | N. Kalach² | V. Dhelft¹ | T. Larcher³ | C. Delayre-Orthez⁴ | P. H. Benhamou¹ | J. Spergel⁵ | H. A. Sampson⁶ | C. Dupont⁷¹DBV Technologies, Montrouge, France²Hôpital Saint Vincent de Paul, GHICL, Lille, France³APEX, INRA, Nantes, France⁴Institut Polytechnique UniLaSalle, Beauvais, France⁵Children Hospital of Philadelphia, Philadelphia, PA, USA⁶DBV Technologies, New York, NY, USA⁷Hôpital Necker, Université Paris-Descartes, Paris, France

Correspondence

Lucie Mondoulet, DBV Technologies, Montrouge, France.

Email: lucie.mondoulet@dbv-technologies.com

Funding information

DBV Technologies

Summary

Background: Eosinophilic gastrointestinal disorders (EGIDs) are hypersensitivity disorders frequently triggered by food allergy and manifested by mucosal eosinophilic infiltration at any level of the gastrointestinal tract. This study established a model of gastric eosinophilia in peanut-sensitized piglets to evaluate the efficacy of epicutaneous immunotherapy (EPIT) for its treatment.

Methods: Experiments were carried out in piglets first sensitized by three intraperitoneal injections of peanut protein extract (PPE) with adjuvant, and then given PPE orally for 10 days, a sequence leading to gastric eosinophilia assessed by endoscopy. For 3 months, eight piglets received active EPIT, using Viaskin[®] loaded with PPE, applied daily on the ear, while eight received placebo EPIT (Placebo). Piglets were exposed to a second 10-day period of PPE orally. Lesions were scored by endoscopy on the last day of PPE exposure. After killing, all parts of the digestive tract were analysed by a pathologist unaware of the piglets' status. IgE response was measured, and mechanistic parameters were analysed in the spleen.

Results: After sensitization, a significant increase of total IgE was observed in sensitized compared to naive animals (61.1 ± 13.3 vs 27.8 ± 6 ng/mL, $P < .01$). Following oral intake of PPE, sensitized piglets developed moderate gastritis compared to naive piglets (1.5 vs 1.0, median score). After 3 months of immunotherapy, median IgE was significantly reduced in EPIT vs placebo piglets (61.4 ± 16.3 vs 105.9 ± 25.6 ng/mL, $P < .01$). Active EPIT significantly reduced gastric mucosal lesions induced by PPE oral intake (macroscopic score 0 [0-2] vs 2 [1-3], $P < .01$, respectively, active vs placebo) and gastric mucosa eosinophils counts (239 eosinophils/mm² [59-645] vs 2554 eosinophils/mm² [462-8057], $P < .01$, respectively active vs placebo). GATA-3, IL-5 and eotaxin mRNA expression decreased significantly after EPIT ($P < .05$).

Conclusions: This study describes a large animal model of gastric eosinophil in peanut-sensitized piglets. Utilizing this model, we demonstrated the efficacy of EPIT in treating peanut-induced EGIDs.

KEYWORDS

animal models, eosinophils, epicutaneous, EGIDs, food allergy, gastritis, immunotherapy

1 | INTRODUCTION

Eosinophilic gastrointestinal disorders (EGIDs) are an expanding entity of food hypersensitivities and constitute a diverse group of disorders with increased eosinophil counts in one or more parts of the gastrointestinal tract.¹ Eosinophilic oesophagitis (EoE) is the most common form of EGIDs in humans, with symptoms related to eosinophil-predominant mucosal inflammation and oesophageal dysfunction.² Recommendations in diagnostics, genetics, allergy testing, therapeutics and disease complications have been published by various work groups.²⁻⁴ Patients have high rates of concurrent food sensitivities,⁵ and it has been recently reported by Hill et al that 68% of EoE patients have IgE-mediated food allergy.⁶ Elimination diet/ amino-acid feedings are one of the mainstays of treatment in young children.⁷ Diagnostic criteria for other EGIDs, including eosinophilic gastritis, are less well defined, but Caldwell et al⁸ and Cianferoni and Spergel⁷ have proposed fundamental clinical and molecular parameters of patients with eosinophilic gastritis, such as eosinophil-predominant inflammation of the stomach, a conserved transcriptome and increased number of mast cells and Foxp3⁺ leucocytes in the gastric mucosa, potentially useful as biomarkers for diagnostic criteria. Based on the fact that EGIDs are mainly food-mediated diseases and on the recent clinical data showing the efficacy of epicutaneous immunotherapy (EPIT) in peanut allergic children,⁹ we have decided to investigate the impact of EPIT on EGIDs.

First, to address the treatment of EoE and more largely EGIDs, we developed a mouse model of esophago-gastro-enteropathy by sensitizing mice to peanut proteins and then feeding extensively with peanuts. By treating them just before the peanut oral feeding, we showed that EPIT protected previously peanut-sensitized mice from the eosinophilic mucosal infiltration seen in mice fed peanut

compared to untreated mice.¹⁰ Because endoscopy to assess the digestive damages before EPIT was not feasible in mice, we decided to work on a larger animal model rendering possible this kind of investigation and thus better mimic the management of EGIDs in clinical practice. An experimental model was developed in piglets following a sensitization/provocation procedure similar to the protocol developed in mice.¹⁰ This protocol resulted in severe inflammation in the stomach observed by endoscopy, with the absence of involvement of the oesophagus, allowing for the testing of EPIT in the treatment of gastric eosinophilia (GE).

2 | METHODS

2.1 | Design of the study

Twenty-four piglets (LW*LR)*P (16 females and 8 males), 13 days old at the beginning of the experiment, were obtained from regional farmers and transferred to a research facility for animal experiments (Institut UniLaSalle, Beauvais, France). All procedures complied with the European Community rules on animal care and authorization (B36344-2012) from the animal protocol review committee (Ethical Committee Institut Polytechnique Lasalle Beauvais, CEEA-116) and from the French Veterinary Services. The standard food given for the study duration did not contain any trace of peanut protein (manufacturer's claims and internal ELISA kit; Indoor Biotechnologies Cardiff, UK). Animals were acclimated one week prior to starting the experiment. In the first phase of the experiment (sensitization period), four animals were housed per box (until 30 kg), whereas in the second phase (immunotherapy period), animals were housed in individual boxes.

As presented in Figure 1, sixteen piglets were sensitized using PPE (100 µg/piglet) mixed to aluminium hydroxide (alum, 8 mg/piglet),

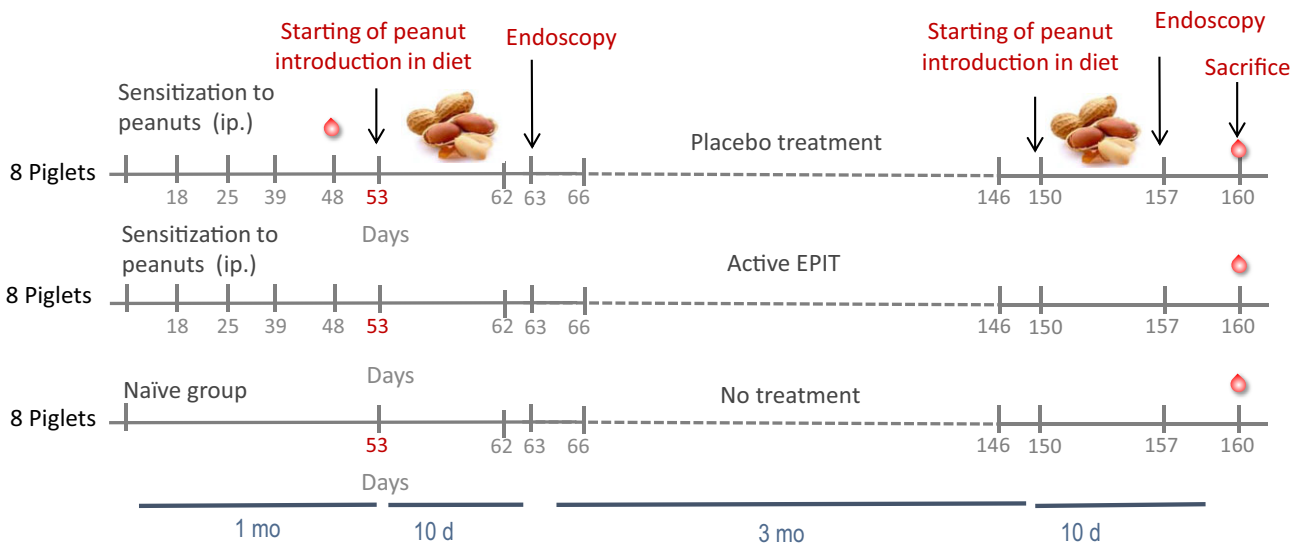


FIGURE 1 Study design. Eighteen piglets are sensitized to peanut protein extract (PPE) by 3 intra-peritoneal (ip) injections at 1-week interval each and eight naïve animals are also included in the study. PPE introduction into the diet is started at day 53 for 10 consecutive days and then endoscopy is performed to assess injuries in the upper digestive tract (from oesophagus until stomach). Epicutaneous immunotherapy (EPIT) is performed for 3 mo by applying active ($n = 8$) or placebo ($n = 8$) patches daily and renewed every 24 h. At the end of EPIT, animals are all exposed to the PPE diet daily. Endoscopy is performed at day 157 and killed at day 160

administered intra-peritoneally at days of age 18, 25 and 39. A blood sample was obtained at day 48 to measure total serum (s)IgE levels. From days 53 to 62, sensitized piglets received once per day 5 mL of an oil formula containing 4 mg of PPE. At day 63, an endoscopy evaluated the inflammation induced from oesophagus to stomach. Immediately following this period of oral PPE exposure, sensitized animals were separated in two arms for treatment with EPIT, active (EPIT, $n = 8$) or not (placebo, $n = 8$). Viaskin[®] patches were applied in the outer part of ear and maintained using an adhesive dressing (Tegaderm[®]; 3M, Saint-Paul, Minnesota, USA), for 24 hours and changed daily. Sites of application rotated between the left and right ear. EPIT was continued for 3 consecutive months (day 66 to day 146). Animals were then re-exposed to the same PPE formula (day 150 to day 159), and the oesophagus and stomach were re-evaluated endoscopically.

Eight naive animals (controls) followed the same scheme, with intra-peritoneal injection of alum buffer and oral challenge with the oily matrix devoid of PPE.

Three days before killing, a peanut atopy patch test (APT) was applied for 48 hours on the outer part of left ear of each piglet (EPIT, placebo, control), and skin samples taken after killing (ie, 24 hours after removal) and preserved in formol for HE staining. Animals were killed after overnight fast, at day 160, the day following the end of oral PPE exposure. Oesophagus, stomach, duodenum and jejunum were taken for histological analysis and mRNA expression of cytokines and transcription factors. Blood samples were taken every month during EPIT and at the end of PPE oral exposure to measure the evolution of IgE.

2.2 | Reagents

Peanut protein extract (lyophilized extract; Greer Laboratories, Lenoir, North Carolina, USA) was used for sensitization and immunotherapy. Commercial peanut oil (commercial organic food, France) was used for dilution of PPE to perform sustained food exposure. Viaskin[®] patches (DBV Technologies, Montrouge, France) were used for the immunotherapy treatment and contained PPE (100 μ g, active group, EPIT) or buffer formulation (no proteins, non-active group; Placebo).

2.3 | Endoscopy and biopsy samples histology

At days 63 and 157, animals fasted overnight were anesthetized by ip injection of ketamine (22 mg/kg) and + acepromazine (1.1 mg/kg). Oesophagus and stomach were examined by endoscopy, and biopsies were performed. All endoscopic procedures were performed by an endoscopist blinded to case/control status. Oesophagus and stomach were carefully evaluated, and lesions were scored: Grade 0: no lesion/Grade 1: slight gastritis/Grade 2: moderate gastritis/Grade 3: severe gastritis.¹¹

2.4 | Collection of tissues

Oesophagus, stomach, duodenum, jejunum and skin were fixed either in 4% neutral-buffered formalin or in liquid nitrogen and

prepared for analysis as previously described.¹⁰ Three sections of each tissue were analysed by a pathologist blinded to piglet treatment group. Eosinophilic inflammation was scored as follows: (i) rare spread of eosinophils; (ii) local increase of eosinophils density; (iii) diffuse increase with eosinophilic pseudo-abscess. Eosinophils were counted on haematoxylin-eosin-saffron stained sections by the pathologist, and results were expressed as number of eosinophils per mm^2 .

2.5 | Immune parameters

Spleen was sampled similarly for each animal, and the longitudinal central section was taken and cut into small pieces of 1 cm^2 each. Pieces of spleen were used for mRNA analysis. Total RNA from spleen was extracted using RNeasy Mini Kit (Qiagen, Courtaboeuf, France) as previously described.¹⁰ The pig primer sequences were previously described.¹² qPCR was performed using an ABI Prism 7300 sequence detector system (Applied Biosystems, Villebon-sur-Yvette, France) using SYBR-green fluorescence (Master Mix Quantifast Syber Green; Qiagen) for quantification. Results were presented as mRNA expression in the control, placebo and EPIT groups. Target gene expression was calculated relative to the expression of PPIA in each experimental sample, using the ΔCq method. Each set of quantitative PCR reactions were also run with negative controls without RNA and without RT.

Blood was collected following sensitization and after the treatment period. Sera were stored at -20°C until analyzed. IgE levels were determined by ELISA as described previously using a commercial kit and following the manufacturer's instructions (Porcine IgE ELISA kit; Bio-Medical Assay, Beijing, China).

2.6 | Statistical analysis

All statistical analyses were performed using the GraphPad Prism Software 6 (San Diego, CA, USA). Results are expressed as median \pm interquartile ranges. For histological analyses, mRNA expression and IgE responses, statistical differences were determined by Mann-Whitney test analyses.

3 | RESULTS

3.1 | Study adherence and clinical observations

Four piglets died before the end of the study but no death was directly related to the epicutaneous treatment. One sensitized animal died at 31 days (after sensitization but before peanut introduction in diet) due to piglet wasting disease. Two animals died at 63 days subsequently to anaesthesia and endoscopy. Those animals were randomized to placebo group. One EPIT animal died at 154 days due to a rectal prolapse, requiring subsequent euthanasia.

One naive and one sensitized piglets could not be evaluated during the first endoscopy due to anaesthesia and/or endoscopy issue.

We evaluated the weight of piglets over the treatment and peanut re-exposure phases. There were no differences in symptoms, feeding or behaviour (data not shown).

3.2 | Oral peanut exposure induces gastric lesions in peanut-sensitized piglets

Sensitized piglets developed severe gastric lesions after 10 days of oral PPE exposure (Figure 2). The score of macroscopic signs of inflammation in the stomach during endoscopy was significantly greater than in controls ($P < .01$).

3.3 | EPIT decreases gastric inflammation and gastric eosinophilia

Epicutaneous immunotherapy decreased the macroscopic signs of inflammation triggered in the stomach by PPE exposure ($P = .0729$, Figure 3A), in contrast to the severe lesions observed in the placebo-treated group, with ulcers present in 2/8 animals. Endoscopic analysis, as illustrated in Figure 3D-F, revealed less inflamed mucosa in the EPIT-treated group compared to the placebo group, with a nodular appearance suggesting the recovery of inflamed mucosa.

Epicutaneous immunotherapy also reduced the histologic score compared to the placebo treatment, respectively, 1.0 (median with 0 in 4 animals, 1 in 2 and 2 in 1) and 1.5 (1 in 1 animal, 2 in 2 and 3 in 2), $P < .01$ (Figure 3B). Following EPIT, eosinophilic infiltration was significantly decreased (median count: 129 eosinophils/mm², $P < .05$) compared to placebo (1109 eosinophils/mm², $P < .05$), similar to that of controls (305 eosinophils/mm²) (Figure 3C).

3.4 | EPIT improves immunological parameters

Sensitization of the two groups of piglets was associated with an increase in total IgE ($P < .001$ vs control) (Figure 4). Following EPIT

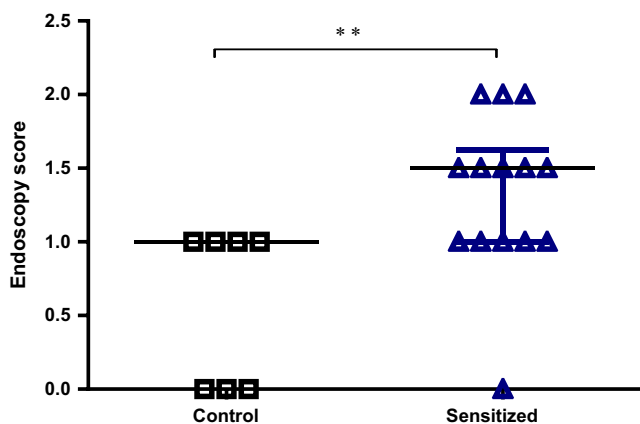


FIGURE 2 Score determined by endoscopy at day 63 (after sensitization and peanut protein extract PPE enriched regimen) upon Delvaux et al,¹¹ $**P < .01$ ($n = 21$ animals, 7 controls and 14 sensitized). Grade 0: no lesion/ Grade 1: slight gastritis/Grade 2: moderate gastritis/Grade 3: severe gastritis

and oral exposure to PPE, total IgE was significantly lower than in placebo animals ($P < .05$).

The expression of transcription factors (GATA-3, Tbet and Foxp3) and Th2 cytokines/chemokines involved in the eosinophilic disorders (IL-5, IL-13 and eotaxin) was assessed in spleens (Figure 5). The relative expression of GATA-3 was increased in sensitized (placebo-treated group) compared to naive animals ($P < .05$). EPIT significantly decreased the expression of GATA-3 and FOXP3 compared to placebo (respectively, $P < .01$ and $P < .05$). Moreover, EPIT significantly decreased the expression of IL-5 and eotaxin compared to placebo (respectively, $P < .01$ and $.05$). There was no major modification for IL-13, probably due to the heterogeneity of response in the placebo group.

No change was observed in Tbet expression in spleen either during sensitization or the period of epicutaneous immunotherapy.

Unfortunately, quantification of gene expression from the majority of samples obtained from the oesophagus, stomach, duodenum and jejunum could not be determined satisfactorily and in a viable manner, as gene expression was below the level of detection of the PCR device.

3.5 | Management of skin inflammation after APT by EPIT

Skin samples obtained after PPE APT exhibited a greater infiltration of eosinophils in placebo-treated animals compared to controls (108 vs 27 eosinophils/mm², $P < .01$), as a proof of skin immune responses to the allergens (Figure 6). EPIT significantly decreased this infiltration compared to placebo (37 eosinophils/mm², $P < .01$), showing a global effect of the desensitization procedure also on the skin.

4 | DISCUSSION

Herein we report both an original model of EGID, piglets sensitized to PPE exhibiting gastric eosinophilia following sustained oral exposure to peanut, and an original therapeutic approach in this disorder—EPIT.

For human eosinophilic gastrointestinal diseases (EGIDs), foods have been shown to be causative in both children and adults with eosinophilic oesophagitis (EoE). However, there is less evidence for foods causing eosinophilic gastroenteritis. One abstract by Gonsalves and one manuscript by Ko showed that the six-food elimination and elemental diets were successful to a similar degree when compared to EoE.^{13,14} Furthermore, there are three case reports of milk-induced eosinophilic gastroenteritis.¹⁵⁻¹⁷ Recently, Echeverria-Zudaire et al¹⁸ have described a case series of Spanish subjects that developed EGIDs during milk and/or egg OIT. In our piglet model, we have developed a peanut sensitive gastric eosinophilia to mimic food-induced EGIDs.

Previous studies have assessed the effects of food on the oesophagus and jejunum in sensitized mice.¹⁹⁻²¹ A human scale animal model was needed to test the feasibility of EPIT in humans. In

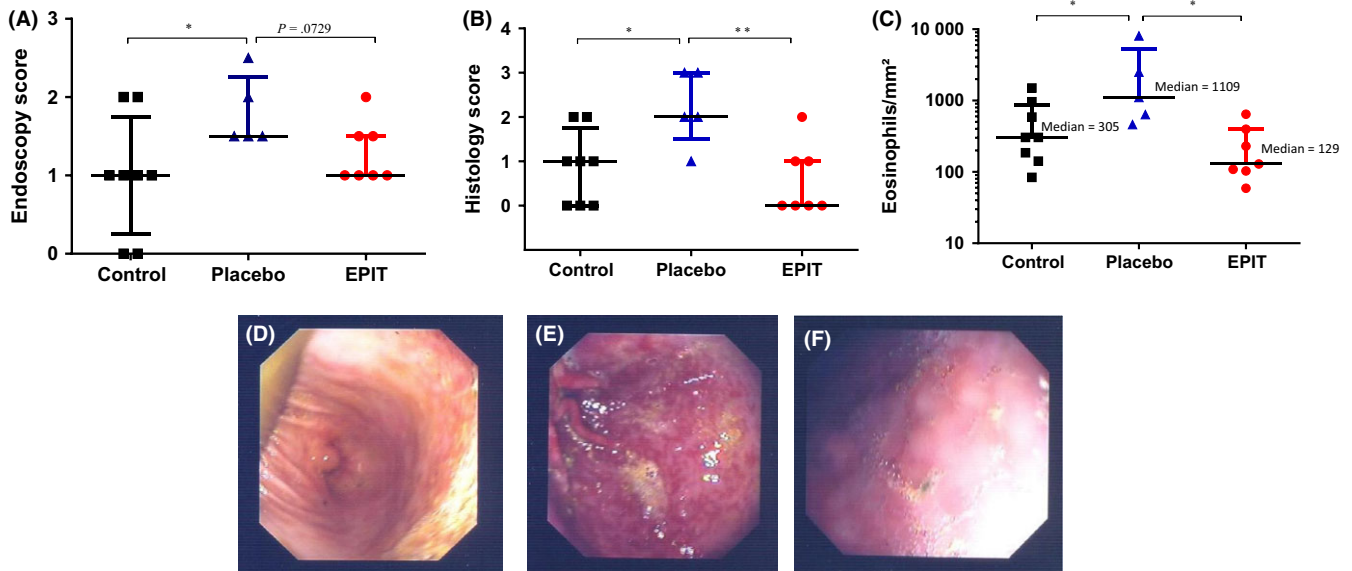


FIGURE 3 A, Endoscopy score, (B) Eosinophil score in stomach samples, (1: rare spread of eosinophils, 2: local increase in eosinophil density, 3: diffuse increase with eosinophilic micro-abscess), (C) counting of eosinophil infiltration by pathologist after HE staining. Endoscopy illustration for (D) control, (E) placebo and (F) epicutaneous immunotherapy (EPIT) treated groups. Individual data are plotted as the median value for each group. * $P < .05$ and ** $P < .01$ ($n = 8$ control, 5 placebo and 7 EPIT)

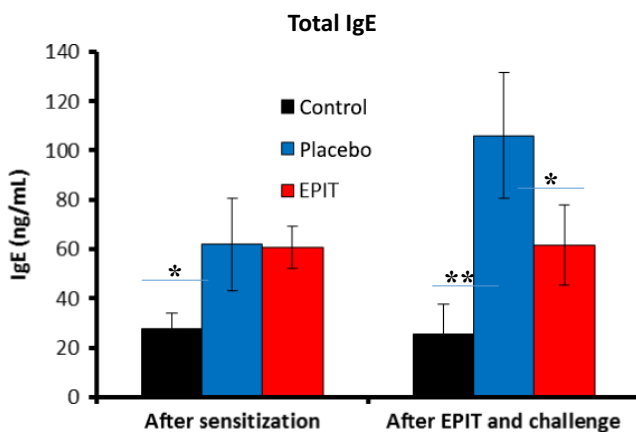


FIGURE 4 Immunological parameters: total serum IgE following sensitization, epicutaneous immunotherapy (EPIT), and allergen provocation measured in plasma. Data are expressed as the medians and interquartile ranges. * $P < .05$, ** $P < .01$ ($n = 8$ control, 5 placebo and 7 EPIT)

piglets, we can observe the exclusive location of eosinophil inflammation in one organ, the stomach, probably due to interspecies variation. Also of note, malpighian epithelium is observed in one region of piglet stomach similarly to oesophagus epithelium (in human and piglet). Piglets were the result of a crossbreeding, raised in the farm of a French stock breeder fattener. Individual variability of responses after sensitization procedure, peanut diet exposure and epicutaneous immunotherapy, might be due, at least in part, to genetic differences. The protocol of intra-peritoneal sensitization was optimized in a preliminary experiment (data not shown) based on published methods.²²⁻²⁴ And animals were maintained on a peanut-free diet to more closely mimic the elimination diet that is prescribed to EGID

patients.^{2,25} The allergen, mixed with peanut oil favouring the contact of peanut proteins to the digestive mucosa, was subsequently reintroduced at the end of the sensitization period to mimic the natural course in man. Although the extensive exposure to the matrix may induce slight gastritis in 50% of control animals, the reintroduction of allergen into the diet of sensitized animals resulted in a model of stomach injuries, observed and scored by endoscopy. Lesions were exclusively localized to the stomach, without any injuries or eosinophil infiltration observed in the oesophagus or the jejunum. A significant increase in total IgE was concomitantly observed in sensitized animals. Several assays were attempted to detect peanut-specific IgE by coating the ELISA plate with peanut and using the secondary antibody provided in total IgE kit or using an anti-human IgE. Unfortunately, high background levels prevented the reliable detection of peanut-specific IgE. However, despite the lack of measurement of specific IgE, it may be hypothesized that this increase reflected at least partially the peanut-specific IgE increase depicted in animal models of sensitization.^{10,26,27} RT-qPCR performed on spleen samples showed significantly higher mRNA levels of GATA-3, IL-5 and eotaxin, which are likely involved in the pathogenesis of eosinophilic gastritis.^{7,8} Indeed, Th2 cytokines and Foxp3⁺ cell numbers are characteristics of EG and may have value as diagnostic markers.⁸ Several studies indeed reported increased Foxp3⁺ cells (mainly Tregs but not only, as eosinophils express Foxp3⁺) in the biopsies of EoE patients.^{8,28,29} During active eosinophilic gastritis, Foxp3⁺ Tregs and as described recently Foxp3⁺ eosinophils may infiltrate the tissue to counterbalance the inflammation linked to T cell infiltrate.

Despite the severity of lesions induced by the PPE regimen, EPIT appeared efficacious, indicating that animals became less sensitive to PPE exposure, in agreement with our previous study in a mouse

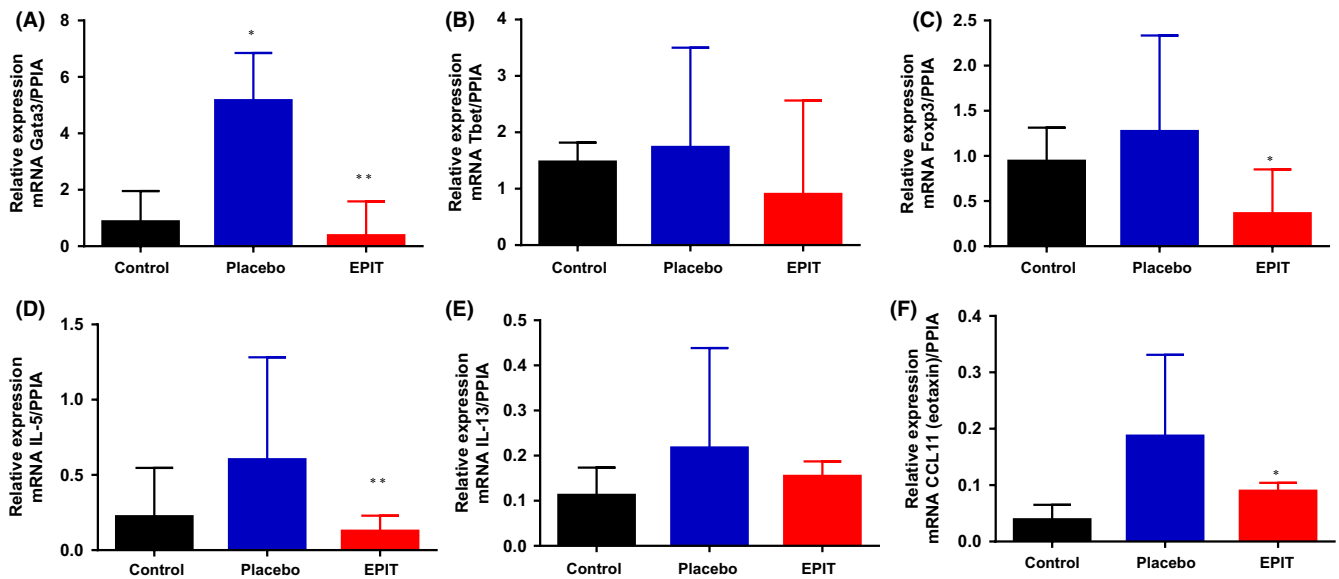


FIGURE 5 : Immunological parameters: measurement of (A) GATA-3, (B) Tbet, (C) FOXP3, (D) IL-5, (E) IL-13 and (F) eotaxin (CCL11) gene expression in splenocytes. Data are expressed as the medians and interquartile ranges. * $P < .05$, ** $P < .01$ ($n = 8$ control, 5 placebo and 7 epicutaneous immunotherapy)

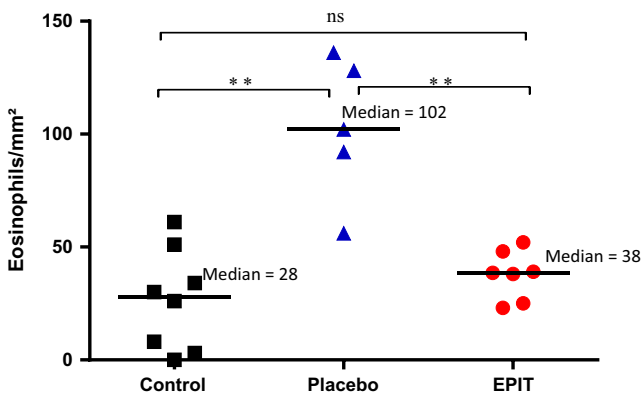


FIGURE 6 Eosinophil infiltration in skin after 48 h of peanut protein extract patch applications. Data are plotted individually and median indicated for each group, ** $P < .01$ ($n = 8$ control, 5 placebo and 7 epicutaneous immunotherapy)

model of eosinophilic oesophagitis.¹⁰ In the mouse model, EPIT prevented the eosinophilia and oesophageal inflammation after sustained oral exposure to peanut, whereas in the present study, EPIT appeared to reverse the lesions induced by the PPE regimen, as measured by all parameters. Further confirmation was observed by the decrease in mRNA expression of GATA-3, likely linked to the expression of Th2 cytokines, which participate in the pathogenesis of EGID. Interestingly, Foxp3 mRNA was significantly decreased by EPIT, indicating that either this transcript may be linked to Foxp3 + eosinophils (ie, less suppressive eosinophils are needed to counterbalance T cell infiltrate or their immunoregulatory function was restored) or lower Tregs were necessary to counteract the inflammatory process of eosinophilic gastritis.^{7,8} On the other hand, EPIT had no effect on the expression of Tbet mRNA, as already observed in our mouse model.^{10,26}

In contrast to our findings, Akei et al,³⁰ and Venturelli et al³¹ suggest that epicutaneous exposure to allergens could prime gastrointestinal injuries, especially EoE, via a Th2-dependant mechanism. This sensitization/desensitization role of the skin has been addressed in previous studies and seems particularly linked to the integrity of the superficial layer of the skin (ie, the stratum corneum).^{10,32} In the present study, total IgE (increased by the sensitization process) was reduced with EPIT at the end of immunotherapy. PPE-sensitized mice with eosinophilic esophago-gastro-enteropathy showed similar trends for specific IgE at the end of EPIT treatment. It is noteworthy that EPIT may be useful for the treatment of both IgE-mediated food allergy and EG, whereas sublingual or oral immunotherapy (SLIT and OIT) can be used only for IgE-mediated food allergy. Indeed, a recent paper compared the effectiveness of EPIT, OIT and SLIT in peanut-sensitized mice, clearly demonstrating differences in Treg phenotype after application of EPIT, SLIT and OIT.³³ Importantly, EPIT-induced Tregs display a broader chemokine receptor profile, shown by expression of CCR3 (oesophagus-homing) and CCR9 (gut-homing), illustrating their capacity to migrate to different sites and thus preventing/treating inflammatory responses. Adoptive Treg transfer confirmed that only EPIT-induced Tregs could prevent eosinophil infiltration in oesophagus.³³

As noted in clinical trials with our Viaskin peanut patch, skin redness occurred at the site of application during the first weeks of treatment. This cutaneous reaction was mild enough to allow application of another Viaskin peanut 24 hours later. It has been shown in clinical trials^{9,34} that during EPIT, skin reactivity, here mainly due to eosinophilic infiltration, progressively decreases, further underscoring the systemic desensitization effect of EPIT. Epicutaneous application of allergens through intact skin of sensitized animals leads to its transport via Langerhans cells to the draining lymph nodes³² and is likely to

promote a specific T regulatory cell response not only at the draining lymph node,³² but also at the systemic level, thus reaching the skin, the gut immune system and other organs.^{33,35} A similar decrease in eosinophilic inflammation on the skin after an APT was observed in our model of peanut-sensitized mice (unpublished data).

Eosinophilic oesophagitis is usually considered to be associated with 6 food allergens (especially milk, wheat, egg, and soy)^{7,36} and to be effectively treated with the dietary elimination of those foods in a majority of patients. Given the risk of severe dietary restriction, specific immunotherapies need to have a global effect on the pathogenesis of EGIDs and not affect a single allergen. Our recent studies in mice have shown that epicutaneous immunotherapy leads to Treg-dependent, long-term protection from oesophageal eosinophilia, and that this protection is not necessarily limited to the antigen administered in the epicutaneous immunotherapy.^{26,35,37} This bystander effect observed in mice could open a new pathway to manage EGIDs. Unfortunately, this potent Tregs mechanism of action could not be explored in piglets due to a lack of appropriate biological reagents to target/isolate Tregs. Moreover, we did not investigate whether adoptive transfer of Tregs into piglets sensitized to a different antigen (eg, milk) would confer protective and/or therapeutic effects.

In conclusion, we developed an original model of PPE exposure in piglets sensitized to PPE resulting in GE. This model was then used to assess the efficacy of EPIT, which desensitized peanut-sensitized piglets with severe eosinophilic inflammation in the stomach. This study may open the way to a specific immunotherapeutic approach in allergy-induced diseases, especially EGIDs. Further studies will be necessary to confirm that EPIT is an effective form of therapy.

CONFLICT OF INTEREST

This study was supported by DBV Technologies, the developer and owner of Viaskin[®]. Pierre-Henri Benhamou is the Chief Executive Officer of DBV Technologies. Véronique Dhelft and Lucie Mondoulet are DBV Technologies employees (part time or full time). Hugh Sampson had no conflict of interest with the company when the study was designed and conducted. Christophe Dupont, Jonathan Spergel, Thibaut Larcher, Nicolas Kalach and Carine Delayre-Orthez received honoraria and/or compensation in regards to the study, as investigator, coordinator or expert, in relation to the time spent on the study.

ORCID

L. Mondoulet  <http://orcid.org/0000-0003-0110-0321>

REFERENCES

1. Rothenberg ME. Eosinophilic gastrointestinal disorders (EGID). *J Allergy Clin Immunol.* 2004;113:11-28.
2. Liacouras CA, Furuta GT, Hirano I, et al. Eosinophilic esophagitis: updated consensus recommendations for children and adults. *J Allergy Clin Immunol.* 2011;128:3-20.
3. Furuta GT, Liacouras CA, Collins MH, et al. Eosinophilic esophagitis in children and adults: a systematic review and consensus recommendations for diagnosis and treatment. *Gastroenterology.* 2007;133:1342-1363.
4. Furuta GT, Katzka DA. Eosinophilic esophagitis. *N Engl J Med.* 2015;373:1640-1648.
5. Simon D, Cianferoni A, Spergel JM, et al. Eosinophilic esophagitis is characterized by a non-IgE-mediated food hypersensitivity. *Allergy.* 2016;71:611-620.
6. Hill DA, Dudley JW, Spergel JM. The prevalence of eosinophilic esophagitis in pediatric patients with ige-mediated food allergy. *J Allergy Clin Immunol Pract.* 2017;5:369-375.
7. Cianferoni A, Spergel JM. From genetics to treatment of eosinophilic esophagitis. *Curr Opin Allergy Clin Immunol.* 2015;15:417-425.
8. Caldwell JM, Collins MH, Stucke EM, et al. Histological eosinophilic gastritis is a systemic disorder associated with blood and extra-gastric eosinophilia, Th2 immunity, and a unique gastric transcriptome. *J Allergy Clin Immunol.* 2014;134:1114-1124.
9. Jones SM, Sicherer SH, Burks AW, et al. Epicutaneous immunotherapy for the treatment of peanut allergy in children and young adults. *J Allergy Clin Immunol.* 2017;139:1242-1252.e9.
10. Mondoulet L, Dioszeghy V, Larcher T, et al. Epicutaneous immunotherapy (EPIT) blocks the allergic esophago-gastro-enteropathy induced by sustained oral exposure to peanuts in sensitized mice. *PLoS One.* 2012;7:e31967.
11. Delvaux M, Crespi M, Armengol-Miro JR, et al. Minimal standard terminology for digestive endoscopy: results of prospective testing and validation in the GASTER project. *Endoscopy.* 2000;32:345-355.
12. Yoshida T, Nomura T, Shinoda N, Kusama T, Kadowaki K-I, Sugiura K. Development of PCR primers for the detection of porcine DNA in feed using mtATP6 as the target sequence. *Shokuhin Eiseigaku Zasshi.* 2009;50:89-92.
13. Ko HM, Morotti RA, Yershov O, Chehade M. Eosinophilic gastritis in children, clinicopathological correlation, disease course, and response to therapy. *Am J Gastroenterol.* 2014;109:1277-1285.
14. Gonsalves N, Doerfler B, Yang GY, Hirano I. Prospective clinical trial of six food elimination diet or elemental diet in the treatment of adults with eosinophilic gastroenteritis. *Gastroenterology.* 2009;136:A280.
15. Suzuki S, Homma T, Kurokawa M, et al. Eosinophilic gastroenteritis due to cow's milk allergy presenting with acute pancreatitis. *Int Arch Allergy Immunol.* 2012;158(Suppl 1):75-82.
16. Rodríguez Jimenez B, Domínguez Ortega J, González García JM, Kindelan Recarte C. Eosinophilic gastroenteritis due to allergy to cow's milk. *J Investig Allergol Clin Immunol.* 2011;21:150-152.
17. Costa C, Pinto PI, Rios E, Costa C. Milk-sensitive eosinophilic gastroenteritis in a 2-month-old boy. *BMJ Case Rep.* 2015;2015:1-3.
18. Echeverría-Zudaire LÁ, Fernández-Fernández S, Rayo-Fernández A, Muñoz-Archidona C, Checa-Rodríguez R. Primary eosinophilic gastrointestinal disorders in children who have received food oral immunotherapy. *Allergol Immunopathol.* 2016;44:531-536.
19. Mishra A. Mechanism of eosinophilic esophagitis. *Immunol Allergy Clin North Am.* 2009;29:29-40, viii.
20. Mishra A, Wang M, Pemmaraju VR, et al. Esophageal remodeling develops as a consequence of tissue specific IL-5-induced eosinophilia. *Gastroenterology.* 2008;134:204-214.
21. Mishra A, Schlotman J, Wang M, Rothenberg ME. Critical role for adaptive T cell immunity in experimental eosinophilic esophagitis in mice. *J Leukoc Biol.* 2007;81:916-924.
22. Helm RM, Burks AW. Animal models of food allergy. *Curr Opin Allergy Clin Immunol.* 2002;2:541-546.

23. Rupa P, Schmied J, Wilkie BN. Porcine allergy and IgE. *Vet Immunol Immunopathol.* 2009;132:41-45.
24. Rupa P, Hamilton K, Cirinna M, Wilkie BN. A neonatal swine model of allergy induced by the major food allergen chicken ovomucoid (Gal d 1). *Int Arch Allergy Immunol.* 2008;146:11-18.
25. Liacouras CA. Clinical presentation and treatment of pediatric patients with eosinophilic esophagitis. *Gastroenterol Hepatol.* 2011;7:264-267.
26. Mondoulet L, Dioszeghy V, Vanoirbeek JA, Nemery B, Dupont C, Benhamou P-H. Epicutaneous immunotherapy using a new epicutaneous delivery system in mice sensitized to peanuts. *Int Arch Allergy Immunol.* 2011;154:299-309.
27. Mondoulet L, Dioszeghy V, Ligouis M, Dhelft V, Dupont C, Benhamou P-H. Epicutaneous immunotherapy on intact skin using a new delivery system in a murine model of allergy. *Clin Exp Allergy.* 2010;40:659-667.
28. Lingblom C, Andersson J, Andersson K, Wennerås C. Regulatory eosinophils suppress T cells partly through galectin-10. *J Immunol.* 2017;198:4672-4681.
29. Fuentebella J, Patel A, Nguyen T, et al. Increased number of regulatory T cells in children with eosinophilic esophagitis. *J Pediatr Gastroenterol Nutr.* 2010;51:283-289.
30. Akei HS, Brandt EB, Mishra A, et al. Epicutaneous aeroallergen exposure induces systemic TH2 immunity that predisposes to allergic nasal responses. *J Allergy Clin Immunol.* 2006;118:62-69.
31. Venturelli N, Lexmond WS, Ohsaki A, et al. Allergic skin sensitization promotes eosinophilic esophagitis through the IL-33-basophil axis in mice. *J Allergy Clin Immunol.* 2016;138:1367-1380.
32. Dioszeghy V, Mondoulet L, Dhelft V, et al. Epicutaneous immunotherapy results in rapid allergen uptake by dendritic cells through intact skin and downregulates the allergen-specific response in sensitized mice. *J Immunol.* 2011;190:5629-5637.
33. Dioszeghy V, Mondoulet L, Puteaux E, et al. Differences in phenotype, homing properties and suppressive activities of regulatory T cells induced by epicutaneous, oral or sublingual immunotherapy in mice sensitized to peanut. *Cell Mol Immunol.* 2016;13:1-13.
34. Jones SM, Agbotounou WK, Fleischer DM, et al. Safety of epicutaneous immunotherapy for the treatment of peanut allergy: a phase 1 study using the Viaskin patch. *J Allergy Clin Immunol.* 2016;137:1258-1261.e1-10.
35. Dioszeghy V, Mondoulet L, Dhelft V, et al. The regulatory T cells induction by epicutaneous immunotherapy is sustained and mediates long-term protection from eosinophilic disorders in peanut-sensitized mice. *Clin Exp Allergy.* 2014;44:867-881.
36. Shukla A, Mishra A, Venkateshaiah SU, Manohar M, Mahadevappa CP, Mishra A. Elements involved in promoting eosinophilic gastrointestinal disorders. *J Genet Syndr Gene Ther.* 2015;6:1-22.
37. Mondoulet L, Dioszeghy V, Puteaux E, et al. Specific epicutaneous immunotherapy prevents sensitization to new allergens in a murine model. *J Allergy Clin Immunol.* 2015;135:1546-1557.

How to cite this article: Mondoulet L, Kalach N, Dhelft V, et al. Treatment of gastric eosinophilia by epicutaneous immunotherapy in piglets sensitized to peanuts. *Clin Exp Allergy.* 2017;47:1640-1647. <https://doi.org/10.1111/cea.13037>