



**HAL**  
open science

## Tumor shape pulmonary mucormycosis associated with sinonasal aspergillosis in a diabetic patient

Sophie Point, Frédéric Gabriel, Hugues Begueret, Jacques Jougon, Fanny Lanternier, Frederic Grenouillet, Manal Abdel Fattah, Emilie Catherinot, Chantal Raherison, Elodie Blanchard

### ► To cite this version:

Sophie Point, Frédéric Gabriel, Hugues Begueret, Jacques Jougon, Fanny Lanternier, et al.. Tumor shape pulmonary mucormycosis associated with sinonasal aspergillosis in a diabetic patient. *Medical Mycology Case Reports*, 2018, 19, pp.13 - 17. 10.1016/j.mmcr.2017.08.001 . hal-01667759

HAL Id: hal-01667759

<https://hal.science/hal-01667759v1>


Submitted on 20 Aug 2024

**HAL** is a multi-disciplinary open access archive for the deposit and dissemination of scientific research documents, whether they are published or not. The documents may come from teaching and research institutions in France or abroad, or from public or private research centers.

L'archive ouverte pluridisciplinaire **HAL**, est destinée au dépôt et à la diffusion de documents scientifiques de niveau recherche, publiés ou non, émanant des établissements d'enseignement et de recherche français ou étrangers, des laboratoires publics ou privés.



Distributed under a Creative Commons Attribution - NonCommercial - NoDerivatives 4.0 International License



## Tumor shape pulmonary mucormycosis associated with sinonasal aspergillosis in a diabetic patient



Sophie Point<sup>a</sup>, Frédéric Gabriel<sup>b</sup>, Hugues Bégueret<sup>c</sup>, Jacques Jougon<sup>d</sup>, Fanny Lanternier<sup>e</sup>, Frédéric Grenouillet<sup>f</sup>, Manal Abdel Fattah<sup>g</sup>, Emilie Catherinot<sup>h</sup>, Chantal Raheison<sup>a,i</sup>, Elodie Blanchard<sup>a,\*</sup>

<sup>a</sup> Pneumology Department, Hôpital Haut-Lévêque, CHU de Bordeaux, avenue de Magellan, 33604 Pessac, France

<sup>b</sup> Parasitology and Mycology Department, Hôpital Pellegrin, CHU de Bordeaux, place Amélie Raba Léon 33000 Bordeaux, France

<sup>c</sup> Pathology Department, Hôpital Haut-Lévêque, CHU de Bordeaux, avenue de Magellan, 33604 Pessac, France

<sup>d</sup> Thoracic Surgery Department, Hôpital Haut-Lévêque, CHU de Bordeaux, avenue de Magellan, 33604 Pessac, France

<sup>e</sup> Infectious and Tropical Disease Department, Centre d'infectiologie Necker-Pasteur, 149 rue de Sèvres, 75015 Paris, France

<sup>f</sup> Parasitology and Mycology Department, CHRU Besançon, 2 boulevard Fleming, 25030 Besançon cedex, France

<sup>g</sup> Infectious and Tropical Disease Department, CHRU Nancy, rue du Morvan, 54511 Vandoeuvre-les-Nancy, France

<sup>h</sup> Pneumology Department, Hôpital Foch, 40 rue Worth, 92150 Suresnes, France

<sup>i</sup> INSERM U1219 Université de Bordeaux, 146 rue Leo Saignat, 33076 Bordeaux, France

### ARTICLE INFO

#### Keywords:

Pulmonary mucormycosis  
Sinusal aspergillosis  
Fungal infection  
Bronchial obstruction  
Diabetic ketoacidosis

### ABSTRACT

Mucormycosis is a rare and life-threatening fungal infection of the Mucorales order occurring mainly in immunosuppressed patients. The most common forms are rhinocerebral but pulmonary or disseminated forms may occur. We report the case of a 61-year-old patient in whom pulmonary mucormycosis was diagnosed during his first-ever episode of diabetic ketoacidosis. While receiving liposomal amphotericin B, a sinonasal aspergillosis due to *Aspergillus fumigatus* occurred. Evolution was slowly favorable under antifungal tritherapy by liposomal amphotericin B, posaconazole and caspofungin.

### 1. Introduction

Within the Mucorales, *Rhizopus* sp, *Mucor* sp. and *Lichtheimia* sp are the most frequent fungi involved in human mucormycosis. The main process of infection consists of inhalation of ubiquitous saprophytic spores. No inter-human contamination has been described to date. The main risk factors are severe chronic neutropenia, systemic corticotherapy, hematological malignancies, severe graft versus host disease (GVHD), bone marrow transplantation, diabetic ketoacidosis or uncontrolled diabetes, iron overload, prior exposure to voriconazole, severe renal insufficiency and protein-energy malnutrition [1].

While the disease occurs in 40% of cases in the rhino-orbital or cerebral form (mostly in diabetic patients), pulmonary presentations, primary cutaneous (mostly in premature infants), gastrointestinal and disseminated forms in severely immunosuppressed patients [2] have been described. The differential diagnosis with aspergillosis can be challenging but they are two different diseases that do not respond to the same treatment. Indeed, the Mucorales have a natural resistance to voriconazole which is the first-line treatment for aspergillosis [3].

### 2. Case

We report the case of a 61-year-old ex-smoker (10 pack-years). He was a retired automobile worker who had been exposed to asbestos. He had no major medical history. He was hospitalized on 06/24/2014: D0 (day 0) for his first-ever episode of diabetic ketoacidosis, after 3 weeks of polyuropolydipsic syndrome. Since he also had hemoptysis, a CT scan was performed and revealed bi-basal condensation and infiltration of the left main bronchus (Fig. 1).

Bronchoscopy at D7 showed granulation tissue in the left main bronchus which was sampled for pathologic analysis. Histopathologic examination realized out of the hospital center of Bordeaux revealed the presence of septate hyphae with narrow angles suggesting aspergillus infection. Treatment with voriconazole was therefore initiated at D10. The work-up did not reveal any primary or secondary immunodeficiency in particular no neutropenia, negative HIV status, no evidence of a neoplasia on the thoracoabdominal CT-scan. After D28, however, a new thoraco-abdomino-pelvic scan revealed complete atelectasis of the left lung with complete obstruction of the left main

Abbreviations: GVH, graft Versus Host disease; BAL, Bronchoalveolar Lavage; PCR, Polymerase Chain Reaction

\* Corresponding author.

E-mail address: [elodie.blanchard@chu-bordeaux.fr](mailto:elodie.blanchard@chu-bordeaux.fr) (E. Blanchard).

<https://doi.org/10.1016/j.mmcr.2017.08.001>

Received 30 June 2017; Received in revised form 31 July 2017; Accepted 16 August 2017

Available online 01 September 2017

2211-7539/ © 2017 The Author(s). Published by Elsevier B.V. on behalf of International Society for Human and Animal Mycology. This is an open access article under the CC BY-NC-ND license (<http://creativecommons.org/licenses/by-nc-nd/4.0/>).

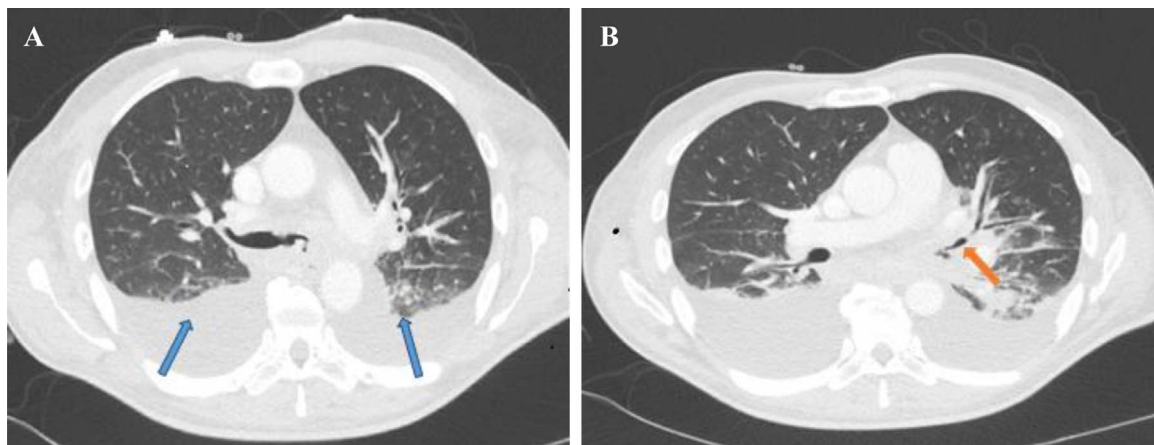


Fig. 1. Initial thoracic CT scan, axial section. A: bi-basal condensation (blue arrows). B: infiltration of left main bronchus (orange arrow).

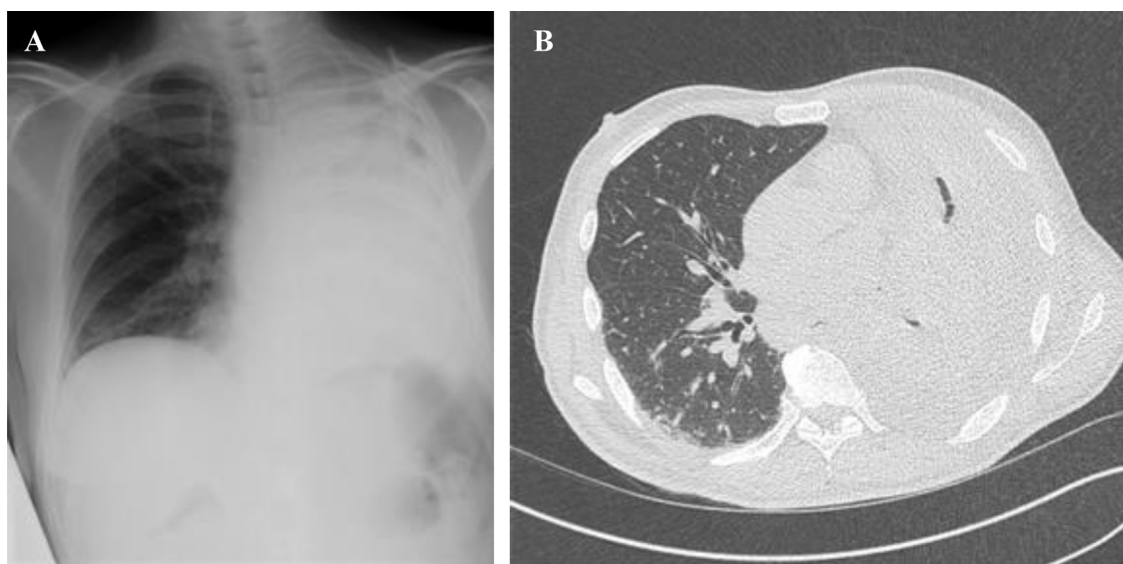


Fig. 2. A: Frontal Chest X-ray: left lung atelectasis and suspicion of pleural effusion. B: Axial section of thoracic CT scan: left lung atelectasis with obstruction of left main bronchus and left pleural effusion.

bronchus and left pleural effusion. There was no evidence of sinonasal, encephalic or abdominal infection (Fig. 2). Transthoracic echocardiography ruled out endocarditis.

The clinical worsening under voriconazole in the context of diabetes mellitus with ketoacidosis therefore suggested the diagnosis of pulmonary mucormycosis, which could be a differential diagnosis of aspergillosis.

A new endoscopy at D30 revealed a non-catheterisable left bronchial tree that was obstructed by granulation tissue. Histological analysis showed the presence of non-septate mycelial bodies suggestive of Mucorales hyphae (Fig. 3). Culturing of this histopathologic tissue didn't allow to isolate the pathogen. Galactomannan assay (Platelia® *Aspergillus* Ag Kit, Bio-Rad) on a bronchoalveolar lavage (BAL) was negative. Mycological cultures of BAL and pulmonary biopsy did not allow recovery of any mold isolate. Molecular diagnosis of Mucorales was performed, and showed positive quantitative polymerase chain reaction (qPCR) using hydrolysis probes targeting *Mucor/Rhizopus* species both on formalin-fixed paraffined embedded pedicle biopsy and

bronchial aspirate [4]. Nevertheless, this result sampled at D30 was obtained only later at D45. However, no circulating blood DNA was concomitantly detected by qPCR.

Liposomal amphotericin B 10 mg/kg/day was administered one month from the beginning of the treatment at D31, according to the opinion of the reference center.

The clinical evolution was favorable with rapid withdrawal of oxygen at D58 despite severe persistent malnutrition. A control endoscopy at D64 revealed an extension of the endobronchial lesions to the carina. A bronchoscopy to relieve obstruction was performed with insertion of a stent in the left main bronchus (Fig. 5). Thoracic surgery was discussed but proved impossible because the carina was invaded. The various biopsies performing during the endoscopies for the follow-up were negative.

The treatment was extended at D64 to liposomal amphotericin B 5 mg/kg (onset of renal failure with a creatinine clearance 25 mL/min), caspofungin and posaconazole.

Initially the patient has been treated for one month by intravenous

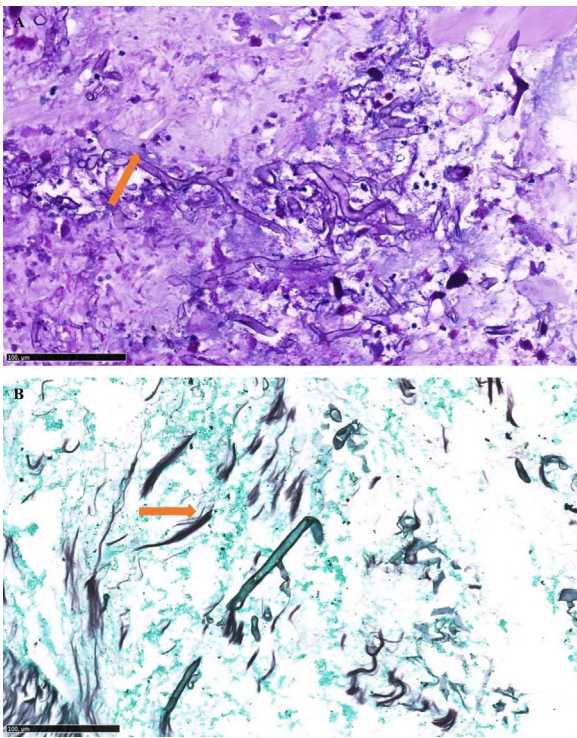


Fig. 3. A: Fragments of stained bronchial mucosa (PAS  $\times 140$ ): presence of non-septate hyphae (orange arrow), B: Fragments of stained bronchial mucosa (Gomori Grocott  $\times 170$ ): presence of non-septate hyphae (orange arrow).

liposomal amphotericin B at 10 mg/kg/day. The treatment was extended at D64 by oral posaconazole 400 mg twice daily and intravenous caspofungin 50 mg/day. So two months after the start of treatment with liposomal amphotericin B including one month of tri-therapy with caspofungin and posaconazole a sinus CT scan revealed filling of the left maxillary sinus suggesting fungal ball while the initial sinus CT scan was normal.

This diagnosis was evoked by histological examination at D85 which highlighted the presence of septate mycelial hyphae with narrow angles (Fig. 4) and confirmed by culture of the sinus sample which was positive and allowed the identification of an *Aspergillus fumigatus*. A meatotomy was performed.

According to the EORTC/MSG [5] this diabetic immunocompromised patient therefore had both proven pulmonary mucormycosis *Mucor/Rhizopus* species and *Aspergillus fumigatus* fungal ball on left maxillary sinus without bone or tissular invasion.

Unfortunately, *Aspergillus fumigatus* subculture didn't allow performing anti-fungal testing regarding amphotericin B susceptibility because the organism didn't grow in subculture.

The antifungal tri-therapy was discontinued after 1 year on account of the favorable clinical and radiological evolution and because qPCR for Mucorales in circulating blood and bronchial biopsies on subsequent bronchial endoscopies remained negative.

### 3. Discussion

We report the case of a 61-year-old patient suffering from fungal co-infection with proven mucormycosis and proven sinus aspergillosis in the setting of uncontrolled diabetes.

The diagnosis of infection with Mucorales should be considered

whenever there is clinical and/or endoscopic evidence of fungal infection, especially if the patient is diabetic or immunocompromised.

In this patient, both diseases coexisted with bronchopulmonary infection with a *Mucor/Rhizopus* species and aspergillosis sinus due to *Aspergillus fumigatus*. In a review of 929 cases of zygomycosis, the sinuses were the most common location (39% of cases), *Rhizopus* was the most frequently involved causal agent and proven or probable co-infection with *Aspergillus* sp. occurred in 44% of cases [6]. To date, only two cases to our knowledge involving mucormycosis and aspergillosis at the same time, namely the oropharyngeal sphere, has been reported. It was in a patient with Castleman's disease [7] and in a diabetic patient [8].

Pathologic analysis is mandatory in such cases. Microscopically, the Mucorales hyphae are not septate and are thicker than *Aspergillus* sp. hyphae. However, even when the hyphae are not septate, a pathologist's expertise may be necessary and multidisciplinary collaboration between pathologists and mycologists is indispensable [9–11]. Culture of biopsies is positive in only 50% of cases. This is especially the case for immunocompromised patients in whom bronchoalveolar lavage produces low culture yields, especially hematologic patients. [9] Importantly, there is a significant risk of environmental contamination during cultivation, so the mycology laboratory performing the procedure should be aware of this methodological pitfall and make sure that their culture techniques are totally aseptic. Furthermore, beta-D-glucan and galactomannan antigenemia are negative in mucormycosis. In our case, the 3 qPCR assays targeting *Mucor/Rhizopus*, *Lichtheimia* (formerly *Absidia*), and *Rhizomucor* were of great help in the diagnosis as previously described in several studies [4,12,13].

The differential diagnosis of mucormycosis and aspergillosis is important because their treatments are different [14]. As a first line, aspergillosis is treated with voriconazole while the Mucorales are naturally resistant to it [15]. Thus, in case of suspected fungal infection, an unfavorable evolution with voriconazole is a strong argument for mucormycosis. The Mucorales also show resistance *in vitro* to fluconazole and flucytosine while their sensitivity to itraconazole is variable. The most active agents *in vitro* are amphotericin B and posaconazole [14,16] so they are the treatment of choice.

Treatment should be continued for a minimum of twelve weeks but especially until all the clinical and radiological symptoms resolved and cultures have become negative. Immunity should also be strengthened as far as possible and risk factors such as diabetes and protein-energy malnutrition should be treated or kept under control [1]. Surgery should always be considered in the management of mucormycosis. In our patient the nature of the lesions invading the carina ruled out such initial management but surgical resection of necrotic tissue must be the discussed in case of localized disease. It allows systemic treatment to reach the infected areas isolated by vascular thrombotic events, and reduces the fungal burden [11,17].

Interestingly, the Mucorales infection in our patient occurred in a setting of a first-ever episode of diabetic ketoacidosis. Hyperglycemia, and particularly ketoacidosis, impairs the ability of neutrophils to destroy the Mucorales hyphae. Moreover, ketoacidosis increases the availability of free iron which is used as a growth factor by Mucorales [18,19]. Unfortunately, deferasirox, an iron chelator was associated with a higher mortality rate at 90 days in clinical trials [20,21].

In conclusion, the diagnosis of mucormycosis should be considered in an immunocompromised patient with either rhino-orbital or pulmonary involvement. Other pseudotumoral forms may also occur. It is essential to perform several biopsies in order to obtain a positive culture. Co-infections are common, as this case clearly demonstrates. Multidisciplinary collaboration between clinicians, pathologists, mycologists and a reference center is mandatory as early as possible to diagnose this disease, which carries a poor prognosis.

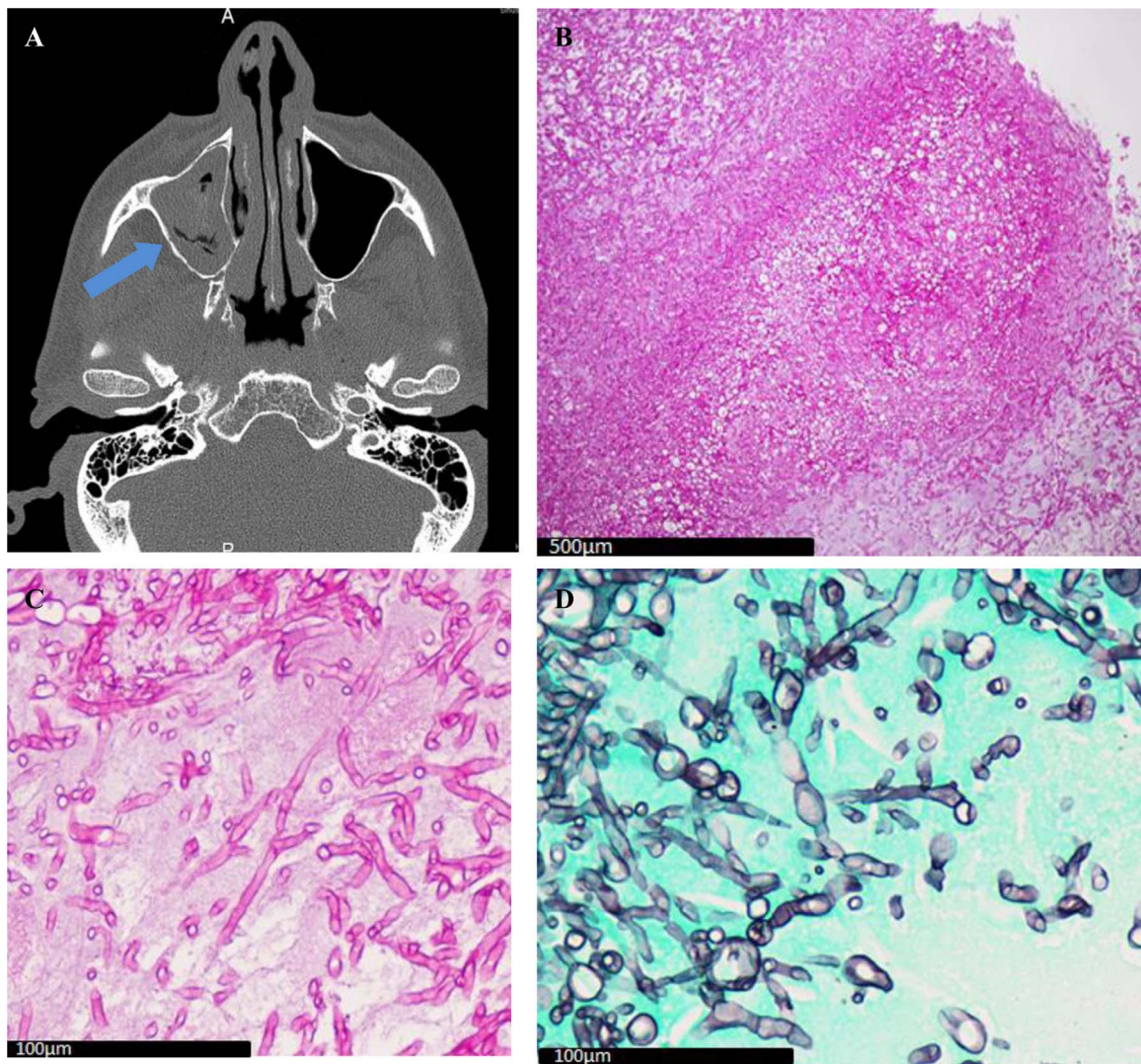


Fig. 4. A: Sinus CT axial section: Filling of left maxillary sinus (blue arrow); B: Sinus biopsy (PAS  $\times 10$ ): *Aspergillus* fungus ball; C: Sinus biopsy (PAS  $\times 60$ ): *Aspergillus* hyphae; D: Sinus biopsy (Gomori Grocott  $\times 60$ ): *Aspergillus* hyphae.

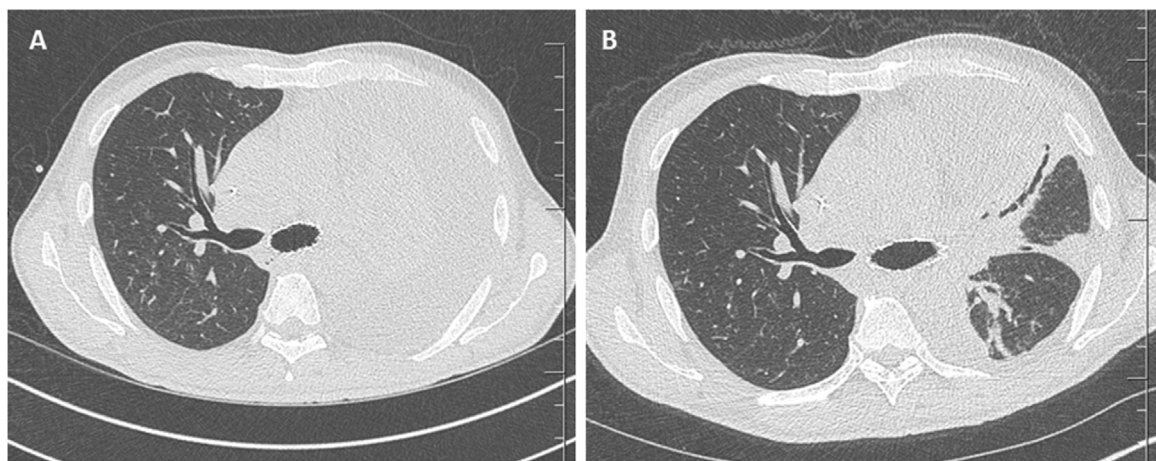


Fig. 5. A and B: CT images at one and two months of treatment, respectively.

## Acknowledgements

Thanks go to Dr. Minh Triet Ngo at the Suresnes Hospital and to Pr. Tunon de Lara, Dr. Dromer, Dr. Demant and Dr. Accoceberry for participating in the management of the patient. Thanks go to Dr. Claire Castain for providing the pathology images of the *Aspergillus fumigatus* fungal ball and to Dr. Clemence Pierry for providing images of the Mucorales hyphae and for reading the work. We also thank Ray Cooke for translating the manuscript.

## Conflict of interest

The authors have no disclosure to make.

This study did not receive any specific grant from funding agencies in the public, commercial or not-for-profit sectors.

## References

- [1] D.P. Kontoyiannis, R.E. Lewis, How I treat mucormycosis, *Blood* 118 (5) (2011) 1216–1224.
- [2] R.E. Lewis, D.P. Kontoyiannis, Epidemiology and treatment of mucormycosis, *Future Microbiol.* 8 (9) (2013) 1163–1175.
- [3] R.E. Lewis, O. Lortholary, B. Spellberg, E. Roilides, D.P. Kontoyiannis, T.J. Walsh, How does antifungal pharmacology differ for mucormycosis versus aspergillosis? *Clin. Infect. Dis.* 54 (Suppl 1) (2012) S67–S72.
- [4] L. Millon, F. Larosa, Q. Lepiller, F. Legrand, S. Rocchi, E. Daguindau, et al., Quantitative polymerase chain reaction detection of circulating DNA in serum for early diagnosis of mucormycosis in immunocompromised patients, *Clin. Infect. Dis. Publ. Infect. Dis. Soc. Am.* 56 (10) (2013) e95–e101.
- [5] B. De Pauw, T.J. Walsh, J.P. Donnelly, D.A. Stevens, J.E. Edwards, T. Calandra, et al., Revised definitions of invasive fungal disease from the European organization for research and treatment of cancer/invasive fungal infections Cooperative Group and the National Institute of allergy and infectious diseases Mycoses study Group (EORTC/MSG) Consensus Group, *Clin. Infect. Dis.* 46 (12) (2008) 1813–1821.
- [6] M.M. Roden, T.E. Zaoutis, W.L. Buchanan, T.A. Knudsen, T.A. Sarkisova, R.L. Schaufele, et al., Epidemiology and outcome of zygomycosis: a review of 929 reported cases, *Clin. Infect. Dis.* 41 (5) (2005) 634–653.
- [7] E. Maiorano, G. Favia, S. Capodiferro, M.T. Montagna, L. Lo Muzio, Combined mucormycosis and aspergillosis of the oro-sinonasal region in a patient affected by Castleman disease, *Virchows Arch.* 446 (1) (2005) 28–33.
- [8] W. Torres-Damas, D. Yumpo-Cárdenas, E. Mota-Anaya, Coinfection of rhinocerebral mucormycosis and sinus aspergillosis, *Rev. Peru. Med. Exp. Salud Publica* 32 (4) (2015) 813–817.
- [9] M.D.M. Luna, M.D.I. Warraich, M.D.X.Y. Han, Ph.D.G.S. May, M.D.D.P. Kontoyiannis, M.D.J.J. Tarrand, et al., Diagnosis of invasive septate mold infections: a correlation of microbiological culture and histologic or cytologic examination, *Am. J. Clin. Pathol.* 119 (6) (2003) 854–858.
- [10] T.J. Walsh, M.N. Gamaletsou, M.R. McGinnis, R.T. Hayden, D.P. Kontoyiannis, Early clinical and laboratory diagnosis of invasive pulmonary, extrapulmonary, and disseminated mucormycosis (zygomycosis), *Clin. Infect. Dis.* 54 (Suppl 1) (2012) S55–S60.
- [11] F.Y.W. Lee, S.B. Mossad, K.A. Adal, Pulmonary mucormycosis: the last 30 years, *Arch. Intern. Med.* 159 (12) (1999) 1301.
- [12] T. Boch, M. Reinwald, P. Postina, O.A. Cornely, J.J. Vehreschild, C.P. Heußel, et al., Identification of invasive fungal diseases in immunocompromised patients by combining an *Aspergillus* specific PCR with a multifungal DNA-microarray from primary clinical samples, *Mycoses* 58 (12) (2015) 735–745.
- [13] L. Millon, R. Herbrecht, F. Grenouillet, F. Morio, A. Alanio, V. Letscher-Bru, et al., Early diagnosis and monitoring of mucormycosis by detection of circulating DNA in serum: retrospective analysis of 44 cases collected through the French Surveillance Network of Invasive Fungal Infections (RESSIF), *Clin. Microbiol. Infect.* 22 (9) (2016) 810.e1–810.e8.
- [14] F. Tissot, S. Agrawal, L. Pagano, G. Petrikos, A.H. Groll, A. Skiada, et al., ECIL-6 guidelines for the treatment of invasive candidiasis, aspergillosis and mucormycosis in leukemia and hematopoietic stem cell transplant patients, *Haematologica* 102 (3) (2017) 433–444.
- [15] A.H. Limper, K.S. Knox, G.A. Sarosi, N.M. Ampel, J.E. Bennett, A. Catanzaro, et al., An official American thoracic society statement: treatment of fungal infections in adult pulmonary and critical care patients, *Am. J. Respir. Crit. Care Med.* 183 (1) (2011) 96–128.
- [16] Q.N. Sun, A.W. Fothergill, D.I. McCarthy, M.G. Rinaldi, J.R. Graybill, In vitro activities of posaconazole, itraconazole, voriconazole, amphotericin B, and fluconazole against 37 clinical isolates of zygomycetes, *Antimicrob. Agents Chemother.* 46 (5) (2002) 1581–1582.
- [17] M. Tedder, J.A. Spratt, M.P. Anstadt, S.S. Hegde, S.D. Tedder, J.E. Lowe, Pulmonary mucormycosis: results of medical and surgical therapy, *Ann. Thorac. Surg.* 57 (4) (1994) 1044–1050.
- [18] B. Rammaert, F. Lanternier, S. Poirée, R. Kania, O. Lortholary, Diabetes and mucormycosis: a complex interplay, *Diabetes Metab.* 38 (3) (2012) 193–204.
- [19] W.M. Artis, J.A. Fountain, H.K. Delcher, H.E. Jones, A mechanism of susceptibility to mucormycosis in diabetic ketoacidosis transferrin and iron availability, *Diabetes* 31 (12) (1982) 1109–1114.
- [20] A. Soummer, A. Mathonnet, O. Scatton, P.P. Massault, A. Paugam, V. Lemiale, et al., Failure of deferasirox, an iron chelator agent, combined with antifungals in a case of severe zygomycosis, *Antimicrob. Agents Chemother.* 52 (4) (2008) 1585–1586.
- [21] B. Spellberg, A.S. Ibrahim, P.V. Chin-Hong, D.P. Kontoyiannis, M.I. Morris, J.R. Perfect, et al., The Deferasirox-AmBisome Therapy for Mucormycosis (DEFEAT Mucor) study: a randomized, double-blinded, placebo-controlled trial, *J. Antimicrob. Chemother.* 67 (3) (2012) 715–722.