



**HAL**  
open science

## **Stereo-electroencephalography and surgical outcome in polymicrogyria-related epilepsy: A multicentric study**

Louis Maillard, Laura Tassi, Fabrice Bartolomei, H el ene Catenoux, Fran ois Dubeau, William Szurhaj, Philippe Kahane, Anca Nica, Petr Marusic, Ioana Mindruta, et al.

### ► To cite this version:

Louis Maillard, Laura Tassi, Fabrice Bartolomei, H el ene Catenoux, Fran ois Dubeau, et al.. Stereo-electroencephalography and surgical outcome in polymicrogyria-related epilepsy: A multicentric study. *Annals of Neurology*, 2017, 82 (5), pp.781-794. 10.1002/ana.25081 . hal-01661897

**HAL Id: hal-01661897**

**<https://hal.science/hal-01661897>**

Submitted on 31 Jan 2018

**HAL** is a multi-disciplinary open access archive for the deposit and dissemination of scientific research documents, whether they are published or not. The documents may come from teaching and research institutions in France or abroad, or from public or private research centers.

L'archive ouverte pluridisciplinaire **HAL**, est destin ee au d ep ot et  a la diffusion de documents scientifiques de niveau recherche, publi es ou non,  emanant des  tablissements d'enseignement et de recherche fran ais ou  trangers, des laboratoires publics ou priv es.

## **Stereo-electroencephalography and surgical outcome in polymicrogyria-related epilepsy: a multi-centric study**

**Louis Georges Maillard<sup>1-3</sup>, Laura Tassi<sup>4</sup>, Fabrice Bartolomei<sup>5-6</sup>, H el ene Catenoux<sup>7</sup>, Fran ois Dubeau<sup>8</sup>, William Szurhaj<sup>9-10</sup>, Philippe Kahane<sup>11-13</sup>, Anca Nica<sup>14-15</sup>, Petr Marusic<sup>16</sup>, Ioana Mindruta<sup>17-18</sup>, Francine Chassoux<sup>19</sup>, Georgia Ramantani<sup>1,20-21</sup>**

**Centre de Recherche en Automatique de Nancy (CRAN), University of Lorraine, CNRS, UMR 7039, Vandoeuvre, France<sup>1</sup>; Department of Neurology, Central University Hospital, CHU de Nancy, Nancy, France<sup>2</sup>; Medical Faculty, University of Lorraine, Nancy, France<sup>3</sup>; "Claudio Munari" Epilepsy Surgery Centre, Niguarda Hospital, Milan, Italy<sup>4</sup>; Aix Marseille Universit e, Institut de Neurosciences des Syst emes, Marseille, France<sup>5</sup>; AP-HM, H opital de la Timone, Service de Neurophysiologie Clinique, Marseille, France<sup>6</sup>; Functional Neurology and Epileptology Department, Pierre Wertheimer Neurological Hospital, Lyon, France<sup>7</sup>; Montreal Neurological Institute and Hospital, McGill University, Montreal, Qu ebec, Canada<sup>8</sup>; Epilepsy Unit, Lille University Medical Centre, Lille, France<sup>9</sup>; INSERM U1171, University of Lille, France<sup>10</sup>; Clinique de Neurologie, Centre Hospitalier Universitaire, Grenoble, France<sup>11</sup>; INSERM U1216, Grenoble Institut des Neurosciences, Grenoble, France<sup>12</sup>; University Grenoble Alpes, Grenoble, France<sup>13</sup>; Neurology Department, CHU, Rennes, France<sup>14</sup>; INSERM, U1099, Rennes, France<sup>15</sup>; Department of Neurology, 2nd Faculty of Medicine, Charles University, Motol University Hospital, Prague, Czech Republic<sup>16</sup>; Department of Neurology, University Emergency Hospital, Bucharest, Romania<sup>17</sup>; Department of Neurology, Carol Davila University of Medicine and Pharmacy, Bucharest, Romania<sup>18</sup>; Department of Neurosurgery, Sainte-Anne Hospital, Paris, France<sup>19</sup>; Child Neurology, University Children's Hospital, Zurich, Switzerland<sup>20</sup>; Swiss Epilepsy Center, Zurich, Switzerland<sup>21</sup>**

**Correspondence to:** Georgia Ramantani MD, Division of Child Neurology, University Children's Hospital Zurich, Steinwiesstrasse 75, CH-8032 Zurich, Switzerland; *phone:* +41 44 266 75 92; *fax:* +41 44 266 71 65; *e-mail:* georgia.ramantani@kispi.uzh.ch

**Running head:** SEEG and epilepsy surgery in PMG

**ABSTRACT**

*Objective:* We aimed to 1) assess the concordance between various PMG types and the associated epileptogenic zone (EZ), as defined by stereo-electroencephalography (SEEG), and 2) determine the postsurgical seizure outcome in PMG-related drug-resistant epilepsy.

*Methods:* We retrospectively analyzed 58 cases: 49 had SEEG and 39 corticectomy or hemispherotomy. *Results:* Mean age at SEEG or surgery was 28.3 years (range 2-50). PMG was bilateral in 9 (16%) patients and unilateral in 49, including 17 (29%) unilobar, 12 (21%) multilobar, 15 (26%) perisylvian, and only 5 (9%) hemispheric. Twenty-eight (48%) patients additionally had schizencephaly, heterotopia or focal cortical dysplasia. The SEEG-determined EZ was fully concordant with the PMG in only 8 (16%) cases, partially concordant in 74% and discordant in 10%. The EZ included remote cortical areas in 21 (43%) cases and was primarily localized in those in 5 (10%), all related to the mesial temporal structures. All but one PMG patients with corticectomy or hemispherotomy had a unilateral PMG. At last follow-up (mean 4.6 years, range 1-16), 28 (72%) patients remained seizure free. Shorter epilepsy duration to surgery was an independent predictor of seizure freedom. *Interpretation:* PMG-related drug-resistant epilepsy warrants a comprehensive presurgical evaluation, including SEEG investigations in most cases, since the EZ may only partially overlap with the PMG or include solely remote cortical areas. Seizure freedom is feasible in a large proportion of patients. PMG extent should not deter from exploring the possibility of epilepsy surgery. Our data support the early consideration of epilepsy surgery in this patient group.

**Keywords:** drug-resistant epilepsy, cortical malformations, epilepsy surgery, seizure outcome, stereo-electroencephalography.

## INTRODUCTION

Polymicrogyria (PMG) is one of the most common malformations of cortical development (MCD), accounting for ca. 20% of all MCDs<sup>1</sup>. PMG can occur together with other brain abnormalities, such as schizencephaly (SCZ), periventricular and subcortical heterotopia, hippocampal malformation, focal cortical dysplasia (FCD), and hemimegalencephaly<sup>2-4</sup>. The main PMG patterns described in the largest series to date<sup>3</sup> are perisylvian (61%), generalized (13%), frontal (5%) and parasagittal parieto-occipital (3%). The most common features attributable to the PMG are epilepsy (78-87%), developmental delay (70%), and motor deficits (51%)<sup>5-7</sup>.

In spite of the high rate of drug-resistant epilepsy among PMG patients<sup>3,8,9</sup>, only few studies have focused on anatomico-electro-clinical correlations and postsurgical outcomes. Two recent studies deriving from intracranial, mainly stereo-electroencephalography (SEEG) recordings in only 4 PMG patients each, addressed the correlations between the electro-clinical findings, the epileptogenic zone (EZ) and the topography of the PMG<sup>10,11</sup>. They found that: 1) the EZ may include only part of the PMG and often extend to remote cortical areas, 2) both epileptogenic and eloquent cortex may co-exist within the PMG, and 3) in well-selected cases, a focal resection may result in a favorable seizure outcome, even in cases of a malformation extending over several lobes. Nevertheless, epilepsy surgery in PMG has been rarely considered and results have been heterogeneous, ranging from 33% to 78% postsurgical seizure freedom in retrospective mono-centric studies<sup>9-14</sup>. The most recent of these studies<sup>13</sup> showed a higher rate of seizure freedom in the operated group compared to a medical treatment group, suggesting that, in a subset of selected patients with PMG-related epilepsy, surgery may represent an efficient therapeutic option.

These studies, however, did not address the following two key questions in the context of these complex and often widespread malformations and seizure generators, (1) in which patients would SEEG be indicated and useful, and (2) which patients are appropriate candidates for surgery. To address these two questions, we initiated a retrospective multi-centric study, enrolling 58 patients with PMG-related drug-resistant epilepsy that underwent SEEG or surgery.

The primary purpose of our study was to assess the concordance between the PMG and associated EZ. The secondary purpose was to analyze the overall seizure outcome following surgery for PMG-related drug-resistant epilepsy and, thus, to identify optimal surgical candidates.

## **METHODS**

### **Patient selection**

This is a retrospective multi-centric cohort study of patients with PMG-related drug-resistant focal epilepsy referred for presurgical evaluation. Eleven epilepsy surgery centers in Europe and North America agreed to collaborate sharing clinical, SEEG and postsurgical seizure outcome data. Inclusion criteria were: 1) PMG-related drug-resistant epilepsy, 2) SEEG investigating the PMG and remote cortex, and/or 3) corticectomy or hemispherotomy with > 1 year of follow-up. The presurgical evaluations and/or surgical treatments were performed from 1999 to 2014. Seven patients had been previously included in small case series on a similar topic<sup>1,2</sup>. Patients or their caretakers gave their informed consent for the diagnostic and therapeutic procedures herein described. This retrospective study of anonymous patient data was done according to the ethics and legal regulations of countries involved in the study coordination and data management (France) and from where data were collected. Wherever needed, patients or family provided written informed consent for the use of the clinical and SEEG data reported in this study.

### **Clinical data review**

The clinical records of all patients were reviewed for family history of epilepsy, ante-/perinatal history, neurologic deficit, assessment of cognitive functioning, age at epilepsy onset, age at invasive EEG or at surgery, seizure frequency and -type.

### **MRI findings**

Presurgical 1.5 or 3T MRI scans of all patients were evaluated as to 1) the PMG localization and extent, and 2) the presence of associated malformations, including SCZ, heterotopia, FCD, and hippocampal malformation.

### **PET findings**

FDG-PET scans, when available, were evaluated as to the presence of regional hypometabolism and classified according to their concordance 1) with the PMG, and 2) with the EZ.

### **SEEG findings**

Invasive EEG recordings with stereotactically implanted intracerebral electrodes (SEEG), with or without additional subdural electrodes, were performed 1) when non-invasive investigations failed to precisely delineate the EZ or 2) when an overlapping of the EZ with eloquent cortex was presumed. The EZ was defined as the cortical structures involved in the

initial ictal discharge at the onset of spontaneous typical seizures and whose electrical stimulation elicited these typical seizures, where applicable.

### **Concordance study**

We assessed the concordance between the MRI-defined PMG, the PET-delineated hypometabolism, the SEEG-determined EZ, and the surgical resection, when performed. In order to facilitate the comparison between different modalities, each localization was classified in one or several sublobar regions<sup>15</sup>. For each patient, the sublobar extent of the MRI-defined PMG and PET-delineated hypometabolism was then compared with the sublobar extent of the SEEG-determined EZ and classified according to their concordance as fully concordant (=), concordant, more extensive ( $\geq$ ), concordant, less extensive ( $\leq$ ), and discordant ( $\neq$ ).

### **Surgical procedures**

Epilepsy surgery included tailored focal or regional corticectomy and hemispherotomy, aimed at EZ-resection or -disconnection, respectively. Subtotal resection was intentionally undertaken when the EZ overlapped with functionally eloquent cortical areas, as verified by fusion with the pre-surgical fMRI, intracranial or intracerebral electrical stimulation studies and intraoperative evoked potentials, when applicable. Epilepsy substrates were ascertained by histopathology<sup>16</sup>.

Further procedures included SEEG-guided thermo-coagulation and callosotomy.

### **Postsurgical outcome**

Patients were followed at regular intervals after surgery and antiepileptic drugs (AEDs) adjusted according to seizure outcomes; these were categorized according to the Engel classification<sup>17</sup>.

### **Statistical analysis**

We assessed the relations between seizure outcome (Engel I vs. Engel II-IV) and clinical variables with possible predictive value (Table 3). Descriptive statistics were used for each variable. Univariate analysis was performed using the Mann Whitney U-test and the Fisher's Exact Test to identify potential predictive factors. Logistic regression analysis with backward elimination was performed for variables with  $p \leq 0.20$  in the univariate analysis: age at epilepsy onset, epilepsy duration, PMG lateralization, resection beyond the PMG. Kaplan–Meier survival analysis was used to determine the probability of seizure-freedom over time.

Statistical analysis was conducted using R version 3.1.2<sup>18</sup>.

## RESULTS

### *Clinical data*

Our cohort consisted of 58 patients with PMG-related drug-resistant epilepsy (Table 1). Forty-nine had SEEG (Fig. 1) and 39 (67%) underwent corticectomy or hemispherotomy (Fig. 2), 30 after SEEG. Most patients (47: 81%) had childhood epilepsy onset, with the majority (45: 78%) undergoing SEEG or epilepsy surgery in adulthood. Ten (17%) patients had a family history of epilepsy and 7 (12%) perinatal events, 11 (19%) a history of psychiatric disorder, 26 (45%) a cognitive impairment, and 17 (29%) a neurologic deficit. Median seizure frequency was 9 per month with 16 (28%) patients presenting daily seizures. Twenty-four patients (41%) had multiple seizure types including secondary generalized seizures in 18, drop attacks in 4 and epileptic spasms in 2.

### *MRI findings*

Most patients (49: 84%) had unilateral PMGs, more frequently right than left hemispheric (59% vs. 26%) (Table 1). Seventeen unilobar (9 temporal, 6 frontal, 1 parietal, 1 occipital), 12 multilobar and 15 perisylvian PMGs were encountered in our cohort, whereas hemispheric PMGs were less frequent with only 5 cases. Multilobar PMGs were all located in the posterior cortex (8 temporo-occipital, 3 temporo-parieto-occipital, 1 parieto-occipital). Bilateral PMG was perisylvian in 4 cases, multilobar in 3 (2 fronto-parietal, 1 parieto-occipital), and unilobar (frontal) in 2. Twenty-two (38%) patients had additional MRI-visible cortical malformations, including 3 with FCD; 3 had hippocampal sclerosis. None of the hemispheric PMG cases were suggestive of hemimegalencephaly.

### *Concordance of SEEG-defined EZ, FDG-PET and PMG*

#### **Epileptogenic zone concordance with PMG**

Forty-nine patients underwent invasive recordings with intracerebral electrodes, and additional subdural electrodes in 3 cases (Table 1, Fig. 1). Two illustrative cases of SEEG in perisylvian and multilobar PMG with partial involvement of the PMG in the EZ and additional involvement of remote cortical areas are presented in Figs. 3 & 4.

The PMG was fully concordant with the EZ in only 8 of 49 cases (16%) (Table 2). In the remaining 41 cases, SEEG provided crucial information regarding the location and extent of the EZ that involved 1) only part of the PMG in 29 out of 49 (60%) cases including, in 9

(18%), additional remote cortical areas, 2) the entire PMG and remote cortical areas in 7 (14%) cases, and 3) exclusively remote cortical areas in 5 (10%). In unilateral multilobar and perisylvian PMG as well as in bilateral PMG, the EZ involved only part of the structural malformation in 6 of 11, 12 of 15, and 6 of 9 cases respectively, thus enabling epilepsy surgery despite the extent of the malformation. Twelve of 21 cases with EZ involving remote cortical areas, related to the mesial temporal structures (MTS), with typical seizures elicited by electrical stimulation of the MTS in 8 of 12 cases. These included all 5 cases with EZ restricted to remote cortical areas. Although the PMG was extensively sampled in all SEEG investigations, habitual seizures were elicited by electrical stimulation of the PMG only in 6 cases.

In 17 of 49 cases, eloquent cortical functions within the PMG were established by electrical stimulation, precluding epilepsy surgery in 4 cases and restricting the resection extent in another case.

#### **FDG-PET concordance with PMG and EZ**

FDG-PET was performed in 31 of 49 patients explored with SEEG. Focal hypometabolism was observed in 28 cases, and classified as fully concordant with the PMG in 6 of 31 cases (21%), involving the full PMG and remote cortical areas in 7, involving only part of the PMG in 4, with remote cortical areas in 6, and fully discordant with the PMG in 5. Of note, the PMG was partially or fully normo-metabolic in 14 of 31 cases.

Focal hypometabolism was classified as fully concordant with the SEEG-determined EZ in 9 of 31 patients, fully discordant with the EZ in 4, involved an area that was larger than or remote from the EZ in 7, and smaller than the EZ in 8 cases. PET correctly pointed to the MTS in 6 cases with EZ involving additionally or exclusively remote cortical areas.

#### **Epilepsy surgery**

Following SEEG, 3 of 49 patients refused surgery and another one remained seizure-free and therefore did not proceed to surgery. Fifteen of 49 patients were excluded from corticectomy or hemispherotomy due to a risk of functional deficit in 7 or a bilateral EZ in 8. Of note, 7 of these 8 patients had a bilateral PMG.

Six patients underwent SEEG-guided thermo-coagulation: 2 promptly proceeded to corticectomy, whereas the remaining 4 were excluded from corticectomy or hemispherotomy due to an extensive SEEG-delineated EZ or functional considerations. Among them, 1 patient with a perisylvian EZ remained seizure-free (Engel I) after thermo-coagulation and



another one with bilateral PMG but unilateral EZ had rare ( $\leq 2$  per year) disabling seizures (Engel II). Of the remaining 2 patients that did not considerably profit from thermo-coagulation (Engel III/IV), one eventually underwent a callosotomy

Overall, 2 patients underwent a callosotomy following SEEG without worthwhile improvement (Engel IV).

Thirty-four patients underwent corticectomy, all but one with unilateral PMGs, including 29 patients with prior SEEG and 5 who proceeded directly to surgery based on non-invasive findings (Tables 1 & 3; Fig. 2). In addition, 5 patients underwent hemispherotomy including 1 patient with and 4 without prior SEEG. Similar proportions of unilobar (64%), multilobar (73%) and perisylvian (80%) patients evaluated by SEEG eventually proceeded to corticectomy or hemispherotomy that led to comparable rates of seizure freedom (66-75%: Table 2; Fig. 1). Most patients (35 of 41) had childhood onset, and the majority (27 of 41) suffered seizures for  $\geq 10$  years prior to surgery.

Nine patients proceeded directly to surgery: 1) 4 had a hemispheric PMG with concordant electro-clinical findings, contralateral hemiparesis and hemianopia and underwent hemispherotomy, 2) 2 had a multilobar or hemispheric PMG with concordant electro-clinical findings, contralateral hemianopia and underwent (temporo-)parieto-occipital resections, and 3) 3 had a small-sized frontal or temporal PMG with concordant electro-clinical findings, allowing for full PMG resection.

The PMG resection or disconnection was complete in 19 and partial in 17 cases. In 21 of 39 cases the resection involved remote cortical areas. This remote cortical resection was additional to a partial PMG resection in 6 and to a full PMG resection in 12 cases. Finally, the resection spared the PMG in 3 cases with SCZ and periventricular nodular heterotopia localized in the posterior cortex. In these 3 cases, the EZ was limited to the MTS, extending to the temporal pole in one.

Following surgery, 8 patients presented permanent novel neurologic deficits. Six patients had visual field deficits (5 hemianopia, 1 quadrantanopia). Two additional patients presented sensory-motor deficits in the upper limb after a parietal lobe resection that also included insular cortex. Another 2 patients presented with postsurgical transient memory deterioration or psychiatric aggravation.

Histopathology confirmed the presence of PMG in 29 of 39 cases, with evidence for

additional heterotopia in 2 and FCD in 12 cases. It should be noted that only 3 of 12 FCDs in our cohort had been detected in presurgical MRI.

### **Seizure Outcome**

The mean follow-up after corticectomy or hemispherotomy was 4.6 years (SD 3.5; range 1-16 years); 33 of 39 patients had  $\geq 2$  year follow-up. At last follow-up, 28 (72%) patients remained seizure free (Figs. 2 & 5A): 22 were completely seizure free since surgery (Engel Ia), 3 had only auras (Engel Ib), and 3 had generalized seizures after AED discontinuation only (Engel Id). Six (15%) patients had rare disabling seizures (Engel II), 4 (10%) had a worthwhile improvement (Engel III), and only one showed no worthwhile improvement (Engel IV). AEDs were discontinued in 9 (23%) patients and reduced in 13 (33%). Of note, all 3 patients whose resection included the MTS and the temporal pole, sparing the PMG, were seizure free.

Considering both corticectomies and hemispherotomies as the final surgery, both later epilepsy onset and shorter epilepsy duration – but not age at surgery – were associated with significantly higher rates of seizure freedom in univariate analysis, with shorter epilepsy duration remaining statistically significant in multivariate analysis (OR 0.99 per year, 95% CI 0.98 to 1.0,  $p = 0.04$ ) (Table 3; Fig. 5B). However, when considering only corticectomies, only later epilepsy onset was associated with significantly higher rates of seizure freedom in univariate analysis ( $p = 0.006$ ), remaining statistically significant in multivariate analysis (OR 1.02 per year, 95% CI 1.00 to 1.04,  $p = 0.03$ ). It should be noted that seizure-freedom depended neither on the concordance between the PMG and EZ nor on PMG resection in its full or partial extent (Table 3). Two thirds of unilobar or multilobar resections and all 5 hemispherotomies resulted in long-term seizure freedom.

## **DISCUSSION**

Our study reports the first large multi-centric cohort of PMG-related drug-resistant epilepsy patients undergoing SEEG and/or epilepsy surgery. This large and carefully studied series enables to elucidate the concordance between this often-extensive cortical malformation and the associated EZ. The study allowed assessing the postsurgical seizure outcome and its potential predictors in this patient group.

### **Concordance study**

The SEEG-determined EZ was fully concordant with the PMG in only 16% of all cases. This

finding strongly supports a comprehensive presurgical work-up including invasive recordings, such as SEEG, for EZ-delineation in the majority of PMG-related drug-resistant epilepsy. Our study, deriving from 49 SEEG explorations, extends previous observations from two 4-case-series of PMG-to-EZ concordance<sup>10,11</sup> that displayed a variable degree of PMG involvement in the EZ, often combined with the additional or predominant involvement of remote cortical areas. In our study, the EZ involved only part of the PMG in the majority of cases (60%), with additional remote cortical areas in 18%. The other constellations comprised, by decreasing order of frequency, an EZ involving 1) the entire PMG without additional remote cortical areas, 2) the entire PMG and remote cortical areas, and 3) only remote cortical areas. Our findings thus confirm the heterogeneity of intrinsic epileptogenicity in the PMG and highlight the complexity of PMG-to-EZ interrelations, with the PMG constituting only part of an epileptogenic network, often extending beyond and in some cases sparing the PMG.

Notably, the partial or lack of involvement of the PMG in the EZ in 70% cases in our cohort stands in stark contrast to the more straightforward malformation-to-EZ concordance encountered in FCD type II, the most common surgically remediable malformation<sup>19</sup>. FCD type II is perceived as highly epileptogenic itself, with several studies supporting that the EZ mostly co-localizes with the (MRI-visible) malformation<sup>20-22</sup>. In contrast to FCD-related epilepsy, with the completeness of FCD resection indisputably constituting a key determinant of seizure outcome<sup>23-25</sup>, partial or no involvement of the PMG in the EZ was the rule rather than the exception in our study. Furthermore, in contrast to the electrophysiological properties of FCD type II, with spontaneous seizures reproduced by electrical stimulation in the majority of cases<sup>20,26</sup>, electrical stimulation within the PMG elicited seizures in only 6 patients in our study. These specific electrophysiological properties of PMG may be related to the reduced connectivity between neighboring primary gyri within the malformation as well as between the malformation and distant gyri, as recently shown in an MRI-based connectivity study<sup>27</sup>.

The EZ involved remote cortical areas in 43% cases in our study. Overall, 15 of 21 cases related to associated cortical malformations, 8 of them localized in the neocortex (FCD and schizencephaly in 5 patients each, heterotopia in 3) and 7 in the MTS (hippocampal malformation in 5, parahippocampal nodular heterotopia and schizencephaly in 1 patient each), suggesting primary epileptogenesis as the main mechanism. In a single case, the remote cortical areas localized in the neocortex and were unrelated to a malformation. The

involvement of MTS in the 5 remaining cases may be attributed to secondary epileptogenesis. The higher vulnerability of MTS to secondary epileptogenesis compared to other sites in the brain has been previously shown in kindling models<sup>28</sup> and SEEG studies<sup>29</sup> and has been linked to younger age at epilepsy onset<sup>30</sup> as well as to longer epilepsy duration<sup>29</sup>.

The observation of 70% partial or no involvement of the PMG in the EZ in our PMG cohort is consistent with numerous studies suggesting a heterogenous epileptogenicity of the PMG. This is in line with the findings of recent studies using novel modalities such as EEG–functional(fMRI)<sup>3</sup>, electrical source imaging (ESI)<sup>4</sup>, magnetic source imaging (MSI)<sup>5</sup>, or combined magnetic and electric source imaging (MSI/ESI) in simultaneous EEG/magnetoencephalography (MEG) recordings<sup>6</sup>. These findings are also consistent with the heterogeneous histopathologic cortical organization of the PMG including less excitable neural tissue such as a cell sparse zone<sup>7</sup> and with experimental models of PMG suggesting a widespread functional disruption that extends beyond the visible abnormality<sup>8</sup>. Altogether, these findings strongly support a strategy of EZ-delineation and consequent resection in PMG-related drug-resistant epilepsy that cannot generally rely on the rough concordance of electro-clinical and neuroimaging findings, since the PMG can be completely spared or only secondarily involved or initially but partially involved in the epileptogenic network. In particular, the evidence for 16% PMG-EZ full concordance and 10% PMG-EZ discordance underlines the need for a different strategy in PMG-related drug-resistant epilepsy compared to other MCDs, namely one that is not predominantly MRI- but rather SEEG-oriented. This view is further reinforced by the fact that the vast majority of additional FCDs in our cohort escaped detection in MRI to be diagnosed on the grounds of histopathology alone.

A formal efficacy comparison between the SEEG-oriented- and the non-SEEG-oriented approaches in our study was, however, impracticable, due to the limited number of patients proceeding directly to surgery. Furthermore, 4 of 9 patients with non-SEEG oriented surgery underwent hemispherotomy for hemispheric PMG. Young children with a hemispheric PMG, multifocal unilateral seizure onset and presurgical hemiparesis that eventually undergo hemispherotomy differ to a great extent from patients undergoing SEEG-guided focal or regional corticectomy. At the other end of the spectrum, in very selected cases of small-sized unilobar PMG with fully concordant electro-clinical findings, direct resection of the entire PMG may also be a reasonable option, provided that there is no electro-clinical and PET evidence of remote cortical involvement.

The full concordance of focal hypometabolism with the EZ in our series (32%) is lower compared to a FCD type II series<sup>24</sup> (48%) and to 2 recent PMG series<sup>10,11</sup>. In these 2 PMG series, PET featured a focal or regional hypometabolism including the PMG in 5 of 8 patients and was concordant with the EZ in 7 of 8. The lower rate of PET-to-EZ concordance observed in the current study might be related to the larger size of our cohort, including cases with variable PMG localizations, other than the predominantly infrasyllian cases addressed in these 2 previous studies. However, in the present study, 6 of 12 cases with EZ involving remote cortical areas related to the MTS were highlighted by FDG-PET. Overall, our findings suggest that FDG-PET can be useful for devising the SEEG implantation scheme in PMG patients, particularly for those with infrasyllian PMG and electro-clinical evidence of MTS involvement.

### **Epilepsy surgery**

Seven of 8 patients with bilateral PMG who underwent SEEG in our study were excluded from corticectomy or hemispherotomy, due to a bilateral EZ in the majority of cases. However, a patient with bilateral frontal PMG but unilateral EZ profited substantially from right frontal corticectomy. Furthermore, another patient with bilateral PMG and unilateral EZ involving eloquent cortex had a worthwhile improvement after SEEG-guided thermo-coagulation. This indicates that some benefit may be obtained by SEEG-explorations in bilateral PMG, even in complex cases not suitable for corticectomy or hemispherotomy. It should be noted that in one previous mono-centric study of epilepsy surgery in PMG-related drug-resistant epilepsy<sup>14</sup>, 3 patients with bilateral PMG underwent epilepsy surgery, one of them remaining seizure free in the 1.5 year follow-up. Our findings suggest that SEEG should be indicated with caution in bilateral PMG, considering the lower chances to proceed to successful epilepsy surgery that clearly concerns only unilateral EZ cases. Nevertheless, SEEG-guided thermo-coagulation may prove an efficient treatment for some of these complex cases. Overall, considering the common occurrence of bilateral PMG<sup>3</sup> as opposed to the few published cases explored with SEEG or operated on, current evidence is yet inconclusive and further studies in this specific population are warranted.

Our findings of 72% seizure freedom in a large cohort with  $\geq 2$  year follow-up in the majority of patients clearly establish the overall favorable outcomes of epilepsy surgery in selected candidates with PMG-related drug-resistant epilepsy. This surgical success is even more striking, when considering the 87% rate of Engel I/II outcomes, given the devastating nature of the seizures these patients often suffer. These favorable results stand in stark contrast to

the overall poor results reported for PMG patients in MCD-related epilepsy surgery studies<sup>31,32</sup> as well as in exclusively PMG-related epilepsy surgery case series<sup>12,14</sup>, with only 33-50% of patients achieving seizure freedom. The high rates of seizure freedom in our cohort, with 77% patients undergoing corticectomy or hemispherotomy based on SEEG findings, reflect the potential of intracerebral -and intracranial- recordings to delineate tailored resections in PMG-related epilepsy with favorable postsurgical seizure outcomes, in spite of the extensive MRI-lesions and EEG-abnormalities. In addition, it should be noted that a favorable outcome could be achieved following SEEG-guided thermo-coagulation, even though this was performed in only few patients in our study. The unfavorable 33-50% rates of seizure freedom following PMG-related epilepsy surgery stem from patient series with 25% and 33% invasive recordings<sup>12,14</sup>, whereas a recent study relying on SEEG to delineate the EZ in 58% patients reported a more favorable 67% rate of seizure freedom<sup>13</sup>.

The full resection of PMG cortex was not associated with superior seizure outcomes compared to the partial or no resection of PMG cortex in our study. This observation highlights the complexity of epileptogenic networks in PMG-related drug-resistant epilepsy and corroborates the potential of SEEG to improve seizure outcomes by accurately delineating the EZ. Our findings support an entirely different surgical approach in PMG compared to FCD, where the main predictor of poor postsurgical outcome has been identified as the incomplete resection of the malformation<sup>20,23,33</sup>. In this context, a surgical resection based on intracranial recordings, sparing part of or the entire PMG can lead to long-term seizure freedom. This finding is in contrast to the trend for superior seizure outcomes following complete PMG resection in a recent case series<sup>14</sup>. This disparity can be attributed to the small sample size and the inclusion of hemimegalencephaly patients in the latter study.

Interestingly, seizure outcomes remained unaffected by the extent of the malformation, ranging from 75% to 80% for unilobar vs. multilobar vs. perisylvian vs. hemispheric PMG. This supports the notion that, in selected cases, the presence of an extensive PMG does not necessarily call for an extensive resection with possible functional losses, since the EZ may only partly overlap with the PMG<sup>10,11</sup>. On the other hand, patients with hemispheric PMG differ to a great extent from those with unilobar, multilobar and perisylvian PMG and can be excellent hemispherotomy candidates, particularly at the presence of contralateral hemiparesis<sup>9,12,13</sup> with more favorable results than in hemimegalencephaly patients<sup>14</sup>.

Finally, our findings highlight the prognostic implication of epilepsy duration, specifically in PMG-related drug-resistant epilepsy, on long-term seizure outcomes. Both later epilepsy

onset and shorter epilepsy duration were associated with significantly higher rates of seizure freedom in univariate analysis, with shorter epilepsy duration remaining statistically significant in multivariate analysis. This effect of time variables on seizure outcomes in PMG-related refractory epilepsy has not been reported before, possibly due to the small sample sizes of previous studies that failed to identify any significant predictors of seizure freedom<sup>13,14</sup>. However, shorter epilepsy duration to surgery has been highlighted as a predictor of superior seizure outcomes in previous epilepsy surgery studies<sup>34-37</sup>, though not in the specific context of PMG-related drug-resistant epilepsy. The negative effect of epilepsy duration may be partly related to a selection bias inherent to the retrospective nature of our study, since referring doctors quickly identify those patients with the highest likelihood of benefit. Alternative hypotheses include the progressive establishment of epileptogenic networks within the PMG and the associated malformations over time, culminating in secondary epileptogenesis. The identification of the appropriate time of intervention is apparently of great importance, since it concerns a potentially modifiable factor. Although 90% PMG patients presented with epilepsy in childhood, surgical intervention occurred with a latency of  $\geq 10$  years in two thirds of our epilepsy surgery cohort. This may be partly attributed to the prospect of seizure-freedom with AEDs alone that, unfortunately, holds true only for a minority of patients<sup>38</sup> as well as to the inherent difficulties in dealing with these often very extensive malformations. On the other hand, surgery has been shown to provide seizure freedom for carefully selected candidates<sup>10,11,13</sup>, including 72% patients in our study, and timely intervention, particularly in children, may help to prevent the damage caused by seizures and AEDs to the developing brain and thus offer developmental and cognitive benefits<sup>39-42</sup>.

### **Limitations**

The main limitations of our study arise from the inherent biases of its retrospective design. A prospective randomized study evaluating the relation between the PMG and the associated EZ would be optimal. However, this study design is unrealistic due to the low prevalence of this particular subgroup of patients. Furthermore, our cohort, including higher rates (33%) of predominantly unilateral perisylvian and focal PMG and of right lateralized PMG, is hardly representative for the full spectrum of PMG-related epilepsy. It rather reflects a careful patient selection for performing SEEG, excluding those at higher risk of functional contraindication for potential epilepsy surgery. In the largest PMG cohort to date<sup>3</sup>, bilateral perisylvian PMG was by far the most common pattern, whereas unilateral frontal or (temporo-)parieto-occipital PMG patterns were rarely encountered. This lower proportion of

bilateral PMG in our cohort clearly reflects the a priori exclusion of these patients for epilepsy surgery, based on the findings of non-invasive investigations.

### **Conclusions**

PMG-related drug-resistant epilepsy patients can be considered for epilepsy surgery in well-selected cases. In this context, a comprehensive presurgical evaluation, often including SEEG investigations, is warranted to accurately delineate the EZ. This study suggests that SEEG is suitable for guiding tailored resections, since the EZ may only partly overlap with the PMG or include only remote cortical areas. Favorable results in terms of seizure freedom and antiepileptic drug cessation are feasible in a large proportion of patients with unilateral PMG and PMG extent should not deter from exploring the possibility of epilepsy surgery. Finally, our data supports the early consideration of epilepsy surgery in patients with PMG-related drug-resistant epilepsy.

### **Author Contributions**

L.G.M. and G.R. were responsible for conception and design of the study. All authors were responsible for acquisition and analysis of data. L.G.M. and G.R. were responsible for drafting of the manuscript and figures.

### **Potential Conflicts of Interest**

Nothing to report.



## REFERENCES

1. Leventer RJ, Phelan EM, Coleman LT, et al. Clinical and imaging features of cortical malformations in childhood. *Neurology* 1999;53(4):715–722.
2. Wieck G, Leventer RJ, Squier WM, et al. Periventricular nodular heterotopia with overlying polymicrogyria. *Brain J. Neurol.* 2005;128(Pt 12):2811–2821.
3. Leventer RJ, Jansen A, Pilz DT, et al. Clinical and imaging heterogeneity of polymicrogyria: a study of 328 patients. *Brain J. Neurol.* 2010;133(Pt 5):1415–1427.
4. Desikan RS, Barkovich AJ. Malformations of cortical development. *Ann. Neurol.* 2016;80(6):797–810.
5. Guerrini R, Dubeau F, Dulac O, et al. Bilateral parasagittal parietooccipital polymicrogyria and epilepsy. *Ann. Neurol.* 1997;41(1):65–73.
6. Parrini E, Ferrari AR, Dorn T, et al. Bilateral frontoparietal polymicrogyria, Lennox-Gastaut syndrome, and GPR56 gene mutations. *Epilepsia* 2009;50(6):1344–1353.
7. Guerrini R. Polymicrogyria and epilepsy. *Epilepsia* 2010;51 Suppl 1:10–12.
8. Takano T. Seizure susceptibility in polymicrogyria: clinical and experimental approaches. *Epilepsy Res.* 2011;96(1-2):1–10.
9. Shain C, Ramgopal S, Fallil Z, et al. Polymicrogyria-associated epilepsy: a multicenter phenotypic study from the Epilepsy Phenome/Genome Project. *Epilepsia* 2013;54(8):1368–1375.
10. Chassoux F, Landre E, Rodrigo S, et al. Intralesional recordings and epileptogenic zone in focal polymicrogyria. *Epilepsia* 2008;49(1):51–64.
11. Ramantani G, Koessler L, Colnat-Coulbois S, et al. Intracranial evaluation of the epileptogenic zone in regional infrasyllvian polymicrogyria. *Epilepsia* 2013;54(2):296–304.
12. Wichert-Ana L, de Azevedo-Marques PM, Oliveira LF, et al. Ictal technetium-99 m ethyl cysteinate dimer single-photon emission tomographic findings in epileptic patients with polymicrogyria syndromes: a subtraction of ictal-interictal SPECT coregistered to MRI study. *Eur. J. Nucl. Med. Mol. Imaging* 2008;35(6):1159–1170.
13. Cossu M, Pelliccia V, Gozzo F, et al. Surgical treatment of polymicrogyria-related epilepsy. *Epilepsia* 2016;57(12):2001–2010.
14. Wang DD, Knox R, Rolston JD, et al. Surgical management of medically refractory epilepsy in patients with polymicrogyria. *Epilepsia* 2016;57(1):151–161.
15. Rikir E, Koessler L, Gavaret M, et al. Electrical source imaging in cortical malformation-related epilepsy: a prospective EEG-SEEG concordance study. *Epilepsia* 2014;55(6):918–932.
16. Barkovich AJ, Guerrini R, Kuzniecky RI, et al. A developmental and genetic classification for malformations of cortical development: update 2012. *Brain J. Neurol.* 2012;135(Pt 5):1348–1369.
17. Engel J Jr, Van Ness PC, Rasmussen TB, Ojemann LM. Outcome with respect to epileptic seizures. In: Engel J Jr, editor. *Surgical treatment of the epilepsies*. New York: Raven Press; 1993 p. 609–21.
18. R Core Team. R: A language and environment for statistical computing. [Internet]. Vienna, Austria: R Foundation for Statistical Computing; 2014. Available from: <http://www.R-project.org/>
19. Guerrini R, Duchowny M, Jayakar P, et al. Diagnostic methods and treatment options for focal cortical dysplasia. *Epilepsia* 2015;56(11):1669–1686.
20. Chassoux F, Devaux B, Landré E, et al. Stereoelectroencephalography in focal cortical dysplasia: a 3D approach to delineating the dysplastic cortex. *Brain J. Neurol.* 2000;123 ( Pt

- 8):1733–1751.
21. Tassi L, Pasquier B, Minotti L, et al. Cortical dysplasia: electroclinical, imaging, and neuropathologic study of 13 patients. *Epilepsia* 2001;42(9):1112–1123.
  22. Krsek P, Maton B, Korman B, et al. Different features of histopathological subtypes of pediatric focal cortical dysplasia. *Ann. Neurol.* 2008;63(6):758–769.
  23. Krsek P, Maton B, Jayakar P, et al. Incomplete resection of focal cortical dysplasia is the main predictor of poor postsurgical outcome. *Neurology* 2009;72(3):217–223.
  24. Chassoux F, Rodrigo S, Semah F, et al. FDG-PET improves surgical outcome in negative MRI Taylor-type focal cortical dysplasias. *Neurology* 2010;75(24):2168–2175.
  25. Chassoux F, Landré E, Mellerio C, et al. Type II focal cortical dysplasia: electroclinical phenotype and surgical outcome related to imaging. *Epilepsia* 2012;53(2):349–358.
  26. Varotto G, Tassi L, Franceschetti S, et al. Epileptogenic networks of type II focal cortical dysplasia: a stereo-EEG study. *NeuroImage* 2012;61(3):591–598.
  27. Im K, Paldino MJ, Poduri A, et al. Altered white matter connectivity and network organization in polymicrogyria revealed by individual gyral topology-based analysis. *NeuroImage* 2014;86:182–193.
  28. Bertram E. The relevance of kindling for human epilepsy. *Epilepsia* 2007;48 Suppl 2:65–74.
  29. Bartolomei F, Chauvel P, Wendling F. Epileptogenicity of brain structures in human temporal lobe epilepsy: a quantified study from intracerebral EEG. *Brain J. Neurol.* 2008;131(Pt 7):1818–1830.
  30. Morrell F. Secondary epileptogenesis in man. *Arch. Neurol.* 1985;42(4):318–335.
  31. Sisodiya SM. Surgery for malformations of cortical development causing epilepsy. *Brain J. Neurol.* 2000;123 ( Pt 6):1075–1091.
  32. Chang EF, Wang DD, Barkovich AJ, et al. Predictors of seizure freedom after surgery for malformations of cortical development. *Ann. Neurol.* 2011;70(1):151–162.
  33. Aubert S, Wendling F, Regis J, et al. Local and remote epileptogenicity in focal cortical dysplasias and neurodevelopmental tumours. *Brain J. Neurol.* 2009;132(Pt 11):3072–3086.
  34. Liava A, Francione S, Tassi L, et al. Individually tailored extratemporal epilepsy surgery in children: anatomo-electro-clinical features and outcome predictors in a population of 53 cases. *Epilepsy Behav. EB* 2012;25(1):68–80.
  35. Simasathien T, Vadera S, Najm I, et al. Improved outcomes with earlier surgery for intractable frontal lobe epilepsy. *Ann. Neurol.* 2013;73(5):646–654.
  36. Ramantani G, Stathi A, Brandt A, et al. Posterior cortex epilepsy surgery in childhood and adolescence: Predictors of long-term seizure outcome. *Epilepsia* 2017;58(3):412–419.
  37. Ramantani G, Kadish NE, Mayer H, et al. Frontal lobe epilepsy surgery in childhood and adolescence: predictors of long-term seizure freedom, overall cognitive and adaptive functioning. *Neurosurgery* 2017;
  38. Caraballo RH, Cersósimo RO, Fortini PS, et al. Congenital hemiparesis, unilateral polymicrogyria and epilepsy with or without status epilepticus during sleep: a study of 66 patients with long-term follow-up. *Epileptic Disord. Int. Epilepsy J. Videotape* 2013;15(4):417–427.
  39. Freitag H, Tuxhorn I. Cognitive function in preschool children after epilepsy surgery: rationale for early intervention. *Epilepsia* 2005;46(4):561–567.
  40. Loddenkemper T, Holland KD, Stanford LD, et al. Developmental outcome after epilepsy surgery in infancy. *Pediatrics* 2007;119(5):930–935.
  41. Skirrow C, Cross JH, Cormack F, et al. Long-term intellectual outcome after temporal lobe

surgery in childhood. *Neurology* 2011;76(15):1330–1337.

42. Ramantani G, Kadish NE, Anastasopoulos C, et al. Epilepsy surgery for glioneuronal tumors in childhood: avoid loss of time. *Neurosurgery* 2014;74(6):648–657; discussion 657.

Accepted Article

## FIGURE LEGENDS

**Figure 1:** Flowchart illustrating the findings of stereo-electroencephalography (SEEG) evaluation according to the extent of the polymicrogyria (PMG), including the extent of the epileptogenic zone and the outcome of epilepsy surgery, where applicable.

**Figure 2:** Flowchart illustrating the patient selection and presurgical evaluation as well as the outcome of corticectomy or hemispherotomy according to the extent of the polymicrogyria (PMG).

**Figure 3:** Illustrative case displaying (A) a right perisylvian polymicrogyria (PMG) with (B) a 3D surface MRI reconstruction of the depth electrode entry points. (C) The seizure onset in stereo-electroencephalography (SEEG) involved the right pre-central and frontal operculum (electrodes S, R, H, marked in red). The propagation zone involved the right temporal region (electrodes T, W) and the post-central operculum (electrode V, all marked in green). (D) The postsurgical MRI presents the resection that involved only part of the PMG (pre-central and frontal operculum).

**Figure 4:** Illustrative case displaying (A) a multilobar polymicrogyria (PMG) involving the right temporal lobe and temporo-parieto-occipital junction with the entry points of the depth electrodes on the 3D surface MRI reconstruction and the trajectories of the main electrodes on axial slices. (B) The seizure onset was characterized by a fast low voltage discharge involving the right medial temporal structures (MTS: amygdala, hippocampus, displayed in red brackets) and a rapid propagation to the most anterior part of the PMG (middle and inferior temporal gyri, displayed in blue brackets). (C) The postsurgical MRI displays the resection involving the MTS and the anterior part of the PMG.

**Figure 5:** (A) Kaplan-Meier curves illustrating chances of postsurgical seizure freedom following corticectomy or hemispherotomy for PMG-related drug-resistant epilepsy in all patients. The confidence interval is displayed as dotted lines. (B) Boxplot of epilepsy duration to surgery by seizure freedom status after surgery for PMG-related drug-resistant epilepsy. Both epilepsy duration and age at seizure onset were identified as statistically significant predictors of seizure freedom in univariate analysis, but only epilepsy duration retained its prognostic value in multivariate analysis.

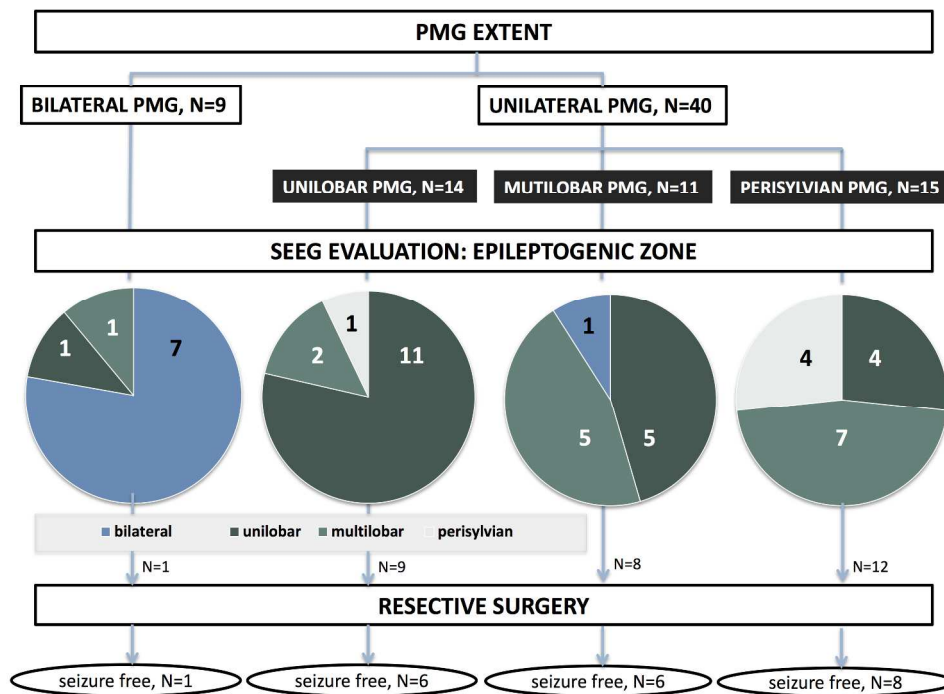


Figure 1: Flowchart illustrating the findings of stereo-electroencephalography (SEEG) evaluation according to the extent of the polymicrogyria (PMG), including the extent of the epileptogenic zone and the outcome of epilepsy surgery, where applicable.

254x190mm (300 x 300 DPI)

Accep

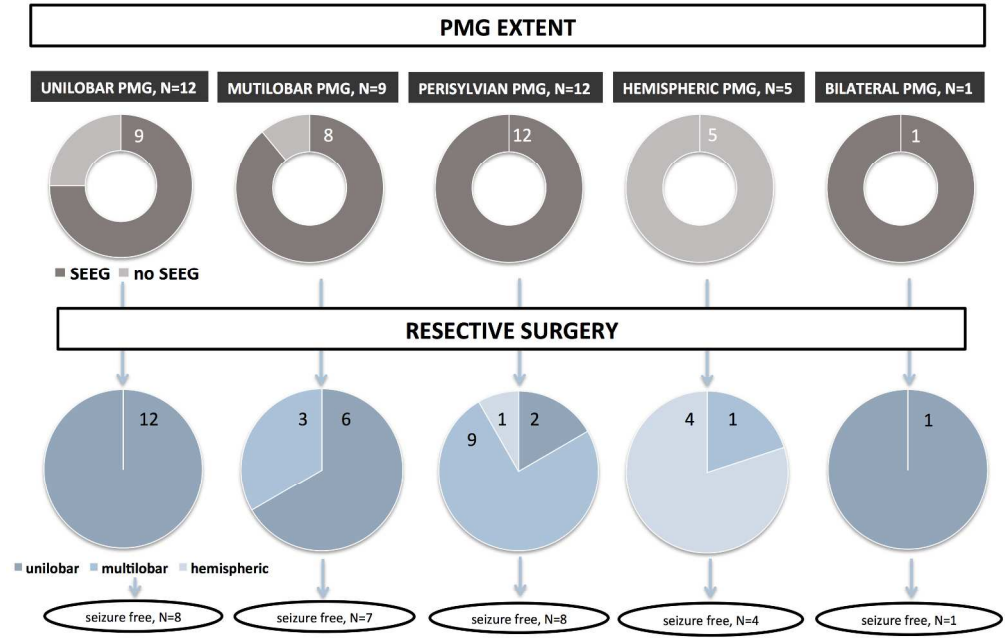


Figure 2: Flowchart illustrating the patient selection and presurgical evaluation as well as the outcome of corticectomy or hemispherotomy according to the extent of the polymicrogyria (PMG).

254x190mm (300 x 300 DPI)

Accepted

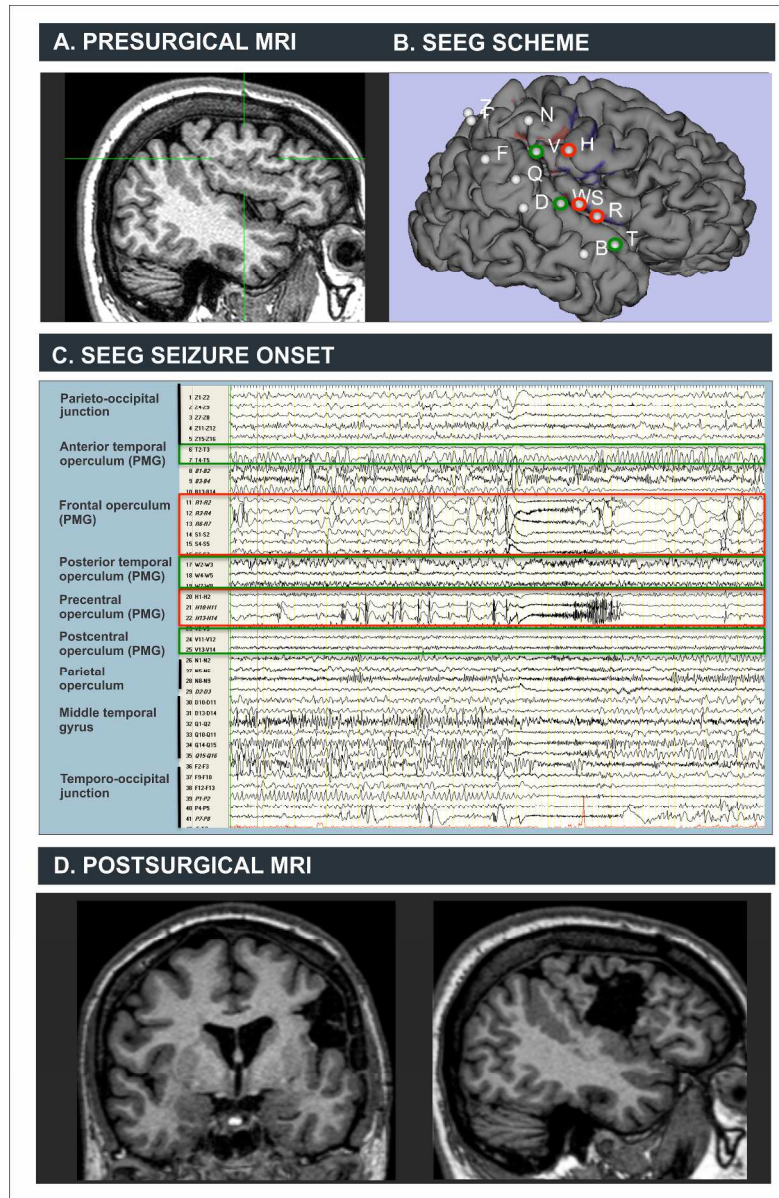


Figure 3: Illustrative case displaying (A) a right perisylvian polymicrogyria (PMG) with (B) a 3D surface MRI reconstruction of the depth electrode entry points. (C) The seizure onset in stereo-electroencephalography (SEEG) involved the right pre-central and frontal operculum (electrodes S, R, H, marked in red). The propagation zone involved the right temporal region (electrodes T, W) and the post-central operculum (electrode V, all marked in green). (D) The postsurgical MRI presents the resection that involved only part of the PMG (pre-central and frontal operculum).

333x510mm (300 x 300 DPI)

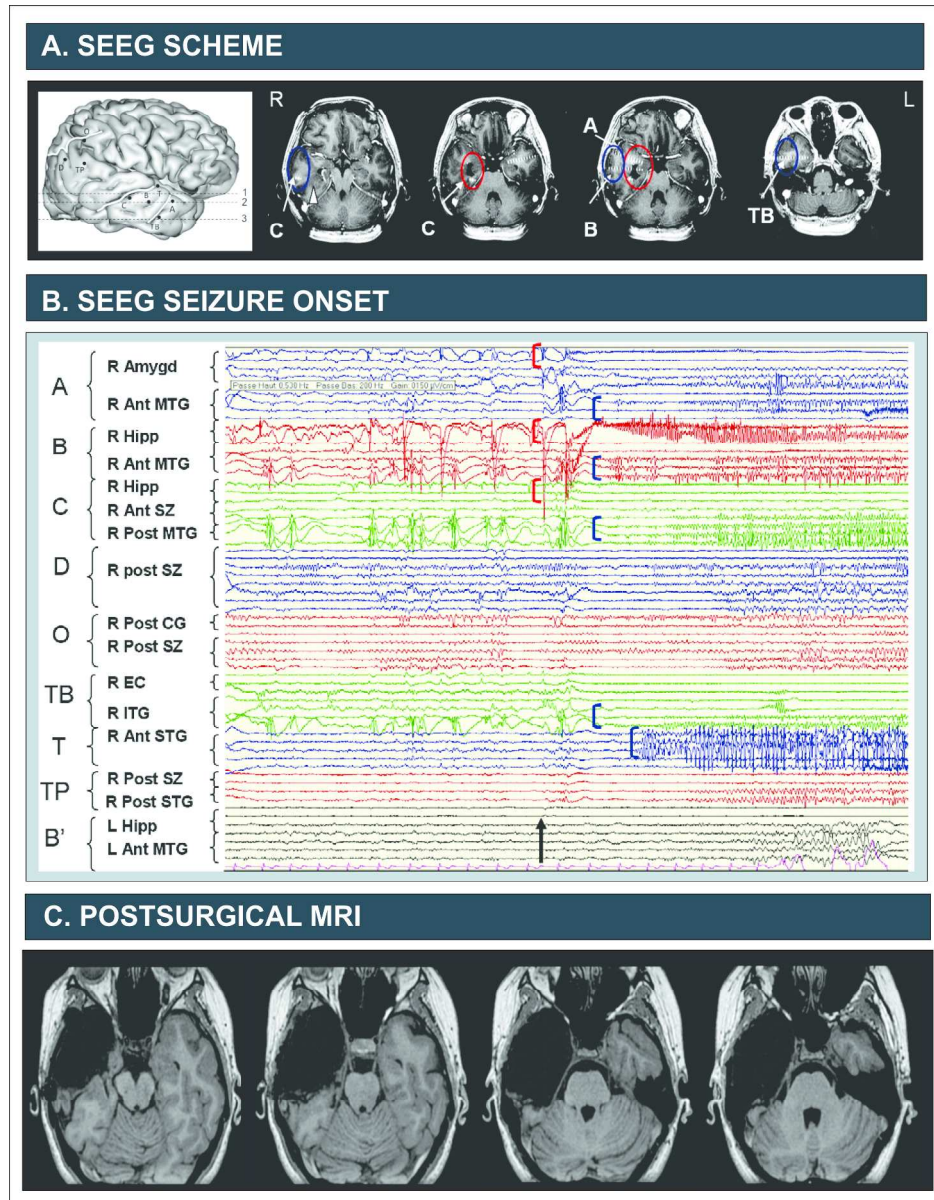


Figure 4: Illustrative case displaying (A) a multilobar polymicrogyria (PMG) involving the right temporal lobe and temporo-parieto-occipital junction with the entry points of the depth electrodes on the 3D surface MRI reconstruction and the trajectories of the main electrodes on axial slices. (B) The seizure onset was characterized by a fast low voltage discharge involving the right medial temporal structures (MTS: amygdala, hippocampus, displayed in red brackets) and a rapid propagation to the most anterior part of the PMG (middle and inferior temporal gyri, displayed in blue brackets). (C) The postsurgical MRI displays the resection involving the MTS and the anterior part of the PMG.

271x347mm (300 x 300 DPI)



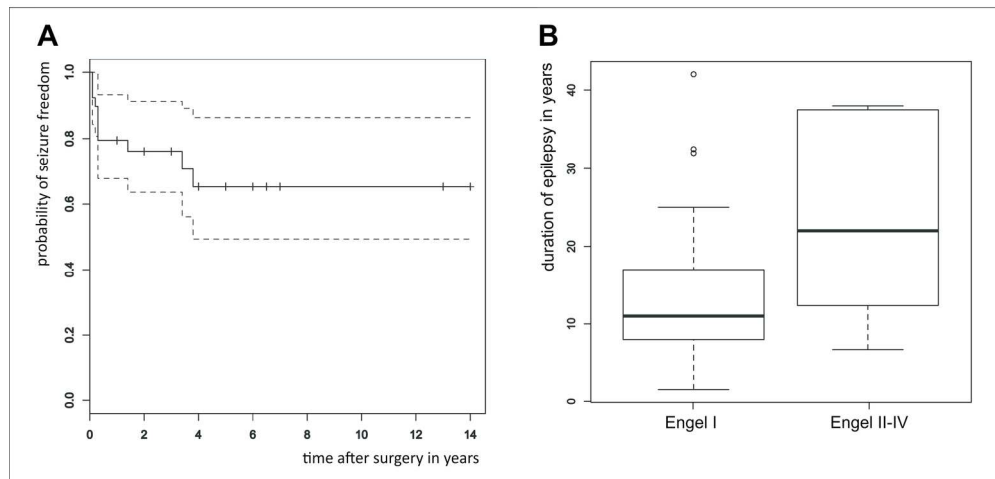


Figure 5: (A) Kaplan-Meier curves illustrating chances of postsurgical seizure freedom following corticectomy or hemispherotomy for PMG-related drug-resistant epilepsy in all patients. (B) Boxplot of epilepsy duration to surgery by seizure freedom status after surgery for PMG-related drug-resistant epilepsy. Both epilepsy duration and age at seizure onset were identified as statistically significant predictors of seizure freedom in univariate analysis, but only epilepsy duration retained its prognostic value in multivariate analysis.

179x95mm (300 x 300 DPI)

Accepte

<b>CHARACTERISTICS</b>	<b>TOTAL (n=58)</b>	<b>SEEG (n=49)</b>	<b>CORTICECTOMY/ HEMISPHEROTOMY (n=39)</b>
<b>Male</b>	34(59%)	29(59%)	22(56%)
<b>Cognitive impairment</b>	26(45%)	18(37%)	18(46%)
<b>Neurologic deficit</b>			
Visual	10(17%)	5(10%)	9(23%)
Motor	14(24%)	8(16%)	12(31%)
<b>Age at epilepsy onset, y, mean <math>\pm</math> SD (range)</b>	11.0 $\pm$ 8.0 (0.1-36)	12.3 $\pm$ 7.9 (0.1-36)	9.1 $\pm$ 7.3 (0.1-28)
<b>Age at SEEG/surgery, y, mean <math>\pm</math> SD (range)</b>	28.3 $\pm$ 12.7 (2-50)	31.1 $\pm$ 11.1 (7-50)	25.4 $\pm$ 13.0 (2-47)
<b>Duration of epilepsy, y, mean <math>\pm</math> SD (range)</b>	17.4 $\pm$ 10.9 (1.5-42)	18.9 $\pm$ 10.8 (4-42)	16.5 $\pm$ 11.4 (1.5-42)
<b>MRI</b>			
<b>PMG lateralization</b>			
Right	34(59%)	28(57%)	28(72%)
Left	15(26%)	12(24%)	10(26%)
Bilateral	9(16%)	9(18%)	1(3%)
<b>Unilateral PMG topography</b>			
Unilobar	17(29%)	14(29%)	12(31%)
Multilobar	12(21%)	11(22%)	9(23%)
Perisylvian	15(26%)	15(31%)	12(31%)
Hemispheric	5(9%)	-	5(13%)
<b>Associated malformations*</b>	28(48%)	25(51%)	21(54%)
Schizencephaly	13(22%)	12(24%)	9(23%)
Heterotopia	12(21%)	12(24%)	9(23%)
Hippocampal malformation	6(10%)	6(12%)	4(10%)
FCD	12(21%)	10(20%)	12(31%)
<b>FDG-PET-hypometabolism</b>	30(52%)	28(57%)	19(49%)
<b>Final surgical procedure</b>			
Corticectomy	34(59%)	29(59%)	34(87%)
Hemispherotomy	5(9%)	1(2%)	5(13%)
Thermo-coagulation	3(5%)	3(6%)	
Callosotomy	2(3%)	2(4%)	

**Table 1:** Characteristics of all study patients as well as of the subgroups with SEEG-delineated epileptogenic zone and with corticectomy or hemispherotomy.

SEEG: stereo-electroencephalography; y: years; SD: standard deviation; PMG: polymicrogyria; \*: based on MRI and histopathology findings; FCD: focal cortical dysplasia; EZ: epileptogenic zone

CHARACTERISTICS	UNILOBAR (n=14)	MULTILOBAR (n=11)	PERISYLVIAN (n=15)	BILATERAL (n=9)	ALL (n=49)
<b>PMG – EZ concordance</b>					
= EZ	2(14%)	0	3(20%)	3(33%)	8(16%)
≥ EZ	5(36%)**	6(55%)*	12(80%)	6(66%)*	29(60%)*
≤ EZ	5(36%)	2(18%)	0	0	7(14%)
≠ EZ	2(14%)	3(27%)	0	0	5(10%)
<b>Resection contraindication/ limitation</b>					
Risk of functional deficit	2(14%)	3(27%)	1(7%)	1(11%)	7(14%)
EZ too extensive	0	0	1(7%)	7(78%)	8(16%)
<b>Corticectomy or hemispherotomy</b>	9(64%)	8(73%)	12(80%)	1(11%)	30(61%)
<b>Postsurgical follow-up, y, mean±SD (range)</b>	4.3±2.7 (1-9)	3.6±1.7 (1-6)	3.8±3.4 (1-13)	5.0	4.0±2.7 (1-13)
<b>Seizure free<sup>§</sup> at last follow-up</b>	6(66%)	6(75%)	8(75%)	1(100%)	21(70%)

**Table 2:** Anatomico-electrical concordance and surgical variables in PMG patients that underwent SEEG. The EZ included remote cortical areas in 21 (43%) cases and was primarily localized in those in 5 (10%), all related to the mesial temporal structures. All but one patients proceeding to surgery had a unilateral PMG.

PMG: polymicrogyria; EZ: epileptogenic zone; \*: cases additionally including remote cortical areas; y: years; SD: standard deviation; §: Engel I outcome = : fully concordant; ≥ : concordant, more extensive; ≤ : concordant, less extensive; ≠: discordant

CHARACTERISTICS		ENGEL I (n=28)	ENGEL II-IV (n=11)	P-value
CLINICAL	<b>Cognitive impairment (n=18)</b>	13(72%)	5(28%)	1
	<b>Age at epilepsy onset, y, mean±SD (range)</b>	10.5±7.8 (0.5-28)	5.5±4.5 (0.1-11)	0.03*
	<b>Age at surgery, y, mean ±SD (range)</b>	24.2±12.0 (2-46)	28.6±15.4 (7-47)	0.35
	<b>Duration of epilepsy, y, mean±SD (range)</b>	13.8±9.7 (1.5-42)	23.4±12.8 (6.7-38)	0.04*
	<b>Secondary generalized seizures (n=13)</b>	9(69%)	4(31%)	1
MRI	<b>PMG lateralization</b>			
	Right (n=28)	22(79%)	6(21%)	0.20
	Left (n=10)	5(50%)	5(50%)	
	Bilateral (n=1)	1(100%)		
	<b>PMG extent</b>			
	Unilobar (n=12)	8(75%)	4(25%)	0.92
	Multilobar (n=9)	7(78%)	2(22%)	
	Perisylvian (n=12)	8(75%)	4(25%)	
	Hemispheric (n=5)	4(80%)	1(20%)	
	<b>Associated malformations (n=21)<sup>§</sup></b>	15(71%)	6(29%)	1
Schizencephaly (n=9)	8(89%)	1(11%)		
Nodular heterotopia (n=9)	8(89%)	1(11%)		
Hippocampal malformation (n=4)	2(50%)	2(50%)		
FCD (n=12)	8(75%)	4(25%)		
SEEG	<b>EZ – PMG concordance (n=37)</b>			
	= PMG (n=12)	10(83%)	2(17%)	0.72
	≥ PMG (n=4)	3(75%)	1(25%)	
	≤ PMG (n=18)	12(67%) <sup>§§§§§</sup>	6(33%) <sup>§§</sup>	
	≠ PMG (n=3)	3(100%)	0	
RESECTION	<b>Resection – PMG concordance</b>			
	Complete PMG resection (n=19)	13(68%)	6(32%)	0.76
	Partial PMG resection (n=17)	12(71%)	5(29%)	
	No PMG resection (n=3)	3(100%)	0	
	<b>Resection beyond the PMG<sup>#</sup> (n=21)</b>	18(86%)	3(14%)	0.07
	<b>Resection/disconnection extent</b>			
	Unilobar (n=21)	14(67%)	7(33%)	0.47
Multilobar (n=13)	9(69%)	4(31%)		
Hemispheric (n=5)	5(100%)	0		

**Table 3:** Characteristics of PMG patients that underwent corticectomy or hemispherotomy in relation to seizure outcome.

\*:  $p < 0.05$ ; <sup>§</sup>: based on MRI and histopathology findings; <sup>§</sup>: including remote cortical areas; <sup>#</sup>: either exclusive or additional to a complete/partial PMG resection; PMG: polymicrogyria; EZ: epileptogenic zone; y: years; SD: standard deviation

= : fully concordant; ≥ : concordant, more extensive; ≤ : concordant, less extensive; ≠: discordant