



HAL
open science

Localizing value of electrical source imaging: Frontal lobe, malformations of cortical development and negative MRI related epilepsies are the best candidates

Chifaou Abdallah, Louis Maillard, Estelle Rikir, Jacques Jonas, Anne Thiriaux, Martine Gavaret, Fabrice Bartolomei, Sophie Colnat-Coulbois, Jean-Pierre Vignal, Laurent Koessler

► To cite this version:

Chifaou Abdallah, Louis Maillard, Estelle Rikir, Jacques Jonas, Anne Thiriaux, et al.. Localizing value of electrical source imaging: Frontal lobe, malformations of cortical development and negative MRI related epilepsies are the best candidates. *Neuroimage-Clinical*, 2017, 16, pp.319-329. 10.1016/j.nicl.2017.08.009 . hal-01660370

HAL Id: hal-01660370

<https://hal.science/hal-01660370>

Submitted on 25 Oct 2023

HAL is a multi-disciplinary open access archive for the deposit and dissemination of scientific research documents, whether they are published or not. The documents may come from teaching and research institutions in France or abroad, or from public or private research centers.

L'archive ouverte pluridisciplinaire **HAL**, est destinée au dépôt et à la diffusion de documents scientifiques de niveau recherche, publiés ou non, émanant des établissements d'enseignement et de recherche français ou étrangers, des laboratoires publics ou privés.



Distributed under a Creative Commons Attribution 4.0 International License



Localizing value of electrical source imaging: Frontal lobe, malformations of cortical development and negative MRI related epilepsies are the best candidates



Chifaou Abdallah^a, Louis G. Maillard^{a,d,e,j}, Estelle Rikir^{b,c}, Jacques Jonas^{a,d,e}, Anne Thiriaux^g, Martine Gavaret^{f,h,i}, Fabrice Bartolomei^{f,h,i}, Sophie Colnat-Coulbois^{j,k}, Jean-Pierre Vignal^{a,d,e}, Laurent Koessler^{a,d,e,*}

^a Neurology Department, University Hospital of Nancy, Nancy, France

^b Neurology Department, University Hospital of Sart-Tilman, Liege, Belgium

^c Medical Faculty, Liege University, Liege, Belgium

^d CRAN, UMR 7039, Lorraine University, Vandœuvre-les-Nancy Cedex, France

^e CNRS, CRAN, UMR 7039, Vandœuvre-les-Nancy Cedex, France

^f Clinical Neurophysiology Department, AP-HM, University Hospital la Timone, Marseille, France

^g Neurology department, University Hospital of Reims, Reims, France

^h INSERM UMR 1106, Institut de Neurosciences des Systemes, Marseille, France

ⁱ Medical Faculty, Aix-Marseille University, Marseille, France

^j Medical Faculty, Lorraine University, Nancy, France

^k Neurosurgery Department, University Hospital of Nancy, Nancy, France

ARTICLE INFO

Keywords:

Electrical source imaging
Stereo-EEG
High resolution EEG
Epilepsy surgery
Malformations of cortical development

ABSTRACT

Objective: We aimed to prospectively assess the anatomical concordance of electric source localizations of interictal discharges with the epileptogenic zone (EZ) estimated by stereo-electroencephalography (SEEG) according to different subgroups: the type of epilepsy, the presence of a structural MRI lesion, the aetiology and the depth of the EZ.

Methods: In a prospective multicentric observational study, we enrolled 85 consecutive patients undergoing pre-surgical SEEG investigation for focal drug-resistant epilepsy. Electric source imaging (ESI) was performed before SEEG. Source localizations were obtained from dipolar and distributed source methods. Anatomical concordance between ESI and EZ was defined according to 36 predefined sublobar regions. ESI was interpreted blinded to and subsequently compared with SEEG estimated EZ.

Results: 74 patients were finally analyzed. 38 patients had temporal and 36 extra-temporal lobe epilepsy. MRI was positive in 52. 41 patients had malformation of cortical development (MCD), 33 had another or an unknown aetiology. EZ was medial in 27, lateral in 13, and medio-lateral in 34. In the overall cohort, ESI completely or partly localized the EZ in 85%: full concordance in 13 cases and partial concordance in 50 cases. The rate of ESI full concordance with EZ was significantly higher in (i) frontal lobe epilepsy (46%; $p = 0.05$), (ii) cases of negative MRI (36%; $p = 0.01$) and (iii) MCD (27%; $p = 0.03$). The rate of ESI full concordance with EZ was not statistically different according to the depth of the EZ.

Significance: We prospectively demonstrated that ESI more accurately estimated the EZ in subgroups of patients who are often the most difficult cases in epilepsy surgery: frontal lobe epilepsy, negative MRI and the presence of MCD.

1. Introduction

Drug-resistant epilepsy represents 33% of all epilepsies. In structural focal drug-resistant epilepsies, functional neurosurgery remains the

only potentially curative treatment, provided that it includes the entire epileptogenic zone (Spencer and Huh, 2008). In order to localize and delineate the epileptogenic zone (EZ), the pre-surgical investigations include primarily long term video-EEG recordings, structural magnetic

* Corresponding author at: CRAN UMR 7039, CNRS - Université de Lorraine, 2 Avenue de la forêt de Haye, 54516 Vandœuvre-lès-Nancy, France.
E-mail address: laurent.koessler@univ-lorraine.fr (L. Koessler).

<http://dx.doi.org/10.1016/j.nicl.2017.08.009>

Received 12 October 2016; Received in revised form 24 July 2017; Accepted 7 August 2017

Available online 08 August 2017

2213-1582/ © 2017 The Authors. Published by Elsevier Inc. This is an open access article under the CC BY-NC-ND license (<http://creativecommons.org/licenses/by-nc-nd/4.0/>).

imaging (MRI), and additional investigations such as a [(18) F] fluorodeoxyglucose positron emission tomography (FDG-PET) and single-photon emission computed tomography (SPECT) scans. In recent years, high resolution EEG combined to electrical source imaging (ESI) as well as magnetoencephalography (MEG) have taken up a promising place in this pre-surgical investigation due to its ability to localize epileptic sources in the individual anatomical space and in a non-invasive way. Due to short duration of high resolution EEG recordings (often less than one day), the major part of ESI studies concerns the analysis of interictal discharges (IID).

The overall accuracy of ESI from interictal discharges (IID) in the pre-surgical investigation was evaluated in several studies (Plummer et al., 2008; Kaiboriboon et al., 2012). Two recent prospective studies assessed this overall accuracy of electric source imaging (Lascano et al., 2016; Brodbeck et al., 2011) in a large cohort of patients undergoing pre-surgical investigations for drug-resistant focal epilepsy. Brodbeck et al., found highest sensitivity and specificity (> 80%) of ESI which derived from high resolution-EEG and individual head modelling using the volume of resection combined with the post-surgical outcomes as the reference method. Lascano et al., extended these results and showed in 58 patients that the presence of concordant structural MRI and ESI results was the strongest predictor of postoperative seizure freedom.

The specific accuracy of ESI was investigated in different subgroups with: negative MRI (Brodbeck et al., 2010), large lesions (Brodbeck et al., 2009), malformations of cortical development (Rikir et al., 2014), temporal (Gavaret et al., 2004), frontal (Gavaret et al., 2006) and posterior lobe epilepsies (Gavaret et al., 2009). Most of these studies were retrospective and they all relied on heterogeneous methodologies (number of electrodes, type of head model, methods of source localization, reference methods), which precluded a direct or indirect comparison of ESI performance according to the presence of a MRI lesion, type of epilepsy, and aetiology. One study prospectively compared ESI performance between temporal and extra-temporal lobe epilepsy and did not find any significant difference (Brodbeck et al., 2011).

The purposes of our study were therefore to: (1) prospectively assess, in a large cohort the overall anatomical concordance of IID source localization with the epileptogenic zone estimated by SEEG; (2) prospectively compare the anatomical concordance of IID source localization with the epileptogenic zone estimated by SEEG according to the type of epilepsy, the presence of a MRI lesion, the aetiology and the depth of the EZ.

2. Materials and methods

2.1. Patient selection

Eighty five patients (15 years old and older; mean age: 30 years old) with drug-resistant focal epilepsy, who were candidates for SEEG were prospectively and consecutively enrolled between October 2009 and October 2013 in the multicentric National Clinical Research Project PHRC 2009-17-05, Clinical trial NCT 01090934 (Nancy, Marseille, and Reims). This study was approved by the ethics committee CPP Est III and all patients gave their informed written consent (Clinical trial NCT 01090934).

2.2. Data recording and analysis

Non-invasive pre-surgical evaluation included comprehensive medical history, neurological examination, long-term video-EEG recordings, MRI and neuropsychological evaluation. Some patients benefited interictal positron emission tomography (PET) and/or interictal/ictal single-photon emission computed tomography (SPECT). The analysis of the electro-clinical correlations (ECC) was based on the interictal and ictal EEG findings as well as the ictal semiology, combining both interdependent modalities toward dynamic spatiotemporal hypotheses (Rikir et al., 2014). High resolution EEG (64 scalp taped

electrodes) and SEEG recordings were similar to our previous study (Rikir et al., 2014). The analysis of electro-clinical correlations (ECC), MRI, ESI and SEEG were classified in the 18 pre-defined sub-lobar anatomical localizations (Rikir et al., 2014) in each hemisphere: ventral medial prefrontal, dorsal medial prefrontal, ventral lateral prefrontal, dorsal lateral prefrontal, medial premotor, lateral premotor, medial central, lateral central, medial anterior temporal, lateral anterior temporal, medial posterior temporal, lateral posterior temporal, medial parietal, lateral parietal, medial occipital, lateral occipital, operculoinsular and temporo-parieto-occipital junction. So, a total of 36 pre-defined regions of interest (ROIs) were considered.

2.2.1. Interictal discharge detection and analysis

Scalp IID included interictal spikes (< 70 ms) and sharp waves (< 200 ms). They were visually identified and marked in an average reference montage channel (excluding electrodes with artefacts) by one of four experienced epileptologists according to the following established criteria (Rikir et al., 2014): (a) paroxysmal occurrence, (b) abrupt change in polarity, (c) duration < 200 ms, (d) scalp topography consistent with a clear dipolar projection onto the scalp (radial or tangential). Temporal windows of analysis (max 100 ms) were manually defined around the IID and centered at the time of maximal negativity on the electrode trace with the highest amplitude (Advanced Signal Analysis, Enschede, The Netherlands) (Rikir et al., 2014; Gavaret et al., 2004; Koessler et al., 2010). All 64 electrode traces were then superimposed to ascertain that the signal to noise ratio (SNR), defined as the highest IID amplitude divided by the highest background (1 s duration before the spike) activity amplitude, was > 2. For each patient, an average of 15 single IIDs were visually categorized according to their respective topography and morphology and then individually analyzed per type for source localization (range 1–4 IID types, average of 2 IID types by patient).

2.2.2. ESI methodology

For each patient, we constructed realistic head models (boundary element method; BEM) derived from an additional MRI sequence (3D BRAVO T1-weighted sequence, voxel: 1.3 mm³, General Electric Medical System, Milwaukee, United States) and the scalp electrodes were localized (Koessler et al., 2007; Koessler et al., 2008). We performed a semi-automatic segmentation that consisted in the identification of three isoconductivity compartments (scalp, skull and intracranial space) with the skull estimated by the dilatation of the intracranial space. We subsequently calculated an electric matrix with a conductivity of 0.008 S/m for the skull and 0.33 S/m for the brain and scalp (conductivity ratio of skull to scalp = 1/40). Co-registration of EEG and MRI data derived from the identification of the same three fiducials (nasion, right and left tragi).

Intracerebral sources of each selected IID were localized using both equivalent current dipoles (Scherg and Ebersole, 1993) (ECD), MUSIC (Mosher et al., 1992) and sLORETA (Pascual-Marqui, 2002) (grid spacing of 10 mm). For more details, see Rikir et al., 2014.

2.2.3. Determination of the irritative zone by ESI

The anatomical localization was interpreted from the coordinates of moving and rotating dipoles with goodness of fit (GOF) > 90%, of the equivalent dipoles explaining more than 95% of the signal (eigenvector decomposition) using MUSIC, and of the dipoles with the highest magnitude using sLORETA. We extrapolated these dipole positions to one (or maximum two) sublobar region for each sLORETA map of each single IID.

No comparison of ESI localizations was done across the different source model for each single IID. In this study, for each IID type, the interpreter visually chose only relevant (i.e. in accordance with his clinical hypothesis) and reproducible anatomical localizations. A localization was considered as reproducible when sources were located in a same sublobar region for at least 10/15 individual spikes. Other source

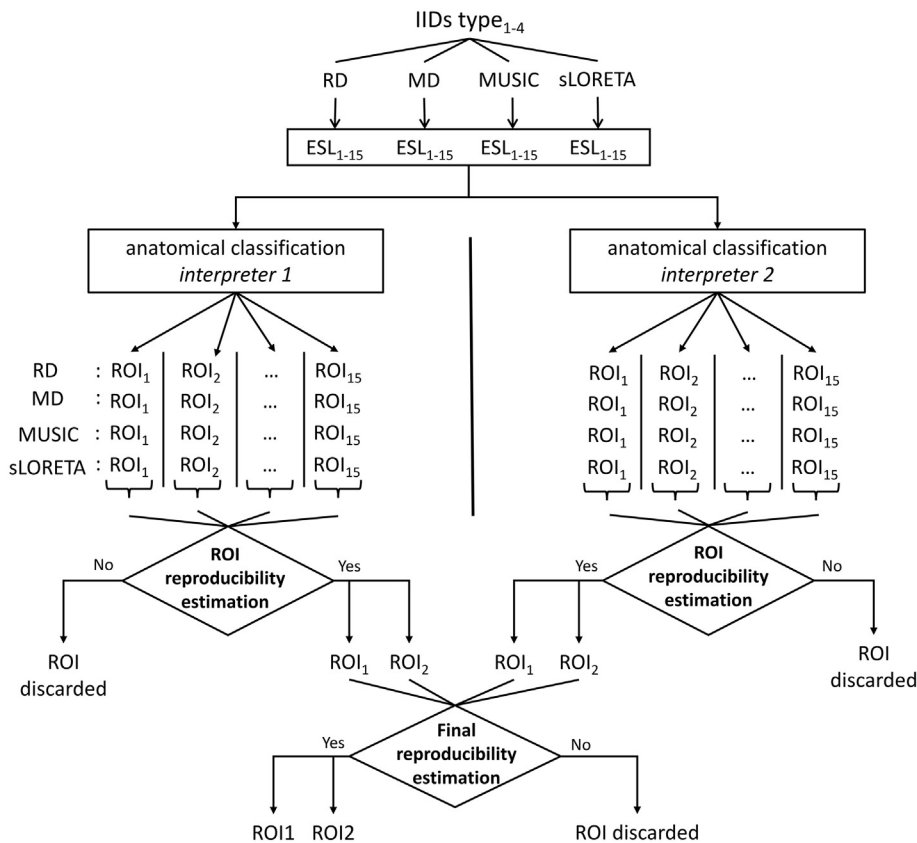


Fig. 1. Consecutive steps of electrical source imaging analysis. Two different interpreters analyzed the results prior to the SEEG results. Within each spike subgroup, only reproducible and concordant ESI results were selected and classified according to 36 predefined sublobar regions. ESL, electrical source localization; ROI, region of interest; RD, rotating dipole; MD, moving dipole; IIDs, interictal discharges.

localizations were discarded.

These reproducible and relevant anatomical localizations were then classified according to the same 36 predefined sublobar localizations (regions of interest) used for ECC and MRI. In case of multifocal IIDs, all reproducible and relevant sources were anatomically classified. When the distribution of the source localizations was inferior or equal to one specific sublobar localization, this localization was retained. When the distribution of the source localizations was superior to one sublobar localization, we retained all sublobar localizations that completely included the source localizations.

For each patient, ESI results were interpreted prospectively and independently by two investigators in order to localize the presumed irritative zone (IZ). In case of discordance between the two interpreters, further joint analysis led to a final anatomical classification (consensus).

This step was performed several months prior to SEEG recordings and therefore blinded to its results. Fig. 1 summarizes all this section.

2.3. ESI and SEEG overall anatomical concordance

The planning of the SEEG implantation was based on the results of ECC, MRI, neuropsychological evaluation and (for patients who have benefited) PET-FDG and/or interictal/ictal SPECT and ESI results.

Epileptogenic zone, defined as “the anatomical location of the site of the beginning and of the primary organization of the epileptic discharge” (Kahane et al., 2006), was defined by one of four experienced epileptologists using spontaneous and electrically induced seizures during SEEG investigation. When the spatial extent of EZ was superior to one sublobar region, several regions were selected in order to include all the EZ.

The anatomical concordance of ESI and SEEG results was assessed and classified as fully concordant, partly concordant, or discordant for each patient (Rikir et al., 2014) using the same 36 sublobar localizations.

Full concordance corresponded to a complete matching between ESI results and EZ sublobar localizations i.e. the similar sublobar localization retained (ESI = EZ). Partial concordance corresponded to a partial matching between ESI results and EZ sublobar localizations i.e. at least one similar sublobar localization retained plus other sublobar localizations. The partial concordance encompassed three different conditions: (1) ESI pointed to the full EZ as well as additional sublobar localizations (ESI > EZ); (2) ESI pointed only to some EZ sublobar localizations (ESI < EZ); (3) ESI pointed to some EZ sublobar localizations and to additional localizations outside the EZ (ESI > < EZ). ESI results and EZ were discordant if they had no common sublobar localization (ESI ≠ EZ).

In case of multifocal sources (sources that are spatially distinct, non-contiguous and temporally independent) corresponding to multifocal IIDs, if all sources were included in- but did not fully match the EZ, ESI was considered partially concordant. If none of the sources corresponded to the EZ, they were considered discordant. We further assessed the sublobar anatomical concordance of ECC, MRI and SEEG results according to the same classification as for ESI. Negative MRI cases were considered as “discordant”. ECC and MRI results were classified before and so blinded to SEEG investigations.

2.4. ESI and SEEG anatomical concordance in subgroups

2.4.1. Epilepsy types

According to SEEG results, the epilepsy types were classified in temporal lobe epilepsy (TLE), frontal lobe epilepsy (FLE), posterior epilepsy (PE including the parietal, occipital, occipito-temporal, temporo-occipito-parietal junction regions), operculo-insular epilepsy (OIE) and multifocal epilepsy (MFE).

2.4.2. Presence of a MRI structural lesion

The anatomical concordance was assessed according to the presence of a MRI visible structural lesion. MRI scans were reviewed in a

multidisciplinary case management conference by experienced epileptologists and neuroradiologists in order to assess the presence or not of a structural lesion (positive or negative MRI cases respectively) and then to realize the classification of their sublobar localization.

2.4.3. Aetiology

For operated patients, the aetiology was determined according to the pathological findings, while for non-operated patients it was based on clinical aspects (like pediatric febrile seizure, age at onset of epilepsy, severe trauma) but most frequently on the combination of MRI and electrophysiological findings. All cases were divided in two categories: (i) malformations of cortical development (MCD) or (ii) other including hippocampal sclerosis, cavernoma, post-traumatic and unknown aetiology.

2.4.4. The depth of the EZ (categorized in lateral, medial or medio-lateral)

We determined the depth of EZ using SEEG investigations. Three possible localizations of the EZ were classified: (i): deep localization corresponding to medial localizations in frontal (ventral medial prefrontal, dorsal medial prefrontal, medial premotor, medial central), in temporal (medial anterior temporal, medial posterior temporal), in posterior (medial parietal, medial occipital) and operculo-insular regions; (ii) lateral localization corresponding to the lateral convexity; (iii) medio-lateral localization corresponding to medial and lateral localizations.

2.5. Surgery

Surgical decision was considered during a multidisciplinary case management conference. The volume of resection was based on results from EEG-Video, neuroimaging techniques, ESI, neuropsychological tests and especially from SEEG. Post-surgical outcome at two years was determined for each patient.

2.6. Statistical analysis

Statistical comparisons between subgroups were performed using Fisher's Exact Test (Biostat TGV, Jussieu University). The following H_0 hypothesis were tested: the epilepsy types did not influence the concordance of the ESI and SEEG results; the presence of an MRI structural lesion did not influence the concordance of the ESI and SEEG results; the aetiology did not influence the concordance of the ESI and SEEG results; the depth of the EZ did not influence the concordance of the ESI and SEEG results. Values of $p \leq 0.05$ were considered significant under the null hypothesis that each of the above mentioned factors did not influence the concordance of the ESI and SEEG results.

3. Results

3.1. Patients

74 patients (38 males) were finally analyzed among a cohort of eighty five included patients (81 in Nancy, 4 in Marseille) who were candidates for a SEEG. 11 patients were excluded from the analysis because they eventually did not have the SEEG (8 patients) or because the epileptogenic zone could not be defined using SEEG investigation (3 patients). Mean age at inclusion was 30 years old (15–50). The mean epilepsy duration at inclusion was 17 years (range: 3–45).

Out of 74 patients, 38 (51%) had TLE. 36 (49%) had extratemporal lobe epilepsy: 13 (18%) FLE; 10 (14%) PE; 4 (5%) OIE; 9 (12%) MFE (Table 1).

MRI was positive in 52 (70%) including MCD, cavernoma, hippocampal sclerosis, porencephalic cysts and other abnormalities.

41 patients (55%) had MCD as aetiology.

The epileptogenic zone was medial in 27 (36%); lateral in 13 (18%); medio-lateral in 34 (46%).

3.2. Overall ESI and SEEG anatomical concordance

ESI and EZ were fully concordant in 13/74 (18%) patients (Figs. 2–3; Table 1).

ESI and EZ were partly concordant in 50/74 (67%) (Fig. 4).

Among the partly concordant cases: (i) ESI was entirely included into the EZ in 9 (ESI < EZ); (ii) EZ entirely included ESI in 12 (ESI > EZ); (iii) ESI and EZ partially overlapped in 29 patients (ESI > < EZ) (Table 1).

Finally, 11 of 74 patients (15%) showed a complete anatomical discordance (Fig. 5).

In comparison, ECC and SEEG were fully concordant in 7 (9%), partly concordant in 65 (88%) and discordant in 2 (3%). MRI and SEEG were fully concordant in 12 (16%), partly concordant in 32 (43%) and discordant in 30 (41%).

We also quantified the percentage of ESI results retained according to the inverse problem methods we used (ECD, MUSIC, sLORETA). In our population, we retained ECD, MUSIC and sLORETA respectively in 71.6%, 77% and 62.2%.

3.3. ESI anatomical concordance with SEEG in the subgroups

3.3.1. Epilepsy types

In the 38 TLE patients, ESI results were fully concordant with EZ in 4 (11%), partly concordant in 30 (79%) (Fig. 4) and discordant in 4 patients (10%) (Fig. 5). In the 13 FLE patients, ESI results were fully concordant with EZ in 6 (46%) (Fig. 2), partly concordant in 5 (39%) and discordant in 2 (15%). In the 10 PE patients, ESI results were fully concordant with EZ in 2 (20%), partly concordant in 6 (60%) and discordant in 2 (20%). In the 4 operculo-insular epilepsy patients, ESI results were partly concordant with EZ in 1 (25%) and discordant in 3 (75%). In the 9 multifocal epilepsy patients, ESI results were fully concordant with EZ in 1 (11%), partly concordant in 8 (89%) (Table 1).

Full concordance between ESI results and EZ was statistically higher in frontal lobe epilepsy than in temporal, posterior, operculo-insular and multifocal epilepsy (respectively 46% vs 11%, 20%, 0%, 11%; $p = 0.05$; Figs. 1–2).

3.3.2. The presence of a MRI structural lesion

In the 22 negative MRI patients, ESI results were fully concordant with EZ in 8 (36%) (Fig. 2), partly concordant in 13 (59%) and discordant in 1 (5%). In the 52 positive MRI patients, ESI results were fully concordant with EZ in 5 (10%), partly concordant in 37 (71%) and discordant in 10 (19%) (Table 1).

Full concordance between ESI results and EZ was significantly higher in cases of negative than positive MRI (respectively 36% vs. 10%; $p = 0.01$; Figs. 1–2).

3.3.3. The aetiology

In the 41 MCD patients, ESI results were fully concordant with EZ in 11 (27%), partly concordant in 25 (61%) and discordant in 5 (12%) (Table 1).

In the other aetiologies, ESI results were fully concordant with EZ in only 2 cases (6%), partly concordant in 24 (75%) and discordant in 6 (19%).

Full concordance between ESI results and EZ was significantly higher in MCD than in other aetiologies (respectively 27% vs 6%; $p = 0.03$; Fig. 2).

3.3.4. The depth of the EZ

In the 27 medial EZ patients, ESI results were fully concordant with EZ in 2 (7%), partly concordant in 21 (78%) (Fig. 4) and discordant in 4 (15%) (Fig. 5).

In the 13 lateral EZ patients, ESI results were fully concordant with EZ in 4 (31%), partly concordant in 5 (38%) and discordant in 4 (31%).

In the 34 medio-lateral EZ patients, ESI results were fully

Table 1
Concordance analysis in the different epilepsy subgroups ($N = 74$).

	Fully concordant ($n = 13$)	Partly concordant ($n = 50$)			Discordant ($n = 11$)
		ESI > EZ ($n = 12$)	ESI < EZ ($n = 9$)	ESI > < EZ ($n = 29$)	
Epilepsy types					
TLE ($n = 38$)	11%	24%	10%	45%	10%
FLE ($n = 13$)	46%	23%	8%	8%	15%
PE ($n = 10$)	20%	0%	20%	40%	20%
OIE ($n = 4$)	0%	0%	0%	25%	75%
MFE ($n = 9$)	11%	0%	22%	67%	0%
Presence of a MRI lesion					
Negative MRI ($n = 22$)	36%	14%	18%	27%	5%
Positive MRI ($n = 52$)	10%	17%	10%	44%	19%
Aetiology					
MCD ($n = 41$)	27%	15%	12%	34%	12%
Other ($n = 33$)	6%	18%	12%	45%	19%
Depth of the EZ					
M ($n = 27$)	7%	26%	7%	45%	15%
L ($n = 13$)	31%	31%	0%	7%	31%
ML ($n = 34$)	21%	3%	21%	46%	9%
Surgery					
Operated patients ($n = 44$)	69%	56%			64%
Engel I	100%	68%			57%

TLE, temporal lobe epilepsy; FLE, frontal lobe epilepsy; PE, posterior epilepsy; MFE, multifocal epilepsy; OIE, operculo-insular epilepsy; MCD, malformation of cortical development; M, medial; ML, medio-lateral; L, lateral; EZ, epileptogenic zone.; ESI, electrical source imaging.

concordant with EZ in 7 (21%), partly concordant in 24 (70%) and discordant in 3 (9%) (Table 1).

Full concordance between ESI results and EZ was not significantly different according to the depth of the EZ ($p = 0.15$).

3.4. Overall post-surgical seizure outcome

In the 74 patients, 44 (59%) were operated. At two years after surgery: Among the 13 patients whose ESI results were fully concordant with EZ, all operated patients (9, 100%) were seizure free (Table 1). Among the 61 patients whose ESI results were partly concordant or discordant with EZ, 35 were operated. 23 (66%) were seizure free and 12 (34%) were not seizure free. Patients with a full concordance between ESI and SEEG had a significantly higher chance of being seizure free than patients with partial concordance or discordance (respectively 100% vs 66%, $p = 0.04$, Fisher's Exact Test).

4. Discussion

Localizing the epileptogenic zone in structural focal drug resistant epilepsy is essential before surgical treatment. The strengths of the present study include the prospective design of the study, the large cohort ($n = 74$), the uniform ESI methodology with high density EEG recordings and realistic head models in all patients. Our gold standard was SEEG because it was physiologically meaningful in validating another electro-physiologic investigation, and differentiating the zone of seizure initiation from the zone of propagation (Kahane et al., 2006).

4.1. Overall anatomical concordance

The rate of overall anatomical concordance (full and partial) between ESI and EZ (85%) is consistent with the rates usually found in the literature (Lascano et al., 2016; Brodbeck et al., 2011). These two previous studies used the volume of resection combined to the post-surgical outcomes as reference method. This reference method is clinically meaningful but may overestimate the specificity. Indeed, surgical failure does not necessarily rule out the epileptogenicity of resected tissue, and is indeed often related to its incomplete resection (Ramantani et al., 2013). In the definition of the specificity, any ESI

localization beyond the resection volume in cases of surgical failure is considered as a “true” localization, whereas non-resected areas encompass both the epileptogenic zone and non-epileptogenic regions.

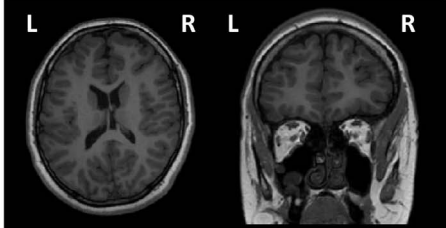
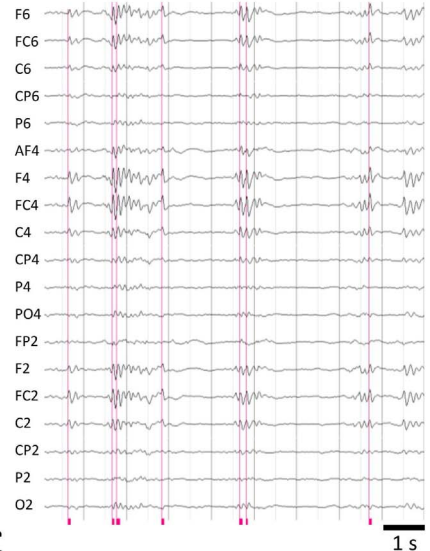
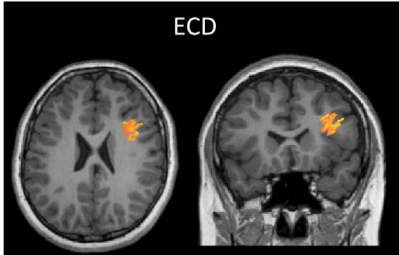
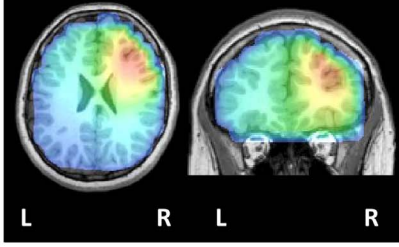
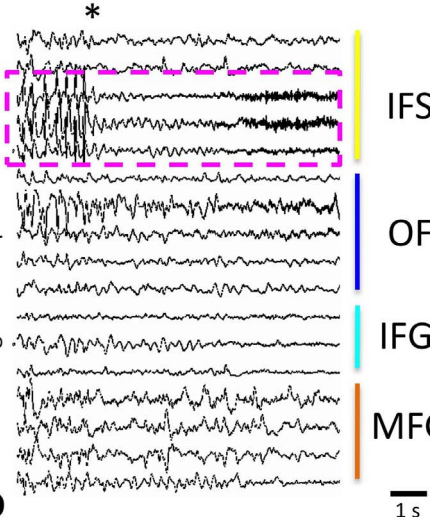
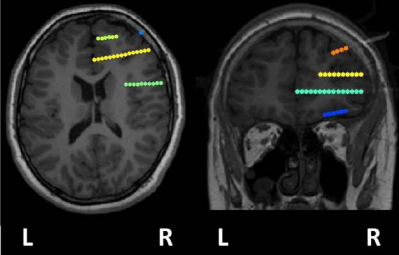
Partial concordance between ESI results and EZ was the most frequent case. When ESI results included the whole EZ and additional sublobar localizations (ESI > EZ), this additional sublobar localizations were physiologically meaningful and corresponded to propagation zones in almost all patients (Fig. 4).

When ESI results involved only a part of the EZ (ESI < EZ), the part of the EZ that was not localized by ESI corresponded to insular, or medial temporal structures (Fig. 5). This can be easily explained by the low observability of the scalp EEG correlates of deep generators.

In the remaining cases, ESI results pointed to some part of the EZ and other additional localizations outside the EZ (ESI > < EZ). This situation can be explained by the combination of the two above described situations. Additional localizations located outside the EZ corresponded either to propagation zones (79%) or to propagation zones and false source localizations (21%). The false source localizations were probably related to methodological problems (non-unique source, non-uniqueness of the inverse problem, sensitivity to initialization procedure, local minimum localizations). In order to investigate if the partly concordant results are closer to the full or discordant results, the use of an automatic data classifier could help.

In our study, the rate of overall (i.e. full plus partial) anatomical concordance between ESI and EZ (85%) was higher than MRI-EZ (59%) and in the same range as the ECC-EZ (97%). The relatively high rate of ECC concordance with EZ may be related to the formulation of several anatomo-electro-clinical hypotheses encompassing both possible seizure onset and propagation zones. This is reflected by the full concordance rate (9%) between ECC hypotheses and EZ that is lower than the overall full concordance rate between ESI results and EZ (18%). The relatively low rate of concordance between MRI and EZ in our study (59%) compared to the values of sensitivity (70%) and specificity (70%) reported by Lascano and colleagues (Lascano et al., 2016) might be related to the higher rate of negative MRI patients in our cohort (30% versus 10%) which were considered as discordant in our study.

Interestingly, in our study all operated patients with full ESI-EZ anatomical concordance were seizure free after 2 years surgical follow-up and had a statistically higher chance ($p = 0.04$) of being seizure free

Presurgical Investigations →	Anatomical localizations →	Sublobar classification			
A Ictal & Inter-ictal Video-EEG recordings	ECC: medial and lateral premotor	●	●	●	●
B High-resolution MRI 	Negative MRI	-	-	-	-
C Inter-ictal HR- EEG recordings Selected electrodes of interest 	ESI analysis ECD  sLORETA 	●	-	-	-
D Ictal SEEG recordings * Right side exploration 	SEEG analysis 	●	-	-	-
		DL Pref	VL Pref	L Prem	OI

(caption on next page)

Fig. 2. Illustration of a patient with a negative MRI and a full sublobar concordance between ESL and EZ. (A) Hypothesis derived from long-term video-EEG recordings and ECC pointing the right dorsolateral prefrontal, the ventrolateral prefrontal, the lateral premotor, and the operculo-insula areas. (B) Negative MRI for structural lesions. (C) 64-Channel EEG recordings showed IID in channels F6, FC6, F4, FC4, C4, F2, FC2, C2 (monopolar montage, common average reference), correlating with sources localized in the depth of the right IFS and in the right MFG (ECD and sLORETA). These anatomic localizations corresponded to a dorsolateral prefrontal sublobar classification. (D) SEEG recordings showed ictal discharges occurring first in the right inferior frontal sulcus (IFS) (pink square). CT-MRI coregistration shows the localization of the depth electrodes of interest. The yellow electrode recorded the activity of IFS. The sublobar classification of EZ was consequently dorsolateral prefrontal. (E) Considering the third column (sub-lobar classification), ESI was fully concordant with SEEG. ESI allowed a restriction of ECC that was validated by SEEG.

ECC, electroclinical correlations; IID, interictal discharge; 64 chEEG, 64 channel EEG; ESI, electrical source imaging; ECD, equivalent current dipole; sLORETA, standardized low-resolution brain electromagnetic tomography; SEEG, stereo-electroencephalography; IFS, inferior frontal sulcus; MFG, middle frontal gyrus; IFG, inferior frontal gyrus; OF, orbito frontal gyrus; EZ, epileptogenic zone; DMPref, dorsal medial prefrontal; DLPref, dorsal lateral prefrontal; L Prem, lateral premotor; VLPref, ventrolateral prefrontal; DLPref, dorsolateral prefrontal; OI, operculo-insula.

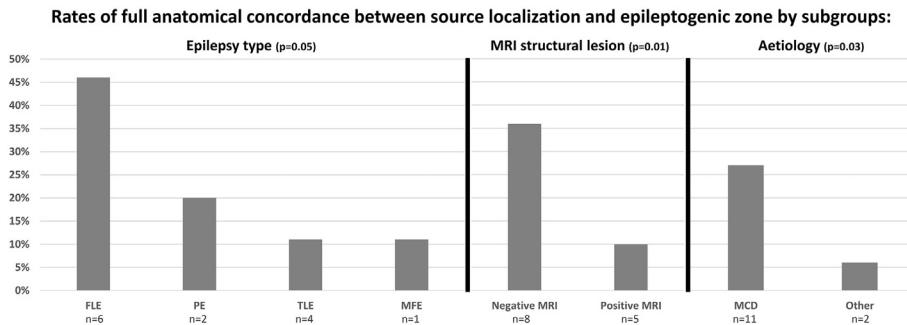


Fig. 3. Rates of full concordance between the electrical source localizations and the epileptogenic zones according to the different subgroups in our population ($n = 74$): epilepsy type, MRI structural lesion and aetiology. The higher rates of full concordance was for frontal lobe epilepsy, negative MRI (non lesional epilepsy) and malformation cortical development.

TLE, temporal lobe epilepsy; FLE, frontal lobe epilepsy; PE, posterior epilepsy; MFE, multifocal epilepsy; MCD, malformation cortical development.

than patients with partial concordance or discordance.

4.2. Subgroups analysis

4.2.1. Epilepsy types

FLE had the highest rate of full concordance (46%). For the first time, we showed that full concordance was statistically higher in FLE than that in TLE, PE, OIE and MFE ($p = 0.05$). This higher rate in FLE is certainly due to the abundance and the high SNR of scalp IID, the geometric parameters of the frontal convexity and the higher rate of MCD. Furthermore, another electric source imaging study derived from scalp-EEG recordings (Gavaret et al., 2006) provided also relevant ESI results in FLE but authors compared ESI results with intracerebral irritative zone defined by SEEG.

Otherwise, most ESI studies have compared the diagnostic value of ESI just between temporal versus extra temporal lobe epilepsy (Brodbeck et al., 2011; Michel et al., 2004; Sperli et al., 2006). It is certainly related to the fact that TLE is the most common localization and is associated with better surgical outcomes (Spencer and Huh, 2008). In our study, the rate (90%) of anatomical concordance (full and partial) in TLE subgroup are in the same range with those obtained by using the volume of resection combined to the post-surgical outcomes as reference method and using ESI derived from 128 to 256 channels (Brodbeck et al., 2011). Although in Brodbeck, the sensitivity in TLE was higher but not statistically different than in extra TLE (91, 7% versus 75%). This small difference between the two groups was probably due to the inclusion of more parietal, occipital and multi-lobe epilepsies than FLE. In our study, the low rate of full concordance in TLE (11% versus 46% in FLE) is probably due to the lack of visible IIDs coming from deep medial sources (Koessler et al., 2015) and the low spatial sampling in basal temporal regions. At the opposite, the high rate of partial concordance in TLE (79%) could be explained by the localization of propagation zone in more lateral structures (Kahane et al., 2006).

To conclude, our results showed that ESI was particularly efficient in FLE which constitutes the second most frequent subtype of localization related refractory epilepsy and which presents lower rates of surgical success than TLE (Spencer and Huh, 2008).

4.2.2. Presence of an MRI structural lesion

Negative MRI had a higher rate (36%) of full concordance than

positive MRI (10%). This difference was statistically significant ($p = 0.01$). This is consistent with two previous studies (Brodbeck et al., 2010; Rikir et al., 2014). The first one (Brodbeck et al., 2010) focused on a small cohort of negative MRI cases and did not have a control group (positive MRI). The second study (Rikir et al., 2014) reported a higher rate of full concordance of ESI results with EZ in cases with negative versus positive MRI. However, that study focused on MCD only. Our current study confirms this result through a large prospective cohort including all possible aetiologies. This result is clinically relevant because negative MRI cases are particularly challenging for pre-surgical investigation of drug-resistant epilepsy and often requires large and multifocal explorations. In such situation, ESI could be used to restrict or confirm the hypothesis defined by ECC and finally to define more precisely the intracerebral electrode positions and decrease their number.

In positive MRI cases, the low rate of full concordance (10%) suggests that the interrelations between the MRI detectable lesion, the irritative and epileptogenic zones are more complex and rarely superimposed (Ramantani et al., 2013; Maillard et al., 2009; Bartolomei et al., 2016). In our study, 13 of 52 positive MRI patients had large brain lesions. In a study (Brodbeck et al., 2009) focusing on large brain lesions, ESI indicated the maximum source of the epileptic activity in the volume of resection in 85%. However, these results could be largely overestimated because the volume of resection is often more important than the epileptogenic zone. Another reason for the low rate of full anatomical concordance was that 12 cases had an epileptogenic zone confined to the medial temporal structures associated with a hippocampal sclerosis. It has been demonstrated (Koessler et al., 2015) that purely medial temporal lobe sources do not generate visible scalp IIDs (negative SNR) and so cannot be readily localizable using ESI.

Among the positive MRI cases with a full anatomical concordance between ESI results and EZ, 4 of 5 had MCD suggesting that in case of MRI visible lesion, ESI provided more accurate localizations in MCD than in other aetiologies.

In MEG study, it was also demonstrated a spatial overlap between the seizure-onset zone and the spiking volume in MR negative case (Jung et al., 2013).

4.2.3. Aetiology

Our study is the first to evaluate the anatomical concordance of ESI and SEEG according to the aetiology. The rate of ESI full concordance in

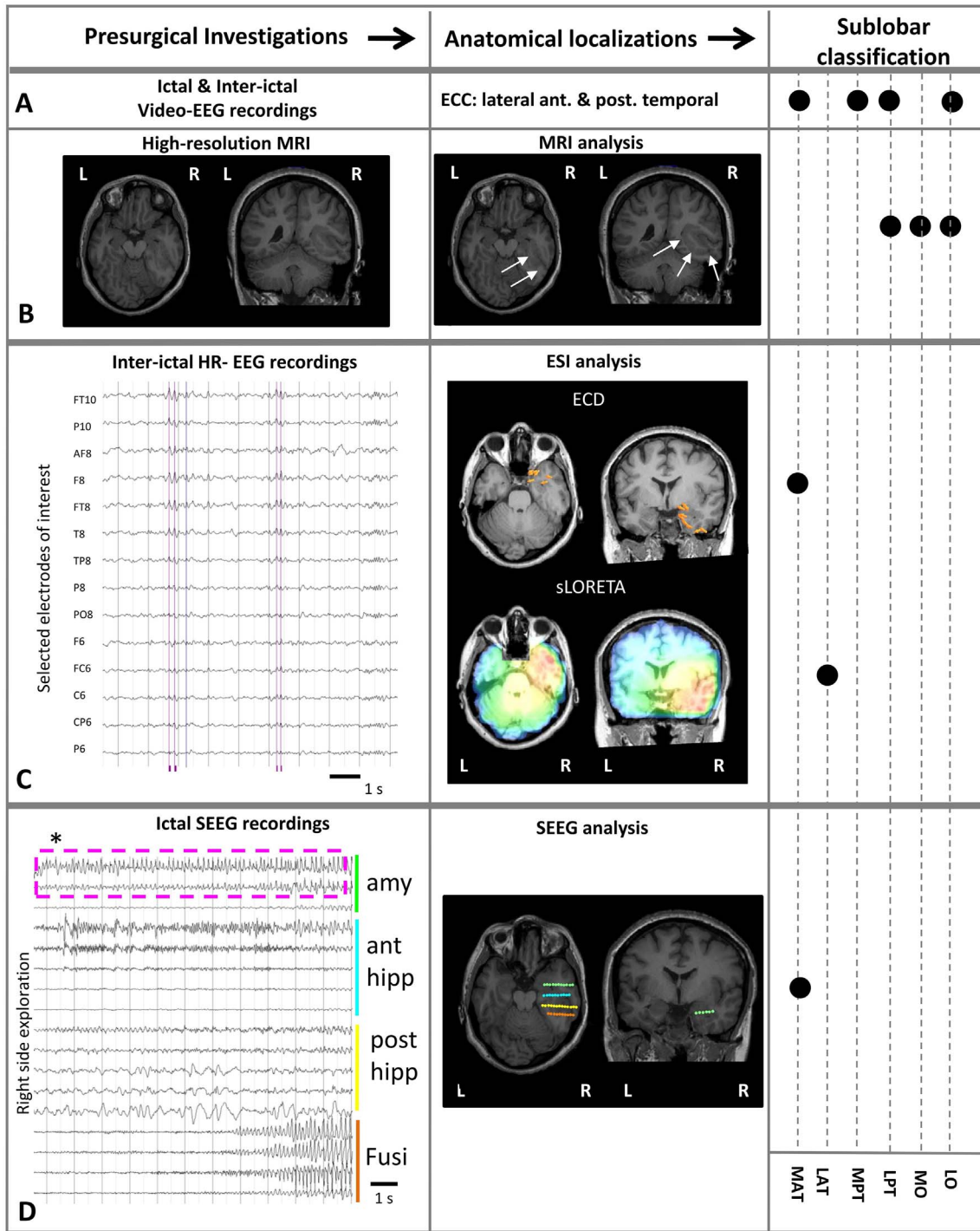


Fig. 4. Illustration of a patient with a positive MRI and a partial sublobar concordance between ESL and EZ ($IZ > EZ$). (A) Hypothesis derived from long-term video-EEG recordings and ECC pointing the right mesial anterior and posterior temporal areas, the right lateral posterior temporal area and the mesial occipital area. (B) MRI showed a closed-lip schizencephaly (classified in MCD etiology) in T3, T4, T5 and O3, O4 and O5 gyri (lateral temporal area and the mesial and lateral occipital areas). (C) 64-Channel EEG recordings showed IID in channels FT10, P10, AF8, F8, FT8, T8 (monopolar montage, common average reference), correlating with sources localized in mesial and basal temporal areas (ECD) and lateral temporal area (sLORETA). These anatomic localizations corresponded to a mesial and lateral anterior temporal sublobar classification. (D) SEEG recordings showed ictal discharges occurring first in the right amygdala (amy) (pink dotted-square). CT-MRI coregistration showed the localization of the depth electrodes of interest. The green electrode recorded the activity of amygdala. The sublobar classification of EZ was consequently mesial anterior temporal. (E) Considering the third column (sub-lobar classification), ESI was partially concordant with SEEG ($IZ > EZ$). This result could be explained by the common lateral anatomical diffusion of IIDs in temporal lobe epilepsy. ECC, electroclinical correlations; IID, interictal discharge; 64 chEEG, 64 channel EEG; ESI, electrical source imaging; ECD, equivalent current dipole; sLORETA, standardized low-resolution brain electromagnetic tomography; SEEG, stereo-electroencephalography; Amy, amygdala; Ant hipp, anterior hippocampus; Post hipp, posterior hippocampus; Fusi, fusiform gyrus; MAT, mesial anterior temporal; LAT, lateral anterior temporal; MPT, mesial posterior temporal; LPT, lateral posterior temporal; MO, mesial occipital; LO, lateral occipital.

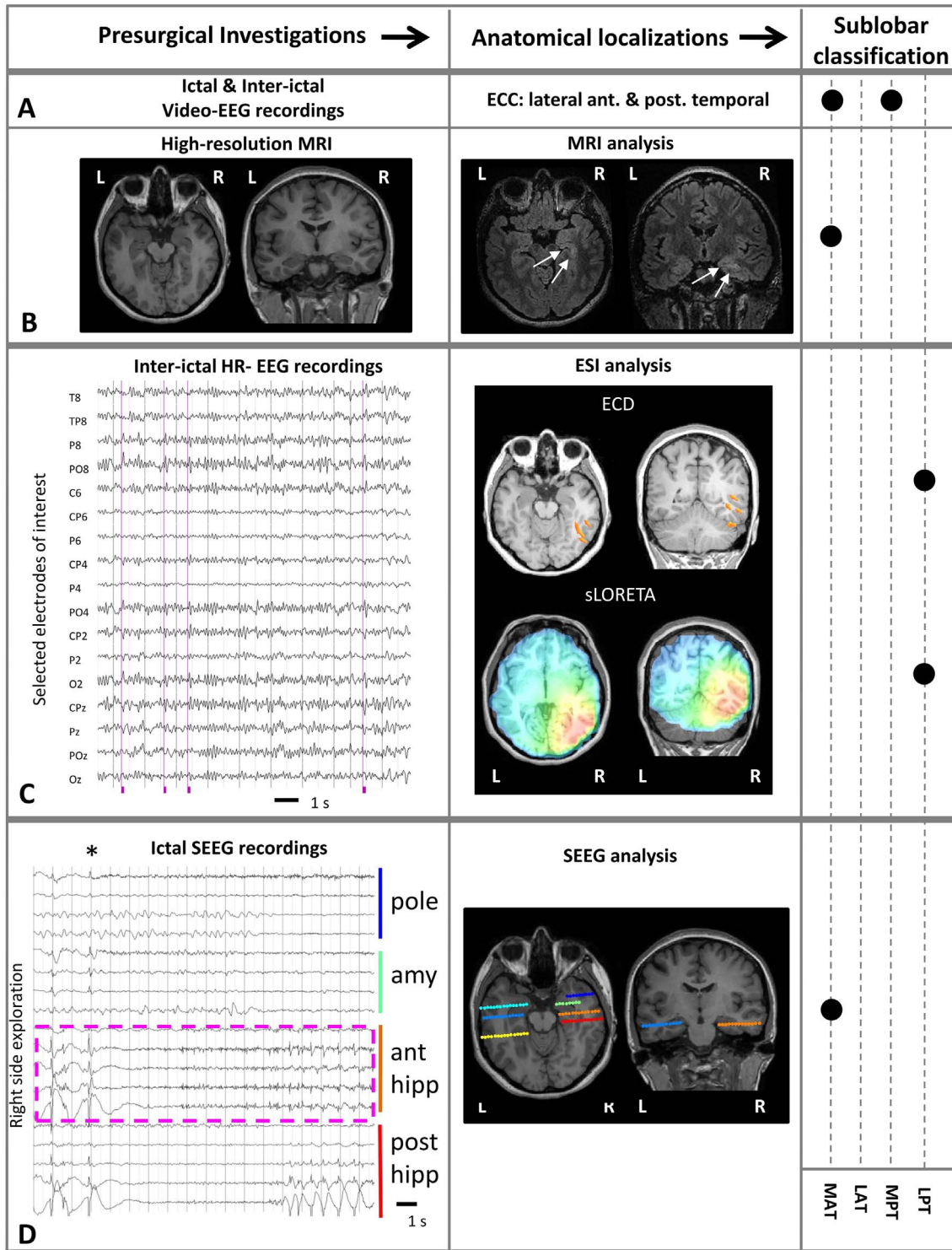


Fig. 5. Illustration of a patient with a positive MRI and a sublobar discordance between ESL and EZ ($IZ \neq EZ$). (A) Hypothesis derived from long-term video-EEG recordings and ECC pointing the right mesial anterior and posterior temporal areas. (B) MRI showed a right hippocampal sclerosis (classified in other etiologies) (mesial anterior temporal area). (C) 64-Channel EEG recordings showed IID in channels P8, PO8, PO4, O2 (monopolar montage, common average reference), correlating with sources localized in lateral posterior temporal area (ECD, sLORETA). (D) SEEG recordings showed ictal discharges occurring first in the right anterior hippocampus (ant hipp) (pink dotted-square). CT-MRI coregistration showed the localization of the depth electrodes of interest. The orange electrode recorded the activity of anterior hippocampus. The sublobar classification of EZ was consequently mesial anterior temporal. (E) Considering the third column (sub-lobar classification), ESI was discordant with SEEG ($IZ \neq EZ$). This result could be explained by non-visible IIDs in scalp EEG originating from the purely mesial part of the temporal lobe.

ECC, electroclinical correlations; IID, interictal discharge; 64 chEEG, 64 channel EEG; ESI, electrical source imaging; ECD, equivalent current dipole; sLORETA, standardized low-resolution brain electromagnetic tomography; SEEG, stereo-electroencephalography; Amy, amygdala; Ant hipp, anterior hippocampus; Post hipp, posterior hippocampus; MAT, mesial anterior temporal; LAT, lateral anterior temporal; MPT, mesial posterior temporal; LPT, lateral posterior temporal.

patients with MCD (27%; $n = 11$), was statistically higher ($p = 0.03$) than in the “others” subgroup (6%, $n = 2$). MCD especially FCD represent a challenge in pre-surgical investigations and are the most frequent aetiology of negative MRI drug-resistant neocortical epilepsy in adults (Hauptman and Mathern, 2012).

The 27% rate of full concordance in MCD reported in the present study is comparable with the 36% reported in Rikir et al., 2014 focusing in MCD ($n = 28$). This 27% rate of concordance better reflects the reality considering the larger size of the current cohort. In this subgroup of MCD, the highest rate of full concordance (31%) was found in FCD. This is consistent with a recent SEEG study reporting a higher rate of overlapping between the irritative zone and the seizure onset zone in FCD than in other aetiologies (Bartolomei et al., 2016).

4.2.4. Depth of the EZ (categorized in lateral, medial or medio-lateral)

In the 27 medial EZ patients, only two (7%) had ESI full concordance with EZ whereas the rate of ESI anatomical full concordance was higher in patients with lateral (31%) and medio-lateral (21%) EZ. This trend was not statistically significant. The difficulty to localize deep epileptic sources with ESI is primarily related to the lack of visibility of their scalp correlates. In a recent simultaneous intracerebral and scalp EEG recording study (Koessler et al., 2015), medial temporal sources were not spontaneously visible on the scalp even if they were shown to contribute to scalp EEG. The only situation that would allow medial ESI results corresponds to the co-activation of medial and lateral sources that produce usually scalp IID with high signal to noise ratio (Lantz et al., 1997; Merlet et al., 1998; Wennberg and Cheyne, 2014; Wennberg et al., 2011; Zumsteg et al., 2005; Merlet and Gotman, 2001). This result is in accordance with a MEG study validated with electrocorticography, where authors found that 75% of the interictal spikes can be localized when generated in the lateral temporal lobe versus only 27% in medial temporal region (Agirre-Arrizubieta et al., 2009).

4.2.5. Anatomical discordance between ESI and SEEG

In the overall cohort, patients with anatomical discordance between ESI results and EZ represented only 15%. Interestingly the rate of discordance between ESI results and EZ is lower than between MRI and EZ (41%). The highest ESI-EZ discordance was found in extra frontal lobe epilepsy (9/11), positive MRI (10/11), aetiologies other than MCD (6/11) and medial depth of the EZ (4/11). Our study is the first to identify subgroups of patients where ESI results should be interpreted with caution. Other or new analysis methods (signal pre-processing, averaging, inverse problem algorithms) should be used for addressing these difficult cases. In this study, it is important to notice that all retained ESI results were covered, at a sublobar resolution, by SEEG implantation. When ESI results pointed out new ROIs (i.e. ROIs not defined by the previous pre-surgical evaluations), intracerebral electrodes were positioned to confirm (or exclude) these ROIs in the definition of EZ.

4.3. Limits and perspectives

Despite the significant size of this whole prospective cohort, the subgroup of FLE included a limited number of patients ($n = 13$), which may theoretically limit the extrapolation of the results to a larger population. The higher accuracy of ESI observed in this subgroup would deserve further confirmation on a larger prospective cohort.

The use of BEM model with 3 isoconductivity compartments and without grey matter constraints on ESI could slightly decrease the accuracy of ESI. In this study, this inaccuracy should be limited due to the sublobar concordance we used. The use of anisotropic FEM model (with 5 or more compartments) could help in term of accuracy particularly in case of large anatomical lesion. Now, a recent study (Biro et al., 2014) including 38 patients demonstrated that for clinical routine application of ESI, the use of highly sophisticated and complex FEM model is not crucial for an accurate source localization.

Concerning the spike classification, automatic clustering method (Nonclercq, 2012; Scherg et al., 2012) could help for classifying different spike clusters (higher coherence across spikes) and for saving time. In our study, the impact of visual spike classification was certainly low because ESI results were defined at a sublobar resolution. In this study, the anatomical extent of ESI results was corresponding to a spike-to-spike and spike type variabilities. This distribution rely mostly on the changes or dynamical changes in the background activity. Finally, the distribution of ESI results was mainly controlled by the noise level and then extrapolated by the use of predefined sublobar localizations.

Finally, we were not able to compare the results of ESI to those of FDG-PET because this prospective study was designed at a time when not all patients had a FDG-PET. The second limit is the comparison of the irritative zone (s) defined by ESI with the EZ defined by SEEG. Physiologically, the irritative zone is more complex and often larger than the epileptogenic zone. This limit is common to all previous large studies on ESI and is mostly related to the difficulty of performing long-term recordings with HR-EEG and therefore recording seizures.

5. Conclusions

Our prospective study showed that ESI of interictal spikes clearly contributes to estimating EZ and can play an important role in non-invasive pre-surgical evaluations by comparison to the invasive reference methods (SEEG). It identified subgroups of patients where ESI has the highest accuracy and would be clinically the most relevant: frontal lobe epilepsy, negative MRI and presence of a MCD.

Key points

- This multicentric prospective study of 74 patients investigated the localizing value of ESI compared to SEEG
- Full anatomical concordance of ESI and SEEG was significantly higher in frontal lobe epilepsy (46%) than in other types of epilepsy (0 to 20%)
- Full anatomical concordance of ESI and SEEG was significantly higher in negative MRI (non lesional epilepsy) (36%) than in positive MRI (10%)
- Full anatomical concordance of ESI and SEEG was significantly higher in malformation cortical development (27%) than in other aetiologies (6%)
- ESI is a relevant method that accurately estimates the epileptogenic zone especially in the subgroups which are the most difficult challenges in epilepsy surgery

Acknowledgements

This study was supported by the French Ministry of Health (PHRC 17-05, 2009) and the regional council of Lorraine.

Disclosure

None of the authors has any conflict of interest to disclose. We confirm that we have read the Journal's position on issues involved in ethical publication and affirm that this report is consistent with those guidelines.

References

- Agirre-Arrizubieta, Z., Huiskamp, G.J., Ferrier, C.H., et al., 2009. Interictal magnetoencephalography and the irritative zone in the electrocorticogram. *Brain* 132, 3060–3071.
- Bartolomei, F., Trébuchon, A., Bonini, F., et al., 2016. What is the concordance between the seizure onset zone and the irritative zone? A SEEG quantified study. *Clin. Neurophysiol.* 127, 1157–1162.
- Biro, G., Spinelli, L., Vulliémou, S., et al., 2014. Head model and electrical source imaging: a study of 38 epileptic patients. *Neuroimage Clin.* 16, 77–83.

- Brodbeck, V., Lascano, A.M., Spinelli, L., et al., 2009. Accuracy of EEG source imaging of epileptic spikes in patients with large brain lesions. *Clin. Neurophysiol. Off. J. Int. Fed. Clin. Neurophysiol.* 120, 679–685.
- Brodbeck, V., Spinelli, L., Lascano, A.M., et al., 2010. Electrical source imaging for pre-surgical focus localization in epilepsy patients with normal MRI. *Epilepsia* 51, 583–591.
- Brodbeck, V., Spinelli, L., Lascano, A.M., et al., 2011. Electroencephalographic source imaging: a prospective study of 152 operated epileptic patients. *Brain J. Neurol.* 134, 2887–2897.
- Gavaret, M., Badier, J.-M., Marquis, P., et al., 2004. Electric source imaging in temporal lobe epilepsy. *J. Clin. Neurophysiol. Off. Publ. Am. Electroencephalogr. Soc.* 21, 267–282.
- Gavaret, M., Badier, J.-M., Marquis, P., et al., 2006. Electric source imaging in frontal lobe epilepsy. *J. Clin. Neurophysiol. Off. Publ. Am. Electroencephalogr. Soc.* 23, 358–370.
- Gavaret, M., Trébuchon, A., Bartolomei, F., et al., 2009. Source localization of scalp-EEG interictal spikes in posterior cortex epilepsies investigated by HR-EEG and SEEG. *Epilepsia* 50, 276–289.
- Hauptman, J.S., Mathern, G.W., 2012. Surgical treatment of epilepsy associated with cortical dysplasia: 2012 update. *Epilepsia* 53 (Suppl. 4), 98–104.
- Kahane, P., Landré, E., Minotti, L., et al., 2006. The Bancaud and Talairach view on the epileptogenic zone: a working hypothesis. *Epileptic Disord. Int. Epilepsy J. Videotape* 8 (Suppl. 2), S16–26.
- Kaiboriboon, K., Lüders, H.O., Hamaneh, M., et al., 2012. EEG source imaging in epilepsy—practicalities and pitfalls. *Nat. Rev. Neurol.* 8, 498–507.
- Koessler, L., Maillard, L., Benhadid, A., et al., 2007. Spatial localization of EEG electrodes. *Neurophysiol. Clin. Clin. Neurophysiol.* 37, 97–102.
- Koessler, L., Benhadid, A., Maillard, L., et al., 2008. Automatic localization and labeling of EEG sensors (ALLES) in MRI volume. *NeuroImage* 41, 914–923.
- Koessler, L., Benar, C., Maillard, L., et al., 2010. Source localization of ictal epileptic activity investigated by high resolution EEG and validated by SEEG. *NeuroImage* 51, 642–653.
- Koessler, L., Cecchin, T., Colnat-Coulbois, S., et al., 2015. Catching the invisible: mesial temporal source contribution to simultaneous EEG and SEEG recordings. *Brain Topogr.* 28, 5–20.
- Lantz, G., Ryding, E., Rosén, I., 1997. Dipole reconstruction as a method for identifying patients with mesolimbic epilepsy. *Seizure* 6, 303–310.
- Lascano, A.M., Perneger, T., Vulliemoz, S., et al., 2016. Yield of MRI, high-density electric source imaging (HD-ESI), SPECT and PET in epilepsy surgery candidates. *Clin. Neurophysiol. Off. J. Int. Fed. Clin. Neurophysiol.* 127, 150–155.
- Maillard, L., Koessler, L., Colnat-Coulbois, S., et al., 2009. Combined SEEG and source localisation study of temporal lobe schizencephaly and polymicrogyria. *Clin. Neurophysiol. Off. J. Int. Fed. Clin. Neurophysiol.* 120, 1628–1636.
- Merlet, I., Gotman, J., 2001. Dipole modeling of scalp electroencephalogram epileptic discharges: correlation with intracerebral fields. *Clin. Neurophysiol. Off. J. Int. Fed. Clin. Neurophysiol.* 112, 414–430.
- Merlet, I., Garcia-Larrea, L., Ryvlin, P., et al., 1998. Topographical reliability of mesio-temporal sources of interictal spikes in temporal lobe epilepsy. *Electroencephalogr. Clin. Neurophysiol.* 107, 206–212.
- Michel, C.M., Lantz, G., Spinelli, L., et al., 2004. 128-channel EEG source imaging in epilepsy: clinical yield and localization precision. *J. Clin. Neurophysiol. Off. Publ. Am. Electroencephalogr. Soc.* 21, 71–83.
- Mosher, J.C., Lewis, P.S., Leahy, R.M., 1992. Multiple dipole modeling and localization from spatio-temporal MEG data. *IEEE Trans. Biomed. Eng.* 39, 541–557.
- Nonclercq, A., 2012. Foulon M. Verheulpen D et al. Cluster-based spike detection algorithm adapts to interpatient and inpatient variation in spike morphology. *J. Neurosci Methods.* 210 (259–65).
- Pascual-Marqui, R.D., 2002. Standardized low-resolution brain electromagnetic tomography (sLORETA): technical details. *Methods Find. Exp. Clin. Pharmacol.* 24 Suppl D, 5–12.
- Plummer, C., Harvey, A.S., Cook, M., 2008. EEG source localization in focal epilepsy: where are we now? *Epilepsia* 49, 201–218.
- Ramantani, G., Koessler, L., Colnat-Coulbois, S., et al., 2013. Intracranial evaluation of the epileptogenic zone in regional infrasylvian polymicrogyria. *Epilepsia* 54, 296–304.
- Rikir, E., Koessler, L., Gavaret, M., et al., 2014. Electrical source imaging in cortical malformation-related epilepsy: a prospective EEG-SEEG concordance study. *Epilepsia* 55, 918–932.
- Scherg, M., Ebersole, J.S., 1993. Models of brain sources. *Brain Topogr.* 5, 419–423.
- Scherg, M., Ille, N., Weckesser, D., et al., 2012. Fast evaluation of interictal spikes in long-term EEG by hyper-clustering. *Epilepsia* 53, 1196–1204.
- Spencer, S., Huh, L., 2008. Outcomes of epilepsy surgery in adults and children. *Lancet Neurol.* 7, 525–537.
- Sperli, F., Spinelli, L., Seeck, M., et al., 2006. EEG source imaging in pediatric epilepsy surgery: a new perspective in presurgical workup. *Epilepsia* 47, 981–990.
- Wennberg, R., Cheyne, D., 2014. EEG source imaging of anterior temporal lobe spikes: validity and reliability. *Clin. Neurophysiol. Off. J. Int. Fed. Clin. Neurophysiol.* 125, 886–902.
- Wennberg, R., Valiante, T., Cheyne, D., 2011. EEG and MEG in mesial temporal lobe epilepsy: where do the spikes really come from? *Clin. Neurophysiol. Off. J. Int. Fed. Clin. Neurophysiol.* 122, 1295–1313.
- Zumsteg, D., Friedman, A., Wennberg, R.A., et al., 2005. Source localization of mesial temporal interictal epileptiform discharges: correlation with intracranial foramen ovale electrode recordings. *Clin. Neurophysiol. Off. J. Int. Fed. Clin. Neurophysiol.* 116, 2810–2818.