



HAL
open science

Usefulness of the Hook knife in flexible endoscopic myotomy for Zenker's diverticulum

Olivier Rouquette, Armando Abergel, Aurélien Mulliez, Laurent Poincloux

► To cite this version:

Olivier Rouquette, Armando Abergel, Aurélien Mulliez, Laurent Poincloux. Usefulness of the Hook knife in flexible endoscopic myotomy for Zenker's diverticulum. *World Journal of Gastrointestinal Endoscopy*, 2017, 9 (8), 10.4253/wjge.v9.i8.411 . hal-01659009

HAL Id: hal-01659009

<https://hal.science/hal-01659009>

Submitted on 21 Dec 2018

HAL is a multi-disciplinary open access archive for the deposit and dissemination of scientific research documents, whether they are published or not. The documents may come from teaching and research institutions in France or abroad, or from public or private research centers.

L'archive ouverte pluridisciplinaire **HAL**, est destinée au dépôt et à la diffusion de documents scientifiques de niveau recherche, publiés ou non, émanant des établissements d'enseignement et de recherche français ou étrangers, des laboratoires publics ou privés.



Distributed under a Creative Commons Attribution - NonCommercial 4.0 International License

World Journal of *Gastrointestinal Endoscopy*

World J Gastrointest Endosc 2017 August 16; 9(8): 346-427



REVIEW

- 346 Terahertz endoscopic imaging for colorectal cancer detection: Current status and future perspectives
Doradla P, Joseph C, Giles RH

MINIREVIEWS

- 359 Use and barriers to chromoendoscopy for dysplasia surveillance in inflammatory bowel disease
Shukla R, Salem M, Hou JK
- 368 Evolution of stereoscopic imaging in surgery and recent advances
Schwab K, Smith R, Brown V, Whyte M, Jourdan I
- 378 Endoscopic ultrasonography - emerging applications in hepatology
Magalhães J, Monteiro S, Xavier S, Leite S, de Castro FD, Cotter J

ORIGINAL ARTICLE

Retrospective Cohort Study

- 389 Clinical impact of confocal laser endomicroscopy in the management of gastrointestinal lesions with an uncertain diagnosis
Robles-Medranda C, Vargas M, Ospina J, Puga-Tejada M, Valero M, Soria M, Bravo G, Robles-Jara C, Lukashok HP

- 396 Impact of laparoscopic liver resection on bleeding complications in patients receiving antithrombotics
Fujikawa T, Kawamoto H, Kawamura Y, Emoto N, Sakamoto Y, Tanaka A

Retrospective Study

- 405 Correlation of abnormal histology with endoscopic findings among mycophenolate mofetil treated patients
Izower MA, Rahman M, Molmenti EP, Bhaskaran MC, Amin VG, Khan S, Sultan K
- 411 Usefulness of the Hook knife in flexible endoscopic myotomy for Zenker's diverticulum
Rouquette O, Abergel A, Mulliez A, Poincloux L

CASE REPORT

- 417 Russell body gastritis with Dutcher bodies evaluated using magnification endoscopy
Yorita K, Iwasaki T, Uchita K, Kuroda N, Kojima K, Iwamura S, Tsutsumi Y, Ohno A, Kataoka H
- 425 Simultaneous Courvoisier's and double duct signs
Agrawal S, Vohra S

ABOUT COVER

Editorial Board Member of *World Journal of Gastrointestinal Endoscopy*, Jorg G Albert, MD, PhD, Associate Professor, Department of Internal Medicine I, Johann Wolfgang Goethe-University Hospital, D-60590 Frankfurt, Germany

AIM AND SCOPE

World Journal of Gastrointestinal Endoscopy (*World J Gastrointest Endosc*, *WJGE*, online ISSN 1948-5190, DOI: 10.4253) is a peer-reviewed open access (OA) academic journal that aims to guide clinical practice and improve diagnostic and therapeutic skills of clinicians.

WJGE covers topics concerning gastroscopy, intestinal endoscopy, colonoscopy, capsule endoscopy, laparoscopy, interventional diagnosis and therapy, as well as advances in technology. Emphasis is placed on the clinical practice of treating gastrointestinal diseases with or under endoscopy.

We encourage authors to submit their manuscripts to *WJGE*. We will give priority to manuscripts that are supported by major national and international foundations and those that are of great clinical significance.

INDEXING/ABSTRACTING

World Journal of Gastrointestinal Endoscopy is now indexed in Emerging Sources Citation Index (Web of Science), PubMed, and PubMed Central.

FLYLEAF

I-III Editorial Board

EDITORS FOR THIS ISSUE

Responsible Assistant Editor: *Xiang Li*
Responsible Electronic Editor: *Ya-Jing Lu*
Proofing Editor-in-Chief: *Lian-Sheng Ma*

Responsible Science Editor: *Fang-Fang Ji*
Proofing Editorial Office Director: *Jin-Lei Wang*

NAME OF JOURNAL
World Journal of Gastrointestinal Endoscopy

ISSN
 ISSN 1948-5190 (online)

LAUNCH DATE
 October 15, 2009

FREQUENCY
 Monthly

EDITORS-IN-CHIEF
Atsushi Imagawa, PhD, Director, Doctor, Department of Gastroenterology, Mitoyo General Hospital, Kan-onji, Kagawa 769-1695, Japan

Juan Manuel Herrerias Gutierrez, PhD, Academic Fellow, Chief Doctor, Professor, Unidad de Gestión Clínica de Aparato Digestivo, Hospital Universitario Virgen Macarena, Sevilla 41009, Spain

EDITORIAL BOARD MEMBERS
 All editorial board members resources online at <http://www.wjgnet.com>

www.wjgnet.com/1948-5190/editorialboard.htm

EDITORIAL OFFICE
 Xiu-Xia Song, Director
World Journal of Gastrointestinal Endoscopy
 Baishideng Publishing Group Inc
 7901 Stoneridge Drive, Suite 501, Pleasanton, CA 94588, USA
 Telephone: +1-925-2238242
 Fax: +1-925-2238243
 E-mail: editorialoffice@wjgnet.com
 Help Desk: <http://www.f6publishing.com/helpdesk>
<http://www.wjgnet.com>

PUBLISHER
 Baishideng Publishing Group Inc
 7901 Stoneridge Drive, Suite 501,
 Pleasanton, CA 94588, USA
 Telephone: +1-925-2238242
 Fax: +1-925-2238243
 E-mail: bpgoffice@wjgnet.com
 Help Desk: <http://www.f6publishing.com/helpdesk>
<http://www.wjgnet.com>

PUBLICATION DATE
 August 16, 2017

COPYRIGHT
 © 2017 Baishideng Publishing Group Inc. Articles published by this Open-Access journal are distributed under the terms of the Creative Commons Attribution Non-commercial License, which permits use, distribution, and reproduction in any medium, provided the original work is properly cited, the use is non commercial and is otherwise in compliance with the license.

SPECIAL STATEMENT
 All articles published in journals owned by the Baishideng Publishing Group (BPG) represent the views and opinions of their authors, and not the views, opinions or policies of the BPG, except where otherwise explicitly indicated.

INSTRUCTIONS TO AUTHORS
<http://www.wjgnet.com/bpg/gerinfo/204>

ONLINE SUBMISSION
<http://www.f6publishing.com>

Retrospective Study

Usefulness of the Hook knife in flexible endoscopic myotomy for Zenker's diverticulum

Olivier Rouquette, Armando Abergel, Aurélien Mulliez, Laurent Poincloux

Olivier Rouquette, Armando Abergel, Laurent Poincloux, Department of Digestive and Hepatobiliary Diseases, CHU Estaing Clermont-Ferrand, 63003 Clermont-Ferrand, France

Armando Abergel, Laurent Poincloux, ISIT, UMR 6284 CNRS Université d'Auvergne, 63003 Clermont-Ferrand, France

Aurélien Mulliez, Biostatistics Unit, DRCI, CHU Gabriel Montpied Clermont-Ferrand, 63003 Clermont-Ferrand, France

Author contributions: Rouquette O, Mulliez A and Poincloux L collected and analyzed the data; Rouquette O and Poincloux L drafted the manuscript; Abergel A revised the manuscript for important intellectual content; all authors have read and approved the final version to be published.

Institutional review board statement: The study was reviewed and approved by the CHU Clermont-Ferrand Institutional Review Board, reference 2016 CE/91.

Informed consent statement: All study participants, or their legal guardian, provided informed written consent prior to study enrollment.

Conflict-of-interest statement: All authors disclosed no financial relationships relevant to this publication.

Data sharing statement: No additional data are available.

Open-Access: This article is an open-access article which was selected by an in-house editor and fully peer-reviewed by external reviewers. It is distributed in accordance with the Creative Commons Attribution Non Commercial (CC BY-NC 4.0) license, which permits others to distribute, remix, adapt, build upon this work non-commercially, and license their derivative works on different terms, provided the original work is properly cited and the use is non-commercial. See: <http://creativecommons.org/licenses/by-nc/4.0/>

Manuscript source: Invited manuscript

Correspondence to: Olivier Rouquette, MD, Department of Digestive and Hepatobiliary Diseases, CHU Estaing Clermont-Ferrand, 1, place Lucie et Raymond Aubrac, 63003 Clermont-

Ferrand, France. orouquette@chu-clermontferrand.fr
Telephone: +33-4-73750523
Fax: +33-4-73750524

Received: February 2, 2017
Peer-review started: February 7, 2017
First decision: April 18, 2017
Revised: May 13, 2017
Accepted: May 30, 2017
Article in press: May 31, 2017
Published online: August 16, 2017

Abstract**AIM**

To investigate the outcome of flexible endoscopic myotomy performed with the Hook knife in patients with symptomatic Zenker's diverticulum (ZD).

METHODS

All consecutive patients treated for ZD at our institution between 7/2012 and 12/2016 were included. The flexible endoscopic soft diverticuloscope-assisted technique with endoclips placement and Hook knife myotomy were performed in all patients. Here we report a retrospective review of prospectively collected data. Demographics, dysphagia score (Dakkak and Bennett), associated symptoms and adverse events were collected pre-procedure, at 2 and 6 mo post-procedure, and at the end of the follow-up period. Clinical success was defined as at least 1-point improvement in dysphagia score and a residual dysphagia score ≤ 1 , with no need for reintervention. Dysphagia scores were compared before treatment and at end-of-follow-up using the Wilcoxon test.

RESULTS

Twenty-four patients were included. Mean size of ZD was 3.0 cm (range 2-8 cm). Mean number of sessions

was 1.17/patient (range 1-3 sessions). Overall clinical success was 91.7%. Two adverse events (8.3%) occurred, and both were managed conservatively. No bleeding or perforation was reported. Mild pain was reported by 9 patients (37.5%). Median hospital stay was 1 d (range 1-6). Median follow-up was 19.5 mo (range 6-53). Mean \pm SD dysphagia score was 2.25 ± 0.89 before treatment and decreased to 0.41 ± 0.92 at end-of-follow-up ($P < 0.001$). Regurgitation and cough dropped from 91.7% and 50% to 12.5% and 0% at the end of follow-up, respectively. Recurrence was observed in 3 patients, and all 3 were symptom-free after one more session.

CONCLUSION

The Hook knife, used in the soft diverticuloscope-assisted technique setting, is efficient and safe for treatment of ZD.

Key words: Zenker's diverticulum; Flexible endoscopy

© **The Author(s) 2017.** Published by Baishideng Publishing Group Inc. All rights reserved.

Core tip: Zenker's diverticulum can cause uncomfortable symptoms such as dysphagia, regurgitation and cough, and sometimes weight loss or aspiration pneumonia. Soft diverticuloscope-assisted flexible myotomy is used worldwide and has proven to be safe and efficient. In terms of adverse events, perforation remains the major concern. The most effective tool for performing myotomy in this setting has yet to be determined. Here we treated 24 patients with the Hook knife, resulting in 91.7% overall success, a 13% recurrence rate, and only 2 mild adverse events reported.

Rouquette O, Abergel A, Mulliez A, Poincloux L. Usefulness of the Hook knife in flexible endoscopic myotomy for Zenker's diverticulum. *World J Gastrointest Endosc* 2017; 9(8): 411-416 Available from: URL: <http://www.wjgnet.com/1948-5190/full/v9/i8/411.htm> DOI: <http://dx.doi.org/10.4253/wjge.v9.i8.411>

INTRODUCTION

Zenker's diverticulum (ZD), an acquired rare condition that typically occurs in the elderly^[1], is a pulsion diverticulum developing on the posterior wall of the esophagus through Killian's triangle. ZD development is thought to be caused by dysfunction of the cricopharyngeal muscle resulting in increased intraesophageal pressure^[2]. ZD can cause symptoms such as dysphagia, regurgitations, or chronic cough. Weight loss and aspiration pneumonia are potentially severe complications. Treatment basically consists in myotomy of the cricopharyngeal muscle. Endoscopic myotomy was introduced decades ago, has been widely evaluated since, and is now considered a first-line treatment option^[3]. In Europe, the mini-invasive flexible endoscopic soft diverticuloscope-

Table 1 The Dakkak and Bennett score of dysphagia^[7]

Grade 0	No dysphagia
Grade 1	Solids
Grade 2	Semi-solids
Grade 3	Liquids
Grade 4	Aphagia

assisted technique with endoclip(s) placement, as described by Huberty *et al.*^[4], is common practice and has proven safe and effective. However, various tools are used to perform the myotomy. Submucosal dissection knives have been described in this indication, and appear to be safe and effective^[5]. Myotomy must be continued deep enough to improve clinical symptoms, but dissection must be limited to muscle fibers to avoid perforation. The key issue is where to stop the myotomy^[6]. The Hook knife (Olympus endotherapy, Tokyo, Japan) is designed with a distal tip consisting in a 5 mm-long, rotatable, hook-shaped knife, allowing pulling tissues before cutting. We posit that the Hook knife is the most appropriate tool for this intervention. Here we report short and mid-term outcome and adverse events of soft diverticuloscope-assisted flexible endoscopic myotomy with the Hook knife.

MATERIALS AND METHODS

Population

All consecutive patients treated at our institution by flexible endoscopy for symptomatic ZD between July 2012 and December 2016, and with at least 6 mo of follow-up at December 2016, were included in the study. We performed a retrospective review of prospectively collected data. Demographics, dysphagia score, symptoms, outcome, and adverse events were recorded. The Dakkak and Bennett dysphagia score was used (Table 1)^[7]. All patients were seen as outpatients before and at 2 and 6 mo after the procedure, and were asked to phone anytime in case of recurrence. At the end of the follow-up period, all patients were interviewed by phonecall.

This study was conducted according to the ethical principles of the Declaration of Helsinki and in compliance with good clinical practice. Informed consent was obtained from all patients. This study was reviewed and approved by our center's Institutional Review Board, reference 2016/CE 91.

Endoscopic treatment

All patients were treated by a single endoscopist (Olivier Rouquette). All procedures were performed under general anesthesia, with orotracheal intubation, in supine position. All patients were administered amoxicillin-clavulanic acid prophylaxis beforehand. Anticoagulant therapy was discontinued 5 d before procedure and bridged with low molecular-weight heparin. Low-dose aspirin was continued. Other antiplatelet agents were

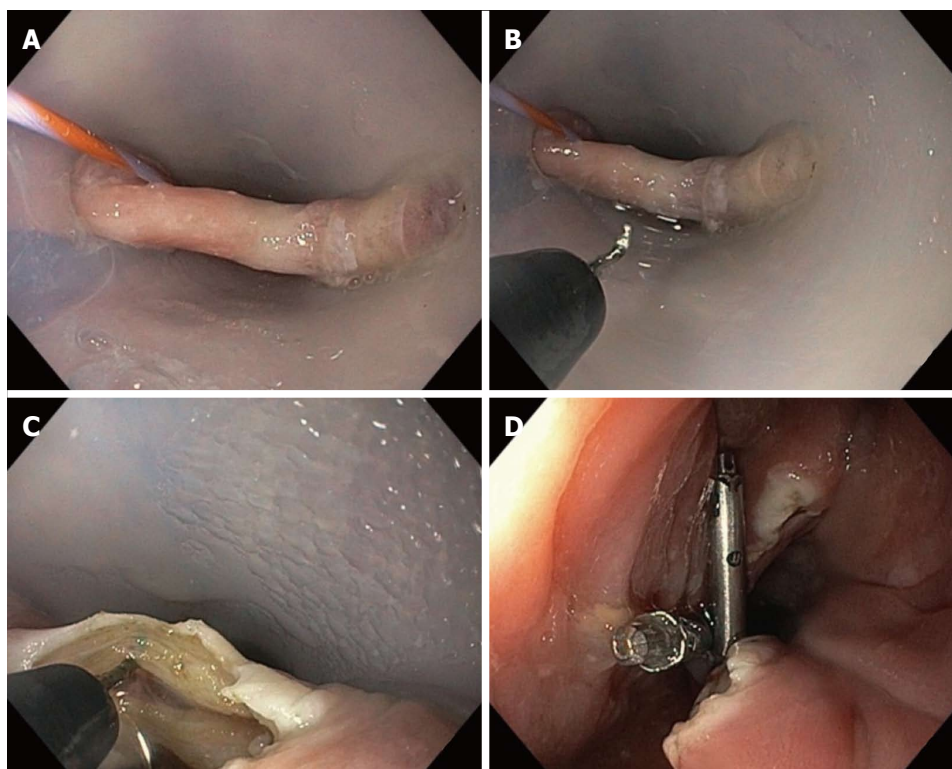


Figure 1 Endoscopic procedure. A: Soft diverticuloscope in place, affording optimal exposure. Esophageal lumen is identified by the guidewire; B: The Hook knife is locked in 12 o'clock position; C: After initial incision, myotomy is performed, pulling the muscle fibers up before cutting; D: End of procedure, with 2 endoclips in place.

discontinued 5 d before procedure and replaced with low-dose aspirin. Anticoagulant and antiplatelet therapies were resumed on the day after the procedure.

Figure 1 describes the endoscopic procedure. First, a complete upper endoscopy, using a standard gastroscope (GIF H180, GIF H190; Olympus, Tokyo, Japan), is performed to rule out any other esophageal or gastric disorder that could explain dysphagia. A 0.035-inch guidewire is advanced in the gastric lumen and left in place for later identification of the esophageal lumen. Then, the soft diverticuloscope (ZDO-22-30, Cook Endoscopy, Winston-Salem, NC) is fitted over the gastroscope and advanced gently, after lubrication, as far as the black mark is located roughly near the incisor line. The endoscope is then slowly withdrawn to allow visualization of the diverticulum and adjust diverticuloscope position across the septum, which is then seen as a bridge, and optimal exposure of the operative site. Once septum exposure is good, myotomy of the cricopharyngeal muscle is performed with the Hook knife (Endocut Q mode, effect 3, 120 W cutting, 40 W soft coagulation; VIO 300; ERBE, Tübingen, Germany). The hook is locked in 12 o'clock position. The initial incision is performed at the top of the bridge. Then, the cricopharyngeal myotomy is continued progressively downward, using the hook to gently pull the muscle fibers before cutting, allowing precise dissection. Myotomy is stopped when the muscle fibers are completely cut. Finally, anterior ZD and posterior esophageal walls are cut up to 5 mm above the bottom of the diverticulum, and one or more

endoclips are placed to prevent delayed perforation or bleeding. If no complication is suspected, oral semi-liquid diet is resumed and patients are discharged from hospital on day one post-surgery.

Primary endpoint was clinical success. Recurrence and adverse event rates were also investigated. Clinical success was defined as at least a 1-point improvement in dysphagia score and a residual dysphagia score ≤ 1 , with no need for reintervention. Recurrence was defined as dysphagia score > 1 after initial clinical success. Any event resulting in readmission or unexpected length of hospital stay post-surgery (> 1 d) was regarded as an adverse event. Bleeding was considered an adverse event if any medical or endoscopic reintervention was needed. Perforation was defined as presence of cervical subcutaneous crepitus, cervical abscess, or free air on computed tomography.

Statistical analysis

The statistical review of the study was performed by a biomedical statistician. Characteristics of the study population are expressed as proportion and means \pm SD. The Wilcoxon matched-pairs signed-rank test was used to compare pre- vs post-treatment dysphagia scores comparison. Statistical significance was set at $P < 0.05$ (two-sided). Statistics were computed using Stata12 (Stata Corp, College Station, TX).

RESULTS

The study included 24 consecutive patients [18 men

Table 2 Patient characteristics n (%)

Characteristics	
Variable	n = 24
Male	18 (75)
Median age (yr)	77
Mean time from onset of symptoms (mo)	18.5
Dysphagia score before treatment	
Grade 1	6 (25)
Grade 2	7 (29)
Grade 3	10 (42)
Grade 4	1 (4)
Weight loss	11 (46)
Mean size of diverticula (cm ± SD)	3.0 ± 1.63

(75%), median age 77 years (range 44-90 years)]. Before procedure, seven patients were treated with anticoagulant therapy and 6 with antiplatelet agents. ZD diagnosis was based on esophagogastrosocopy in 12 (50%) patients, and/or barium swallow in 18 (75%) patients or computed tomography in 3 patients. Mean size of ZD was 3.0 cm (2-8 cm). Mean time from onset of symptoms was 18.5 mo. Four patients had a previous rigid endoscopic treatment (CO₂ laser). All patients presented with dysphagia. Other symptoms included regurgitation (n = 22, 91.7%), chronic cough (n = 12, 50%) and aspiration pneumonia (n = 2, 8.3%). Patient characteristics are reported in Table 2.

A total of 28 endoscopic procedures were performed in our 24 patients (mean 1.17 procedures per patient): One procedure in 21 patients, two procedures in two patients and three procedures in one patient. Diverticuloscope insertion and good septum exposition were achieved in all patients. One or two endoclips were placed in all patients. Median follow-up was 19.5 mo (6-53).

Clinical success was obtained in 21 (87.5%) patients after the first procedure. Two patients developed recurrence, at 4 and 8 mo post-procedure, respectively: One was successfully treated with a second session, the other declined any reintervention. Initial failure was observed in 3 (12.5%) patients: One patient with an 8-cm ZD was contraindicated for general anesthesia for a second session, and two patients with ≤ 3 cm ZD underwent a second procedure. Symptoms resolved in both patients, but one experienced recurrence 6 mo later, which was successfully treated by a third session. Overall clinical success was obtained in 22/24 patients (91.7%). Overall recurrence rate was 13% (3/23). Mean ± SD dysphagia score was 2.25 ± 0.89 before treatment and decreased to 0.25 ± 0.74 at end-of-follow-up (P < 0.001). At end-of-follow-up, 19/22 (86.4%) and 12/12 patients were free from regurgitation and cough, respectively. Among 11 patients with preoperative weight loss, 10 (90.9%) regained weight (mean +4.2 kg) at two months post-treatment. Median time to recurrence was 6 mo. Figure 2 and Table 3 summarize treatment outcome. Overall adverse effect rate was 8.3%: Two patients developed

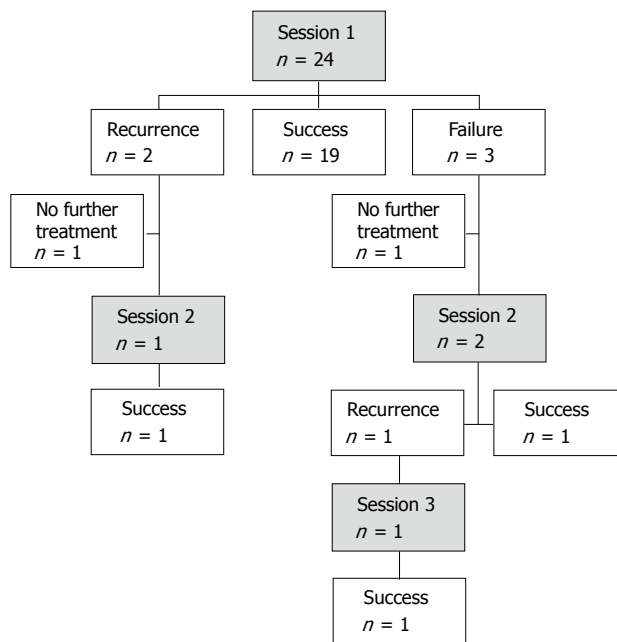


Figure 2 Clinical outcome of endoscopic myotomy.

fever with elevated CRP, without evidence of perforation on CT scan with contrast agent ingestion. Conservative management with antibiotics was successful in both patients, who were discharged from hospital on day 4 and day 6 post-procedure, respectively. No perforation or post-procedural bleeding was recorded. Nine patients (37.5%) reported mild pain, lasting a median 3 d. All of them were treated with acetaminophen as outpatients. Mild bleeding during myotomy occurred in two (8.3%) patients and was treated by soft coagulation applied with a Coagrasper (Olympus endotherapy, Tokyo, Japan). These two patients were not treated with anticoagulant or antiplatelet agents, and both were discharged from hospital on day 1 post-procedure. One asymptomatic patient died of unrelated cause during follow-up, at 29 mo after myotomy. Median hospital stay was 1 d (1-6).

DISCUSSION

Open surgery is mainly considered after endotherapy failure or for large diverticula^[2,8]. Along with endoscopic stapling, flexible endoscopic myotomy is a first-line treatment option for symptomatic ZD. The use of a soft diverticuloscope stabilizes the endoscope and provides better exposure of the septum, resulting in a lower adverse events rate^[9]. We perform diverticulotomy in supine position in order to increase the stability of the gastroscope, which may slip out of the diverticuloscope if the patient is lying in left lateral position. Most authors agree with placing endoclips at the end of the procedure to prevent delayed complications^[4]. Nevertheless, various tools are used to perform the myotomy: Argon plasma coagulation has been practically abandoned as it needs multiple procedures and carries a high complication rate^[10], whereas favorable outcome is

Table 3 Dysphagia score before treatment and at end-of-follow-up

Before treatment	End of the follow-up period			
	0	1	2	3
1	<i>n</i> = 6	<i>n</i> = 0	<i>n</i> = 0	<i>n</i> = 0
2	<i>n</i> = 7	<i>n</i> = 0	<i>n</i> = 0	<i>n</i> = 0
3	<i>n</i> = 7	<i>n</i> = 1	<i>n</i> = 1	<i>n</i> = 1
4	<i>n</i> = 1	<i>n</i> = 0	<i>n</i> = 0	<i>n</i> = 0
Total	21	1	1	1

reported with the use of needle-knife^[11], submucosal dissection knives^[5], a Zimmon needle (Cook endoscopy, Winston-Salem, NC)^[4], or endoscopic scissors^[12,13]. The SB-knife[®] (Sumimoto Bakelite Ltd, Tokyo, Japan), an endoscopic scissor, seems to be safe, fast and effective^[13]. Myotomy with the SB-knife consists in cutting the full thickness of the septum without individualization of muscle fibers, anterior and posterior walls of the diverticulum. It remains unclear where dissection should be stopped in this setting. The most reliable device for diverticulotomy has yet to be determined^[14]. A major concern is perforation risk if dissection extends too deeply. The Hook knife provides advantages for this purpose, as its design allows pulling the muscle fibers upward before cutting. Extensive myotomy can be achieved with complete visual control, and the risk of coagulation-induced injury risk may be reduced by pulling tissues upward instead of pushing downward with most other tools. Unlike previous series on submucosal dissection knives^[5], we believe that these devices-but not the Hook knife-do not confer an optimal visualization, especially in the final steps of the myotomy, before cutting the posterior ZD and anterior esophageal walls, whereas pulling with the hook is helpful to assess the nature and amount of tissue before cutting.

Our 91.7% overall clinical success rate is in line previous papers. A 95% overall success rate was reported in a series of 46 patients treated with the Hook knife^[15]. However, in this series, initial clinical success was 100%, but recurrence rate was high at 30%, leading to frequent retreatment (mean 1.39 sessions/patient). This might be explained by the interruption of the myotomy 5 to 10 mm above the bottom of the diverticulum, regardless of complete cut of muscle fibers and diverticulum size. Indeed, post-treatment size ≥ 10 mm is suspected to be a risk factor for recurrence at 48 mo^[8]. Moreover, diverticula were larger (median size 42 mm) than in our series. Although diverticulum size was not significantly associated with recurrence rate, pre-treatment size ≥ 50 mm may be an independent factor for clinical failure at 6 mo^[8], and this could also explain such a high recurrence rate. Lower (from 50%) or higher (to 100%) success rates have been reported before^[8,16,17]. With the Zimmon needle, overall success, recurrence and complication rates were respectively 84%, 23.1% and 2.2%^[4]. With a needle knife, overall

success rates ranged from 69%^[8] to 84%^[17] at 6 mo, recurrence rates from 15%^[8] to 30%^[17], and adverse event rates from 3%^[8] to 23%^[17]. Laquière *et al.*^[5] described the use of the Dual-knife[®] (Olympus endotherapy, Tokyo, Japan) and the HybridKnife[®] (Erbe elektromedizin GmbH, Tuebingen, Germany), with an overall success rate, recurrence rate and complication rate of respectively 91.7%, 14% and 7.1%. Endoscopic myotomy with the SB-knife[®] resulted in a 87.1% overall success rate, a 6.5% recurrence rate, and a 3.2% complication rate, with a limited median follow-up of 7 mo^[13]. These variations might be related to how tightly clinical success was defined: Dysphagia score ≤ 1 ^[4], or < 1 ^[8] have been proposed. Moreover, composite scores investigating respiratory symptoms or hoarseness and their weekly frequency have been included in clinical success definition by some authors^[9], resulting in lower success rates. Here however, in our definition of clinical success, no further intervention was needed, which means patients were satisfied with the functional result on the ZD-related symptoms. The initial failure rate of 12.5% and the recurrence rate of 13% are consistent with previous studies given the small mean size of ZD in our series; septotomy length ≤ 25 mm is suspected to be an independent prognostic factor for clinical failure and recurrence (HR = 6.34 at 6 mo and 2.20 at 48 mo)^[8].

Only two patients experienced mild adverse events. No bleeding was reported, when anticoagulant or antiplatelet therapy was resumed the day post-procedure in more than half of patients. No perforation occurred. Moreover, after all but two procedures, patients were discharged from hospital on day 1, demonstrating the safety of this technique.

Retrospective analysis, single-center design, and lack of comparison with other devices are limitations to this study. Even with a minimal follow-up of 6 mo, our median follow-up of 19.5 mo might still be too short to investigate long-term recurrences: Even though another study reported a mean time to recurrence after diverticulotomy with the Hook knife of 4.4 mo^[15], recurrence rate may be underestimated, as success rate for dysphagia decreased between 6 and 48 mo in a large study including 89 patients with a 24-mo minimum follow-up^[8].

Conclusion

The Hook knife is a reliable tool for flexible endoscopic soft diverticuloscope-assisted myotomy in patients with symptomatic Zenker's diverticula. It is safe and efficient and could therefore be considered a device of choice in this indication. Larger comparative studies, with extended follow-up, are needed to determine which tool is the best.

COMMENTS

Background

Zenker's diverticulum can cause dysphagia, regurgitations, and sometimes life-

threatening complications. Endoscopic treatment is a first line option.

Research frontier

Flexible endoscopic myotomy can be performed with various tools. Safety (perforation risk) and efficacy are major concerns. The ideal tool has yet to be determined.

Innovations and breakthroughs

The Hook knife allows precise dissection of muscle fibers and complete myotomy in a safe way, by pulling up tissues before cutting. It results in high clinical success rate and low complication and recurrence rates.

Applications

The Hook knife may be a device of choice for flexible endoscopic diverticulotomy.

Peer-review

The manuscript was well written and helpful.

REFERENCES

- 1 **Law R**, Katzka DA, Baron TH. Zenker's Diverticulum. *Clin Gastroenterol Hepatol* 2014; **12**: 1773-1782; quiz e111-e112 [PMID: 24055983 DOI: 10.1016/j.cgh.2013.09.016]
- 2 **Prisman E**, Genden EM. Zenker diverticulum. *Otolaryngol Clin North Am* 2013; **46**: 1101-1111 [PMID: 24262962 DOI: 10.1016/j.otc.2013.08.011]
- 3 **Aiolfi A**, Scolari F, Saino G, Bonavina L. Current status of minimally invasive endoscopic management for Zenker diverticulum. *World J Gastrointest Endosc* 2015; **7**: 87-93 [PMID: 25685264 DOI: 10.4253/wjge.v7.i2.87]
- 4 **Huberty V**, El Bacha S, Blero D, Le Moine O, Hassid S, Devière J. Endoscopic treatment for Zenker's diverticulum: long-term results (with video). *Gastrointest Endosc* 2013; **77**: 701-707 [PMID: 23394840 DOI: 10.1016/j.gie.2012.12.008]
- 5 **Laquière A**, Grandval P, Arpurt JP, Boulant J, Belon S, Aboukheir S, Laugier R, Penaranda G, Curel L, Boustière C. Interest of submucosal dissection knife for endoscopic treatment of Zenker's diverticulum. *Surg Endosc* 2015; **29**: 2802-2810 [PMID: 25475517 DOI: 10.1007/s00464-014-3976-x]
- 6 **Sakai P**. Endoscopic myotomy of Zenker's diverticulum: lessons from 3 decades of experience. *Gastrointest Endosc* 2016; **83**: 774-775 [PMID: 26975283 DOI: 10.1016/j.gie.2015.10.031]
- 7 **Dakkak M**, Bennett JR. A new dysphagia score with objective validation. *J Clin Gastroenterol* 1992; **14**: 99-100 [PMID: 1556441]
- 8 **Costamagna G**, Iacopini F, Bizzotto A, Familiari P, Tringali A, Perri V, Bella A. Prognostic variables for the clinical success of flexible endoscopic septotomy of Zenker's diverticulum. *Gastrointest Endosc* 2016; **83**: 765-773 [PMID: 26344886 DOI: 10.1016/j.gie.2015.08.044]
- 9 **Costamagna G**, Iacopini F, Tringali A, Marchese M, Spada C, Familiari P, Mutignani M, Bella A. Flexible endoscopic Zenker's diverticulotomy: cap-assisted technique vs. diverticuloscope-assisted technique. *Endoscopy* 2007; **39**: 146-152 [PMID: 17327973 DOI: 10.1055/s-2007-966140]
- 10 **Rabenstein T**, May A, Michel J, Manner H, Pech O, Gossner L, Ell C. Argon plasma coagulation for flexible endoscopic Zenker's diverticulotomy. *Endoscopy* 2007; **39**: 141-145 [PMID: 17327972 DOI: 10.1055/s-2007-966164]
- 11 **Evrard S**, Le Moine O, Hassid S, Devière J. Zenker's diverticulum: a new endoscopic treatment with a soft diverticuloscope. *Gastrointest Endosc* 2003; **58**: 116-120 [PMID: 12838237 DOI: 10.1067/mge.2003.311]
- 12 **Neumann H**, Löffler S, Rieger S, Kretschmer C, Nägel A. Endoscopic therapy of Zenker's diverticulum using a novel endoscopic scissor - the Clutch Cutter device. *Endoscopy* 2015; **47** Suppl 1 UCTN: E430-E431 [PMID: 26397855 DOI: 10.1055/s-0034-1392658]
- 13 **Battaglia G**, Antonello A, Realdon S, Cesarotto M, Zanatta L, Ishaq S. Flexible endoscopic treatment for Zenker's diverticulum with the SB Knife. Preliminary results from a single-center experience. *Dig Endosc* 2015; **27**: 728-733 [PMID: 25975384 DOI: 10.1111/den.12490]
- 14 **Ishaq S**, Hassan C, Antonello A, Tanner K, Bellisario C, Battaglia G, Anderloni A, Correale L, Sharma P, Baron TH, Repici A. Flexible endoscopic treatment for Zenker's diverticulum: a systematic review and meta-analysis. *Gastrointest Endosc* 2016; **83**: 1076-1089.e5 [PMID: 26802196 DOI: 10.1016/j.gie.2016.01.039]
- 15 **Brueckner J**, Schneider A, Messmann H, Gölder SK. Long-term symptomatic control of Zenker diverticulum by flexible endoscopic mucomyotomy with the hook knife and predisposing factors for clinical recurrence. *Scand J Gastroenterol* 2016; **51**: 666-671 [PMID: 26807604 DOI: 10.3109/00365521.2015.1130165]
- 16 **Christiaens P**, De Roock W, Van Olmen A, Moons V, D'Haens G. Treatment of Zenker's diverticulum through a flexible endoscope with a transparent oblique-end hood attached to the tip and a monopolar forceps. *Endoscopy* 2007; **39**: 137-140 [PMID: 17657700 DOI: 10.1055/s-2006-945118]
- 17 **Vogelsang A**, Preiss C, Neuhaus H, Schumacher B. Endotherapy of Zenker's diverticulum using the needle-knife technique: long-term follow-up. *Endoscopy* 2007; **39**: 131-136 [PMID: 17041841 DOI: 10.1055/s-2006-944657]

P- Reviewer: Adachi Y, Skok P, Yonem O, Yu B **S- Editor:** Ji FF
L- Editor: A **E- Editor:** Lu YJ





Published by **Baishideng Publishing Group Inc**
7901 Stoneridge Drive, Suite 501, Pleasanton, CA 94588, USA
Telephone: +1-925-223-8242
Fax: +1-925-223-8243
E-mail: bpgoffice@wjgnet.com
Help Desk: <http://www.f6publishing.com/helpdesk>
<http://www.wjgnet.com>

