



HAL
open science

Diagnosis and Management of Spontaneously Recanalized Coronary Thrombus Guided by Optical Coherence Tomography Lessons From the French “Lotus Root” Registry

Geraud Souteyrand, Mathieu Valladier, Nicolas Amabile, François Derimay, Brahim Harbaoui, Pierre Leddet, Pierre Barnay, Guilhem Malcles, Aurélien Mulliez, Colin Berry, et al.

► **To cite this version:**

Geraud Souteyrand, Mathieu Valladier, Nicolas Amabile, François Derimay, Brahim Harbaoui, et al.. Diagnosis and Management of Spontaneously Recanalized Coronary Thrombus Guided by Optical Coherence Tomography Lessons From the French “Lotus Root” Registry. *Circulation Journal*, 2017, 82 (3), pp.783-790. 10.1253/circj.CJ-17-0810 . hal-01656166

HAL Id: hal-01656166

<https://hal.science/hal-01656166>

Submitted on 21 Dec 2018

HAL is a multi-disciplinary open access archive for the deposit and dissemination of scientific research documents, whether they are published or not. The documents may come from teaching and research institutions in France or abroad, or from public or private research centers.

L’archive ouverte pluridisciplinaire **HAL**, est destinée au dépôt et à la diffusion de documents scientifiques de niveau recherche, publiés ou non, émanant des établissements d’enseignement et de recherche français ou étrangers, des laboratoires publics ou privés.



Distributed under a Creative Commons Attribution - NonCommercial 4.0 International License



Diagnosis and Management of Spontaneously Recanalized Coronary Thrombus Guided by Optical Coherence Tomography

— Lessons From the French “Lotus Root” Registry —

Géraud Souteyrand, MD; Mathieu Valladier, MD; Nicolas Amabile, MD;
François Derimay, MD; Brahim Harbaoui, MD; Pierre Leddet, MD; Pierre Barnay, MD;
Guilhem Malcles, MD; Aurelien Mulliez, MD; Colin Berry, MD, PhD;
Romain Eschalier, MD, PhD; Nicolas Combaret, MD; Pascal Motreff, MD, PhD

Background: Spontaneous reanalyzed coronary thrombus (SRCT) has been reported in autopsy series, but little is known about SRCT, and it is potentially under-diagnosed in clinical practice.

Methods and Results: SRCT identified on OCT were included in a French multicenter series, the Lotus Root French Registry. A total of 34 SRCT were identified on OCT in 33 patients (23 male; median age, 56 years; IQR, 52–65 years); 23/33 patients (70%) presented with angina pectoris and/or dyspnea. Three angiographic aspects were distinguished retrospectively: braided, pseudo-dissected, and hazy. Stenosis severity on quantitative coronary analysis varied between 11% and 100% (median, 45%), whereas the reduction in lumen area on OCT varied between 20% and 92% (median, 68%). A typical “lotus root” aspect was confirmed on OCT, consisting of multiple circular concave-edged channels of varying size, numbering between 3 and 12 depending on the slice, separated by smooth-edged septa of high luminosity without posterior attenuation. OCT also served to guide treatment, with stenting in 91% of cases. During the 17-month follow-up 91% of patients had excellent evolution. One death and 3 ACS events occurred.

Conclusions: In this large SRCT cohort, angiography had limited diagnostic value whereas OCT could be used to define disease characteristics and guide treatment of lesions inducing angina pectoris and/or silent myocardial ischemia. OCT-guided management was associated with good prognosis.

Key Words: Optical coherence tomography; Recanalized coronary thrombus

Spontaneously recanalized coronary thrombus (SRCT) has long been recognized on histopathology as being defined by multiple communicating channels divided by thin septa.¹ SRCT is difficult to diagnose in vivo. Angiographic signs (fuzzy intraluminal image without a significant stenosis) lack diagnostic specificity. High-resolution intracoronary imaging techniques such as intravascular ultrasound (IVUS) or optical coherence tomography (OCT) enable routine study of coronary artery lumen and wall. By referring to histopathology data, SRCT can be diagnosed on intracoronary imaging.^{1–3} Even when not apparently obstructive, SRCT lesions may induce symptomatic ischemia

in viable myocardium, confirmed in case reports and small series using fractional flow reserve (FFR), magnetic resonance imaging (MRI) or scintigraphy.^{3–5} OCT, with its high resolution, seems to be the diagnostic method of choice.

The aim of this study was therefore to analyze the angiographic characteristics and determine the relative contribution of OCT in the diagnosis and management of SRCT.

Methods

Subjects

Between March 2011 and June 2016, 33 patients were

Received August 9, 2017; revised manuscript received October 11, 2017; accepted October 25, 2017; released online December 1, 2017 Time for primary review: 27 days

Cardiology Department, CHU Clermont-Ferrand, CNRS (G.S., M.V., G.M., R.E., N.C., P.M.), ISIT-CAVITI, UMR 6284 (G.S., M.V., G.M., R.E., N.C., P.M.), Biostatistics Unit (A.M.), University of Clermont Auvergne (UCA), Clermont-Ferrand; Cardiology Department, Institut Mutualiste Montsouris, Paris (N.A.); Cardiology Department, Bron University Hospital Center, Bron (F.D.); Cardiology Department, Lyon La Croix Rousse Hospital Center, Lyon (B.H.); Cardiology Department, Haguenu Hospital Center, Haguenu (P.L.); Cardiology Department, Avignon Hospital Center, Avignon (P.B.), France; and Institute of Cardiovascular and Medical Sciences, University of Glasgow, Glasgow (C.B.), UK

Mailing address: Géraud Souteyrand, MD, Department of Cardiology, University Hospital of Clermont-Ferrand, 63000 Clermont-Ferrand, France. E-mail: gsouteyrand@chu-clermontferrand.fr

ISSN-1346-9843 All rights are reserved to the Japanese Circulation Society. For permissions, please e-mail: cj@j-circ.or.jp

Table 1. Clinical and Paraclinical Data	
	n=33
Age (years)	56 (52–65)
Male	23 (69.7)
Cardiovascular risk factors and history	
Family history of coronary disease	8 (24.2)
Active smoking	22 (66.7)
Diabetes	7 (21.2)
Hypercholesterolemia	17 (51.5)
High blood pressure	18 (54.5)
Obesity (BMI >30 kg/m ²)	8 (24.2)
ACS/Interval (years)	11 (33.3)/9 (6–16)
Atrial fibrillation	2 (6.1)
Inflammatory disease (HIV+)	3 (9.1) (2(6.1))
Symptoms	
Isolated angina pectoris	12 (36.4)
Isolated dyspnea	7 (21.2)
Angina pectoris+dyspnea	4 (12.1)
None	10 (30.3)
Discovery circumstances	
STEMI ACS	2 (6.1)
Non-STEMI ACS	8 (24.2)
Stable angina pectoris	11 (33.3)
Silent ischemia	11 (33.3)
Post-heart-graft follow-up	1 (3)
Treatment at diagnosis	
Simple/dual antiplatelets	13 (39.4)/8 (24.2)
No anti-thrombotic treatment	12 (36.4)
ECG abnormalities	
None	9 (26.5)
Q wave	17 (50)
ST elevation	2 (5.9)
ST depression	3 (8.8)
Negative T wave	16 (47.1)
TTE	
LVEF (%)	55 (50–60)
Segmental kinetic disorder†	26 (76.5)
Concordant affected segments	23 (88.5); $\kappa^{\dagger}=0.79$; P<0.001
Discordant affected segments	3 (11.5)
Positive functional tests	15 (44.1)

Data given as n (%) or median (IQR). †Concordance or discordance of segmental kinetic disorder topography was assessed with respect to the coronary artery affected by the recanalized thrombus. κ index of concordance between segmental and coronary involvement. ACS, acute coronary syndrome; BMI, body mass index; ECG, electrocardiogram; LVEF, left ventricular ejection fraction; NSTEMI, non-ST-segment elevation myocardial infarction; STEMI, ST-segment elevation myocardial infarction; TTE, transthoracic electrocardiography.

recruited in 15 hospitals in France in a multicenter prospective observational study entitled “Lotus Root French Registry” (31,500 angioplasties during the period of inclusion). The inclusion criterion was SRCT confirmed on OCT following ambiguity, or suspected diagnosis on angiography. Diagnostic and therapeutic management decisions were left to operator discretion.

Patient characteristics (risk factors and history), electrocardiographic signs, left ventricle (LV) function on ultra-

Table 2. Angiography of Recanalized Coronary Thrombi	
	n=34
General data	
Site of SRCT	
Anterior interventricular	14 (41.2)
Circumflex	3 (8.8)
Right coronary	17 (50)
Coronary disorder other than SRCT	16 (47.1)
History of coronary occlusion/interval (years)	7 (21)/ 13.75 (6–17)
Angiographic aspect	
Braided	21 (61.8)
Pseudo-dissected	10 (29.4)
Veiled/hazy	2 (5.9)
Occlusion	1 (2.9)
Quantitative data	
Lesion length (mm)	26.9 (16.8–38)
Reference diameter (mm)	3.05 (2.7–3.5)
Flow	
TIMI 0	1 (2.9)
TIMI 1	0 (0)
TIMI 2	2 (5.9)
TIMI 3	31 (91.2)
Stenosis on QCA	45.5 (36–60)
>50%	9 (26.5)
>70%	3 (8.8)
Qualitative data	
Arterial bifurcation (n=33)	
Upstream of lesion	27 (81.8)
Downstream of lesion	22 (66.7)
Collaterals originating from lesion	25 (73.5)
Retrograde collaterals	2 (5.9)
Delayed contrast medium elimination (n=28)	3 (10.7)

Data given as n (%) or median (IQR). QCA, quantitative coronary angiography; SRCT, spontaneously recanalized coronary thrombus; TIMI, Thrombolysis in Myocardial Infarction.

sound and prior ischemia screening results were collated.

Angiography

Coronary angiography was performed following each center’s standard of care in line with international guidelines.⁶ Angiograms, in DICOM format, were analyzed a posteriori in the Clermont-Ferrand University Hospital Center. Images were calibrated according to catheter dimensions. Qualitative and quantitative data were assessed. Stenosis was assessed on quantitative coronary angiography (QCA) as percentage diameter, using a standard technique based on a program with an automatic detection algorithm (Centricity Cardiology, CA1000, General Electrics, USA) determining the arterial wall and lesion length. Lesion aspect was also described.

OCT

OCT (or optical frequency-domain imaging, OFDI) was acquired using Saint Jude Medical (Lightlab Imaging, St. Jude Medical, Saint Paul, MN, USA) or Terumo (Lunawave[®], fastview[®], Terumo Europe, Leuven, Belgium) consoles, following the international expert consensus

standards.⁷ Images from each center, in DICOM format, were analyzed in the Clermont-Ferrand University Hospital Core Lab, calibrated according to transverse fiber area. Lesion length was measured on longitudinal reconstruction. Lumen and vessel contours were traced manually. In the case of multiple channels, lumen area was calculated by summing the channel areas. Minimum lumen area (MLA) was determined in mm² after segmental analysis every mm along the lumen length. Cross-sectional area (reference lumen CSA) was calculated as the mean of the up- and down-stream lumen areas. Percentage stenosis was calculated as $(1 - \text{MLA}/\text{reference lumen CSA})$.

Angiographic and OCT lesion analyses were in each case performed by 2 independent observers. In the case of disagreement, a third, blind, observer performed re-analysis.

Treatment Decision and Follow-up

The decision to perform stenting following OCT was made at the operator's discretion.

Patients were followed up until the end of the study. The pre-specified study endpoint consisted of major adverse cardiac and cerebral events (MACCE), a composite criterion consisting of death from cardiac causes, ischemic or hemorrhagic stroke, myocardial infarction, or need for myocardial revascularization. Death from all causes, hemorrhagic events (\geq Bleeding Academic Research Consensus 2) and LV ejection fraction (LVEF) at baseline were also recorded.

Statistical Analysis

Data are reported as frequency and percentage for qualitative variables, and as median (IQR) for quantitative variables. Qualitative variables were compared pairwise on chi-squared test (or Fisher exact test as appropriate). Group means were compared on Student test for paired groups, analysis of variance for >2 groups, or Kruskal-Wallis test for non-normal distributions. Quantitative variables were compared pairwise using Pearson (or Spearman as appropriate) correlation coefficient. Concordance between OCT and angiography was assessed on κ coefficient for qualitative, and correlation coefficient for quantitative, variables.

Results

A total of 34 SRCT were studied in 33 patients (1 patient had 2 SRCT) and the clinical characteristics are listed in **Table 1**.

Three patients (9%) had a history of inflammatory illness, including 2 with HIV infection. Eleven patients had a history of prior coronary artery disease (CAD), including 7 previously treated with percutaneous coronary intervention (PCI). The median interval between ischemic event and diagnosis of SRCT was 9 years (IQR, 6–16 years).

The initial diagnosis at admission was acute coronary syndrome (ACS), $n=10$ (30%); $n=8$ with non-ST-segment elevation myocardial infarction [NSTEMI], 24%; and $n=2$ with STEMI, 6%); stable angina, $n=11$ (33%); silent ischemia, $n=11$ (33%); or scheduled diagnostic evaluation in a patient with prior coronary artery bypass graft (CABG), $n=1$ (3%). In the 2 patients with STEMI, the culprit lesion was not the recanalized coronary thrombus.

Twenty-three patients (70%) were symptomatic (angina, 36%; dyspnea, 21%; associated angina and dyspnea, 12%). Ten were asymptomatic, including 9 with positive non-

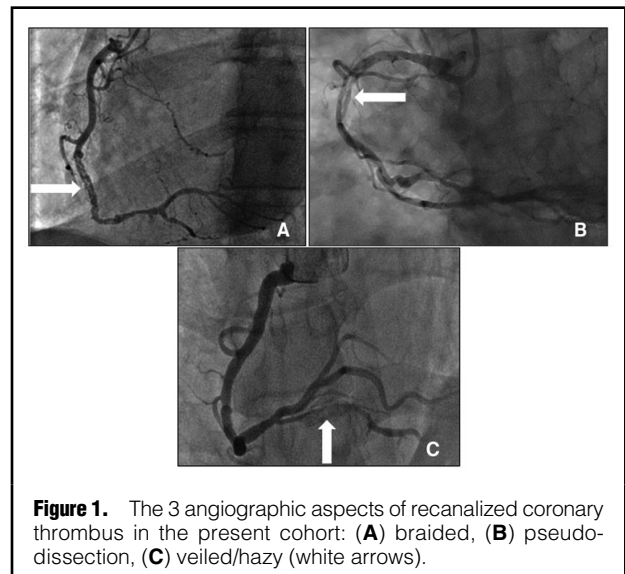


Figure 1. The 3 angiographic aspects of recanalized coronary thrombus in the present cohort: (A) braided, (B) pseudo-dissection, (C) veiled/hazy (white arrows).

invasive stress testing. The patient with prior CABG had not undergone stress testing.

Complementary Examinations

Mean LVEF on echocardiography was 55% (IQR, 50–60%). Wall motion abnormality was evident in 25 patients (76%). Segmental disorder correlated strongly with the artery showing SRCT (88%; $\kappa=0.78$; $P<0.001$); in the 3 cases of discordance, there was significant stenosis in a different coronary vessel (**Table 1**).

All of the patients who underwent stress testing ($n=15$, 45%) had an abnormal test result. Segmental involvement corresponded to the SRCT territory.

FFR was measured in 1 patient (FFR=0.79).

Angiography

SRCT were mainly located in the right coronary (50%) or anterior interventricular artery and its branches (41%), with circumflex network involvement in the other 9% of cases (**Table 2**). On angiography almost half the patients (44%) had a second lesion causing significant coronary stenosis ($>50\%$ diameter).

Ten of the 11 patients with prior CAD had previously undergone coronary angiography. Seven of these patients had a history of occluded artery, in all of whom SRCT was found on the same coronary. Median interval between diagnosis of occlusion and of SRCT was 14 years (IQR, 3–17 years).

Qualitatively, the lesions showed a range of characteristics: braided, with multiple linear and/or interlaced structures in 62% (**Figure 1A**); features of coronary dissection, with a linear contrast defect, often associated with an irregular lumen edge, in 29% (**Figure 1B**); or a veiled, hazy aspect in 6% (**Figure 1C**).

Based on quantitative analysis of the culprit stenosis on coronary angiography, the median percentage stenosis was 45% (IQR, 36–60%).

Arteries with SRCT had a median reference diameter of 3.1 mm (IQR, 2.7–3.5 mm). Median lesion length was 26.9 mm (IQR, 16.8–38 mm). Almost all lesions (91%) had Thrombolysis in Myocardial Infarction (TIMI) 3 flow. There were frequent collaterals originating adjacent to the

Table 3. OCT of Recanalized Coronary Thrombi	
n=34	
Lesion length (n=29)	30.5 (20–38.4)
Reference lumen area	5.55 (4.3–7.8)
MLA	1.55 (0.9–2)
MLA vessel (n=24)	8.9 (7.4–10.65)
Max. channel area	3.05 (2.1–4.1)
Vessel area at max. channel smooth septae with high-luminosity (n=30)	12.2 (9.2–14)
Occlusive fiber	28 (82.4)
Stenosis (%)	68.2 (51.5–84.1)
>50	26 (76.5)
>70	16 (47.1)
Min. area/max. channel area	0.66 (0.35–0.87)
Max. channel number	6 (5–8)

Data given as n (%) or median (IQR). Reference lumen area: mean of lumen areas upstream and downstream of lesion. Max. channel area, lumen area; MLA, minimum lumen area; MLA vessel, vessel area at MLA; vessel area at max. channels, vessel lumen area where the number of channels in the lesion is greatest; occlusive fiber, fiber completely occluding the lumen of the vessel it crosses.

thrombus (73%). SRCT frequently began (82%) or ended (67%) adjacent to a coronary bifurcation.

OCT

OCT was performed without complication in all of the patients (Table 3). All of the lesions could be crossed by the OCT catheter, although pre-dilation using a 1.5-mm balloon was necessary in 1 patient.

OCT also indicated smooth septae with high-luminosity signal, strong reflection and weak attenuation. Channel contours were circular. Areas most distant from the fiber showed weaker signal with lower luminosity.

On the 29 pull-backs covering the entire lesion, median lesion length was 30.5 mm (IQR, 20–38.4 mm); reference

lumen area, 5.6 mm² (IQR, 4.3–7.8 mm²); MLA, 1.55 mm² (IQR, 0.9–2 mm²), and lumen area in the section with maximum channel count, 3.1 mm² (IQR, 2.1–4.1 mm²). The fiber occluded the channel it crossed in 82% of cases. Maximum channel count ranged from 3 to >10 (micro-channels) according to lesion (Figure 2). There was a wide variety of lesion aspects (Figure 3).

Considering the MLA and reference segment area, the median reduction in lumen area was 68.2% (range, 20–92.6%).

There was marked variation in lumen area within each lesion. This variation was typically associated with channel tortuosity within the vessel.

Angiography and OCT

There was a relatively good linear association between lesion length on angiography and OCT ($r=0.80$; $P<0.001$), with lower values on QCA as compared with OCT.

In contrast, the correlation between angiography (QCA) and OCT (area) was poor for lumen reduction ($r=0.30$; $P=0.09$). OCT values were on average significantly higher: $65.7\pm 3.5\%$ vs. $48\pm 19\%$ ($P<0.001$; Figure 4).

For a stenosis threshold of 50%, 26 lesions were significant on OCT vs. 9 on angiography and, for a 70% threshold, 16 vs. 3, respectively.^{7,8} Agreement between the 2 methods was generally very poor ($\kappa=0.15$).

There was a reasonable correlation between stenosis and MLA on OCT ($r=-0.69$; $P<0.001$), compared to a poor correlation on QCA ($r=-0.18$; $P=0.31$).

Treatment and Follow-up

PCI with a drug-eluting stent (DES) was performed immediately in 91% of cases. Pre-dilatation was systematically performed and post-dilatation was performed in 9 SRCT lesions (26%). There were no cases of malapposition, under-deployment or edge dissection on post-stenting OCT in 20 cases (Table 4).

Three patients did not receive a stent. In 1 patient, the lesion was technically inaccessible to revascularization (Table 4). The second patient was stented after confirma-

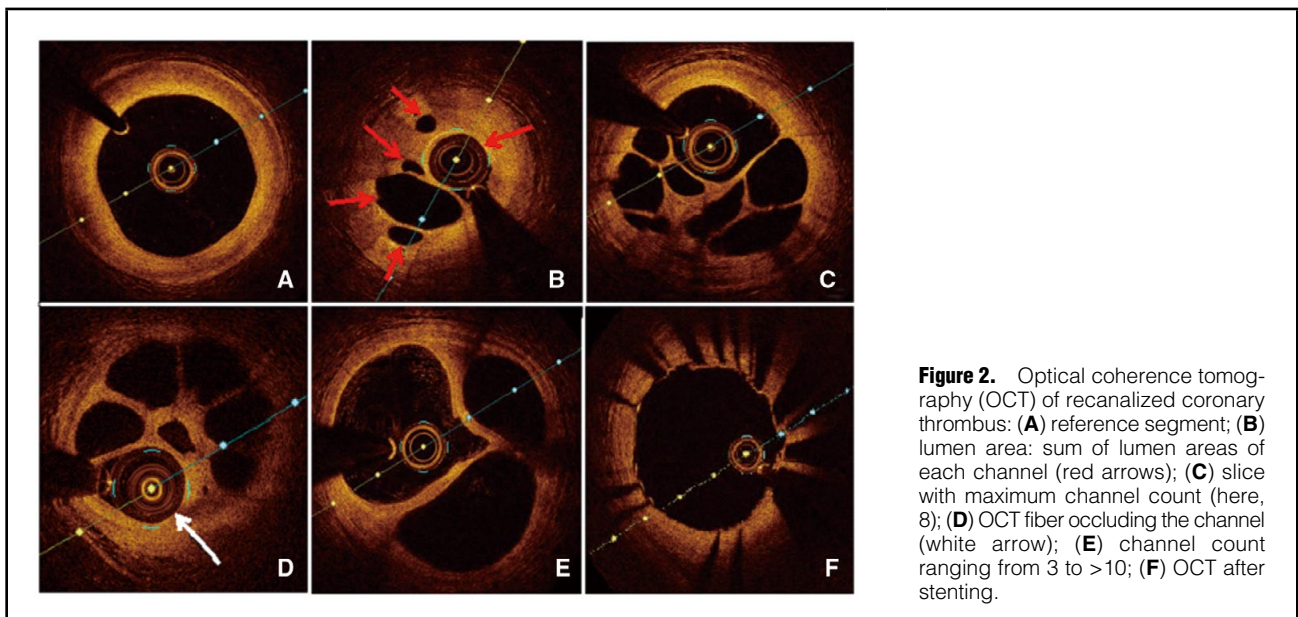


Figure 2. Optical coherence tomography (OCT) of recanalized coronary thrombus: (A) reference segment; (B) lumen area: sum of lumen areas of each channel (red arrows); (C) slice with maximum channel count (here, 8); (D) OCT fiber occluding the channel (white arrow); (E) channel count ranging from 3 to >10; (F) OCT after stenting.

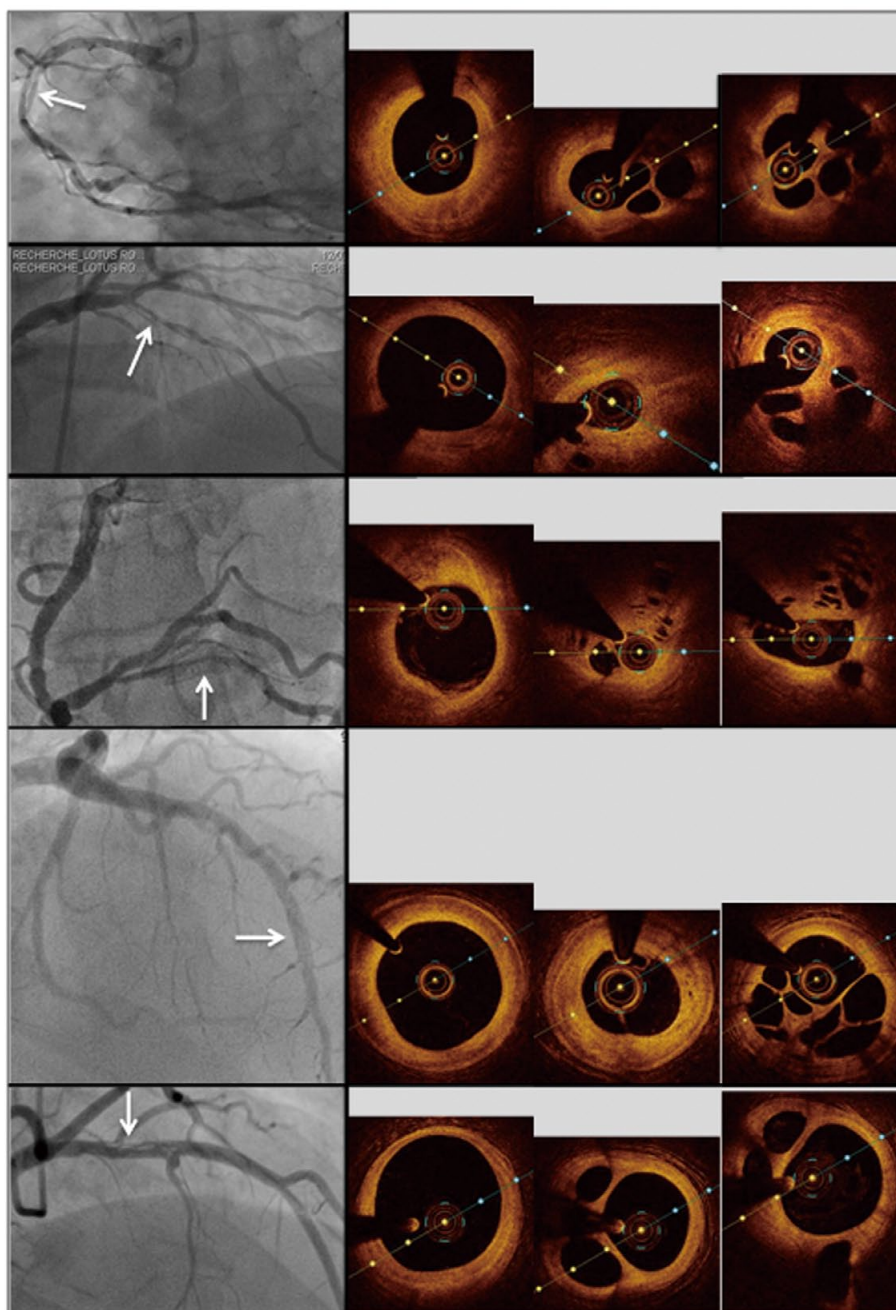


Figure 3. Five recanalized coronary thrombi on angiography (white arrows) and optical coherence tomography, with (left to right) reference segment slice with minimum lumen area measured after mm/mm analysis of pull-back, and 1 representative transverse slice establishing diagnosis.

tion of feasibility, and the third was not stented because feasibility was not confirmed. Dual antiplatelet therapy was prescribed for either 6 months or 12 months according to the clinical presentation.

The median follow-up duration was 17 months (IQR, 8–25 months) after diagnosis. One patient died from cancer 17 months after enrolment. Three patients had ACS: 1 at day 15, as a result of intra-DES thrombosis related to non-adherence to anti-platelet therapy; and 2 had NSTEMI at

months 3 and 8 respectively, due to atherothrombotic destabilization of lesions not primarily implicated in SRCT.

The LVEF increased during follow-up (3–4%; median duration, 20.5 months; IQR, 9–33 months) although this change was not statistically significant ($P=0.06$).

Discussion

We present the largest cohort to date of patients with SRCT.

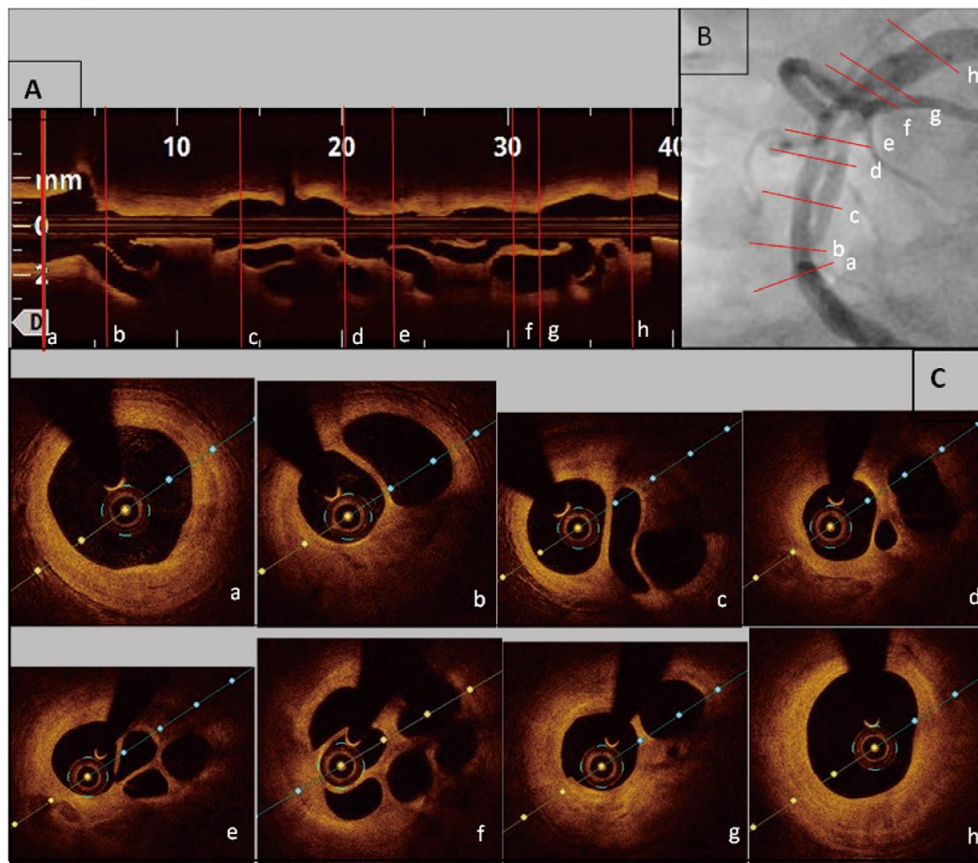


Figure 4. Recanalized coronary thrombus on angiography vs. optical coherence tomography (OCT): each (C) transverse OCT slice (a-h) is located on the respective slices on (A) longitudinal OCT and (B) angiography by red lines.

Using OCT, we identified 3 key characteristics: braided, pseudo-dissection and hazy or veiled aspect.^{2,3,5,9,10}

OCT: Diagnostic Gold-Standard

Thirty-four OCT confirmed typical aspects of channels divided by thin septa, as described in the literature as “spider web”, “swiss cheese”, “lotus root” or “honeycomb”.^{3,5,9} Smooth septa with high-luminosity signal, strong reflection and weak attenuation have been previously reported; their fibrous composition suggests an origin in previous thrombi.^{1,3}

SRCT is due to old thrombus that undergoes recanalization to form several small lumens. The present analysis identified a broad range of lesion types, with variable inter- and intra-lesion lumen areas, varying numbers and sizes of channel, and lumen reduction that was sometimes small and other times great.

SRCT have distinct OCT characteristics that differ from those of recent fresh thrombus, which shows superficial high-intensity signal, with strong attenuation and a shadow cone.¹¹ Older thrombi have a similar signal to that of normal arterial wall adventitia. The pathognomonic feature is the morphology of circular channels separated by thin septa, unlike in dissection, which is characterized by true and false channels that are intraluminal and in communication.

We conclude that the typical features of SRCT on OCT

support the use of this method as the reference diagnostic technique for this problem. OCT is preferable to IVUS, because spatial resolution is 10-fold greater ($10\mu\text{m}$). It can thus confirm a diagnosis of SRCT when angiography is ambiguous.¹⁰

OCT indicated lumen reduction between 20% and 93%, but there was no clear association with stenosis severity or coronary flow. A total of 94% of lesions on OCT were potentially clinical significant (e.g., associated with symptoms of angina or dyspnea), illustrating the poor correlation between lumen area on OCT and hemodynamic impact on FFR.^{12,13} In the present series, FFR was performed only once, and confirmed hemodynamic impact despite little lumen reduction. The present discordance between lumen reduction and symptomatic impact may be due to the tortuosity of the channels. Downstream hemodynamic impact cannot be assessed from cross-sectional imaging and is probably underestimated on angiography, as seen from the symptomatic impact in the present series.

Limitations of Angiography

Most of the present patients (67%) were symptomatic (angina pectoris and/or dyspnea). Nine of the 10 asymptomatic patients were assessed on functional tests, which all proved positive, whereas angiography identified only 9 patients (30%) with >50% (30%) and 3 (10%) with >70%

stenosis. Moreover, estimated lumen reduction varied from 28% to 100% in the 15 patients with functional test, which indicated ischemia in all cases. There was thus discordance between the ischemia and the stenosis induced by the lesion on angiography. In these patients, QCA assessment of stenosis was poorly predictive of the ischemia induced by SRCT. These limitations of angiography help to explain the potential for under-diagnosis at autopsy, reinforcing the need to screen for signs of SRCT, given that diagnosis may be suspected on OCT.

Pathology data reported by Friedman and Van den Bovenkamp showed that one-third of patients with thrombotic occlusion had some degree of recanalization.¹⁴ In the present series, there were 7 cases of history of coronary occlusion on previous angiography; in the same vessel, OCT indicated SRCT, confirming the chronic progression of certain occluding thrombi toward SRCT.⁵

The present data support the contention that OCT-guided management of SRCT is associated with good prognosis. Treatment was mainly by stenting, precluding comparison with other therapies. Stenting is relatively simple and safe, with good immediate (satisfactory apposition) and longer term results, with 9.1% MACCE at a median 17 months' follow-up. Despite atypical morphology, this treatment option is technically feasible and associated with a low rate of failure.

PCI was performed without complication. PCI was straightforward without risk of embolization given that thrombus was established and the arteries were patent due to spontaneous recanalization.

Study Limitations

One limitation of the study was that it included only lesions that were suggestive or ambiguous on angiography. Moreover, coronary instrumentation with OCT had to be feasible. This led to a selection bias, precluding extrapolation: patients with lesions too distal or tortuous to allow the guide to be passed through the thrombus could not be included. Likewise, therapeutically, including only lesions in which the guide could be passed through the recanalized thrombus may have led to overestimation of the feasibility of stenting and of its good immediate results.

The second OCT limitation involved optic fiber passage and flush (generally 4 mL/s), liable to mechanically increase lumen area at the lesion, causing lumen reduction to be underestimated.

Given that FFR was implemented in only 1 case, the ischemic status of each lesion could not be assessed. Positive functional tests and clinical amelioration with stenting, however, point to significant impact.

A prospective study of SRCT exploring hemodynamic impact on FFR and/or functional impact on myocardial ischemia location tests could confirm the impact of SRCT.

Conclusions

The current series is the largest reported cohort of recanalized coronary thrombus confirmed on OCT. Coronary angiography implies a diagnosis based on frequently observed aspects (braided, pseudo-dissection or hazy). OCT formally confirms diagnosis, showing multiple channels separated by thin septa. It also guides treatment, which may be by adapted stenting.

Table 4. Treatment for Recanalized Coronary Thrombus and Follow-up

Treatment	n=34
Medical only	3 (8.8)
Angioplasty with stent(s) (active stents)	31 (91.2) (31 (91.2))
OCT contribution according to the operator	n=34
Enables unsuspected diagnosis	9 (26.5)
Confirms suspected diagnosis	25 (73.5)
Guides treatment	23 (67.6)
Controls result	20 (58.8)
Clinical follow-up	n=33 (100)
Time (months)	17 (8–25)
All-cause mortality	1 (3)
MACCE	3 (9.1)
ACS	3 (9.1)
Stroke	0
Death from cardiac causes	0
LVEF follow-up	n=22 (66.6)
LVEF (%)	60 (52–65)
Follow-up (months)	20.5 (9–33)
Progression (%)	+2 (0–10); P=0.06

Data given as n (%) or median (IQR). ACS, acute coronary syndrome; LVEF, left ventricle ejection fraction; MACCE, major adverse coronary or cerebral events; OCT, optical coherence tomography.

Acknowledgments

For providing medical and paramedical data and corresponding angiographic and OCT images, we thank the cardiology departments of the following hospital centers: Avignon, Brive, Bron, Chambéry, Clermont-Ferrand, Créteil, Haguenau, Institut Mutualiste Montsouris, La Rochelle, Lyon Croix-Rousse, Montpellier, Nîmes, Paris-Cochin, Poitiers, and Toulouse (France).

Disclosures

G.S. and P.M. received lecture fees from St. Jude Medical, Medtronic and Terumo. The other authors declare no conflicts of interest.

References

- Friedman M. The coronary canalized thrombus: Provenance, structure, function and relationship to death due to coronary artery disease. *Br J Exp Pathol* 1967; **48**: 556–567.
- Terashima M, Awano K, Honda Y, Yoshino N, Mori T, Fujita H, et al. "Arteries within the artery" after Kawasaki disease: A lotus root appearance by intravascular ultrasound. *Circulation* 2002; **106**: 887.
- Kang SJ, Nakano M, Virmani R, Song HG, Ahn JM, Kim WJ, et al. OCT findings in patients with recanalization of organized thrombi in coronary arteries. *JACC Cardiovasc Imaging* 2012; **5**: 725–732.
- Yang DH, Kang SJ, Kim YH, Kang JW, Ahn JM, Park DW, et al. Recanalization of organized thrombi demonstrated by coronary CT angiography compared with OCT. *JACC Cardiovasc Imaging* 2016; **9**: 887–890.
- Kadowaki H, Taguchi E, Kotono Y, Suzuyama H, Yoshida M, Miyamoto S, et al. A lotus root-like appearance in both the left anterior descending and right coronary arteries. *Heart Vessels* 2016; **31**: 124–128.
- Levine GN, Bates ER, Blankenship JC, Bailey SR, Bittl JA, Cercek B, et al. 2011 ACCF/AHA/SCAI Guideline for Percutaneous Coronary Intervention. A report of the American College of Cardiology Foundation/American Heart Association Task Force on Practice Guidelines and the Society for Cardiovascular Angiography and Interventions. *J Am Coll Cardiol* 2011; **58**: e44–e122.

7. Tearney GJ, Regar E, Akasaka T, Adriaenssens T, Barlis P, Bezerra HG, et al. Consensus standards for acquisition, measurement, and reporting of intravascular optical coherence tomography studies: A report from the International Working Group for Intravascular Optical Coherence Tomography Standardization and Validation. *J Am Coll Cardiol* 2012; **59**: 1058–1072.
8. Shiono Y, Kitabata H, Kubo T, Masuno T, Ohta S, Ozaki Y, et al. Optical coherence tomography-derived anatomical criteria for functionally significant coronary stenosis assessed by fractional flow reserve. *Circ J* 2012; **76**: 2218–2225.
9. Toutouzas K, Karanasos A, Stathogiannis K, Synetos A, Tsiamis E, Papadopoulos D, et al. A honeycomb-like structure in the left anterior descending coronary artery: Demonstration of recanalized thrombus by optical coherence tomography. *JACC Cardiovasc Interv* 2012; **5**: 688–689.
10. Haraki T, Uemura R, Masuda S, Kobayashi N, Lee T. A honeycomb-like structure in the left anterior descending coronary artery treated using a scoring device and drug-eluting stent implantation: A case report. *J Med Case Rep* 2016; **10**: 80.
11. Kubo T, Imanishi T, Takarada S, Kuroi A, Ueno S, Yamano T, et al. Assessment of culprit lesion morphology in acute myocardial infarction: Ability of optical coherence tomography compared with intravascular ultrasound and coronary angiography. *J Am Coll Cardiol* 2007; **50**: 933–939.
12. Gonzalo N, Escaned J, Alfonso F, Nolte C, Rodriguez V, Jimenez-Quevedo P, et al. Morphometric assessment of coronary stenosis relevance with optical coherence tomography: A comparison with fractional flow reserve and intravascular ultrasound. *J Am Coll Cardiol* 2012; **59**: 1080–1089.
13. Pyxaras SA, Tu S, Barbato E, Barbati G, Di Serafino L, De Vroey F, et al. Quantitative angiography and optical coherence tomography for the functional assessment of nonobstructive coronary stenoses: Comparison with fractional flow reserve. *Am Heart J* 2013; **166**: 1010–1018.
14. Friedman M, Van den Bovenkamp GJ. The pathogenesis of a coronary thrombus. *Am J Pathol* 1966; **48**: 19–44.