



Giant congenital melanocytic nevus with vascular malformation and epidermal cysts associated with a somatic activating mutation in BRAF

Heather C. Etchevers, Christian Rose, Birgit Kahle, Helmuth Vorbringer, Frederic Fina, Pauline Heux, Benjamin Schwarz, Stéphane Zaffran, Nicolas Macagno, Sven Krengel

► To cite this version:

Heather C. Etchevers, Christian Rose, Birgit Kahle, Helmuth Vorbringer, Frederic Fina, et al.. Giant congenital melanocytic nevus with vascular malformation and epidermal cysts associated with a somatic activating mutation in BRAF. 2017. hal-01613153v1

HAL Id: hal-01613153

<https://hal.science/hal-01613153v1>

Preprint submitted on 9 Oct 2017 (v1), last revised 16 Feb 2018 (v2)

HAL is a multi-disciplinary open access archive for the deposit and dissemination of scientific research documents, whether they are published or not. The documents may come from teaching and research institutions in France or abroad, or from public or private research centers.

L'archive ouverte pluridisciplinaire **HAL**, est destinée au dépôt et à la diffusion de documents scientifiques de niveau recherche, publiés ou non, émanant des établissements d'enseignement et de recherche français ou étrangers, des laboratoires publics ou privés.

Giant congenital melanocytic nevus with vascular malformation and epidermal cysts associated with a somatic activating mutation in *BRAF*

Heather C. Etchevers ^{1, ✉}, Christian Rose ², Birgit Kahle ³, Helmuth Vorbringer ⁴, Frédéric Fina ⁵,
Pauline Heux ¹, Benjamin Schwarz ^{1*}, Stéphane Zaffran ¹, Nicolas Macagno ^{5, 6}, Sven Krengel ^{7 ✉}

Affiliations:

¹ Aix Marseille Univ, INSERM, UMR_S910, Génétique Médicale et Génomique Fonctionnelle, Faculté de Médecine AMU, 27 boulevard Jean Moulin, 13005 Marseille, France

² Dermatohistological Laboratory, Lübeck, Germany

³ Department of Dermatology, University Hospital Lübeck, Germany

⁴ Radiological group practice, Lübeck, Germany

⁵ Department of Pathology, Hôpital de la Timone, APHM, Marseille, France

⁶ Aix Marseille Univ, INSERM, UMR_S 911, CRO2, Marseille, France

⁷ Dermatological group practice, Moislinger Allee 95, 23558 Lübeck, Germany

* Current address: Department of Biology, University of Erlangen-Nürnberg, Erlangen, Germany

✉ Authors for correspondence.

Summary

Giant congenital melanocytic nevi may be symptomatically isolated, or syndromic. Associations with capillary malformations are exceptional, and development of epidermal cysts has not been described. A 71-year old patient with a giant congenital melanocytic nevus of the lower back, buttocks and thighs was asymptomatic except for unexpected hemorrhage during partial surgical excision years before. Blunt trauma at age 64 initiated recurrent, severe pain under the nevus; multiple large epidermal cysts developed within it. Imaging and biopsy showed a large, non-pulsatile venous malformation intermingled with the deep nevus. A low-abundance, heterozygous *BRAF* c.1799T>A (p.V600E) mutation was present in both the gluteal and occipital “satellite” nevi; additional mutations in *NRAS*, *GNAQ*, *GNA11*, *HRAS* and *PIK3CA* were undetectable. This is the first demonstration of an identical *BRAF* mutation in multiple congenital nevi from the same individual, confirming genetic heterogeneity in giant nevi. This exceptional case indicates that constitutive activation of BRAF can be an underlying cause of unusual associations of giant nevi with vascular malformations, and that the latter may be included among the somatic RASopathies.

Significance

The molecular basis for an unusual, syndromic giant congenital melanocytic nevus turned out to be a constitutively active, post-zygotic *BRAF* c.1799T>A (p.V600E) mutation in both the primary and a distant nevus. After blunt trauma and inflammation in late adulthood, epidermal cysts developed over, and a venous malformation became symptomatic under, the giant nevus. This observation enlarges the spectrum of congenital mosaic RASopathies to an additional new entity with potentially late symptomatic onset, the result of concurrently affected vascular and pigment cell development before birth.

Keywords: nevus, congenital, melanocyte, venous, malformation, BRAF

A 71-year-old, healthy male Caucasian, Fitzpatrick skin type II, presented with a reddish-brown, giant congenital melanocytic nevus (CMN, classified G1-S1-C1-R2-N2-H1; Krengel, Scope, Dusza, Vonthein, & Marghoob, 2012) involving the complete right gluteal area, parts of the left gluteal area and the lower back, the dorsal aspect of the right thigh and the right hip region (Figure 1A; also known as “bathing trunk” using the “6B” pattern definitions; Martins da Silva et al., 2017). The gluteal area showed soft, nodular thickening with black comedones and multiple yellowish cysts, measuring 1-3 cm (Figure 1B). On the proximal thigh, the CMN exhibited another soft, thickened area with relatively loose skin folds and small fibroma-like nodules. Hypertrichosis was present at the upper and lower borders of the nevus. A single additional light-brown, medium-sized CMN of 8 cm in diameter was found in the occipital area. At age 51, part of the primary CMN was surgically excised. The operation led to severe hemorrhage, requiring blood transfusion.

The CMN had otherwise only caused cosmetic impairment until age 64, when the patient experienced a blunt trauma to the CMN immediately followed by strong pain radiating down the right leg. Motor control was temporarily lost and accompanied by fever. Pain resolved slowly, over several weeks. Since then, similar episodes of pain and fever, often with urticarial rash, recurred every four to six weeks. After the initial injury, painful, yellowish cysts developed in the nevus, discharging pus during the inflammatory episodes. Currently, the severity of the symptoms has diminished to periodic local swelling, cyst inflammation and discomfort. Episodes are reproducibly provoked by prolonged sitting on the affected side, as when travelling. The most intense pain is reported within an elevated area of the CMN of approximately 3 x 15 cm, to the right of the natal cleft.

Blood samples from the first years of painful episodes showed increased C-reactive protein, but this became undetectable, nor were there changes in sedimentation rate. Routine laboratory parameters including rheumatological screening were normal; D-dimers were at 0,41 mg/l (normal) and fibrinogen at 423 mg/dl (normal range 170-420 mg/dl).

DNA was extracted using standard methods from paraffin sections of biopsies from the gluteal nevus, and from the occipital nevus. Both were subjected to Sanger sequencing of *NRAS* exons 2 and 3, *BRAF* exon 15, *GNAQ* exons 4 and 5, *GNA11* exons 4 and 5, *HRAS* exons 2 and 3, and *PIK3CA* exon 20. Minor heterozygosity was found in both forward and reverse orientations for *BRAF* at position c.1799T>A (p.V600E), but not for the other exons sequenced, in both tissue samples (Figure 1C, 1D). Results were reproduced in two distinct laboratories with fresh DNA extractions from both biopsies and subsequently confirmed by Droplet Digital™ PCR (ddPCR) as described (Fina et al., 2017; Figure 1E).

Biopsy from the right buttock shows unpigmented cords of monomorphous small melanocytes throughout the dermis and a large infundibular cyst with a well-defined granular layer in the reticular dermis (Figure 2A, 2B). A specimen from the partial surgical excision did not have cysts, but showed large blood vessels in the dermis and subcutaneous fat, intermingled with the nevus cell aggregates (Figure 2C, arrows). A punch biopsy of the occipital lesion showed a typical CMN composed of small round melanocytes (not shown).

Because epidermal hyperplasia can be caused by Akt activation in mice (Murayama et al., 2007) , we examined phosphorylated Akt immunoreactivity. Areas of the basal epidermis over the nevus, but not surrounding the epidermal infoldings, were positive (arrowheads, Figure 2D).

Immunohistochemistry against tryptase within the primary CMN showed normal density and distribution of mastocytes throughout (Figure 2E). An antibody to V600E-mutant BRAF revealed variable levels of expression in CMN cells, ranging from undetectable to moderate (Figure 2F).

Magnetic resonance (MR) imaging showed a vascular malformation consisting of dilated veins which penetrated the thickened nevus region, and deeper-reaching draining veins (Figure 3A). Dynamic MR angiography after two hours of sitting revealed several small signal-reduced tubular foci within the vascular malformation, potentially small thromboses or flow-void phenomena. Duplex sonography showed a spongiotic vascular infiltration, beginning in the upper nevus (Figure 3B).

As microthromboses in the deep vascular malformation were suspected, several days of oral aspirin (acetylsalicylic acid, 100 mg p.o.) was prescribed before the patient sat on the right buttock for one hour. In a second trial, the patient pre-injected low molecular weight heparin (dalteparin sodium 5000 IU s.c.). Neither of these treatments precluded or abridged the subsequent pain. However, even after onset, his pain responded well to oral ibuprofen 400-600 mg p.o.

We have presented here a patient with giant CMN and unusual clinical and molecular features. Non-invasive imaging indicated an underlying, partially thrombotic venous malformation, where the abnormal vascular structures originated in the mid-dermis. Histology confirmed large veins in the dermis and subcutaneous fat, intimately intermingled with nevus cell aggregates, with flat endothelial cells and normal mast cell count. Along with reported hemorrhage upon earlier surgery and later aggravation after trauma, these observations are compatible with previously undiagnosed congenital venous malformation. Microthromboses were considered as potential causes of the painful episodes; however, there was no measurable elevation of D-dimers and the pain responded not to anti-thrombotic therapies, but to a non-steroid anti-inflammatory drug.

Large cohorts of patients reported with large and giant CMN have not mentioned concomitant vascular malformations. A superficially similar condition, phakomatosis pigmentovascularis, is clinically and histologically distinguished by a combination of dermal melanocytosis and teleangiectatic vascular malformations, due to somatic *GNA11* or *GNAQ* mutations (Thomas et al., 2016). Wu and co-authors (2008) described cases with CMN and “infantile hemangiomas” : three had a solitary vascular lesion in the vicinity of a small/medium CMN, a child with a S1-type LCMN also had six small lesions, and two had deep or segmental lesions associated with LCMN or GCMN in a distinct part of the body. Lovett *et al.* described two children who had a capillary malformation under their large CMN, associated with intense pruritus (Lovett et al., 2009). Chronic itch is often reported by large CMN patients, who also demonstrate significantly higher densities of cutaneous mast cells (Salgado et al., 2014). Our patient also developed an urticarial rash together with the painful episodes, but no eczematous skin changes nor increased mast cell density in his CMN.

Epidermal cysts have occasionally been reported within small CMN on the face (Joo, Kim, & Kang, 2016) but association of multiple epidermal cysts with a giant CMN has never been described. The late onset points to the initial trauma as a precipitating factor. The local inflammatory phenomena accompanying the pain are reminiscent of the inflammation in solitary epidermal cysts or in hidradenitis suppurativa (Danby, Jemec, Marsch, & von Laffert, 2013).

The majority of giant CMN genotyped carry constitutively activating mutations in codon 61 of *NRAS* (Dessars et al., 2009; Kinsler et al., 2013; Salgado et al., 2015; D. Wu et al., 2011). However, multiple cases of large-to-giant CMN with V600 mutations in *BRAF* (Dessars et al., 2009; Salgado et al., 2015), as well as two *BRAF*-activating chromosomal translocations (Dessars et al., 2007), have also been reported. As described here and elsewhere, *BRAF*-mutated CMN have few or no “satellite” disseminated nevi at or after birth (Salgado et al., 2015). Thus, evidence of identical mutations in distant sites, supporting true genetic heterogeneity in giant CMN, had not been presented before. *BRAF*-mutated CMN patients have also been reported to form significantly more frequent subcutaneous proliferative nodules (Salgado et al., 2015), although their risk for melanoma is no higher than for CMN with activating *NRAS* mutations.

In conclusion, we present here the first report of a patient with a *BRAF*-mutated giant CMN in whom the same mutation was found in a distinct, medium-sized CMN at a distant site. In addition, he had an extensive vascular malformation and epidermal cysts associated with the giant CMN. The co-localization of melanocytic, epidermal, and vascular hyperplasia in this patient, but the low mutant allele load within both CMN, indicate that the initiating mutation may have occurred in a single cell of the migratory neural crest. Its descendants would then have exerted non-cell-autonomous effects *in utero* on surrounding tissues of ectodermal and mesodermal origins, which only became symptomatic late in life.

Acknowledgements

Cell Signaling Technology for anti-Akt (4060); Abcam for anti-tryptase (EPR8476 clone); Spring Bioscience for anti-BRAF V600E (VE1); BioRad for ddPCR. This study was supported by grants from Nevus Outreach, Inc., Asociación Española de afectados por Nevus Gigante Congénito, Association du Naevus Géant Congénital, Naevus 2000 France-Europe, Caring Matters Now, the RE(ACT) Community and aid-in-kind from the BeHeard Rare Disease Science Challenge. We thank Irina Berger, Pathological Institute, Kassel, Germany; Christos Zouboulis, Dermatological Clinic, Dessau, Germany; Joanna Ordioni and Dominique Figarella-Branger, Timone Hospital, Marseille, France, for their helpful assistance and discussion.

Figures

Figure 1. **A.** Giant congenital melanocytic nevus of the lower back, gluteal region and right thigh, classified G1-S1-C1-R2-N2-H1. **B.** Detail showing multiple epidermal cysts inside the nevus region. **C,** **D:** Sanger sequencing of *BRAF*, demonstrating c.1799T>A (arrowheads; V600E) mutation in lesional tissue and in the occipital satellite nevus, respectively. **E:** Droplet Digital™ PCR was performed according to the manufacturer's protocol (Bio-Rad) The data was analyzed using absolute quantification mode in QuantaSoft (version 1.7.4.0917, Bio-Rad). The threshold for positive amplification was determined based on the results of a no template control, mutant and wild-type cloning plasmids, and control genomic DNA. Fractional abundance was calculated as the proportion of mutant reads to the sum of mutant and wildtype reads.

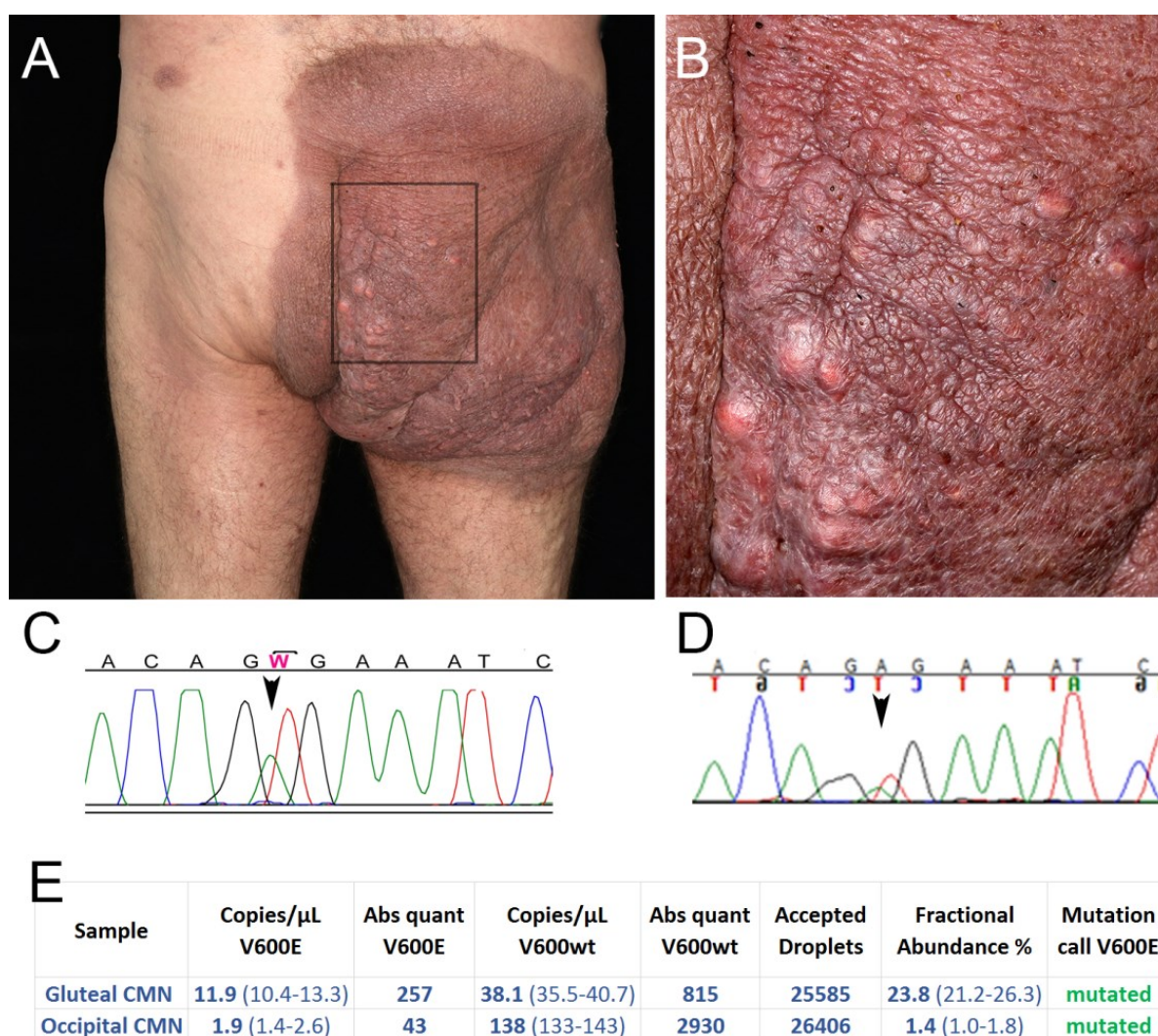


Figure 2.

A. Infundibular cyst within a biopsy of the gluteal CMN. **B.** Epithelial lining with associated granular layer and cords of small melanocytes. **C:** Different section of same sample, showing blood vessels intermingled with junctional and dermal melanocytes. **D:** Immunoreactivity against phosphorylated Akt (brown, arrowheads) in the basal epidermis. **A-D:** Hematoxylin-eosin stain. **E:** Tryptase immunoreactivity (brown, arrowheads) within the gluteal CMN is unremarkable. **F:** BRAF V600E immunoreactivity (brown, arrowheads) in otherwise unpigmented nevus cell cords. Scale bars: A, 1 mm; B, 0.25 mm; C-F, 50 μ m.

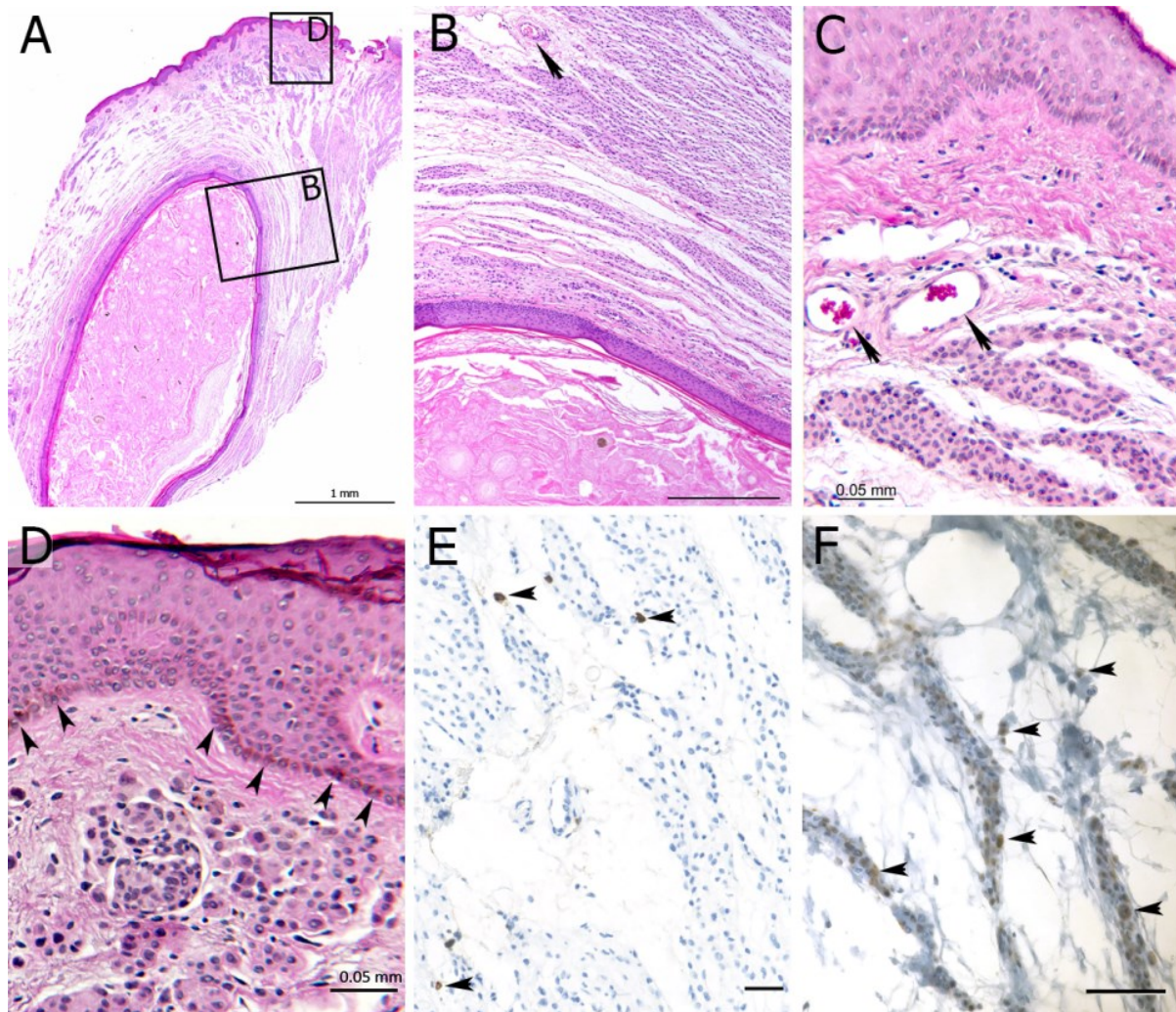
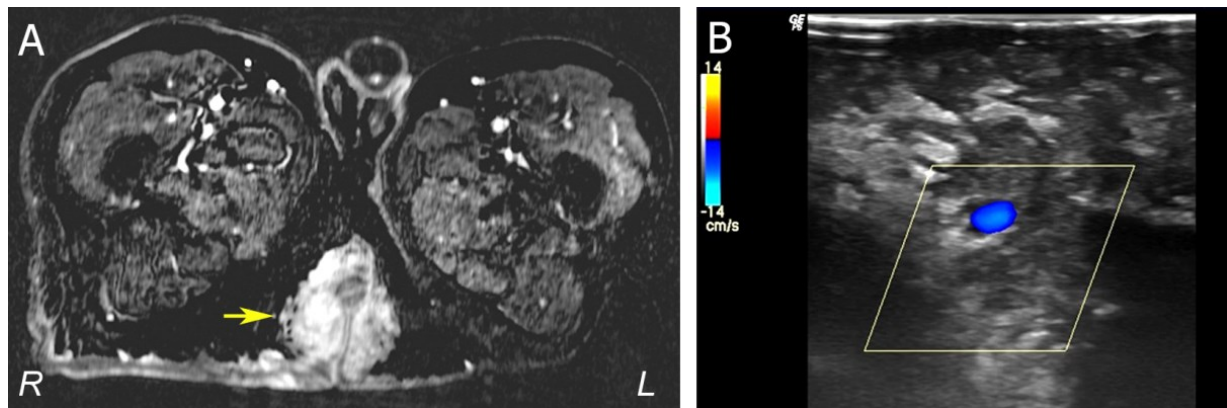


Figure 3. A. T1-weighted MRI cross-section through lower pelvis showing vascular spaces penetrating the hyperintense nevus tissue (yellow arrow; R, right; L, left). **B.** Duplex sonography showing spongiotic vascular malformation (darker areas) infiltrating the nevus tissue (lighter areas). An exemplary vein is shown in blue, measuring 0.36 cm in diameter at a depth of 5.5 cm.



References

- Danby, F. W., Jemec, G. B. E., Marsch, W. C., & von Laffert, M. (2013). Preliminary findings suggest hidradenitis suppurativa may be due to defective follicular support. *British Journal of Dermatology*, 168(5), 1034–1039.
- Dessars, B., De Raeve, L. E., El Housni, H., Debouck, C. J., Sidon, P. J., Morandini, R., ... Heimann, P. (2007). Chromosomal translocations as a mechanism of BRAF activation in two cases of large congenital melanocytic nevi. *The Journal of Investigative Dermatology*, 127(6), 1468–70.
- Dessars, B., De Raeve, L. E., Morandini, R., Lefort, A., El Housni, H., Ghanem, G. E., ... Heimann, P. (2009). Genotypic and gene expression studies in congenital melanocytic nevi: insight into initial steps of melanotumorigenesis. *The Journal of Investigative Dermatology*, 129(1), 139–47.
- Fina, F., Baretts, D., Colin, C., Bouvier, C., Nanni-metellus, I., Ouafik, L. H., ... Figarella-Branger, D. (2017). Droplet digital PCR is a powerful technique to demonstrate frequent FGFR1 duplication in dysembryoplastic neuroepithelial tumors. *Oncotarget*, 8(2), 2104–2113.
- Joo, H. J., Kim, J. E., & Kang, H. (2016). Congenital Melanocytic Nevus with Distinctive Nevus Cell Proliferation within Multiple Epidermal Cyst-Like Changes. *Annals of Dermatology*, 28(1), 123.
- Kinsler, V. A., Thomas, A. C., Ishida, M., Bulstrode, N. W., Loughlin, S., Hing, S., ... Moore, G. E. (2013). Multiple congenital melanocytic nevi and neurocutaneous melanosis are caused by postzygotic mutations in codon 61 of NRAS. *The Journal of Investigative Dermatology*, 133(9), 2229–36.
- Krengel, S., Scope, A., Dusza, S. W., Vonthein, R., & Marghoob, A. A. (2012). New recommendations for the categorization of cutaneous features of congenital melanocytic nevi. *Journal of the American Academy of Dermatology*, 68(3), 441–51.
- Lovett, A., Maari, C., Decarie, J.-C., Marcoux, D., McCuaig, C., Hatami, A., ... Powell, J. (2009). Large congenital melanocytic nevi and neurocutaneous melanocytosis: one pediatric center's experience. *Journal of the American Academy of Dermatology*, 61(5), 766–74.
- Martins da Silva, V. P., Marghoob, A., Pigem, R., Carrera, C., Aguilera, P., Puig-Butillé, J. A., ... Malvehy, J. (2017). Patterns of distribution of giant congenital melanocytic nevi (GCMN): The 6B rule. *Journal of the American Academy of Dermatology*, 76(4), 689–694.
- Murayama, K., Kimura, T., Tarutani, M., Tomooka, M., Hayashi, R., Okabe, M., ... Nakano, T. (2007). Akt activation induces epidermal hyperplasia and proliferation of epidermal progenitors. *Oncogene*, 26(33), 4882–8.
- Salgado, C. M., Basu, D., Nikiforova, M., Bauer, B. S., Johnson, D., Rundell, V., ... Reyes-Múgica, M. (2015). BRAF Mutations Are Also Associated with Neurocutaneous Melanocytosis and Large/Giant Congenital Melanocytic Nevi. *Pediatric and Developmental Pathology*, 18(1), 1–9.
- Salgado, C. M., Silver, R. B., Bauer, B. S., Basu, D., Schmitt, L., Khakoo, Y., & Reyes-Múgica, M. (2014). Skin of patients with large/giant congenital melanocytic nevi shows increased mast cells. *Pediatric and Developmental Pathology*, 17(3), 198–203.
- Thomas, A. C., Zeng, Z., Rivière, J.-B., O'Shaughnessy, R., Al-Olabi, L., St-Onge, J., ... Kinsler, V. A. (2016). Mosaic Activating Mutations in GNA11 and GNAQ Are Associated with Phakomatosis Pigmentovascularis and Extensive Dermal Melanocytosis. *Journal of Investigative Dermatology*, 136(4), 770–778.
- Wu, D., Wang, M., Wang, X., Yin, N., Song, T., Li, H., ... Zhao, Z. (2011). Lack of BRAF(V600E) mutations in giant congenital melanocytic nevi in a Chinese population. *The American Journal of Dermatopathology*, 33(4), 341–4.
- Wu, P. A., Mancini, A. J., Marghoob, A. A., & Frieden, I. J. (2008). Simultaneous occurrence of infantile hemangioma and congenital melanocytic nevus: Coincidence or real association? *Journal of the American Academy of Dermatology*, 58(2 SUPPL. 1), 16–22.