



**HAL**  
open science

## Development of the endocrine pancreas in the Beagle dog: From fetal to adult life

Emilie Bricout-Neveu, Severine Pechberty, Karine Reynaud, Cindy Maenhoudt, Marie José Lecomte, Philippe Ravassard, Paul Czernichow

### ► To cite this version:

Emilie Bricout-Neveu, Severine Pechberty, Karine Reynaud, Cindy Maenhoudt, Marie José Lecomte, et al.. Development of the endocrine pancreas in the Beagle dog: From fetal to adult life. *The Anatomical Record: Advances in Integrative Anatomy and Evolutionary Biology*, 2017, 300 (8), pp.1429-1438. 10.1002/ar.23595 . hal-01607371

**HAL Id: hal-01607371**

**<https://hal.science/hal-01607371>**

Submitted on 26 May 2020

**HAL** is a multi-disciplinary open access archive for the deposit and dissemination of scientific research documents, whether they are published or not. The documents may come from teaching and research institutions in France or abroad, or from public or private research centers.

L'archive ouverte pluridisciplinaire **HAL**, est destinée au dépôt et à la diffusion de documents scientifiques de niveau recherche, publiés ou non, émanant des établissements d'enseignement et de recherche français ou étrangers, des laboratoires publics ou privés.

Copyright

## Development of the Endocrine Pancreas in the Beagle Dog: From Fetal to Adult Life

Emilie Bricout-Neveu<sup>a</sup>, Severine Pechberty<sup>a</sup>, Karine Reynaud<sup>b</sup>, Cindy Maenhoudt<sup>b</sup>, Marie José Lecomte<sup>a</sup>, Philippe Ravassard<sup>c</sup>, and Paul Czernichow<sup>d</sup>

<sup>a</sup>Endocells, Pépinière d'entreprises, Institut du Cerveau et de la Moelle, 75007 Paris, France

<sup>b</sup>Ecole Vétérinaire de Maisons-Alfort, 94700 Maisons-Alfort, France

<sup>c</sup>Sorbonne Universités, UPMC Univ Paris 06, Inserm, CNRS, Institut du cerveau et de la moelle (ICM) – Hôpital Pitié-Salpêtrière, Boulevard de l'Hôpital, F-75013, Paris, France

<sup>d</sup>Animal Cell Therapy (ACT), Université Pierre et Marie Curie, Campus des Cordeliers, 75005 Paris, France

### Corresponding author:

Paul Czernichow

Animal Cell Therapy, University Pierre et Marie Curie, Campus des Cordeliers, 75005 Paris, France

paul.czernichow@wanadoo.fr

This article has been accepted for publication and undergone full peer review but has not been through the copyediting, typesetting, pagination and proofreading process which may lead to differences between this version and the Version of Record. Please cite this article as an 'Accepted Article', doi: 10.1002/ar.23595

**ABSTRACT**

Our objectives were to describe, in Beagle dogs, the ontogenesis of beta (insulin-producing) and alpha (glucagon-producing) cells from fetal to early postnatal life and adulthood. In addition, to have some insight into interspecies comparison, Beagle dog pancreases were compared to pancreases from a Labrador and Chow Chow.

At midgestation, the epithelium was dense, beta cells scarce, and alpha cells numerous and concentrated in the center of the pancreatic bud. From 36 to 45 days post conception (pc), beta cell numbers increased and the epithelium expanded and branched out. At 55 days pc, large beta cell aggregates were seen. At weaning, the islets were similar to those in adults, with limited alpha cells intermingled with numerous beta cells. Quantification of the Alpha to Beta cells ratio has shown a gradual increase of beta cells proportion throughout development.

Similar findings were obtained in the 2 other breeds.

In conclusion, in the fetal Beagle dog beta cells emerge from the pancreatic bud at midgestation, but the endocrine structure is mature only in early postnatal life. The ontogenesis of the endocrine pancreas demonstrated in dogs resembles that reported in rats and mice. In contrast, human beta cells appear earlier, at the beginning of the second trimester of gestation. Our study provides a detailed morphological description of pancreatic development in dogs but supplies no information on alpha- or beta-cell function during fetal life. The morphological data reported here provide a foundation for building physiological studies.

**Keywords:** Fetal development. Pancreas. Dogs. Morphology. Insulin. Glucagon.

## INTRODUCTION

In mammals, fetal growth and maturation depend heavily on maternal nutrition and fetal insulin secretion. Any dysfunction in the process of insulin secretion adversely affects fetal growth and body composition. The important role for insulin in fetal growth is highlighted by the effects on human fetuses of maternal abnormalities in blood glucose control. Poorly controlled diabetes, maternal obesity, and excessive maternal weight gain are associated with fetal and neonatal macrosomia and with intermittent hyperglycemia. In these situations, the high transplacental transfer of glucose causes fetal hyperglycemia and stimulates the fetal release of insulin (1) and other growth factors. In turn, the increased insulin secretion stimulates fetal growth and the accumulation of fat and glycogen. The Hyperglycemic and Adverse Pregnancy Outcomes study in 23 316 pregnant women showed that maternal hyperglycemia was associated with birth weight and cord-blood serum C-peptide level values above the 90<sup>th</sup> percentile (2). Conversely when fetal insulin is low or absent, fetal development is impaired. Intrauterine growth restriction is the rule in newborns with neonatal diabetes, a disease linked to genetic abnormalities in insulin control or production (3), and in leprechaunism, a monogenic disease characterized by severe insulin resistance (4). These conditions illustrate the crucial role for insulin in fetal growth, especially during the last trimester of pregnancy.

Elucidating the function of the endocrine pancreas, most notably that of the beta cells that produce and secrete insulin, is therefore important to understand normal fetal development in mammals. In humans, studies of the above-mentioned conditions have provided valuable insights into fetal insulin secretion. Investigations into the physiology of fetal insulin secretion in rodents, sheep, and rhesus monkeys (5, 6) consistently demonstrated a pivotal role for fetal insulin. Data from humans, monkeys, and rats indicate that glucose is the main source of energy during fetal

life in these species Humans and rats are omnivores and most monkeys are herbivores with a preference for fruit. Among the hormones involved in fetal nutrition in these species, the most important are glucagon and insulin. Little is known about the fetal nutrition of carnivores. Carnivores, including dogs, must draw most of their energy during fetal life from the breakdown of animal proteins ingested by the mother. The alpha and beta cells in the islets of Langerhans secrete glucagon and insulin. We therefore studied the ontogenesis of alpha and beta cells in dogs. Our goal was to create a foundation for physiological studies of the role for insulin and glucagon during fetal life in this species.

Our primary objective was to determine when hormone-producing cells appeared in the primitive pancreas. To this end, we used immunohistochemistry to detect cells containing insulin or glucagon. A secondary objective was to determine at which stage of fetal or early postnatal development the highly organized structure of the islets of Langerhans was formed. We also studied the immunohistological structure of the endocrine pancreas in adult dogs.

## **MATERIAL AND METHODS**

All procedures involving animals were submitted to and approved by the institutional review board of the Maisons-Alfort Veterinary School, Maisons-Alfort, France. Our methods complied with international regulations for the use of animals in experimental studies.

### **Sources of canine pancreatic tissue and sample collection procedure**

As shown in Table 1, we obtained antenatal dog pancreas specimens at six developmental stages, namely, days 30, 33, 36, 40, 45, and 55 postconception (pc). All antenatal samples but

one were from a single strain of Beagle dogs, raised at the Alfort Veterinary School. The exception was the 55-day pc fetus, whose mother resembled a Beagle dog but had no pedigree and was not raised at the Alfort Veterinary School. According to Miller (7), the cutoff between embryonic and fetal life in dogs is 33 days. Thus, our first two specimens were from embryos and the other four from fetuses. All prenatal specimens were obtained by elective caesarean section. The age of the fetuses was determined based on the time of ovulation identified based on the plasma progesterone surge; the exception was the 55-day pc fetus.

Pancreases were also obtained from two Beagle dogs that died during hospitalization, one on day 1 post delivery and the other at weaning at 8 weeks of age.

Finally, we studied a pancreas from an adult Labrador that was euthanized because of a progressive and severely debilitating neuro-muscular disorder. We also compared the morphology of the Beagle dog pancreases at 46 days pc and 1 day postnatally to those of a Labrador and Chow Chow, respectively, at the same ages (Table 2).

### **Preparation of canine pancreatic tissue**

Immediately after surgery, each pancreas was dissected and fixed in 3.7% formaldehyde then embedded in paraffin. The entire midgut tube including the pancreas and stomach was collected from the 30-day and 33-day pc fetuses, whereas only the pancreas was dissected from the four older fetuses. The pancreases from the 1-day-old and 8-week-old dogs were dissected within 1 hour after death and fixed in phosphate buffer saline/10% formaldehyde prior to paraffin embedding. The same procedure was applied to the pancreatic fragment obtained from the adult Labrador. In that case the pancreatic samples were collected from the right lobe. Standard hematoxylin-eosin (HE) staining was performed.

### Immunohistochemistry

Paraffin-embedded slice thickness was 4  $\mu$ m for prenatal specimens and 5  $\mu$ m for postnatal and adult specimens. The slices were stained with guinea pig anti-insulin antibody (1/500; A0564, Dako Cytomation, Carpinteria, CA) and rabbit anti-glucagon antibody (1/1000; 20076-Immuno, Euromedex, Souffelweyersheim, France). The secondary antibodies were fluorescein Texas Red anti-guinea pig antibody (1/2000; 706-076-148) and anti-rabbit antibody (1/200; 711-096-152) (both from Jackson ImmunoResearch Labs, West Grove, PA). Nuclei were stained with Hoechst 33342 fluorescent stain (1/5000; 62249, Thermo Scientific, Waltham, MA).

As shown in Table 1, numerous slices were obtained from each specimen. The slices to be examined were taken at regular intervals and considered representative of the entire gland.

Digital images were taken using an Axio Scan Z1 camera (Zeiss, Oberkochen, Germany).

### Quantification of alpha and beta cells

Alpha and beta cells were enumerated by counting the number of nuclei in immunostained cells. Nucleus counts were performed using ImageJ on whole Axio Scan images (Zeiss, Oberkochen, Germany). The percentage of either glucagon- or insulin-positive cells relative to total glucagon and insulin cells was calculated. The number of immunostained sections for each developmental stage varied from 10 to 15 and the sections used for quantification were chosen every 10 to 40 sections, depending on the size of the tissue sample.

## RESULTS

## Early gestation

Figure 1 A-B illustrates the development of the dog pancreas from 30 to 45 days pc. As seen in the left-hand panel of Figure 1A and in Figure 1B, the pancreatic epithelium underwent marked expansion and complex branching. On days 30 and 33 pc, branched structures were clearly visible. They had developed into more complex tubular structures with epithelial trunks and tips by days 36 to 45 pc.

Few insulin-positive beta cells were visible on days 30 and 33 pc. At the earliest stages, only 25% of examined slices contained beta cells, in very small numbers. Thus, insulin-positive cells seemed to emerge around midgestation (30 days pc). Glucagon cells were seen far more frequently. In the pancreatic buds, both cell types were isolated and scattered throughout the bud.

By day 36 pc, counts of both cell types were higher but alpha cells still predominated. The endocrine cells were chiefly seen near the trunks of the branched epithelial system; most were isolated, although small clusters of alpha or beta cells were found. On day 45 pc, the clusters were larger and some of them contained both alpha and beta cells.

## Late gestation and early postnatal life

Figure 2 A-B shows the pancreases during the perinatal period (55 days pc, postnatal day 1, and 8 weeks after birth). At this last stage, the global organization of the pancreatic tissue was fully mature (Figure 2B). The beta cells were more numerous than at earlier stages and than the alpha cells (see quantification below). Both the alpha and the beta cells formed clusters, and small islet-like structures were visible.

## Adult pancreas



Figure 3 shows the mature endocrine pancreas of an adult dog. Although isolated alpha and beta cells were visible, most of these endocrine cells were organized into aggregates or, more frequently, islets. Islet size varied widely; examples of small (panel A) and larger (panel B) islets are shown. Although glucagon cells were seen in the periphery of some of these islets, they showed no systematic pattern of distribution and, in many islets, they intermingled with beta cells. In some instances, aggregates containing only beta cells (panel C) or only alpha cells (panel D) were found.

#### **Quantification of alpha and beta cells (Figure 4)**

The proportion of beta cells increased gradually, from 2.7% on day 30 pc to 42.3% on day 55 pc. After birth, this proportion continued to rise. At weaning (8 weeks of age), the beta cell proportion reached 61.06% , a proportion still significantly lower than the proportion found in adult pancreas (87.02%).

#### **Comparisons across breeds**

We compared pancreatic morphology at 45 days pc in a Beagle and a Labrador and on postnatal day 1 in a Beagle and a Chow Chow (Figure 5). At both time points, the two breeds were similar regarding the general morphology of the branched pancreatic epithelium and the number and distribution of alpha and beta cells. On postnatal day 1, clusters or islets of endocrine cells were visible in both breeds.

## **DISCUSSION**

In the mammalian pancreas, endocrine cells cluster into islets of Langerhans, which are embedded in the exocrine tissue and secrete insulin, glucagon, and other polypeptide hormones into the bloodstream. These islets have been extensively studied in adult mammals and are conserved across species (8, 9). The development of the fetal and postnatal endocrine pancreas has been studied in depth in rodents (10) and humans (11, 12) but not in other mammals. The objective of this work was to describe the differentiation and growth of alpha and beta cells from early fetal to postnatal life in the Beagle dog. We found that beta cells emerged from the pancreatic bud at midgestation in dogs. However, in the Beagle dog and two other dog breeds, the fully mature endocrine structure was not present until early postnatal life. During prenatal life, alpha cells outnumbered beta cells. The ratio of beta to alpha cells increased during fetal life and after birth. Importantly even at 8 weeks of age, i.e., at weaning, the ratio remained below the adult value. Since we measured the percentage of either alpha or beta cells relative to the total population of alpha plus beta cells, the increase in the beta/alpha cell ratio does not necessarily indicate expansion of the beta cell mass after weaning. A possible bias is that the size and cellular composition of the canine islets vary according to their location in the adult pancreas and tend to increase along a gradient from the right to the left lobe. (8, 9,13, 14). Alpha and beta cell counts during antenatal and early postnatal life were determined on several pancreatic slices that were representative of the entire organ. Consequently, comparing them to the values obtained in a single part of the adult pancreas may not be entirely valid. However it should be noted that, according to most authors cited above, the left right lobe is less rich in beta cells and therefore our decision to compare our data during fetal and post natal life to the right pancreatic adult lobe underestimate the density of beta cells in the adult stage.

Since the pioneering work conducted by Pictet et al. in rats and reported in 1972 (15), the morphological development of the pancreas has been studied in great detail, chiefly in mice. Three developmental stages have been identified. The first phase, known as the primary transition period, is the early undifferentiated stage during which morphogenesis occurs. The prepatterned endodermal epithelium of the foregut develops into branching ducts and undifferentiated epithelium. In mice, this occurs between embryonic days (E) 8.5 and E-12.5. The secondary transition extends in mice from E-13 to birth. The buds begin to differentiate into endocrine and exocrine cellular lineages by E-14 and the pancreatic epithelium proliferates and expands extensively. By E-15, the dorsal and ventral pancreatic buds rotate and fuse, and the pancreas is almost fully developed by E-19, i.e., just before birth. At that stage, the pancreas contains endocrine cells organized into isolated clusters that condense into islets of Langerhans (third developmental transition). Finally, the postnatal period of development extends over the first 2-3 postnatal weeks, during which the endocrine cells become mature and acquire full nutrient responsiveness.

Recently, Jennings and colleagues (16) have reviewed the development of human pancreas and compared it with mice. In light of such study our data suggests that pancreatic ontogenesis in dogs resembles that in mice. Although the equivalent in dogs to the primary transition in mice cannot be firmly established using endocrine markers only, our results suggest that insulin expression start at midgestation (30 and 33 days pc), i.e., the time of the primary transition in mice. The enlargement of the pancreas and the expansion and branching out of the epithelium with the formation of trunk and tip domains replicate the secondary transition; and the development after 55 days pc matches the postnatal period. In humans, in contrast, beta cells become detectable at the beginning of the second trimester of gestation (16). As illustrated figure

6, the time-pattern of beta-cell development in dogs is more closely similar to that in rodents than in humans, although the mature beta-to-alpha cell ratio is reached much later than in mice and other species.

Genetic studies in mice and humans (16-18) have led to the identification of a vast number of transcription factors that participate in pancreatic organogenesis. Our findings indicate that the key morphological events of pancreatic development described in mice and humans also occur in dogs. Immunohistological studies provide valuable information on morphology, but not on function. Thus, whether the transcriptional regulatory mechanisms governing pancreatic development in dogs are identical to those in rodents cannot be determined from our work. Further studies are needed to elucidate this point.

Several immunocytochemical studies of the distribution of beta and alpha cells in normal adult canine pancreatic islets have been published (11,12). Our results agree with previous anatomical studies showing that, in addition to fully formed islets, small beta-cell aggregates and a few isolated alpha cells can be seen. In the islets, the alpha (glucagon) cells were usually in a peripheral location (11, 12). In the adult Labrador in our study, the alpha cells were intermingled with the beta cells within fully formed islets instead of being confined to the periphery. However, only the right lobe of the pancreas was examined, and differences have been reported between the right and left lobes. Thus, variations in the size and cellular composition of canine islets depending on location in the pancreas may explain the discrepancies between our findings and those reported by others. A detailed morphological comparison between islets from the head (right lobe) and tail (left lobe) is needed.

Although we used Beagle dogs for most of our studies, we also studied two other breeds. We were thus able to compare the findings in Beagle dogs with those in a Labrador at 45 days pc

and in a Chow Chow on postnatal day 1. The endocrine cell clusters were similarly distributed between breeds at both ages. On day 45 pc, alpha cells predominated and beta and alpha cells formed aggregates that did not exhibit the islet structure. On postnatal day 1, in contrast, alpha and beta cells were present in comparable numbers and aggregated into clusters that resembled islets without having the typical architecture of mature islets. These data suggest that pancreatic development may be similar across dog breeds.

In conclusion, our data demonstrate that beta cells are visible by midgestation and that islets form a few days before delivery in dogs. We did not evaluate whether the beta cells secreted insulin, thereby regulating the fetal glucose metabolism. Further studies are needed to elucidate the functional capabilities of the fetal pancreas. The morphological data reported here should prove

## REFERENCES

- 1- Obenshain SS, Adam PA, King KC, Teramo K, Raivo KO, Raïhia N, and Swartz R. Human fetal insulin response to sustained maternal hyperglycemia. *N Eng J Med.* 1970; 283: 566-570
- 2- HAPO Study Cooperative Research Group, Metzger BE, Lowe LP, Dyer AR, Trimble ER, Chaovarindr U, Coustan DR, Hadden DR, McCance DR, Hod M, McIntyre HD, Oats JJ, Persson B, Rogers MS, Sacks DA. Hyperglycemia and adverse pregnancy outcomes. *N Engl J Med.* 2008; 358:1991-2002.
- 3-Polak M, Cavé H Neonatal diabetes mellitus: a disease linked to multiple mechanisms. 2007 Mar 9; 2:12. *Orphanet J Rare Dis.*
- 4-Kosztolanyi G. Leprechaunism/Donohue syndrome/insulin receptor gene mutations: a syndrome delineation story from clinicopathological description to molecular understanding. *Eur J Pediatr.* 1997; 156:253-255
- 5-Aldoretta PW, Carver TD, Hay WW Jr. Maturation of glucose-stimulated insulin secretion in fetal sheep. *Biol Neonate.* 1998; 73: 375-386.

- 6-Mintz DH, Chez RA, Horger EO 3<sup>rd</sup>. Fetal insulin and growth hormone metabolism in the subhuman primate. *J Clin Invest.* 1969; 48:176-186
- 7 – In Miller's Anatomy of the dog 4<sup>th</sup> Edition. Evans HE and de Lahuna A Ed Elsevier Publisher 2013 Page 13-60
- 8- Steiner DJ, Kim A, Miller K, Hara M. Pancreatic islet plasticity: interspecies comparison of islet architecture and composition. *Islets.* 2010;2:135-145
- 9- Tsuchitani M, Sato J and Kokoshima H A comparison of the anatomical structure of the pancreas in experimental animal *J Toxicol Pathology* 2016 ; 29: 147-154
- 10- Jørgensen MC, Ahnfelt-Rønne J, Hald J, Madsen OD, Serup P, Hecksher-Sørensen J. An illustrated review of early pancreas development in the mouse. *Endocr Rev.* 2007 ;28:685-705.
- 11- Béringue F, Blondeau B, Castellotti MC, Bréant B, Czernichow P, Polak M. Endocrine pancreas development in growth-retarded human fetuses. *Diabetes.* 2002 ;51:385-91.
- 12- Polak M1, Bouchareb-Banaei L, Scharfmann R, Czernichow P. Early pattern of differentiation in the human pancreas. *Diabetes.* 2000 Feb;49(2):225-32.
- 13- Justice D, Cruccioli N, Roque C, Gallas JF, Remandet B, Cahard, D. Etude morphométrique des îlots de Langerhans du pancréas du chien Beagle. *Rev Fr Histotechnol.* 1997; 10: 45-49,14-Wieczorek G, Pospicshil A, Perentes E.A comparative immunohistochemical study of pancreatic islets in laboratory animals (rats, dogs, minipigs, nonhuman primates). *Exp; toxicol. Pathol* 1998; 50: 151-172.
- 15- Pictet RL, Clark WR, Williams RH, Rutter WJ. An ultrastructural analysis of the developing embryonic pancreas. *Dev. Biol.* 1972; 29: 436-467.
- 16- Jennings RE, Berry AA, Strutt JP, Gerrard DT, Hanley NA. Human pancreas development. *Development.* 2015; 142: 3126-3137
- 17-Cano DA, Soria B, Martín F, Rojas A. Transcriptional control of mammalian pancreas organogenesis. *Cell. Mol. Life Sci.* 2014; 71: 2383-2402
- 18- Habener JF, Kemp DM, Thomas MK. Minireview: transcriptional regulation in pancreatic development. *Endocrinology.* 2005;146:1025-1034

#### CONFLICT OF INTEREST:

Paul Czernichow, and Philippe Ravassard are own shares in Animal Cell Therapy.

#### ACKNOWLEDGMENTS

We thank the Alfort Veterinary School clinicians for their invaluable help in collecting prenatal and postnatal canine tissues.

**Funding:** This research project was partly supported by funding from the BPI-France AIMA Programme under grant agreement #DA15005Q00/05

## FIGURE LEGENDS

### **Figure 1: Dog pancreas development and endocrine cell distribution during the third quarter of dog gestation**

(A) Immunostaining of endocrine markers, insulin (red) and glucagon (green) on 4- $\mu$ m paraffin sections on either dissected midgut tube for dog embryos at 30 and 33 days pc (E-30, E-33) or dissected pancreas from dog fetuses at 36 to 45 days pc. The left-hand columns show large-field images of the immunostained slices. The arrow heads on the images at 36 days pc point to trunks and branch tips of the later-stage epithelia and those at 45 days pc to large cell clusters containing both alpha and beta cells. For each developmental stage, a higher magnification of the area delineated by a dotted line is shown in the other columns. Nuclei were stained with DAPI (blue). Large-field scale bars, 100  $\mu$ m, Insert scale bars, 20  $\mu$ m.

(B) Hematoxylin and eosin (HE) staining of adjacent sections shown in (A). At 30 and 33 days pc, the pancreatic bud (PB) displays branching of the epithelium. By 36 days pc, tubular epithelium is visible, with trunks and branched tips. Scale bars, 100  $\mu$ m

**Figure 2: Dog pancreas development and endocrine cell distribution during the perinatal period and before weaning**

(A) Development of the dog pancreas and distribution of endocrine cells within the gland during the perinatal period and immediately before weaning at 8 weeks of age

Immunostaining for insulin (red) and glucagon (green) on 5- $\mu$ m paraffin sections of dog pancreases from an embryo on day 55 pc a newborn on postnatal day 1 (PND-1), and a pup just before weaning at week 8 (PNW-8). Insulin and glucagon staining are shown separately in the left and middle panels, respectively, and merged in the right panel. The nuclei were stained with DAPI (blue). The arrow heads point to cell clusters containing both insulin and glucagon cells and having an islet-like morphology. Scale bars, 20  $\mu$ m

(B) Hematoxylin and eosin (HE) staining of adjacent sections shown in (A). Scale bars, 100  $\mu$ m

**Figure 3: Endocrine cells in the adult dog pancreas are organized into islets.**

Immunostaining for insulin (red) and glucagon (green) on 5- $\mu$ m paraffin sections from the right lobe of the pancreas of an adult dog. The top panel is a large-field image of the immunostained section. The rectangles A through D delineated by dotted lines are shown at a higher magnification in the bottom panel. The nuclei were stained with DAPI (blue). Large-field scale bars, 500  $\mu$ m; magnified image scale bars, 20  $\mu$ m

**Figure 4: Comparison of beta and alpha cell proportions throughout the development of the dog pancreas and in adulthood**

The proportions of beta (red) and alpha (green) cells among total alpha and beta cells were determined. The data are mean  $\pm$  SEM of total cell counts per slice. The unpaired Student's



*t* test was used to assess whether differences between stages were significant. Values of *p* are shown. n.s., not significant.

**Figure 5: Comparison of endocrine cell distribution in the developing pancreas of different dog breeds**

Immunostaining for insulin (red) and glucagon (green) on 4- $\mu$ m and 5- $\mu$ m paraffin sections of dog pancreases from Beagle or Labrador fetuses at 45-46 days pc (F-45, F-46) and from Beagle or Chow-Chow neonates on postnatal day 1 (D1). The column on the left shows large-field images of the immunostained sections. The rectangles delineated by dotted lines are shown at a higher magnification to the right of each large-field view. The nuclei were stained with DAPI (blue). Large-field scale bars, 100  $\mu$ m for embryo pancreases and 50  $\mu$ m for newborn pancreases; magnified-image scale bars, 20  $\mu$ m

**Figure 6 Comparative scheme of endocrine pancreas development in human mouse and dog.**

Total gestation time is indicated as 100% for the three species. Key steps of endocrine differentiation are indicated such as: first insulin positive cell, onset of branching, tip-trunk segregation and first islet like structure.

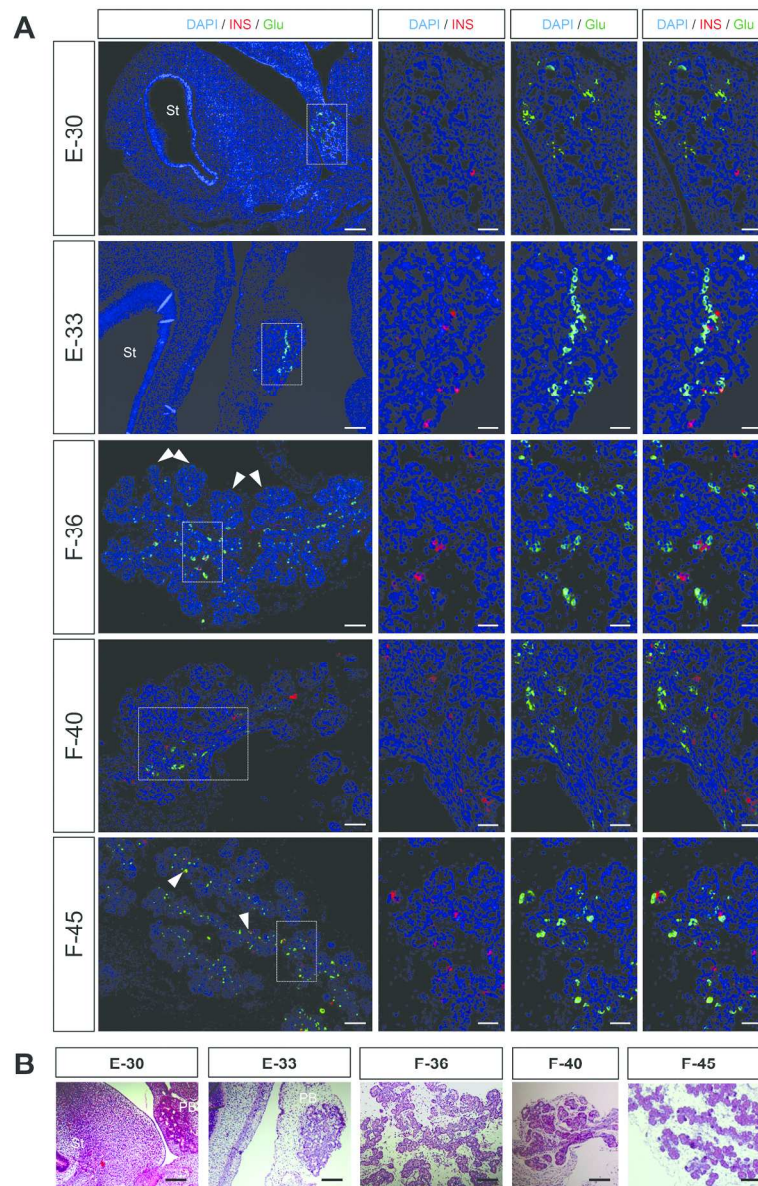


Figure 1: Dog pancreas development and endocrine cell distribution during the third quarter of dog gestation

252x386mm (300 x 300 DPI)

AC

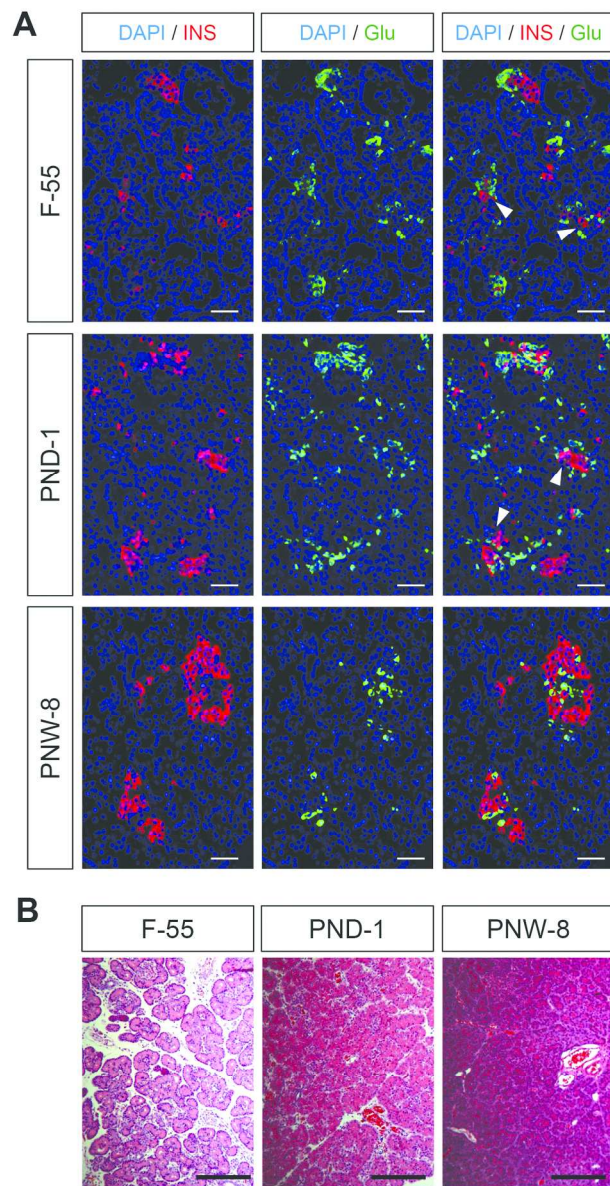


Figure 2: Dog pancreas development and endocrine cell distribution during the perinatal period and before weaning

228x307mm (300 x 300 DPI)



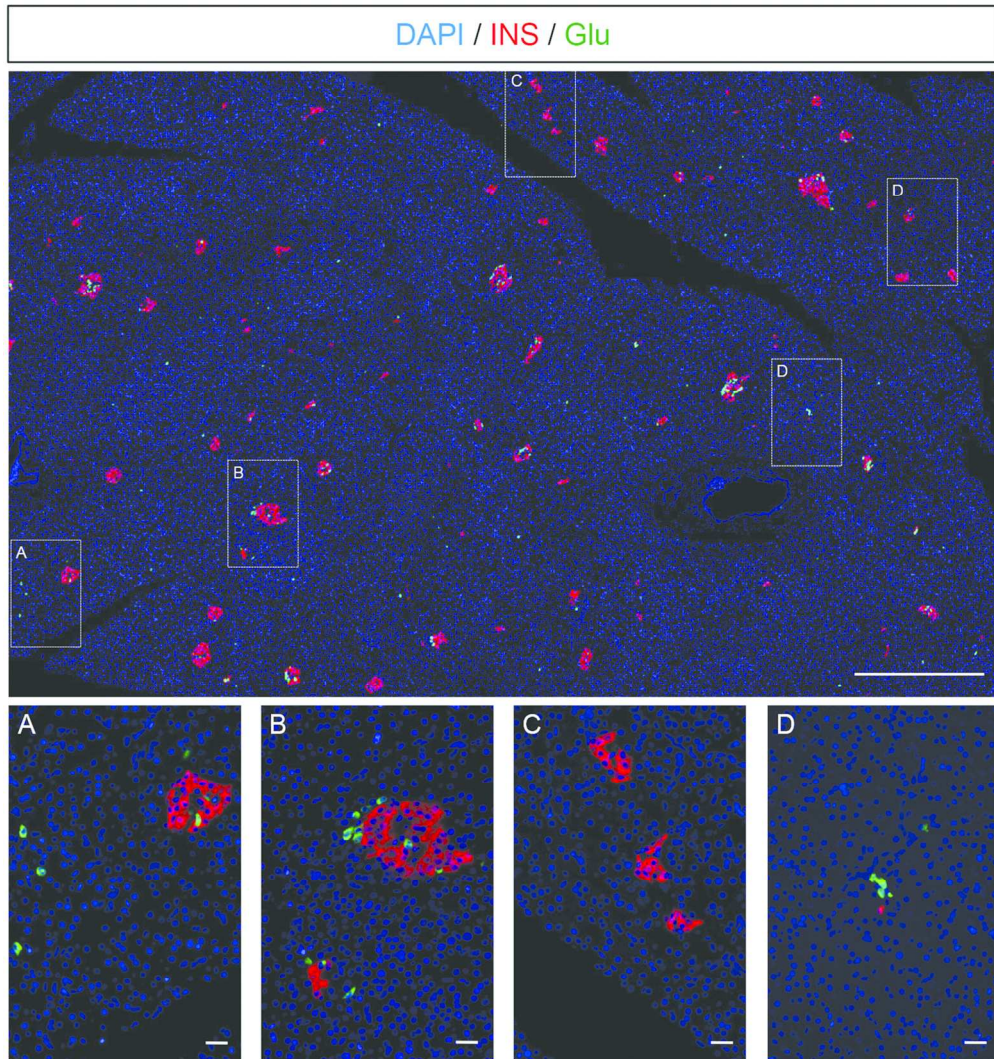


Figure 3: Endocrine cells in the adult dog pancreas are organized into islets.

139x150mm (300 x 300 DPI)

ACC

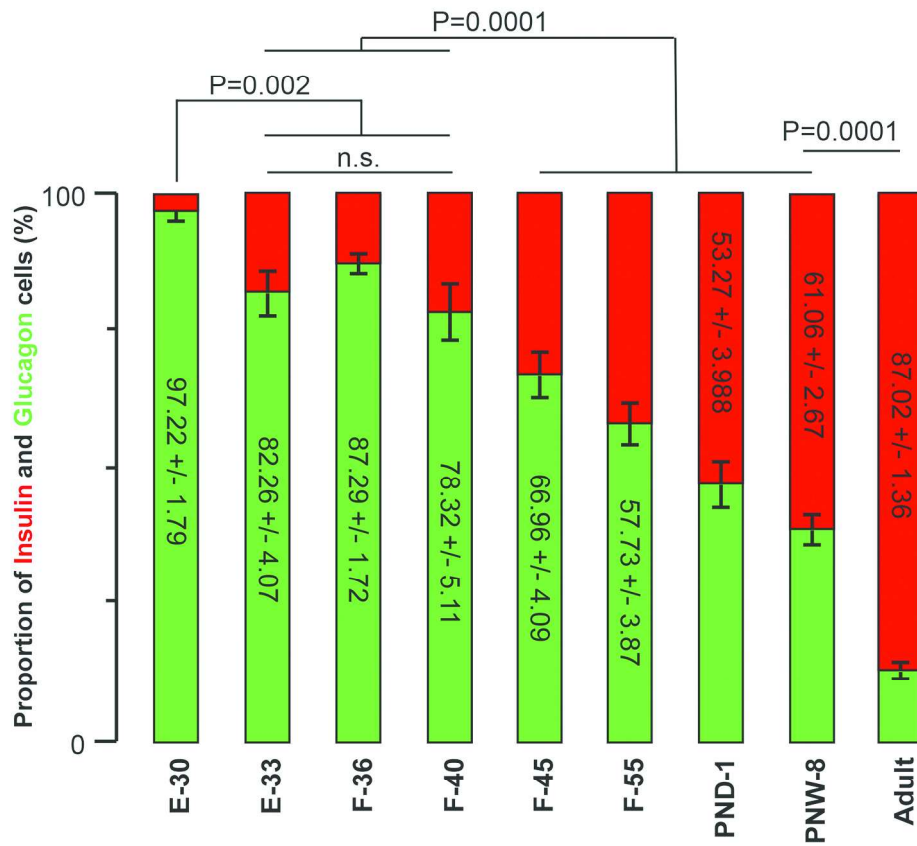


Figure 4: Comparison of beta and alpha cell proportions throughout the development of the dog pancreas and in adulthood

114x103mm (600 x 600 DPI)

Acce



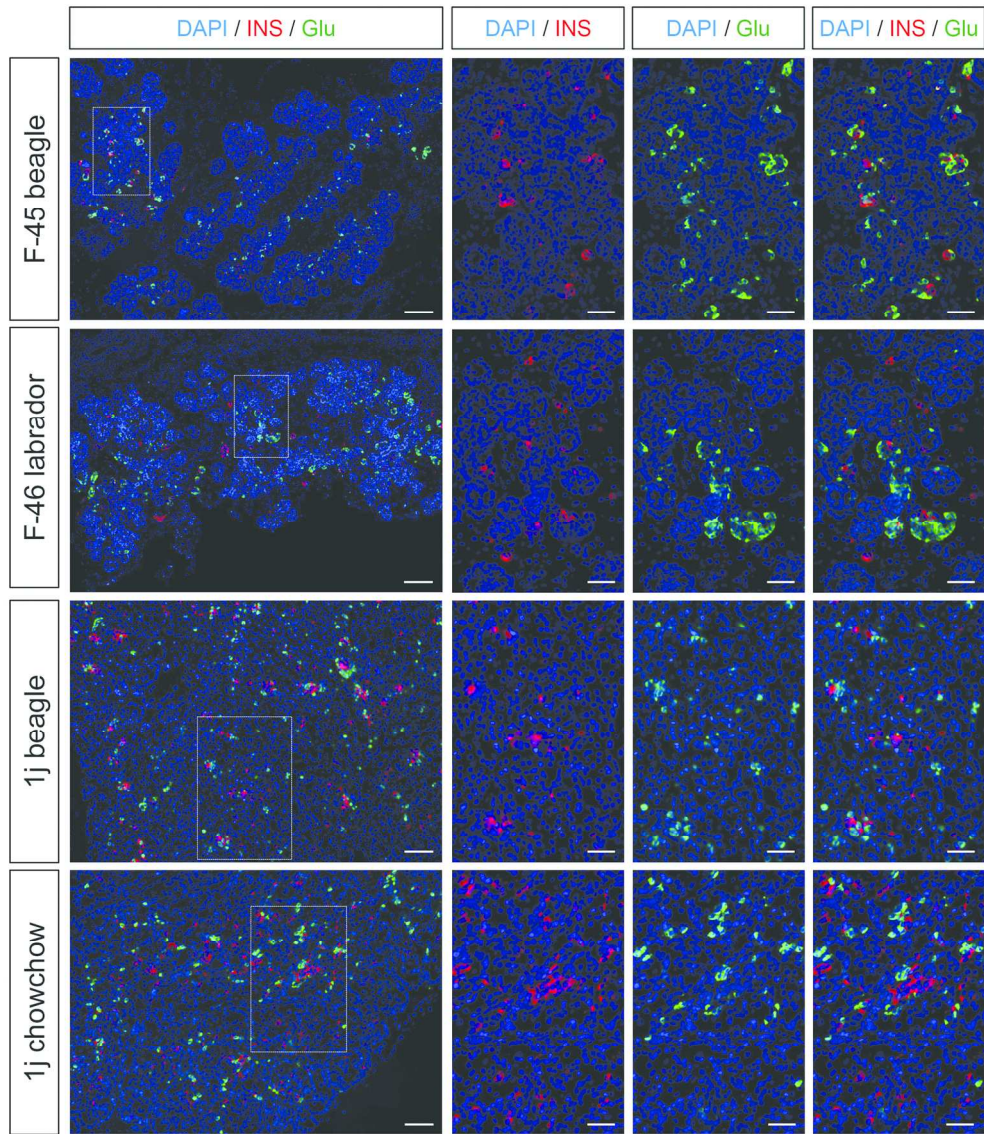


Figure 5: Comparison of endocrine cell distribution in the developing pancreas of different dog breeds

202x232mm (300 x 300 DPI)

AC

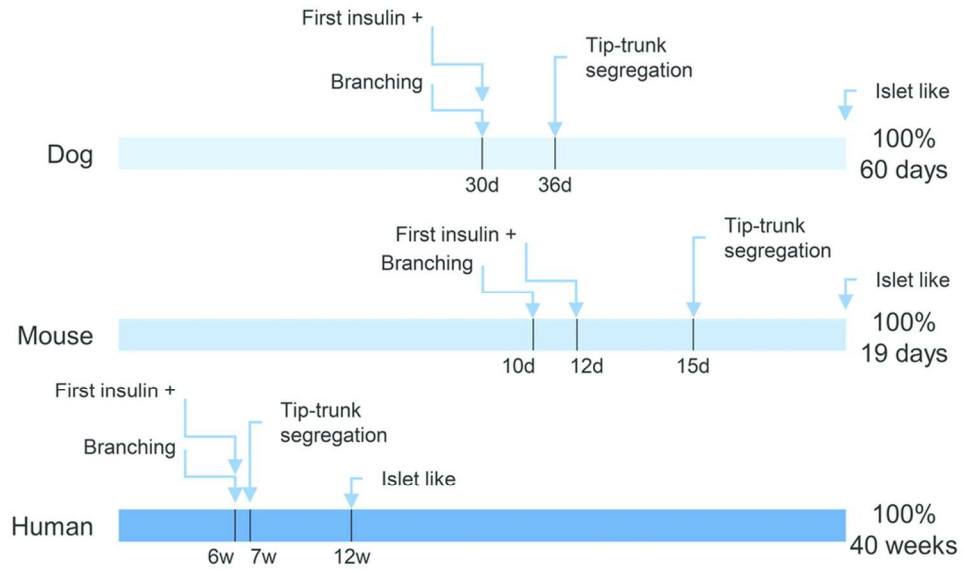


Figure 6 Comparative scheme of endocrine pancreas development in human mouse and dog.

45x26mm (600 x 600 DPI)

Accepted

Table 1 Antenatal and postnatal specimen obtained for the study

| Development stages (days post conception) | Breed   | Tissues Dissected | Number of slices analyzed /number of slices performed |
|---|---------|-------------------|---|
| <b>30 days</b>                            | Beagle  | Pancreas+ stomach | <b>300/300</b>  |
| <b>33 days</b>                            | Beagle  | Pancreas+ stomach | <b>50/273</b>   |
| <b>36 days</b>                            | Beagle  | Pancreas          | <b>30/295</b>   |
| <b>40 days</b>                            | Beagle  | Pancreas          | <b>50/240</b>   |
| <b>45 days</b>                            | Beagle  | Pancreas          | <b>73/495</b>   |
| <b>55 days</b>                            | unknown | Pancreas          | <b>37/168</b>   |
| <b>1 day postnatal</b>                    | Beagle  | Pancreas          | <b>52/268</b>   |
| <b>8 weeks postnatal</b>                  | Beagle  | Pancreas          | <b>42/216</b>   |



Table 2. Description of the samples obtained for the comparison of different dog breeds

| Developmental stage (pc, postconception) | Breed     | Tissues  | Number of slices analyzed /number of slices obtained |
|--|-----------|----------|--|
| <b>45 days pc</b>                        | Beagle    | Pancreas | <b>73/495</b>  |
| <b>46 days pc</b>                        | Labrador  | Pancreas | <b>32/228</b>  |
| <b>postnatal day 1</b>                   | Beagle    | Pancreas | <b>52/268</b>  |
| <b>postnatal day 1</b>                   | Chow Chow | Pancreas | <b>10/60</b>   |