



HAL
open science

Netrin-1 up-regulation in inflammatory bowel diseases is required for colorectal cancer progression

Andrea Paradisi, Carine Maise-Paradisi, Marie-May Coissieux, Nicolas Gadot, Florian Lépinasse, Céline Delloye-Bourgeois, Jean-Guy Delcros, Magali Svrcek, Clemens Neufert, Jean-François Fléjou, et al.

► **To cite this version:**

Andrea Paradisi, Carine Maise-Paradisi, Marie-May Coissieux, Nicolas Gadot, Florian Lépinasse, et al.. Netrin-1 up-regulation in inflammatory bowel diseases is required for colorectal cancer progression. Proceedings of the National Academy of Sciences of the United States of America, 2009, 106 (40), pp.17146-17151. 10.1073/pnas.0901767106 . hal-01604345

HAL Id: hal-01604345

<https://hal.science/hal-01604345v1>

Submitted on 31 May 2020

HAL is a multi-disciplinary open access archive for the deposit and dissemination of scientific research documents, whether they are published or not. The documents may come from teaching and research institutions in France or abroad, or from public or private research centers.

L'archive ouverte pluridisciplinaire **HAL**, est destinée au dépôt et à la diffusion de documents scientifiques de niveau recherche, publiés ou non, émanant des établissements d'enseignement et de recherche français ou étrangers, des laboratoires publics ou privés.

Netrin-1 up-regulation in inflammatory bowel diseases is required for colorectal cancer progression

Andrea Paradisi^{a,1}, Carine Maisee^{a,1}, Marie-May Coissieux^a, Nicolas Gadot^b, Florian Lépinasse^c, Céline Delloye-Bourgeois^a, Jean-Guy Delcros^a, Magali Svrcek^d, Clemens Neufert^e, Jean-François Fléjou^d, Jean-Yves Scoazec^{b,c,2}, and Patrick Mehlen^{a,2,3}

^aApoptosis, Cancer and Development Laboratory-Equipe labellisée "La Ligue," Centre National de la Recherche Scientifique, Unite Mixte de Recherche 5238, Université de Lyon, Centre Léon Bérard, 69008 Lyon, France; ^bANIPATH, Faculté Laennec, 69372 Lyon Cedex 08, France; ^cInstitut National de la Santé et de la Recherche Médicale, U865, Faculté Laennec, 69372 Lyon Cedex 08, France; ^dAssistance Publique-Hôpitaux de Paris, Hôpital Saint-Antoine, Service d'Anatomie et Cytologie Pathologiques and Institut National de la Santé et de la Recherche Médicale, Unite Mixte de Recherche 5893, Team 13 Microsatellite Instability and Cancers, 75012 Paris, France; and ^eFirst Medical Clinic and Institute for Molecular Medicine, Johannes Gutenberg University of Mainz, 51131 Mainz, Germany

Edited by Bert Vogelstein, The Sidney Kimmel Comprehensive Cancer Center at Johns Hopkins, Baltimore, MD, and approved July 20, 2009 (received for review February 17, 2009)

Chronic inflammation and cancer are intimately associated. This is particularly true for inflammatory bowel diseases (IBD), such as ulcerative colitis and Crohn's disease, which show a major increased risk for colorectal cancer. While the understanding of the molecular pathogenesis of IBD has recently improved, the mechanisms that link these chronic inflammatory states to colorectal cancer development are in large part unknown. One of these mechanisms is NF- κ B pathway activation which in turn may contribute to tumor formation by providing anti-apoptotic survival signals to the epithelial cells. Based on the observation that netrin-1, the anti-apoptotic ligand for the dependence receptors DCC and UNC5H is up-regulated in colonic crypts in response to NF- κ B, we show here that colorectal cancers from inflammatory bowel diseases patients have selected up-regulation of netrin-1. Moreover, we demonstrate that this inflammation-driven netrin-1 up-regulation is causal for colorectal cancer development as interference with netrin-1 autocrine loop in a mouse model for ulcerative colitis-associated colorectal cancer, while showing no effect on inflammation, inhibits colorectal cancer progression.

Inflammatory bowel diseases (IBD), such as ulcerative colitis and Crohn's disease, show a major increased risk for colorectal cancer, but the mechanisms that link these chronic inflammatory states to colorectal cancer development are in large part unknown. The main non-immune link known so far is the activation of NF- κ B (1). It was indeed proposed that NF- κ B pathway activation observed during IBD may contribute to tumor formation by providing anti-apoptotic survival signals to the epithelial cells (1). Of interest, netrin-1, a soluble protein initially discovered as an axon navigation cue (2), was also proposed to play a crucial role during colorectal tumorigenesis by regulating apoptosis (3). Indeed, netrin-1 receptors DCC and UNC5H—that is, UNC5H1, UNC5H2, UNC5H3, and UNC5H4, also called UNC5A, UNC5B, UNC5C, or UNC5D—belong to the so-called dependence receptor family (4–6). These dependence receptors, because of their ability to induce cell death when disengaged from their ligands, create cellular states of dependence on their respective ligands (7) and, consequently, may behave as tumor suppressors because they eliminate tumor cells that would develop in settings of ligand unavailability (3, 8).

Along this line, both overexpression of netrin-1 or inactivation of UNC5H3 in mice in the gastro-intestinal tract are associated with intestinal tumor progression (3, 9). Even though according to the dependence receptor hypothesis, a loss of netrin-1 receptors should represent a similar selective advantage for tumor growth than gaining autocrine expression of netrin-1, in sporadic colorectal cancer the vast majority of tumors display a loss of DCC or/and UNC5H (9–12). In these tumors with decreased receptors expression, netrin-1 is not up-regulated and is barely detectable within the tumors [(Fig. 1A) and (13)]. Interestingly,

the fraction of colorectal cancer showing netrin-1 up-regulation—rather than netrin-1 receptors losses—frequently display high expression of markers of NF- κ B activation such Cox-2 and I κ B α (13). Together with the observation that *netrin-1* gene is a transcriptional target for NF- κ B (13) and with the view of IBD-associated colorectal cancer being linked to NF- κ B and survival (1), we investigated whether netrin-1 may be involved in progression of IBD-associated colorectal cancer.

Results and Discussion

First, we analyzed by immunohistochemistry netrin-1 expression in the colonic mucosa of 30 patients with IBD (15 with ulcerative colitis, 15 with Crohn's disease). In all cases, a strong expression of netrin-1 was detected in epithelial cells, especially in areas of inflammation (Fig. 1B and not shown); the apparent expression levels were markedly higher than in the normal colonic mucosa (Fig. 1A and B). We then compared the expression of netrin-1 in a panel of colorectal adenocarcinomas from 30 patients with IBD (24 with ulcerative colitis, six with Crohn's disease), and in a sample of 52 sporadic colorectal adenocarcinomas. While only seven out of 52 (13.5%) sporadic colorectal adenocarcinomas displayed high netrin-1 levels as compared to the internal controls, 21 out of the 30 tumors (70%) from IBD patients were shown to express high netrin-1 levels as compared to the same controls (Fig. 1A–C and data not shown) (χ^2 test, $P < 0.001$). A similar netrin-1 up-regulation in tumors from IBD patients was also observed at the mRNA level. Indeed, RNA from seven pairs tumor/normal tissue were extracted and netrin-1 level was analyzed by Q-RT-PCR analysis. Four out of the seven pairs tested showed at least a 3.3-fold increase of netrin-1 in the tumor, with an increase range from 3.3- to 18.4-fold.

In IBD patients, comparable levels of netrin-1 expression were observed in both lieberkuhnian and colloid adenocarcinomas, irrespective of their clinical stage (Fig. 1Bv and Bvi). We finally tested the expression of netrin-1 in the spectrum of dysplastic lesions of the colon observed in surgical specimens from 25 patients with IBD (21 with ulcerative colitis, four with Crohn's disease). In flat dysplasia, netrin-1 was constantly detected; the

Author contributions: A.P., C.M., J.-Y.S., and P.M. designed research; A.P., C.M., M.-M.C., N.G., F.L., C.D.-B., and J.-G.D. performed research; M.S., C.N., and J.-F.F. contributed new reagents/analytic tools; A.P., C.M., C.D.-B., J.-Y.S., and P.M. analyzed data; and J.-Y.S. and P.M. wrote the paper.

The authors declare no conflict of interest.

This article is a PNAS Direct Submission.

¹A.P. and C.M. contributed equally to this work.

²J.-Y.S. and P.M. contributed equally to this work.

³To whom correspondence should be addressed. E-mail: mehlen@lyon.fnclcc.fr.

This article contains supporting information online at www.pnas.org/cgi/content/full/0901767106/DCSupplemental.

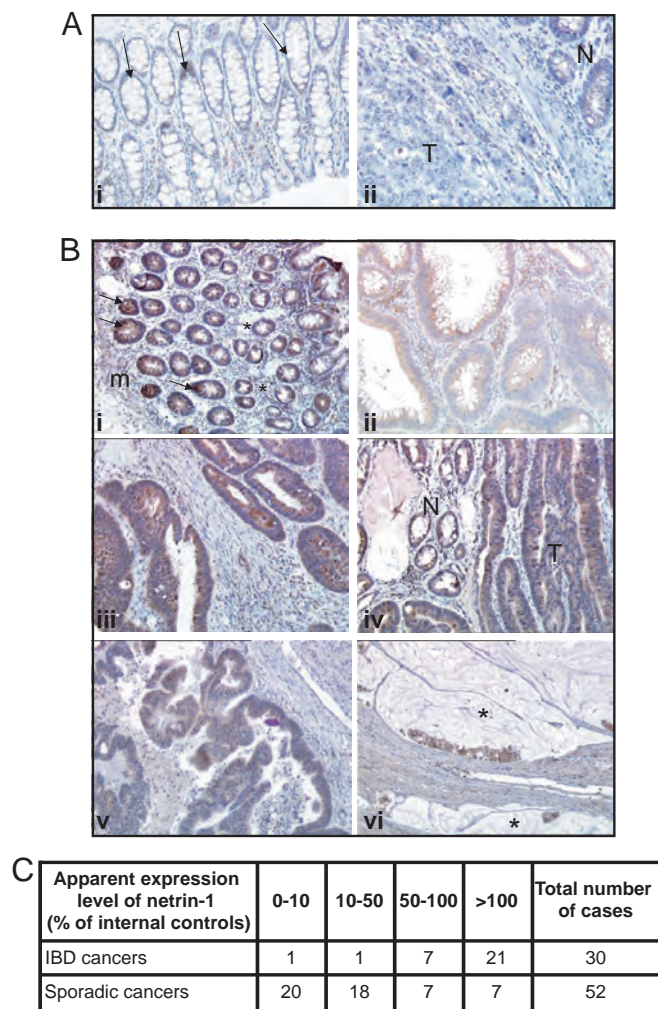


Fig. 1. Netrin-1 expression in neoplastic lesions from IBD and control patients. (A) Expression of netrin-1 in the normal colonic mucosa (i) and in a sporadic colon adenocarcinoma (ii). In the normal colonic mucosa (i), a faint labeling is visible in epithelial cells lining the crypts (arrows); there is a decreasing gradient of expression from the bottom of the crypts to the epithelium surface. In an example of well differentiated adenocarcinoma (ii), only a few cells are positive within the tumor (T), whereas the adjacent peritumoral mucosa (N) retains a readily visible staining. (B) Expression of netrin-1 in representative samples from inflamed mucosa (i) and neoplastic lesions (ii–vi) from IBD patients. In the inflamed mucosa (i), a strong netrin-1 labeling is visible, from the bottom of the crypts (arrows) to the surface; the gradient of expression visible in the normal colonic mucosa is partly preserved (m, muscularis mucosae). Netrin-1 labeling is well visible in epithelial cells at high magnification views of flat low grade dysplasia (ii) and flat high grade dysplasia (iii). Again, netrin-1 is strongly detected in an example of DALM (iv) with high grade dysplasia; the expression levels are comparable in the neoplastic area (T) and the adjacent peritumoral mucosa (N). Finally, netrin-1 is readily detected in two examples of colon adenocarcinoma: a typical lieberkuhnian adenocarcinoma (v) and a colloid mucous carcinoma (vi), characterized by the presence of massive mucous secretion (*). Indirect immunoperoxidase technique; original magnifications: (A) i, $\times 400$; ii, $\times 180$; (B) i, $\times 220$; ii, $\times 400$; iii, $\times 350$; iv, $\times 250$; v, $\times 120$; vi, $\times 100$. (C) Semiquantitative analysis of netrin-1 expression in colorectal cancer. Quantification of the apparent netrin-1 expression level was evaluated as described in the methods section via a comparison to an internal control. In IBD patients, netrin-1 apparent expression levels were comparable or higher to the internal control, while in sporadic cancer patients netrin-1 levels were much lower than the internal control.

apparent expression level was higher in high-grade lesions ($n = 6$) than in low grade lesions ($n = 15$). Netrin-1 was constantly detected in DALM (Dysplasia Associated Lesion or Mass) ($n = 9$), all of high grade but one (Fig. 1 Biv). In contrast, netrin-1 was

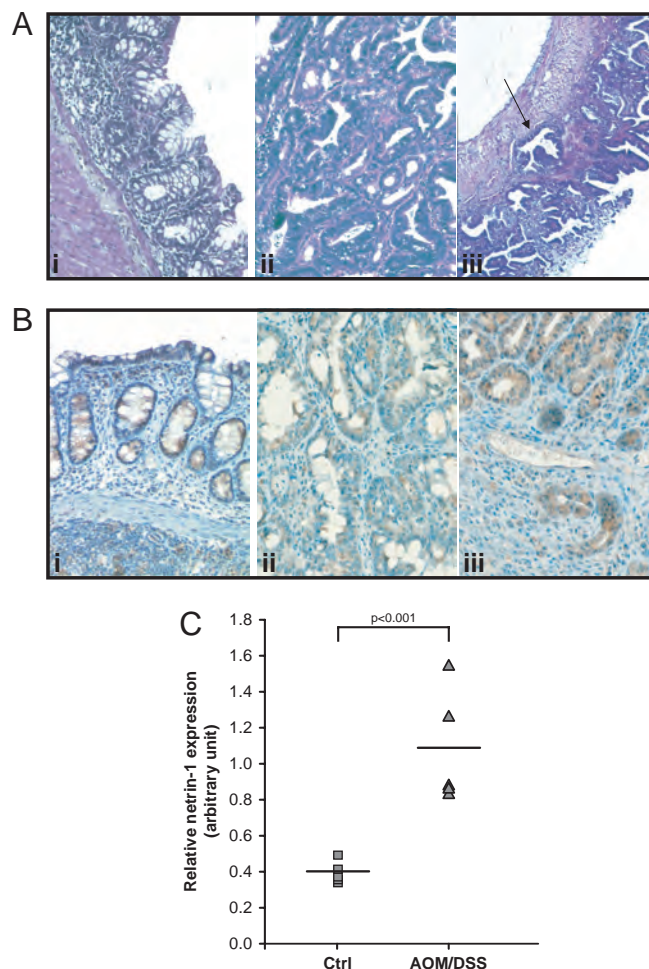


Fig. 2. Netrin-1 expression in a mouse model for inflammation-mediated colorectal tumor progression. (A) Representative colonic lesions in mice submitted to the DSS/AOM treatment. The flat mucosa (i) displays signs of chronic inflammation, with distorted crypts scattered within a lamina propria (*) containing numerous lymphocytes and plasma cells. Neoplastic lesions are illustrated by an example of high grade adenoma (ii), formed by numerous irregular tubular structures lined by markedly atypical cells, and by an example of focally invasive adenocarcinoma (iii), characterized by straight tumoral glands separated by an abundant stroma; note the presence of a neoplastic gland within the muscularis propria (arrow). These tumors fulfilled the diagnostic criteria for low grade and high grade adenomas and for adenocarcinomas (24); some adenocarcinomas showed signs of local invasion, such as the infiltration of the muscularis propria by neoplastic glands. (B) Immunodetection of netrin-1 in the non neoplastic inflamed mucosa (i), in neoplastic epithelial cells of a high grade adenoma (ii) and in neoplastic glands infiltrating the muscularis propria within an invasive adenocarcinoma (iii). Indirect immunoperoxidase technique. Original magnifications: i, $\times 480$; ii, $\times 380$; iii, $\times 300$. (C) Relative expression of netrin-1 mRNA in the colon of DSS/AOM-treated mice. Results from Q-RT-PCR are shown.

usually faintly expressed in the four cases of adenoma-like mass available for the study. Interestingly, while DCC has been described to be down-regulated in sporadic cancer in association with the chromosome 18q LOH (14), 28 out of the 30 tumors from IBD patients show a DCC expression that albeit detected at low level was not decreased in tumoral tissues compared to adjacent normal mucosa (data not shown). Thus, strong netrin-1 expression appears to be a characteristic feature of the whole spectrum of neoplastic lesions observed in IBD patients.

We then moved to an animal model for IBD-associated colorectal cancer. Adult mice were submitted to the DNA alkylation agent azoxymethane (AOM) and the pro-inflamma-

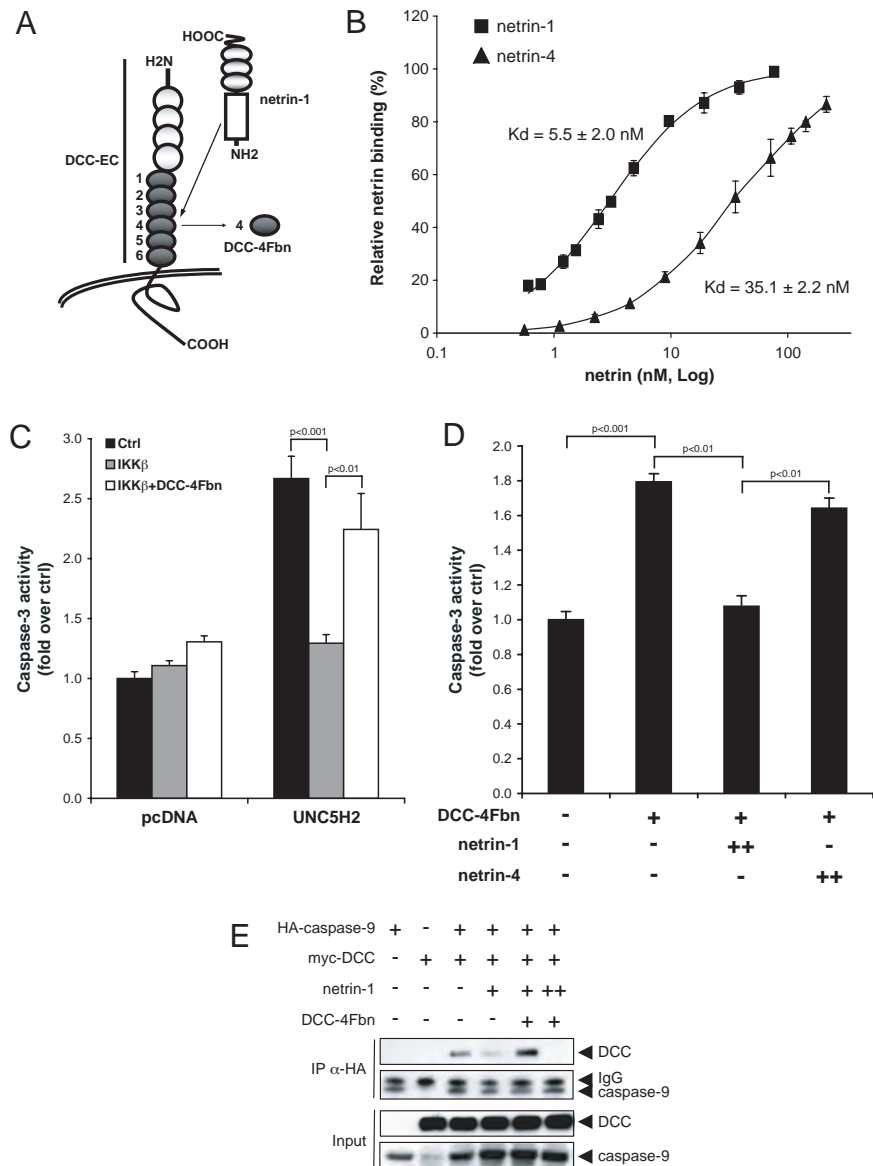


Fig. 3. DCC-4Fbn triggers apoptosis via interference with netrin-1-mediated inhibition of netrin-1 receptors death signaling. (A) Schematic representation of netrin-1 and one of its receptor DCC. Netrin-1 binds the extracellular domain of DCC (DCC-EC) via interaction with fibronectin type III domains (1–6). The fourth domain (DCC-4Fbn) used to induce cell death is indicated. (B) DCC-4Fbn direct binding to netrin-1. Increasing concentrations of flag-tagged netrin-1 were incubated with 5 μ g/mL DCC-4Fbn and bound netrin-1 was detected by immuno-labeling. DCC-4Fbn is able to bind netrin-1 with a K_d of 5.5 ± 2.0 nM. Note that DCC-4Fbn is able to weakly bind netrin-4, another member of the netrin family, with a consistent low K_d (35.1 ± 2.2 nM). The values represent the mean \pm standard deviation of three independent experiments. (C) Caspase-3 activity measured in UNC5H2-transfected HEK293T cells, incubated with conditioned medium from NF- κ B activated (IKK β) or control HBL100 cells, in presence or not of DCC-4Fbn (1 μ g/mL). Medium from IKK β -transfected cells was able to block caspase-3 activation induced by UNC5H2. This effect is due to the presence of netrin-1 produced and secreted by HBL100 cells in response to NF- κ B activation (13). DCC-4Fbn, added to conditioned medium, was able to restore caspase-3 activation in UNC5H2-transfected HEK293T cells incubated with IKK β medium by binding to, and inactivating secreted netrin-1. (D) Caspase-3 activity of HCT116 cells treated with DCC-4Fbn. HCT116 cells that express endogenous netrin-1 were treated or not with DCC-4Fbn (1 μ g/mL) in the presence or absence of an excess of netrin-1 or netrin-4. (E) Activation of DCC apoptotic pathway by DCC-4Fbn. HEK293T cells were co-transfected with HA-caspase-9 and myc-DCC constructs and treated with netrin-1 and/or DCC-4Fbn. Interaction of DCC and caspase-9 was assessed by pull-down using α -HA antibody and by revealing DCC using α -myc antibody. In presence of netrin-1, DCC binding to caspase-9 was decreased, while the addition of DCC-4Fbn (1 ng/mL) restored the interaction. Moreover, a high dose of netrin-1 (excess) was able to inhibit DCC-4Fbn action. Fig. S2 show expression level of netrin-1, netrin-3, and netrin-4 in a series of cancer cell lines.

tory reagent dextran sodium sulfate (DSS), leading to the development of inflammation driven colorectal tumors (15). After 10 weeks of treatment, signs of diffuse inflammation were present in the colonic mucosa; epithelial crypts were distorted and irregularly distributed in the lamina propria, which contained high numbers of inflammatory cells, including lymphocytes and plasma cells (Fig. 2*Ai*). Netrin-1 was strongly expressed in epithelial cells of inflamed mucosa (Fig. 2*Bi*).

Neoplastic lesions progressively developed in the inflamed mucosa (Fig. 2*Aii* and *Aiii*). All neoplastic lesions, including adenomas and adenocarcinomas, showed evidence of netrin-1 expression at immunohistochemical examination (Fig. 2*Bii* and *Biii*). This up-regulation of netrin-1 was not only detected at the protein level but was also observed at the RNA level by Q-RT-PCR analysis (Fig. 2*C*). Of interest, in agreement with the dependence receptor notion which predicts that a tumor selects

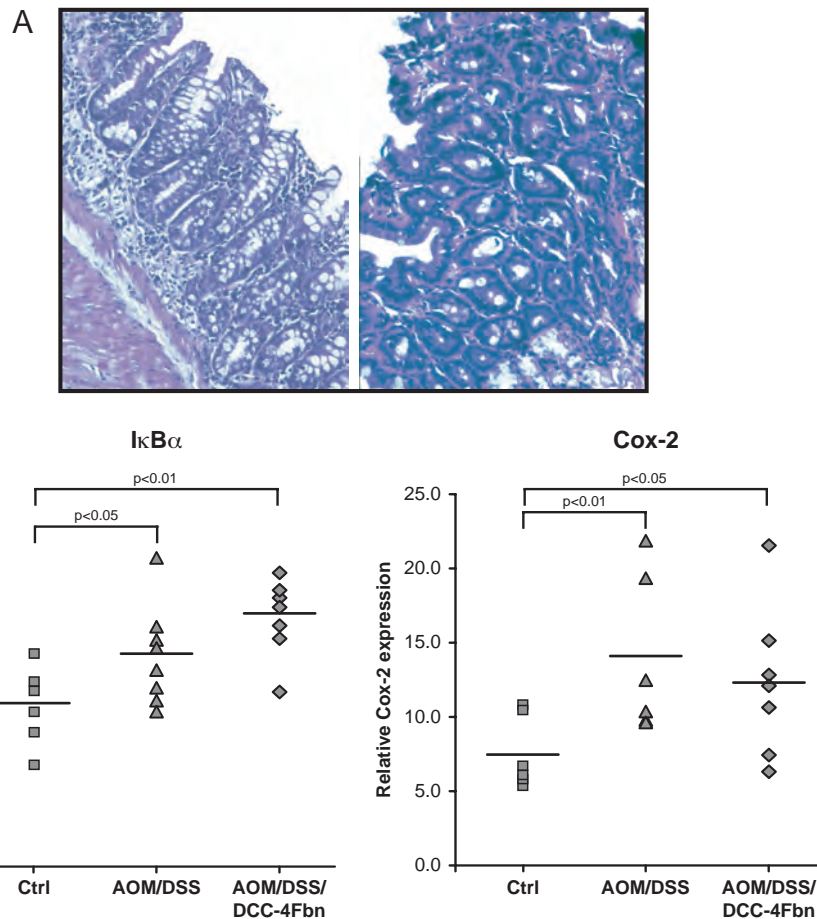


Fig. 4. Interference with netrin-1 does not affect chronic inflammation in a mouse model of IBD-associated colorectal cancer. (A) Representative colonic lesions in mice submitted to DSS/AOM treatment for 10 weeks and administered intra-peritoneally three times per week with DCC-4Fbn. The flat mucosa (Left) displays signs of chronic inflammation, as in control animals (Left). Neoplastic lesions are illustrated by an example of low grade adenoma (Right), formed by numerous regular tubular structures lined by slightly atypical cells. (B) IκBα and Cox-2 expression in DSS/AOM treated mice administered with DCC-4Fbn. IκBα and Cox-2 expression was measured by Q-RT-PCR.

either a gain of netrin-1 or a loss of netrin-1 receptors (16, 17), in AOM/DSS-associated tumors, the analysis of the netrin-1 receptors expression by Q-RT-PCR shows that UNC5H1, UNC5H2, UNC5H3, UNC5H4, or DCC were not down-regulated—that is, while UNC5H1 and UNC5H2 level was not significantly changed, UNC5H3, UNC5H4, and DCC were actually up-regulated- (Fig. S1).

To show whether this high netrin-1 level is causal to the cancer pathology, we analyzed whether titration of netrin-1 in mice treated with DSS/AOM could be associated with prevention of tumor progression. We used for this study DCC-4Fbn as a netrin-1 interfering agent. DCC-4Fbn is the 4th fibronectin domain of DCC ectodomain (Fig. 3A) and has been shown to interact with netrin-1 (18). To confirm the DCC-4Fbn/netrin-1 interaction, an ELISA was performed coating DCC-4Fbn and revealing a possible interaction with increased concentrations of either netrin-1 or netrin-4. As shown in Fig. 3B, the dissociation constant of netrin-1 was estimated to 5.5 nM, a K_d that is 6.4 lower than the K_d detected for DCC-4Fbn/netrin-4. Thus, DCC-4Fbn specifically interacts with netrin-1. This recombinant compound, even though it fails to prevent the interaction of netrin-1 with its receptors (data not shown), inhibits the ability of netrin-1 to block netrin-1 receptors death signaling in vitro. This was shown by the following experiments. First, in agreement with recent published observations (13), forced expression of UNC5H2 in HEK293T cells is associated with apoptosis unless

a conditioned medium from NF-κB activated cells is added. In these settings, addition of DCC-4Fbn reversed the anti-apoptotic effect provided by the conditioned medium (Fig. 3C). Second the HCT116 colorectal cancer cells express endogenous netrin-1 that has been shown to constitutively block UNC5H-induced apoptosis (19). As shown in Fig. 3D, the treatment with DCC-4Fbn of HCT116 cells triggers apoptosis unless an excess of netrin-1 is added to the culture medium. To further support the specificity of DCC-4Fbn in titrating netrin-1, netrin-4 was added in excess instead of netrin-1. As shown in Fig. 3D, netrin-4 was not able to inhibit DCC-4Fbn-induced apoptosis. Third, netrin-1 has been shown to inhibit DCC-mediated apoptosis by preventing DCC interaction with the apical caspase-9 (20, 21). To investigate whether DCC-4Fbn could block the inhibitory activity of netrin-1 on netrin-1 receptors death signaling, HEK293T cells were then co-transfected with DCC and caspase-9 and immunoprecipitations were performed in the presence or absence of netrin-1 and/or DCC-4Fbn. As shown in Fig. 3E, while caspase-9 interacts with DCC unless netrin-1 is added, the addition of DCC-4Fbn allows DCC/caspase-9 interaction even when netrin-1 is present. Altogether these data support the view that DCC-4Fbn acts as a netrin-1 titrating agent that triggers tumor cell death apoptosis by activation of netrin-1 receptors apoptotic pathway.

We thus analyzed whether titration of netrin-1 with DCC-4Fbn in mice treated with DSS/AOM could be associated with

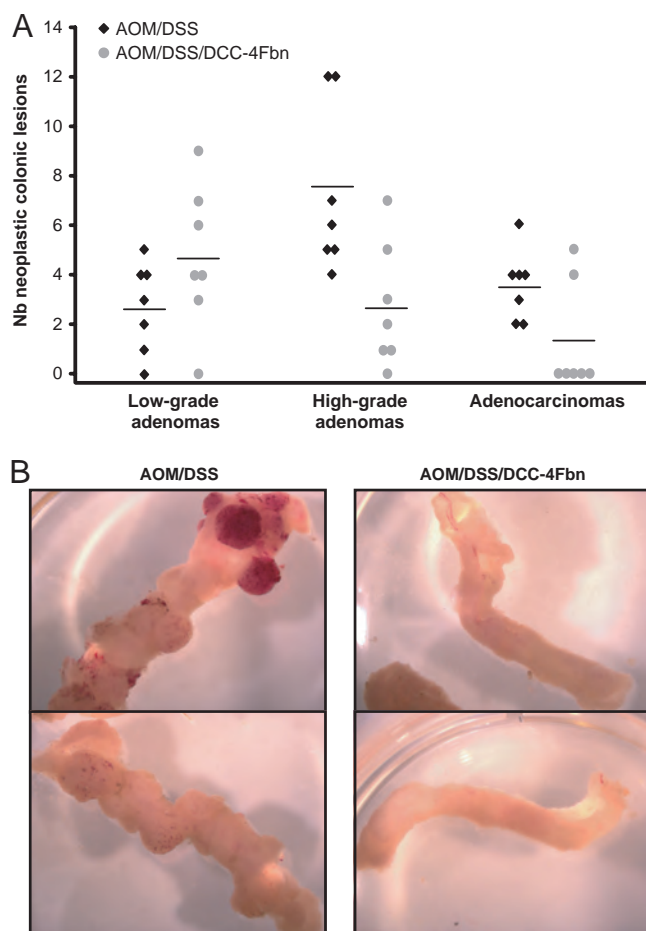


Fig. 5. Interference with netrin-1 prevents tumor progression in a mouse model of IBD-associated colorectal cancer. (A) Number of neoplastic lesions (low grade adenomas, high grade adenomas or intra-mucosal and invasive adenocarcinomas) in each of the 14 mice treated with AOM and DSS, in presence or not of DCC-4Fbn. Note that five out of seven DCC-4Fbn treated mice were adenocarcinoma free animals while seven out of seven show adenocarcinoma in the control treated mice. (B) Representative images of colons removed from mice treated with AOM and DSS in presence (Right) or not (Left) of DCC-4Fbn.

prevention of tumor progression. A series of mice were then submitted to the DSS/AOM treatment for 10 weeks while administered intra-peritoneally three times per week with DCC-4Fbn. DCC-4Fbn repeated injection in DSS/AOM mice had only a modest effect on the number of early neoplastic lesions (61 versus 95) suggesting that netrin-1 inhibition has only a moderate, if any, effect on colorectal tumor initiation. Moreover, the inflammatory aspect of the epithelium appears similar in control versus DCC-4Fbn-treated mice (Fig. 4A). Along this line, DCC-4Fbn fails to have any significant effect on the level of NF- κ B activation as monitored by the measurement of $\text{I}\kappa\text{B}\alpha$ and Cox-2 mRNA levels (Fig. 4B).

Contrarily, DCC-4Fbn had a dramatic effect on tumor progression as repeated injection of DCC-4Fbn triggers an increased frequency of low grade adenoma associated with a decreased frequency of high-grade adenoma and adenocarcinoma (Fig. 5, χ^2 test, $P < 0.005$). Thus netrin-1 up-regulation in response to inflammation induced by DSS is a causal mechanism for colorectal cancer progression.

Together with the observation that colorectal cancer from patients with IBD shows up-regulation of netrin-1, with the fact that NF- κ B has been proposed to contribute to IBD associated-

colorectal cancer formation by providing anti-apoptotic survival signals to the epithelial cells and with the observation that forced expression of netrin-1 in gastrointestinal tract is associated with intestinal tumor progression in mice (3), we propose the following sequence for colorectal tumor progression in IBD patients. In response to chronic inflammation associated with IBD, NF- κ B activation triggers netrin-1 up-regulation not only in the normal but also in the altered epithelium, and this netrin-1 up-regulation, probably in association with other tumor initiation mechanisms, provides the sufficient survival signal to the epithelial cells for tumor progression. Because drug compounds targeting netrin-1 are currently under development, it may then be tempting to investigate the relevance of complementing the actual treatments of IBD, that, until now, have focused mainly on preventing inflammation in general, with such anti-netrin-1 drugs that would more specifically inhibit progression of early neoplastic lesions toward aggressive colorectal cancer. This is particularly important in light of the difficulty detecting and treating IBD-associated lesions by conventional techniques at an early stage and because of the current absence of preventive treatment, apart from colectomy in ulcerative colitis which is often associated with negative side effects and poor life quality.

Materials and Methods

Netrin-1 Immunodetection in Human Tissues. For immunodetection of netrin-1 in human tissues, archival, formalin-fixed, paraffin-embedded tissue material was used. The material selected for study included: samples from 52 cases of sporadic colorectal adenocarcinomas (with their corresponding peritumoral mucosa), 30 cases of colorectal adenocarcinomas from patients with IBD (24 with ulcerative colitis, six with Crohn's disease), and 30 samples of inflamed mucosa from patients with IBD (15 with ulcerative colitis, 15 with Crohn's disease). All lesions were classified according to the recommendations of the Vienna classification (22). After deparaffinization and dehydration, 4- μm thick tissue sections were boiled in citrate buffer pH9 using a water bath at 97 °C for 50 min. For blocking endogenous peroxidases, tissue sections were incubated in 5% hydrogen peroxide in sterile water. They were then incubated at room temperature for one hour with a polyclonal goat antibody to netrin-1 (R&D Systems). This antibody was diluted in antibody diluent solution (ChemMate, Dako) at 1/800. After rinsing in phosphate buffer saline, sections were incubated with a biotinylated secondary antibody bound to a streptavidin peroxidase conjugate (Lsab+ Kit, Dako). Peroxidase activity was revealed using DAB as a chromogen.

Semiquantitative Analysis of Netrin-1 Expression in Colorectal Cancers. A densitometric evaluation of netrin-1 expression in tumoral and peritumoral tissues was performed as previously described (23). Five fields were digitized and converted onto a gray scale. The apparent expression level of netrin-1 in ganglion cells of submucosal and myenteric plexuses was used as an internal control and the corresponding gray level was normalized to 100%. The apparent expression netrin-1 level in adjacent neoplastic and non neoplastic epithelial cells was expressed as a percentage of the control value in the same section.

Animal Model: Histological and Immunohistochemical Analysis. To induce colorectal carcinogenesis associated with chronic colitis, mice were treated as described previously (15). Briefly, pathogen-free 8-week-old female wild-type Balb/C mice were injected i.p. with 10 mg/kg body weight of AOM dissolved in PBS. The day after, 2.5% DSS was given in the drinking water over 1 week, followed by 2 weeks of regular water. Mice were treated with DSS for 1 week every 2 weeks until the 10th week of the experiment and were injected three times per week with 30 μg purified DCC-4Fbn or with PBS. The animals were killed at the beginning of the tenth week and the colon was removed for histological analysis or total RNA extraction. The intestine was preserved, open and fixed in buffered formalin. After macroscopical examination under a magnifying lens, all visible lesions were taken; in addition, random tissue samples were performed at regular intervals to detect non-macroscopically visible lesions. Four-micrometer thick sections were prepared from formalin-fixed, paraffin-embedded tissue samples and stained with hematoxylin-eosin-saffron. All lesions were identified and classified according to international recommendations (24). The histological comparison between treated and non-treated animals was performed blindly. Immunodetection of netrin-1

was performed from the same tissue material, after selection of representative samples. The technique was the same as described above.

Quantitative RT-PCR. Total RNA was extracted using NucleoSpin RNA II Kit (Macherey Nagel) according to manufacturer's protocol. RT-PCR reactions were performed with iScript cDNA Synthesis Kit (Bio-Rad). One microgram total RNA was reverse-transcribed using the following program: 25 °C for 5 min, 42 °C for 30 min, and 85 °C for 5 min. For expression studies, the target transcripts were amplified in LightCycler 2.0 apparatus (Roche Applied Science), using the LightCycler FastStart DNA Master SYBR Green I Kit (Roche Applied Science). Expression of target genes in AOM/DSS-treated mice was normalized to acidic ribosomal phosphoprotein PO (RPLPO), used as housekeeping gene. Expression of Netrin-1, -3, and -4 genes in human tumoral cell lines was normalized to hypoxanthine-guanine phosphoribosyltransferase (HPRT) gene. Netrin-1 expression in human IBD patients was normalized to the ubiquitously expressed retinoid X receptor alpha (RXR α) and glyceraldehyde 3-phosphate dehydrogenase (GAPDH) genes, that showed less variability in expression between normal and colorectal tumoral tissues (9). The amount of target transcripts, normalized to the housekeeping gene, was calculated using the comparative C_T method. A validation experiment was performed, to demonstrate that efficiencies of target and housekeeping genes were approximately equal. The sequences of the primers are available upon request.

Cell Lines, Cell Death Assay, and Immunoprecipitation. Human tumor cell lines HEK293T, HCT116, and HBL100 were cultured in DMEM (Invitrogen) supplemented with 10% FBS and gentamycin (50 μ g/mL). Transient transfections of HBL100 cells were performed using Fugene 6 Transfection Reagent (Roche Applied Science), while HEK293T cells were transfected with Lipofectamine Plus Reagent (Invitrogen), according to the manufacturer's instructions. For caspase-3 activity assay, HBL100 cells were transfected with IKK β or empty vector and serum starved for 3 h before their culture medium was added on HEK293T cells, transfected with UNC5H2 or empty vector. HEK293T cells were harvested after 3 h incubation in the presence or absence of 1 μ g/mL DCC-4Fbn and caspase-3 activity assay was performed using the Caspase 3/CPP32 Fluorimetric Assay Kit (Gentaur Biovision), according to the manufacturer's instructions. Caspase activity (activity/min/microgram of protein) was calculated from a 1-h kinetic cycle reading on a spectrofluorimeter (405 nm/510 nm,

Victor, Wallac). Caspase activation is presented as the ratio between the caspase activity of the sample and that measured in HEK293T cells transfected with the mock vector and incubated with the control HBL100 medium. HCT116 cells were treated with 1 ng/mL DCC-4Fbn for 24 h in combination or not with 150 ng/mL purified netrin-1 or netrin-4. DCC and caspase-9 co-immunoprecipitation analysis was performed as described previously (20).

DCC-4Fbn Purification. DCC-4Fbn DNA fragment was generated by PCR using pDCC-CMV-5 as a template and inserted into the vector by annealing to promote the expression of DCC-4Fbn in fusion with an N-terminal 6 \times His tag. DCC-4Fbn production was then performed using a standard procedure. Briefly, DCC-4Fbn was expressed in BL21 cells in response to IPTG at 25 °C and the BL21 lysate was subjected to affinity chromatography using His purification on Ni-NTA columns (Qiagen).

DCC-4Fbn/Netrin-1 and -4 Binding Assay. DCC-Fbn4 (5 μ g/mL) in PBS was adsorbed on 96-well maxisorp plate (Nalge Nunc International) for 1 h at 37 °C. After blocking in PBS-5% BSA for 1 h at 37 °C, Flag-tagged netrin-1 or netrin-4 (APOTEC Corporation) (ranging from 0 to 0.5 μ g/mL) diluted in PBS-0.1% Tween-20 (PBS-T) 5% BSA was then added. After a 1-h incubation at 37 °C, plates were extensively washed, and bound netrins were detected by immunolabeling using an anti-flagM2 antibody (Sigma-Aldrich) and a HRP-goat-anti-mouse (Jackson ImmunoResearch) using OPD as colorimetric substrate. Absorbance measurement was performed on the multilabel Victor station (Wallac).

Statistical Analysis. The data reported are the mean \pm SD of at least three independent determinations, each performed in triplicate. Statistical analysis was performed by the nonparametric Mann-Whitney *U* test unless indicated.

ACKNOWLEDGMENTS. We thank M. Susag for text corrections. This work was supported by institutional grants from Centre National de la Recherche Scientifique, Centre Léon Bérard (P.M.), and the Ligue Contre le Cancer (P.M.), Institut National du Cancer (P.M.), Agence Nationale de la Recherche (P.M.), the European Union Specific Targeted Research Projects Hermione and APOSYS (P.M.), and Association pour la Recherche contre le Cancer-Institut National du Cancer (P.M. and J.Y.S.) A.P. and C.M. are supported by fellowships from Association pour la Recherche contre le Cancer.

1. Greten FR, et al. (2004) IKKbeta links inflammation and tumorigenesis in a mouse model of colitis-associated cancer. *Cell* 118:285–296.
2. Serafini T, Kennedy TE, Gallo MJ, Mirzayan C, Jessell TM, Tessier-Lavigne M (1994) The netrins define a family of axon outgrowth-promoting proteins homologous to *C. elegans* UNC-6. *Cell* 78:409–424.
3. Mazelin L, et al. (2004) Netrin-1 controls colorectal tumorigenesis by regulating apoptosis. *Nature* 431:80–84.
4. Mehlen P, Rabizadeh S, Snipas SJ, Assa-Munt N, Salvesen GS, Bredesen DE (1998) The DCC gene product induces apoptosis by a mechanism requiring receptor proteolysis. *Nature* 395:801–804.
5. Llambi F, Causeret F, Bloch-Gallego E, Mehlen P (2001) Netrin-1 acts as a survival factor via its receptors UNC5H and DCC. *EMBO J* 20:2715–2722.
6. Tanikawa C, Matsuda K, Fukuda S, Nakamura Y, Arakawa H (2003) p53RDL1 regulates p53-dependent apoptosis. *Nat Cell Biol* 5:216–223.
7. Bredesen DE, Mehlen P, Rabizadeh S (2005) Receptors that mediate cellular dependence. *Cell Death Differ* 12:1031–1043.
8. Mehlen P, Puisieux A (2006) Metastasis: A question of life or death. *Nat Rev Cancer* 6:449–458.
9. Bernet A, et al. (2007) Inactivation of the UNC5C Netrin-1 receptor is associated with tumor progression in colorectal malignancies. *Gastroenterology* 133:1840–1848.
10. Fearon ER, et al. (1990) Identification of a chromosome 18q gene that is altered in colorectal cancers. *Science* 247:49–56.
11. Thiebault K, et al. (2003) The netrin-1 receptors UNC5H are putative tumor suppressors controlling cell death commitment. *Proc Natl Acad Sci USA* 100:4173–4178.
12. Shin SK, et al. (2007) Epigenetic and genetic alterations in Netrin-1 receptors UNC5C and DCC in human colon cancer. *Gastroenterology* 133:1849–1857.
13. Paradisi A, et al. (2008) NF-kappaB regulates netrin-1 expression and affects the conditional tumor suppressive activity of the netrin-1 receptors. *Gastroenterology* 135:1248–1257.
14. Vogelstein B, Kinzler KW (2004) Cancer genes and the pathways they control. *Nat Med* 10:789–799.
15. Neufert C, Becker C, Neurath MF (2007) An inducible mouse model of colon carcinogenesis for the analysis of sporadic and inflammation-driven tumor progression. *Nat Protoc* 2:1998–2004.
16. Delloye-Bourgeois C, et al. (2009) Netrin-1 acts as a survival factor for aggressive neuroblastoma. *J Exp Med* 206:833–847.
17. Delloye-Bourgeois C, et al. (2009) Interference with netrin-1 and tumor cell death in non-small cell lung cancer. *J Natl Cancer Inst* 101:237–247.
18. Kruger RP, Lee J, Li W, Guan KL (2004) Mapping netrin receptor binding reveals domains of Unc5 regulating its tyrosine phosphorylation. *J Neurosci* 24:10826–10834.
19. Mille F, et al. (2009) Interfering with Netrin-1 receptors multimerization triggers apoptosis. *Cell Death Differ* in press.
20. Forcet C, et al. (2001) The dependence receptor DCC (deleted in colorectal cancer) defines an alternative mechanism for caspase activation. *Proc Natl Acad Sci USA* 98:3416–3421.
21. Furne C, Corset V, Herincs Z, Cahuzac N, Hueber AO, Mehlen P (2006) The dependence receptor DCC requires lipid raft localization for cell death signaling. *Proc Natl Acad Sci USA* 103:4128–4133.
22. Schlemper RJ, et al. (2000) The Vienna classification of gastrointestinal epithelial neoplasia. *Gut* 47:251–255.
23. Nejari M, et al. (2001) Integrin up-regulation in chronic liver disease: Relationship with inflammation and fibrosis in chronic hepatitis C. *J Pathol* 195:473–481.
24. Boivin GP, et al. (2003) Pathology of mouse models of intestinal cancer: Consensus report and recommendations. *Gastroenterology* 124:762–777.