



HAL
open science

An efficient and reproducible protocol for distraction osteogenesis in a rat model leading to a functional regenerated femur

Martine Pithioux, Flavy Roseren, Christian Jalain, Franck Launay, Philippe Charpiot, Patrick Chabrand, Sandrine Roffino, Edouard Lamy

► **To cite this version:**

Martine Pithioux, Flavy Roseren, Christian Jalain, Franck Launay, Philippe Charpiot, et al.. An efficient and reproducible protocol for distraction osteogenesis in a rat model leading to a functional regenerated femur. *Journal of visualized experiments: JoVE*, inPress, 128, pp.56433 - 56433. 10.3791/56433. hal-01593127

HAL Id: hal-01593127

<https://hal.science/hal-01593127v1>

Submitted on 15 Nov 2017

HAL is a multi-disciplinary open access archive for the deposit and dissemination of scientific research documents, whether they are published or not. The documents may come from teaching and research institutions in France or abroad, or from public or private research centers.

L'archive ouverte pluridisciplinaire **HAL**, est destinée au dépôt et à la diffusion de documents scientifiques de niveau recherche, publiés ou non, émanant des établissements d'enseignement et de recherche français ou étrangers, des laboratoires publics ou privés.

Video Article

An Efficient and Reproducible Protocol for Distraction Osteogenesis in a Rat Model Leading to a Functional Regenerated Femur

Martine Pithioux^{*1,2}, Flavy Roseren^{*1,2}, Christian Jalain⁴, Franck launay^{1,3}, Philippe Charpiot⁵, Patrick chabrand^{1,2}, Sandrine Roffino¹, Edouard Lamy^{1,6}

¹CNRS, ISM, Inst Movement Sci, Aix Marseille Univ

²Sainte-Marguerite Hospital, Institute for Locomotion, Department of Orthopaedics and Traumatology, APHM

³Sainte-Marguerite Hospital, Institute for Locomotion, Department of Peadiatric Orthopaedics, APHM

⁴Ecole centrale de Marseille

⁵Faculté de Pharmacie, Laboratoire de Biochimie

⁶Service Central de la Qualité et de l'Information Pharmaceutiques, APHM

*These authors contributed equally

Correspondence to: Martine Pithioux at martine.pithioux@univ-amu.fr

URL: <https://www.jove.com/video/56433>

DOI: [doi:10.3791/56433](https://doi.org/10.3791/56433)

Keywords: Bioengineering, Issue 128, Distraction osteogenesis, external fixator, bone lengthening, rat model, surgical procedure, micro-CT

Date Published: 10/23/2017

Citation: Pithioux, M., Roseren, F., Jalain, C., launay, F., Charpiot, P., chabrand, P., Roffino, S., Lamy, E. An Efficient and Reproducible Protocol for Distraction Osteogenesis in a Rat Model Leading to a Functional Regenerated Femur. *J. Vis. Exp.* (128), e56433, doi:10.3791/56433 (2017).

Abstract

This protocol describes the use of a newly developed external fixator for distraction osteogenesis in a rat femoral model. Distraction osteogenesis (DO) is a surgical technique leading to bone regeneration after an osteotomy. The osteotomized extremities are moved away from each other by gradual distraction to reach the desired elongation. This procedure is widely used in humans for lower and upper limb lengthening, treatment after a bone nonunion, or the regeneration of a bone defect following surgery for bone tumor excision, as well as in maxillofacial reconstruction. Only a few studies clearly demonstrate the efficiency of their protocol in obtaining a functional regenerated bone, *i.e.*, bone that will support physiological weight-bearing without fracture after removal of the external fixator. Moreover, protocols for DO vary and reproducibility is limited by lack of information, making comparison between studies difficult. The aim of this study was to develop a reproducible protocol comprising an appropriate external fixator design for rat limb lengthening, with a detailed surgical technique that permits physiological weight-bearing by the animal after removal of the external fixator.

Video Link

The video component of this article can be found at <https://www.jove.com/video/56433/>

Introduction

Distraction osteogenesis (DO) is a surgical technique widely used clinically^{1,2,3,4} in humans for lower^{1,2} and upper³ limb lengthening, treatment after a bone nonunion, or the regeneration of a bone defect following surgery for bone tumor excision as well as in maxillofacial reconstruction⁴. DO leads to bone regeneration after placement of an external fixator in bone and osteotomy. The osteotomized extremities are moved away from each other by gradual distraction² to reach the desired elongation. A consolidation period follows, during which there is no more elongation.

The DO procedure is divided into three distinct phases: latency, distraction, and consolidation. Generally, a 7-day latency period starts just after osteotomy⁴. This allows bone repair to begin the initial step of the healing process⁴. The latency period is followed by a distraction period where traction forces are applied to the regenerated callus and surrounding soft tissues^{1,2,4}. When the desired elongation is reached, distraction stops and the consolidation period begins. During this period, the external fixator is maintained until the regenerated bone is functional enough to support its removal.

Various parameters of DO influence bone repair such as length and rate of lengthening, type of external fixator, frequency of distraction, length of the consolidation period, or type of mechanical stress applied to the distracted callus. As an example, the rate and frequency of lengthening can lead either to premature consolidation⁵ or disruption of the process by creating non-recoverable damage like necrotic tissue or cysts within the callus^{6,7}.

Many DO protocols have been applied to different animal models^{8,9,10} to study bone repair processes and to maximize bone consolidation. In rats, most studies^{11,12,13,14,15} focused on how to shorten the DO protocol by speeding up callus consolidation. Some of these experimental studies used external fixators already commercially available for human clinical applications^{5,13,15,16}. However, these types of external fixator are not suitable for DO on the rat femur, which exhibits different anatomical characteristics from the human femur. Moreover, only a few studies

clearly demonstrate the efficiency of their protocols in obtaining a functional regenerated bone^{7,16}. It is therefore difficult to compare results from various DO studies, due to their differing protocols and lack of information regarding the external fixator^{12,13,14,17}.

Thus, the aim of this study was to describe, in a rat model, an efficient and reproducible protocol for DO on the femur that leads to a functional regenerated bone. To this end, we designed a homemade and easy-to-use external fixator especially for the rat femur, which we have described in detail in this protocol. In drafting the technical specifications for this device, we took into account all the fundamental constraints for a good distribution of mechanical stresses and avoiding the production of residual stress. The technical specification included an appropriate geometry for the device to allow pure traction force on bones and surrounding tissue, an appropriate weight for the gait of the animal, control of the length of bone elongation, and a good alignment of bone segments without production of shear stress at the intersection of pins and bone. Moreover, this device had to be usable without sedation of the animal during distraction, biocompatible, and sterilizable without damage. After 7 weeks of consolidation, this protocol for DO on the rat femur led to a functional regenerated bone, demonstrated by the animals' physiological weight-bearing without fracture of the regenerated callus after removal of the external fixator. The physiological gait of the animals was consistent with architectural parameters obtained from micro-CT analysis of regenerated callus and X-ray analysis.

Protocol

All procedures described were approved by the University of Aix-Marseille institutional animal care and use committee and the French research ministry and performed in the conventional animal house of Marseille Medical Faculty (France).

1. Define Functional Specifications of the External Fixator Based on the Following Guidelines

1. **Optimize bone anchorage.**
 1. Implant half-threaded pins with a diameter (of the threaded section) of 1 mm.
2. **Choose a design to reduce discomfort for the animal.**
 1. Choose an external fixator of a small size that fits into a volume of 7,723 mm³ (32 mm x 19 mm x 12.7 mm).
 2. Choose an external fixator with low weight, less than 13 g without the pins, to avoid disturbing the animals' gait. Choose aluminum as the material for the two blocks due to its low density.
NOTE: The chamfers of the blocks considerably decrease the weight of the two parts.
3. **Control the motion of the fixator such that the direction of tensile force is maintained parallel to the direction of the bone and ensure pure tensile forces.**
 1. Use a sliding bar that goes through the two blocks. Groove and open the blocks so each can bear two pins.
 2. Use an elongation screw with one smooth side that turns freely in the block and can be gripped by fingers and with a threaded side that displaces the second block by rotation. Anchor two pins to the bone, on each side of the fracture, to keep the direction of tensile force parallel to the direction of the bone. Maintain the tensile forces in the longitudinal axis to allow good distribution of stress on the pins. Secure the four pins with locking screws.
4. **Choose materials like aluminum, titanium, and steel that can withstand sterilization temperatures.**
5. **Ensure that pin placement corresponds to external fixator geometry (Figure 1-B).**
 1. Use a drilling guide that contains a clamp tightened on the bone to maintain the drilling position.
 2. Shorten the lever arm of the clamp for low clamping force. Position the clamp in the middle of the device, above the future fracture, to clear the sides.
6. **Make the distraction easy to manual adjust by adding a knurled screw to tighten and release the mobile block.**
 1. Use a screw wide enough to manipulate with fingers alone.
 2. Add a drilled square nut in the middle of the elongation screw between the two blocks, to allow easy distraction.
 3. Make this square nut (8 mm on each side) larger than the two blocks to allow manual use with a thin pin or any kind of object. Turn the screw ¼ turn to allow a 0.125 mm lengthening.

2. Surgery

NOTE: An assistant is required for all surgical procedures. Four 12 week-old male Sprague Dawley rats were fed a standard laboratory diet *ad libitum*.

1. **Prepare surgical tools.**
 1. Sterilize all the following surgical instruments: 1 rugine, 2 Senn's retractors, 1 micro Olsen-Hegar Needle-holder, 1 Mayo-Hegar needle holder, 1 mayo scissor, and 1 scalpel.
 2. Sterilize the external fixator, the drilling guide, 4 half-threaded pins, 4 screws, the tip and the string of the drill, and the tip and the string of the piezotome. Sterilize these instruments by autoclaving at 135 °C for 18 min.
 3. Install a heating pad below the sterile field, on the surgical table. Place all instruments or tools on another sterile field.
2. **Anesthetize and prepare the animal.**
 1. Weigh the rat to prepare the anesthetic and the analgesic mixture
 2. Determine and calculate the amount of Buprenorphine and Carprofen to prepare the analgesic mixture extemporaneously. Use Buprenorphine (0.03 mg/mL) and Carprofen (5 mg/mL) respectively at 0.05 mg/kg and 5 mg/kg.

3. Restrain the rat and subcutaneously inject the analgesic mixture. Wait a few seconds, then inject intraperitoneally the anesthetic mixture.
 4. Shave the right hind limb with an electric razor and disinfect the limb with povidone-iodine solution.
 5. Lay the animal laterally (right side upward) on the sterile field to allow the correct positioning of the external fixator along the mediolateral axis.
 6. Put a sterile compress on its head to protect its eyes during surgery.
- 3. Implant the external fixator in the femur.**
1. Landmark the skin incision. With a marker, draw a point from the distal part (knee) and a second point in the proximal part (hip) following the median line in the sagittal plane. Then draw a line between these 2 points.
 2. Incise the stretched skin along the drawing line using a scalpel.
 3. Cut in between the *biceps femoris* and *vastus lateralis* until the femur is fully exposed, with the help of a scalpel. Use the 2 Senn's retractors (may require an assistant) to facilitate the muscle incision.
 4. Lift the periosteum and disconnect the soft tissue from the bone with the help of a rugine.
 5. Check that the exposed femur is long enough.
 1. Insert pins in the most proximal and distal holes of the external fixator.
 2. Position the external fixator and check that both pins can be anchored into the femur.
 6. Implant 4 parallel 1 mm half-threaded pins in the femur.
 1. Take the drilling guide and move apart the muscles with 2 Senn's retractors. Tighten the clamp of the drilling guide in the middle of the femur.
 2. Drill 4 pre-holes in the femur. Using an electric drill, drill holes at a speed of 2,000 rpm by passing a metal drill bit of 0.6 mm diameter through the 4 guide holes.
 1. Start with the most proximal and distal holes and finish with the two middle ones of the guide. Be careful to go through both cortices but not to damage the soft tissues just beneath the femur.
 3. Take off the drilling guide.
 4. Enlarge the 4 pre-holes with 0.8 mm half-threaded pin.
 1. Work the pin back and forth through the 0.6 mm holes. Be careful to stay perpendicular to the femur and sink through both cortices.
 5. Implant 1 mm half-threaded pins.
 1. Grip the head of the 1 mm half-threaded pin with a needle-holder.
 2. Sink the pin to enlarge the pre-hole. Check that the pins penetrate both cortices and do not protrude more than 1 mm, with a Senn's retractor.
 6. Connect the external fixator to the 4 half-threaded pins. Make sure that the offset (distance between the fixator's two blocks and the bone surface) is about 6 mm to allow easy stitches and good rigidity of the system¹⁸.
 7. Secure the 4 locking screws so that the external fixator is locked to the pins.
- 4. Osteotomize the femur.**
1. Perform an osteotomy between the 2 central pins with a piezotome.
 2. Close the wound using a continuous stitch with a resorbable suture thread (5.0) and Mayo-Hegar needle holder. Make sure only the skin is stitched, and not the muscles.
- 5. Verify the surgery and monitor animals.**
1. Perform an X-ray just after surgery, while the animal is still anesthetized. Check the depth of all the pins and that osteotomized extremities are aligned following the long axis.
 2. Ensure analgesia and antibiophylaxy by subcutaneous injection of Buprenorphine (0.03 mg/mL) and Enrofloxacin (50 mg/mL) respectively at 0.05 mg/kg and 10 mg/kg.
 3. Determine and calculate the amount of antipamezole to reverse the anesthesia. Use antipamezole at 1mg/kg and do a subcutaneous injection to administer the product. Allow the animal to regain consciousness and return it to its cage.
 4. Six hours after the surgery, inject a second dose of the analgesia mixture (Buprenorphine and Carprofen) respectively at 0.05mg/kg and 5 mg/kg subcutaneously.
For the next 3 days at least, give these injections twice a day for the analgesia mixture and once a day for the antibiophylaxy. Regular clinical examinations must be performed to assess the effectiveness of analgesia and must be modified according to the behavior signs of each animal.
 5. Check that the animals can walk using their operated hind limb normally on the day following surgery.

3. Distraction

1. Leave the external fixator in neutral fixation for 1 week. X-ray the limb at the end of this phase. Check the positioning of the pins and the alignment of the bone segments.
2. **Manually turn the square nut one half turn (0.25 mm) clockwise every 12 h to perform the distraction. Distract for 10 days, which should lead to a 5mm bone lengthening, representing a 12% lengthening relative to the initial length of the operated bone segment.**
 1. Do not anesthetize the animal during this step. X-ray the limb half-way through and at the end of this period to check the positioning of the pins and alignment of the bone segments.

3. Maintain the external fixator for 47 days. X-ray the limb weekly to check the progress of distracted gap calcification. On Day 64, remove the external fixator and let the animal walk freely for 2 more days (Day 66). The total consolidation period lasts 7 weeks.
4. Euthanize all rats after 7 weeks of consolidation with an overdose of inhaled sevoflurane.
5. **Resect distracted and contralateral femurs without the surrounding tissues.**
 1. Make a skin incision on the scar located on the median line following the sagittal plane with the help of a scalpel. Run the incision from the top of the hip to the front of the knee.
 2. Cut in between the *biceps femoris* and *vastus lateralis* with a scalpel until the femur is fully exposed. As much as possible, disconnect the muscle attached to the bone.
 3. Cut all the ligaments of the knee and dismantle the articulation.
 4. Cut the joint capsule of the hip.
 5. Clean the bone thoroughly without removing the half-threaded pins. Remove all the soft tissue with a scalpel.
6. Repeat the steps from 3.5.1 to 3.5.5 for the contralateral femur.
7. X-ray distracted and contralateral femurs. Remove the 4 half-threaded pins and store all femurs at -20 °C for micro-CT scan analysis (10 μm resolution).

Representative Results

The X-ray images taken from the end of surgical procedure to the end of consolidation showed no loosening of the half-threaded pins in the femur, indicating stable anchorage. The pins were parallel and well-preserved. The osteotomized extremities were well-aligned along the longitudinal axis of the bone during the DO process (Figure 2). At the end of the latency period, no calcified areas were visible (Figure 2B). At the end of the distraction period, a few calcified areas were visible close to the preexisting cortices (Figure 2C). After 28 days of consolidation (Day 45), the non-calcified region of the gap between the osteotomized extremities was smaller and we observed a periosteal callus not only near the gap but also at the level of the pins (Figure 2D). After 47 days of consolidation (Day 64), the regenerating callus was completely bridged (Figure 2E). After removal of the external fixator and 2 days of physiological weight-bearing, the animals had physiological gait and there was no evidence of fracture (Figure 2F).

3D micro-CT analysis of the serial longitudinal sections of the regenerating callus demonstrated that calcified bridging was always present (Figure 3A-D). A continuous outer cortical was observed at the periphery of the regenerating callus (Figure 3C-D). According to the longitudinal profiles, the regenerating callus was completely filled by a network of bony trabeculae. After 49 days of consolidation (Day 66), a less mineralized region remained at the center of the regenerated bone (Figure 3E-F). The architectural parameters of the micro-CT indicated that the average volume fraction (BV/TV) for the regenerating callus and the contralateral femur were respectively $55\% \pm 13$ and $97.85\% \pm 1.7$ (Table 1 and Table 2). The mean value of volumetric bone mineral density (vBMD) for the regenerating callus was $750 \text{ mg/cm}^3 \pm 25$. The mean value of the cross-sectional area was higher for the regenerating callus than for the contralateral femur ($17.23 \text{ mm}^2 \pm 9.3$ vs $9.5 \text{ mm}^2 \pm 1.2$) (Table 1 and Table 2). The mean callus cortical thickness was thinner than the cortical thickness of contralateral femur ($0.317 \text{ mm} \pm 0.04$ vs $0.6 \text{ mm} \pm 0.05$) (Tables 1 and 2).




Figure 1: Computer-aided design (CAD) of the external fixator and the drilling guide. (A) CAD of the external fixator with the pins. (B) CAD of the drilling guide. Scale bar = 5 mm. [Please click here to view a larger version of this figure.](#)

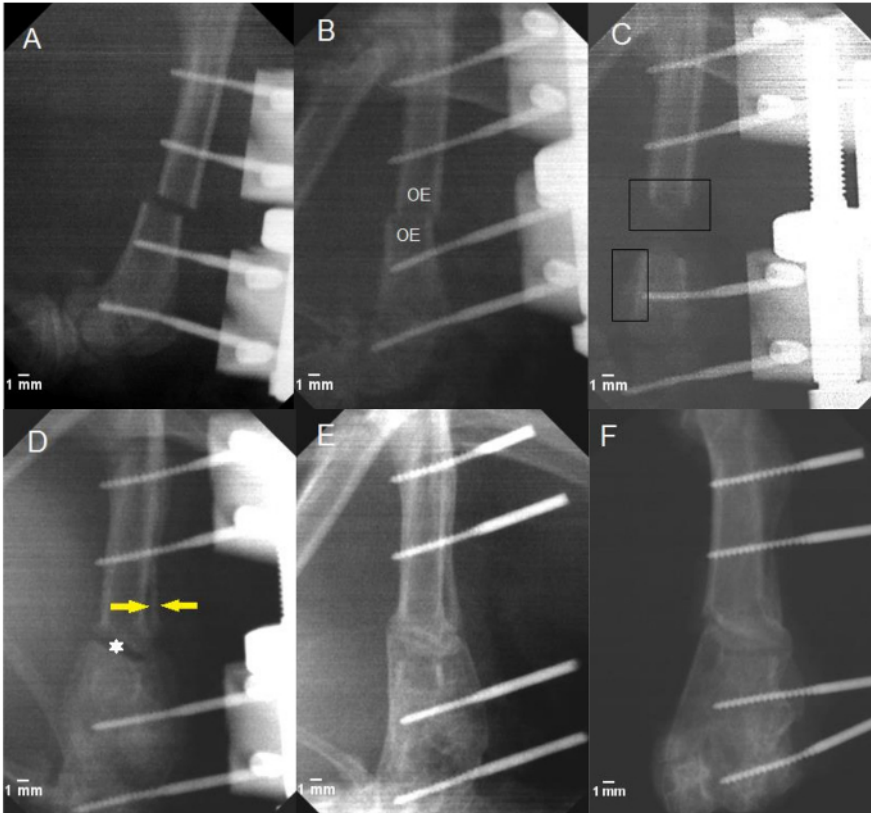


Figure 2: Representative X-rays of a rat femur at various time-points. X-ray radiographs of the distracted callus at 0, 7, 17, 45, 64 and 66 days. (A) X-rays taken after the surgery (Day 0). (B) X-ray radiograph taken after the 7-day latency period. No calcified callus is apparent near the osteotomized extremities (OE). (C) At the end of distraction, a small, poorly calcified zone is apparent near the osteotomized extremities (rectangular zone). (D) After 28 days of consolidation (Day 45), the gap between the osteotomized extremities (*) and a second cortical is apparent (yellow arrow). (E) Radiograph after 47 days of consolidation (Day 64) (F) X-ray radiograph taken after 49 days of consolidation (Day 66), with two days of physiological weight-bearing. Scale bar = 1 mm. [Please click here to view a larger version of this figure.](#)

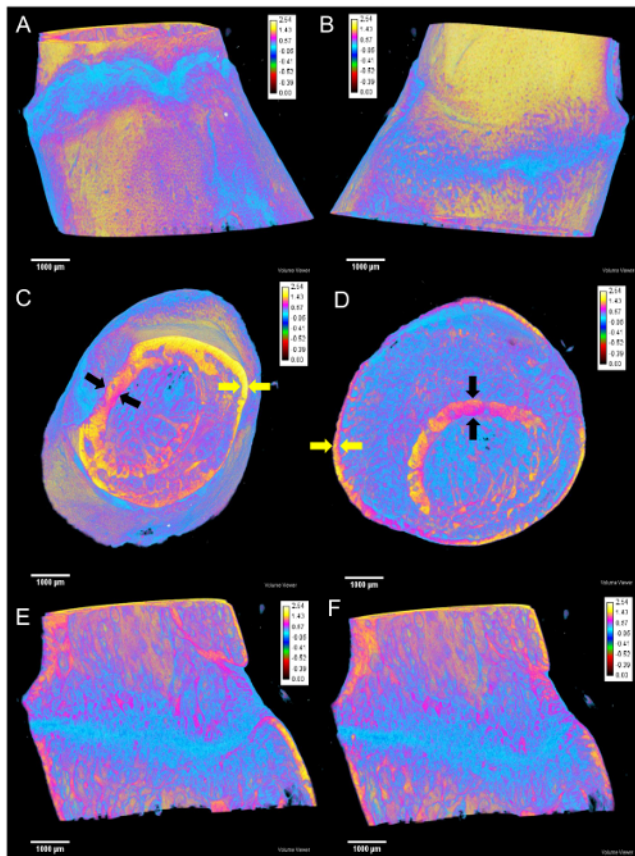


Figure 3: 3D micro-CT reconstruction of the distracted callus of a rat femur. The mineralization of the bone is illustrated by color ranging from yellow to blue. (A,B) Representation of the bridging cortices of the distracted callus following the anteroposterior and longitudinal axis. (C,D) Proximal and distal cross-section revealing the initial cortical bone (black arrow) and the bridging cortices of the distracted callus (yellow arrow) (E,F) 3D longitudinal profiles of the distracted callus after 7 weeks of consolidation: the callus is filled by a network of trabecular bone. Scale bar = 1000 µm. Calibration bar = 0 to 2.54 g/cm³ (yellow = 1.73 g/cm³, pink = 0.84 g/cm³, and blue = 0.17 g/cm³). [Please click here to view a larger version of this figure.](#)

Parameters	Individual values			
	Rat 1	Rat 2	Rat 3	Rat 4
BV/TV (%)	40	50	75	50
CSA (mm ²)	10.87 ± 2	13.48 ± 0.82	31.16 ± 9.03	13.68 ± 2.08
Ct.Th (mm)	0.264 ± 0.09	0.313 ± 0.08	0.36 ± 0.1	0.33 ± 0.08
vBMD (mg/cm ³)	770	750	810	770

Table 1: Callus parameters of distracted femur after 49 days of consolidation. The region of interest (ROI) selected to calculate all the parameters was the zone between the osteotomized extremities. All the values obtained for each rat were calculated on each slice of the image stack. Results are expressed as mean ± standard deviation. BV/TV: volume fraction; CSA: cross-sectional area; vBMD: bone mineral density; Ct.Th: cortical thickness.

Parameters	Individual values			
	Rat 1	Rat 2	Rat 3	Rat 4
BV/TV (%)	99	98.6	95.3	98.5
CSA (mm ²)	8.37	9.84	11.01	8.76
Ct.Th (mm)	0.62 ± 0.06	0.58 ± 0.05	0.54 ± 0.06	0.67 ± 0.09

Table 2: Contralateral parameters of intact femur after 49 days of consolidation. All the values obtained for each rat were calculated on each slice of the image stack. Results are expressed as mean ± standard deviation. BV/TV: volume fraction; CSA: cross-sectional area; Ct.Th: cortical thickness.

Discussion

This study describes a reproducible protocol comprising an appropriate external fixator design for rat limb lengthening, with a detailed surgical technique that permits physiological weight-bearing by the animal after removal of the external fixator. Our DO protocol led to a functional regenerated bone. After 47 days of consolidation, removal of the homemade external fixator and 2 days of physiological weight-bearing by the animal did not induce any fracture of the regenerating callus. Thanks to the micro-CT reconstruction, the evidence of a complete bridging confirmed that the regenerated callus was functional. A previous study clearly demonstrated a positive correlation between the presence of calcified bridging and the load that a regenerated callus can sustain¹⁹. Moreover, the vBMD found for the regenerated callus was about 67% of the vBMD found for the diaphysis part of the femur from the contralateral limb²⁰. We also found an average vBMD of the regenerated callus that was close to the value previously described²¹. This highlights the stable environment created by the homemade external fixator leading to efficient bone repair. In addition, the fixator was well tolerated by the animals. The positioning and the light weight of the external fixator did not disturb the animals' gaits, so they were able to walk just after surgery.

Throughout the protocol, no breaking or loosening of pins occurred, evidence that the threading procedure ensured an effective and stable anchoring of the pins in the femur. It is crucial that pins are well-anchored for good stability of the DO micro-environment: loosening one pin has been shown to decrease by half the stiffness of the device¹⁸. Moreover, rats must be housed singly in cages with a specially designed flat cover to prevent the animal from hooking up the external fixator. The manual and easy-to-perform distraction of the regenerating callus limits pin-loosening but also avoids having to sedate animals every 12 h for several days and contributes to the reliability and efficiency of the homemade external fixator. Another important point to check is that the pins penetrate both cortices and do not protrude more than 1 mm. This step is sensitive, and if X-ray radiographs do not confirm appropriate positioning of the pins, this needs to be corrected manually using a Mayo-Hegar needle-holder while the animal is still anesthetized. The protocol has some limitations. It is a time-consuming and constraining protocol, which limits the number of animals it can be used on. Moreover, given the dexterity required and the meticulousness of the surgery, the procedure could take a couple of practice runs to master.

Throughout the DO procedure, the alignment of the osteotomized extremities was maintained. When implanting pins in the femur, it is very important to use a drilling guide so that the half-threaded pins are parallel, thereby ensuring good distribution of the mechanical stress without production of shear stress throughout the distraction and consolidation phases. It is also very important to clean the wound daily to prevent any blocking of the square nut that would make manual distraction difficult, which could affect the alignment of osteotomized extremities and the proper anchoring of pins. How to proceed to the osteotomy represents the last key point for the regeneration. The osteotomy must be performed with a piezotome to ensure a uniform and regular osseous section and to prevent thermic-induced necrosis and damage to surrounding soft tissues. Moreover, excessive heat is sometimes generated when drilling the pre-holes. An irrigating system coupled with the electric drill can be used to prevent thermic-induced necrosis.

To conclude, we describe an efficient and reproducible protocol, in a rat femoral model, for DO that leads to a functional regenerated bone. Designing a homemade external fixator based on the anatomical characteristics of the rat femur enabled a stable environment to be generated and allowed the formation of a calcified regenerated callus that was sufficiently consolidated to support physiological weight-bearing by the animals. Our next objective is to use this reproducible protocol to determine the shortest consolidation period compatible with a functional regenerated bone. The subsequent aim will be to improve the DO technique, especially seeking ways to shorten the consolidation period. This reproducible protocol could also be useful to identify mechanisms involved in bone repair. Finally, the characteristics of the home-made external fixator make it usable in clinical practice for human finger elongation.

Disclosures

The authors have nothing to disclose.

Acknowledgements

This work was supported and funded by the CNRS Mecabio challenge.

The authors thank the animal care technician for taking care of the animals throughout the procedure. The authors also acknowledge IVTV central Lyon, through Thierry Hoc. Thanks to Marjorie Sweetko for language revision.

We are grateful to Marylène Lallemand, Cécile Génovésio, and Patrick Laurent for their contribution to this experimental study.

References

1. Jauregui, J.J., Ventimiglia, A.V., Grieco, P.W., Frumberg, D.B., Herzberg, J.E. Regenerate Bone stimulation following limb lengthening: a meta-analysis. *BMC Musculoskelet Disord.* **17** (1), 407 (2016).
2. Morcos, M.W., Al-Jallad, H., Hamdy, R. Comprehensive review of Adipose Stem Cells and Their Implication in Distraction Osteogenesis and Bone Regeneration. *Biomed Res Int.* **2015** (842975), 1-20 (2015).
3. Cansü, E., Ünal, M.B., Parmaksizoglu, F., Gürcan, S. Distraction lengthening of the proximal phalanx in distal thumb amputations. *Acta Orthop Traumatol Turc.* **49** (3), 227-232, (2014).
4. Singh, M., Vashistha, A., Chaudhary, M., Kaur, G. Biological Basis of Distraction Osteogenesis - A Review. *J Oral Maxillofac Surg Med Pathol.* **28** (1), 1-7, (2016).
5. Sailhan, F., Gleyzolle, B., Parot, R., Guerini, H., Viguier, E. Rh-BMP-2 in Distraction Osteogenesis: Dose Effect and Premature Consolidation. *Injury.* **41** (7), 680-86, (2010).
6. Schiller, J.R., Moore, D.C., Ehrlich M.G. Increased Lengthening Rate Decreases Expression of Fibroblast Growth Factor 2, Platelet-Derived Growth Factor, Vascular Endothelial Growth Factor, and CD31 in a Rat Model of Distraction Osteogenesis. *J Pediatr Orthop.* **27** (8), 961-968 (2007).
7. Aronson, J., Shen, X.C., Skinner, R.A., Hogue, W.R., Badger, T.M., Lumpkin Jr, C.K. Rat Model of Distraction Osteogenesis. *J Orthop Res.* **15** (2), 221-226 (1997).
8. Aida, T., Yoshioka, I., Tominaga, K., Fukuda, J. Effects of latency period in a rabbit mandibular distraction osteogenesis. *Int J Oral Maxillofac Surg.* **32**, 54-62, (2003).
9. Lammens, J., Liu, Z., Aerssend, J., Dequeker, J., Fabry, G. distraction Bone Healing Versus Osteotomy Healing: A Comparative Biochemical Analysis. *J Bone Miner Res.* **13** (2), 279-286 (1998).
10. Isefuku, S., Joyner, C. J., Simpson, A.H.R.W. A Murine Model of Distraction Osteogenesis. *Bone.* **27** (5), 661-665 (2000).
11. Ebersson, C.P., Hogan, K.A., Moore, D.C., Ehrlich, M.G. Effect of Low-Intensity Ultrasound Stimulation on Consolidation of the Regenerate Zone in a Rat Model of Distraction Osteogenesis. *J Pediatr Orthop.* **23** (1), 46-51 (2003).
12. Özdel, A., Sarisözen, B., Yalçinkaya, U., Demirag, B. The Effect of HIF Stabilizer on Distraction Osteogenesis. *Acta Orthop Traumatol Turc.* **49** (1), 80-84, (2015).
13. Takamine, Y. et al. Distraction Osteogenesis Enhanced by Osteoblastlike Cells and Collagen Gel. *Clin Orthop Relat Res.* **399**, 240-246 (2002).
14. Wang, X., Zhu, S., Jiang, X., Li, Y., Song, D., Hu, J. Systemic Administration of Lithium Improves Distracted Bone Regeneration in Rats. *Calcif Tissue Int.* **96** (6), 534-40 (2015).
15. Xu, J. et al. Human Fetal Mesenchymal Stem Cell Secretome Enhances Bone Consolidation in Distraction Osteogenesis. *Stem Cell Res Ther.* **7** (1), (2016).
16. Yasui, N. et al. Three Modes of Ossification during Distraction Osteogenesis in the Rat. *Bone Joint J.* **79** (5), 824-830 (1997).
17. Chang, F. et al. Stimulation of EP4 Receptor Enhanced Bone Consolidation during Distraction Osteogenesis. *J Orthop Res.* **25** (2), 221-29 (2007).
18. Nyman, J.S et al. Quantitative Measures of Femoral Fracture Repair in Rats Derived by Micro-Computed Tomography. *J Biomech.* **42** (7), 891-97 (2009).
19. Hsu, J.T., Wang, S.P., Huang, H.L., Chen Y.J., Wu, J., Tsai., M.T. The assessment of trabecular bone parameters and cortical bone strength: a comparison of micro-CT and dental cone-beam CT. *J Biomech.* **46**, 2611-2618 (2013).
20. Xue, J. et al. NELL1 Promotes High-Quality Bone Regeneration in Rat Femoral Distraction Osteogenesis Model. *Bone.* **48** (3), 485-95 (2011).
21. Mark, H., Bergholm, J., Nilsson, A., Rydevik, B., Strömberg, L. An External Fixation Method and Device to Study Fracture Healing in Rats. *Acta Orthop.* **74** (4), 476-482 (2003).