



Open Archive TOULOUSE Archive Ouverte (OATAO)

OATAO is an open access repository that collects the work of Toulouse researchers and makes it freely available over the web where possible.

This is an author-deposited version published in : <http://oatao.univ-toulouse.fr/>
Eprints ID : 18162

To link to this article : DOI: 10.1002/lary.25867
URL : <http://dx.doi.org/10.1002/lary.25867>

To cite this version : Bonnacaze, Guillaume De and Chaput, Benoît and Woisard, Virginie and Uro-Coste, Emmanuelle and Swider, Pascal and Vergez, Sébastien and Serrano, Elie and Casteilla, Louis and Planat-Benard, Valerie *Adipose stromal cells improve healing of vocal fold scar: Morphological and functional evidences.* (2016) The Laryngoscope, vol. 126 (n° 8). pp. E278-E285. ISSN 0023-852X

Any correspondence concerning this service should be sent to the repository administrator: staff-oatao@listes-diff.inp-toulouse.fr

Adipose Stromal Cells Improve Healing of Vocal Fold Scar: Morphological and Functional Evidences

Guillaume de Bonnecaze, MD; Benoit Chaput, MD; Virginie Woisard, MD, PhD;
Emmanuelle Uro-Coste, MD, PhD; Pascal Swider, PhD; Sebastien Vergez, MD, PhD; Elie Serrano, MD;
Louis Casteilla, PhD; Valerie Planat-Benard, PhD

Objectives/Hypothesis: Adipose derived stromal cells (ASCs) are abundant and easy to prepare. Such cells may be useful for treating severe vocal disturbance caused by acute vocal fold scars.

Study Design: Prospective animal experiments with controls.

Methods: Twenty New-Zealand white rabbits were used in the present study. We evaluated vocal fold healing, with or without injection of autologous ASCs, after acute scarring. A defined lesion was created and the ASCs were immediately injected. Vocal fold regeneration was evaluated histomorphometrically and via viscoelastic analysis using an electrodynamic shaker.

Results: Six weeks after ASC injection, vocal folds exhibited significantly less inflammation than control folds ($P < 0.005$). In addition, hypertrophy of the lamina propria and fibrosis were significantly reduced upon ASC injection ($P < 0.02$). The decrease in viscoelastic parameters was less important in the ASC injected group compared to the noninjected group ($P = 0.08$).

Conclusion: Injection of autologous ASCs improved vocal fold healing in our preclinical model. Further studies are needed, but this method may be useful in humans.

Key Words: Wound healing, cytotherapy, vocal fold scar, adipose stromal cells, biomechanical analysis.

Level of Evidence: NA.

INTRODUCTION

Scarring caused by trauma, radiation, infection, or inflammation is a common cause of severe vocal disturbance. Current treatment features surgery and rehabilitation, with several associated problems including a requirement for general anesthesia, delivery of new insults to tissue, fibrotic deterioration and relapse. Several recent studies¹⁻⁴ have shown that injection of multipotent stem cells improved wound healing in preclinical models. Stem cell transplantation is an attractive approach that complements traditional restorative or surgical techniques seeking to regenerate injured or pathologically damaged laryngeal tissues. However, to

date no optimal cell delivery strategy has been identified.

We developed a new approach in which adipose-derived stromal cells (ASCs) containing multipotent cells of adipose tissue were used to heal injured vocal folds. Adipose-derived stromal cells have been studied in the context of cell differentiation,^{5,6} tissue engineering,⁷⁻⁹ and immunomodulation.^{10,11} From the perspective of the ear, nose, and throat (ENT) specialist, such cells have two very interesting characteristics: they are abundant and easy to prepare. In addition few recent evidences suggested the interest of ASCs in vocal fold wound healing. Adipose-derived stromal cells have demonstrated their antifibrotic properties *in vitro*.^{12,13} Recently others studies showed that ASCs could induce favorable remodeling of scarred vocal folds *in vivo* by their interactions with endogenous fibroblasts.¹⁴ Thus, we developed a preclinical cell therapy model in which autologous ASCs were injected after acute vocal fold scarring in rabbits. We then analyzed the effect of ASCs on lamina propria morphology and residual inflammation during the healing process. We also developed a novel method to assess the dynamic of the viscoelasticity property of the vocal fold.

Additional supporting information may be found in the online version of this article.

From the CNRS UMR5273 STROMALab (G.DB., B.C., L.C., V.P.-B.); the Université Paul Sabatier de Toulouse (G.DB., B.C.L.C., V.P.-B.); the INSERM U1031 (B.C., L.C., V.P.-B.); the EFS Pyrénées-Méditerranée (B.C., L.C., V.P.-B.); the Department of Ear, Nose and Throat Head and Neck Surgery (G.DB., V.W., S.V., E.S.); the Department of Plastic Reconstructive and Aesthetic Surgery (B.C.); Department of Cytopathology, University of Toulouse (E.U.-C.); and the Biomechanics Group, IMFT UMR CNRS 5502 (P.S.), Toulouse Cedex, France.

Editor's Note: This Manuscript was accepted for publication December 15, 2015.

The authors have no funding, financial relationships, or conflicts of interest to disclose.

Send correspondence to Guillaume de Bonnecaze, MD, Department of Otorhinolaryngology, Head and Neck Surgery, University of Toulouse, CHU Rangueil-Larrey, France. E-mail: guidb31@yahoo.fr

DOI: 10.1002/lary.25867

MATERIALS AND METHODS

Experimental Animals

Twenty New Zealand white rabbits (2.8–3.1 kg) were used in the present study. The animals were housed in a controlled environment (a 12-hour light/dark cycle at 21°C) with free access to water

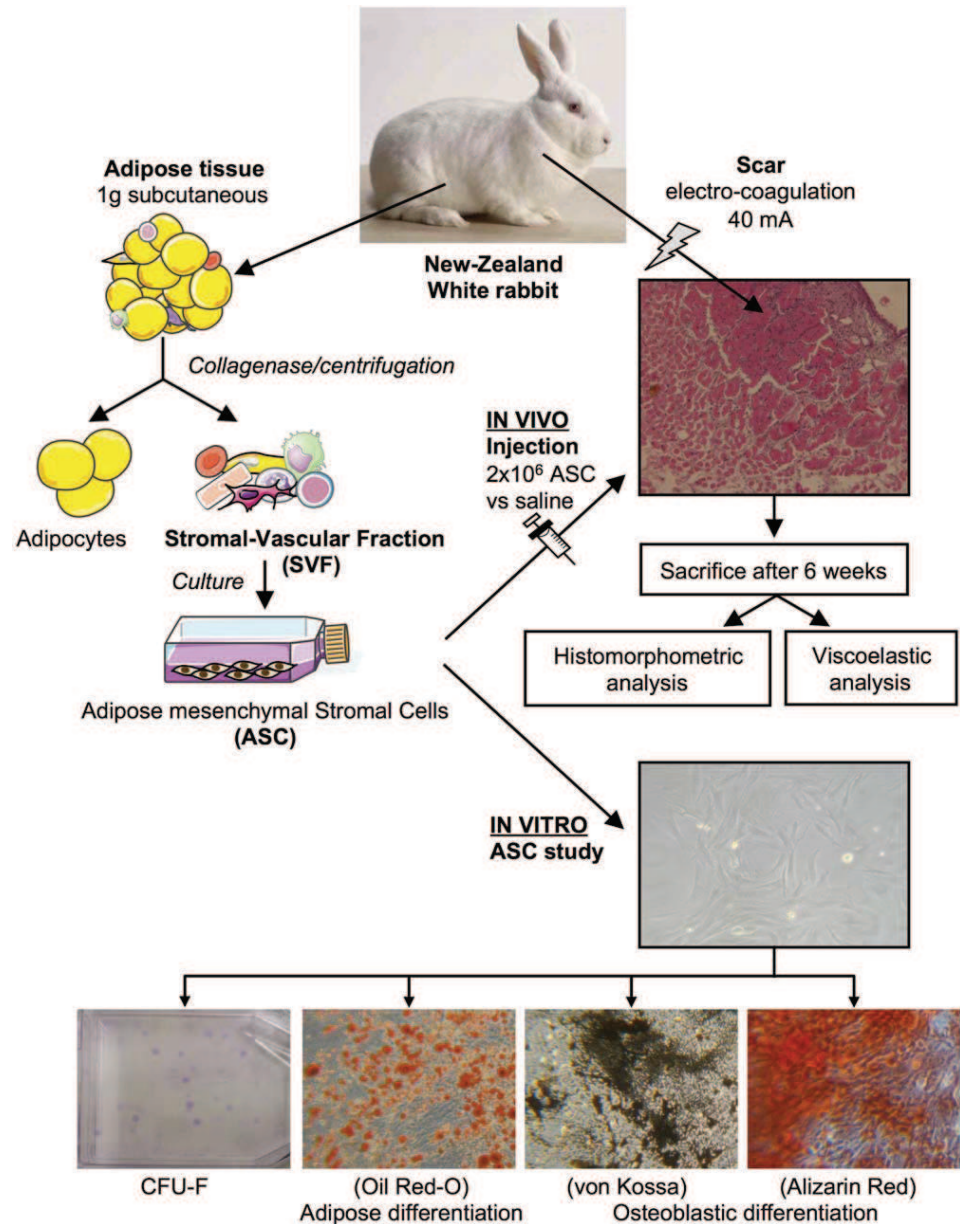


Fig. 1. Experimental protocol.

and a standard chow diet. Our institutional ethics committee approved all of the procedures; the committee considered that we had minimized the number of animals to be used, as well as their pain.

Surgical Procedure

Before surgery, each rabbit received intramuscular injections of Calmivet (5 mg/mL, 0.1 mL/kg; Vetoquinol, Lure Cedex, France), ketamine (50 mg/mL), and Rompun (2% weight/volume [w/v] xylazine) (0.25 mL/kg; Bayer Healthcare, Leverkusen, Germany). In the first surgical procedure, 1 g of subcutaneous fat was collected and immediately placed in phosphate-buffered saline (PBS) (Dulbecco, New-York, United States of America.). Fifteen days later, the ASCs were dispersed with trypsin (Gibco, Saint Aubin, France), and after counting (Beckman Coulter,

California, United States of America.) were diluted to 2×10^6 cells/0.2 mL PBS. On this day, all of the animals underwent their second surgical procedure under general anesthesia; the left-side vocal fold was scarred via calibrated electro cauterization. The animals were then separated into two groups, and all of the rabbits in the test group were immediately injected with autologous ASCs; controls received 0.9% (w/v) saline. The experimental protocol is summarized in Figure 1.

We performed cervicotomy with a median cricolaryngeotomy (Fig. 2). A midline incision from the crico thyroid membrane to the thyroid cartilage was then made to view the vocal folds. In preliminary work, we determined that 40 milliamperes (mA) electrocoagulation delivered over 1 second scarred all three layers of the vocal fold: the epithelium, Reinke's space, and the thyroarytenoid muscle. All of the operations were on the left side; the right side served as unscarred controls. The

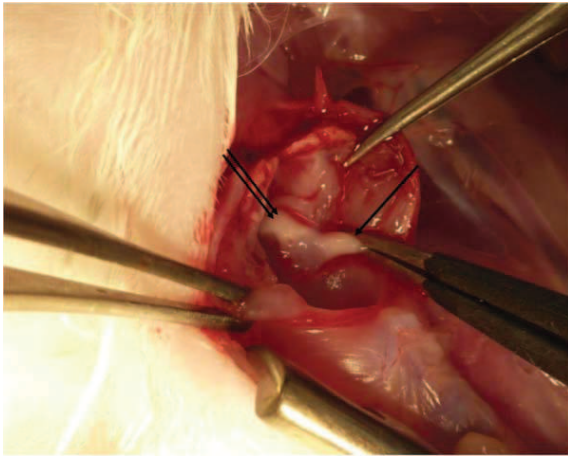


Fig. 2. Surgical procedure. After median laryngotomy, the left vocal fold was electrocauterized, and immediately injected with adipose tissue-derived stromal cells or saline (single arrow: vocal fold; double arrow: arytenoid cartilage).

full length of the vocal fold was scarred with the same intensity (40 mA). All of the injuries were performed in the same condition. Finally, the median thyroidotomy was closed.

Immediately after electrocoagulation, 14 left-side vocal folds were injected with 2×10^6 ASCs in 0.1 mL saline solution, and six folds were injected with 0.1 mL saline solution only. All of the injections were into the lamina propria using a 19-gauge needle.

All of the animals survived the procedure. We monitored their general status, well-being, appetite, and weight. No animals lost weight and no side effects of the ASCs injection were noted. After 6 weeks, all of the animals were painlessly sacrificed by intravenous injection of an overdose of sodium pentobarbital (54 mg/mL, 100 mg/kg; Ceva Santé, Libourne, France) under general anesthesia. The larynges were dissected out, and each larynx was divided at the sagittal midline. Seven left hemilarynges (four injected with ASCs, and three injected with saline) were immediately snap-frozen at -20°C prior to viscoelastic analysis. In total, 13 hemilarynges (10 injected with ASCs; 3 injected with saline) were placed in 4% (volume/volume) formaldehyde prior to histological analysis.

Preparation of Adipose-Derived Stromal Cells

Subcutaneous inguinal adipose tissue was digested at 37°C in PBS containing 2% bovine serum albumin and 2 mg/mL collagenase (Serva, Eidelberg, Germany) for 35 minutes. After elimination by filtration through 25- μm filters of undigested fragments, floating mature adipocytes were separated from the pellet-containing cells from the stromal vascular fraction by centrifugation (600 g, 10 minutes). Stromal-vascular fraction cells were plated (4,000 cells/ cm^2) in Dulbecco's Modified Eagle Medium (DMEM): Nutrient Mixture F-12 containing 10% newborn calf serum and supplemented with amphotericin 0.25 $\mu\text{g}/\text{mL}$, streptomycin 0.1 mg/mL, and penicillin 100 U/mL (all LifeTechnologies, Saint Aubin, France). At subconfluence, ASCs were passaged using trypsin-EDTA (ethylenediaminetetraacetic acid; LifeTechnologies) and cultured until use at passage P1. We confirmed that the adherent cells obtained had the conventional phenotypic signature of ASCs (CD34+, CD45-, CD31-, CD73+, and CD90+), as well as their *in vitro* characteristics (clonogenic activity using the colony-forming unit-fibroblast assay, differentiation potential into adipocytes and osteoblasts), as described by Zuk et al.⁵

Tissue Staining

Vocal folds removed from hemilarynges were further processed in 4% (v/v) paraformaldehyde, rinsed in 10% (w/v) sucrose, dehydrated in a graded series of ethanol baths, embedded in paraffin wax, and cut into 5- μm thick frontal (coronal) sections. The stains used were hematoxylin & eosin (H&E), picrosirius (to detect fibrosis), and orcein (to detect elastic fibers). We studied a 2-mm thick region in the middle of each vocal fold. We stained 10 slices with H&E (a slice every 200 μm), and five slices with picrosirius and orcein (a slice every 400 μm). On the H&E-stained slides, we measured the thicknesses of the epithelium and the lamina propria and calculated the average values (NIS-Elements 3.0, Nikon Inc., Melville, NY; 10 measurements on each of 10 samples). We assessed the extent of inflammation in each vocal fold. The Chisholm classification,¹⁵ derived to assess inflammation in salivary gland disease, was used to identify inflammatory foci, defined by colocalization of at least 50 immunocompetent cells (plasmacytes, macrophages, and/or histiocytes) (Fig 3). We evaluated the extent of fibrosis on the picrosirius-stained slides by calculating the average thickness of fibrosis within the lamina propria. We also studied the mean optical density analysis in 10 sections of picrosirius staining. The integrated optical density (IOD) was evaluated by

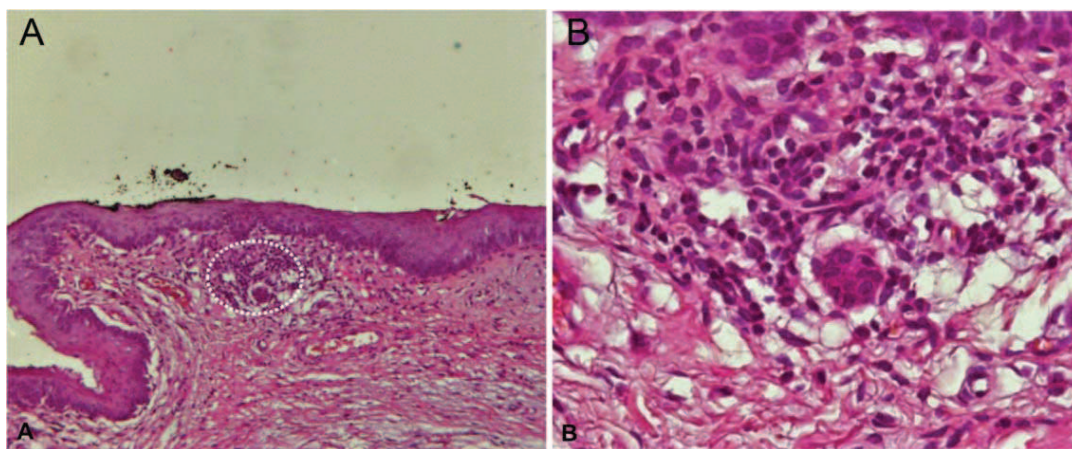


Fig. 3. Inflammatory foci (100 \times and 400 \times magnification) with a dotted circle around it (A). Each focus contains at least 50 inflammatory cells (B).

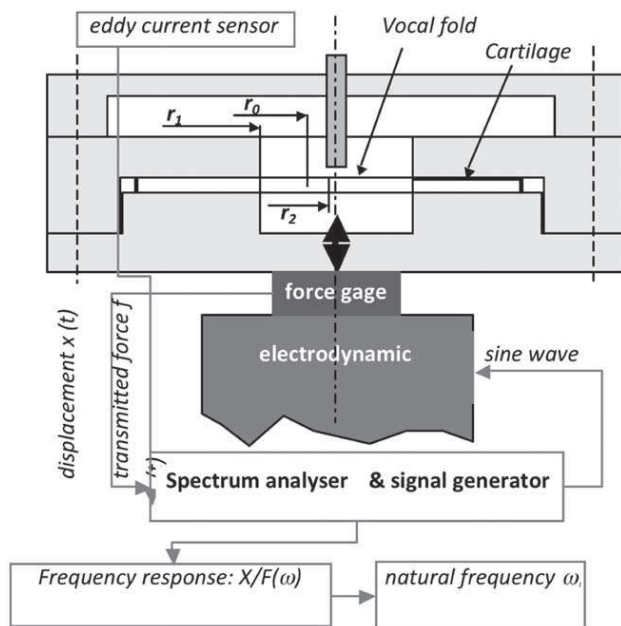


Fig. 4. The two degrees of freedom system. The experimental device is shown. The eddy current sensor measures the transverse displacement ($\times 2-\times 1$) of the vocal fold.

NIS-Elements 3.0 (Nikon Inc.). Orcein staining revealed the density of elastic fibers (fibers/5,000 μm^2 ; NIS-Elements 3.0, Nikon Inc.) and their organization. An experienced cytopathologist, blinded to the treatment, performed all of the histological analyses.

Immunohistochemistry

Paraffin-embedded sections were deparaffinized in xylene and dehydrated in ethanol. Blocking (1 hour) was performed in PBS. Slides were incubated with primary mouse monoclonal antibodies against collagen type 1 (clone C2456; Sigma-Aldrich, St. Louis, MO) or fibronectin (Sigma-Aldrich clone F0791); the levels of both proteins increased in pathological situations.¹⁶⁻¹⁹ Antibody fixation was detected by addition of 200- μL diethylaminoazobenzene. We studied the localization, organization, and density of the two proteins using a semiquantitative analysis performed by a trained specialist.

Persistence of Transplanted ASCs

In order to follow the presence of ASCs after administration in vocal focal folds, two additional rabbits were injected with ASCs expressing enhanced-green fluorescent protein (EGFP). Briefly, ASCs in primary culture were transduced overnight using a lentiviral vector (BiviC core vector facility, IFR 150, Toulouse, France) in a transduction medium containing serum-free medium, 15% BIT9500 (Stemcell Technologies, Grenoble, France), and 4 $\mu\text{g}/\text{mL}$ Protamine Choay (Sanofi-Aventis France, Paris, France) in the presence of purified lentiviral vectors at multiplicity of infection 50. Cells were collected 72 hours after transduction for EGFP-positive cells quantification by flow cytometry analysis on a fluorescent-activated cell sorter (FACS Canto II, Becton Dickinson, Mountain View, CA). Injected EGFP expressing ASCs were detected immunohistochemically using an anti-GFP antibody (Abcam, Cambridge, U.K.) in 20 tissue sections from each vocal fold.

Biomechanical Measurements (Using an Electrodynamic Shaker)

We used modal analysis to measure the viscoelastic properties of vocal folds. As shown in Figure 4, each vocal fold was clamped between two rigid blocks of polyethylene, forming a cylindrical structure with a point mass at the center. A hole was created at $r_2 = 1.5 \text{ mm} \pm 1\%$ in the center of the specimen. The implant and fixture masses were $1.53 \times 10^{-4} \text{ kg} \pm 0.5\%$ and $0.4 \text{ kg} \pm 0.1\%$, respectively. The average mass of the tissue surrounding the implant was $3.32 \times 10^{-4} \text{ kg} \pm 1\%$, which was estimated by averaging the specimen weights in a companion study²⁰ after destructive static pushout testing. We measured the first natural frequency, ω_1 , associated with the symmetric mode shape ϕ ; this was the maximum displacement of the central region of the vocal fold. To generate base excitation, the fixture was mounted on an electrodynamic shaker (Gearing & Watson, Hailsham, East Sussex, U.K.) fitted with a piezoelectric force gauge (8200 Brüel & Kjaer, Nærum, Denmark). An attached eddy current sensor (TQ102 Vibrometer, Meggit SA, Fribourg, Switzerland) allowed the relative displacement x_r of the central titanium region to be measured. The base displacement x_0 was monitored upon imposition of a swept sine wave in the range 20 Hz to 2.5 kHz. The frequency response function, $X_r/F(\Omega)$, was computed by Dynamic Signal and System Analyzer (Siglab; Spectral Dynamics, San Jose, CA). Here, the greatest value of Ω represents the first natural frequency ω_1 ; this frequency is characteristic of the biomechanical properties of a vibrating tissue and is correlated with the tissue k value; thus: $k = \omega_1^2 \times \text{weight (kg)}$. The reliability of the method and the capacity thereof to detect pathological changes have been described.²¹

Statistical Analysis

All of the values were expressed as means with standard deviations. A P value < 0.05 was considered statistically significant. Nonparametric comparisons between groups were made using Student's t test. We used the Mann-Whitney test (GraphPad Prism 5, GraphPad Software, San Diego, CA) to compare dynamic data.

RESULTS

Histology

We measured the epithelial and lamina propria thicknesses on 10 samples from each rabbit (7 scarred ASCs-injected vocal folds; 4 scarred saline-injected vocal folds; 3 untreated controls). The mean of epithelial thickness of nonscarred vocal folds was 60 μm (55–71 μm) versus 52 μm (47–60 μm) in the scarred vocal folds injected with ASCs, and was 45 μm (37–60 μm) in the noninjected scarred vocal folds ($P < 0.02$). The mean of lamina propria thickness of the nonscarred vocal folds was 130 μm (112–157 μm) versus 279 μm (152–369 μm) in the scarred vocal folds injected with ASCs, and was 510 μm (412–589 μm) in the noninjected scarred vocal folds ($P < 0.002$) (Fig. 5). Sirius red staining showed that the thicker folds exhibited higher levels of fibrosis. The optical density analysis showed that the IOD of vocal folds treated with ADSC was significantly lower than vocal folds treated with saline ($P < 0.01$) (Supp. File S1).

Orcein staining showed that scarring reduced the density of elastic fibers, ASCs injection significantly inhibited this decrease (nonscarred group: 82 fibers/5,000 μm^2 ; scarred ASCs-injected group: 40.3 fibers/5,000 μm^2 ; scarred noninjected group: 19.7 fibers/5,000

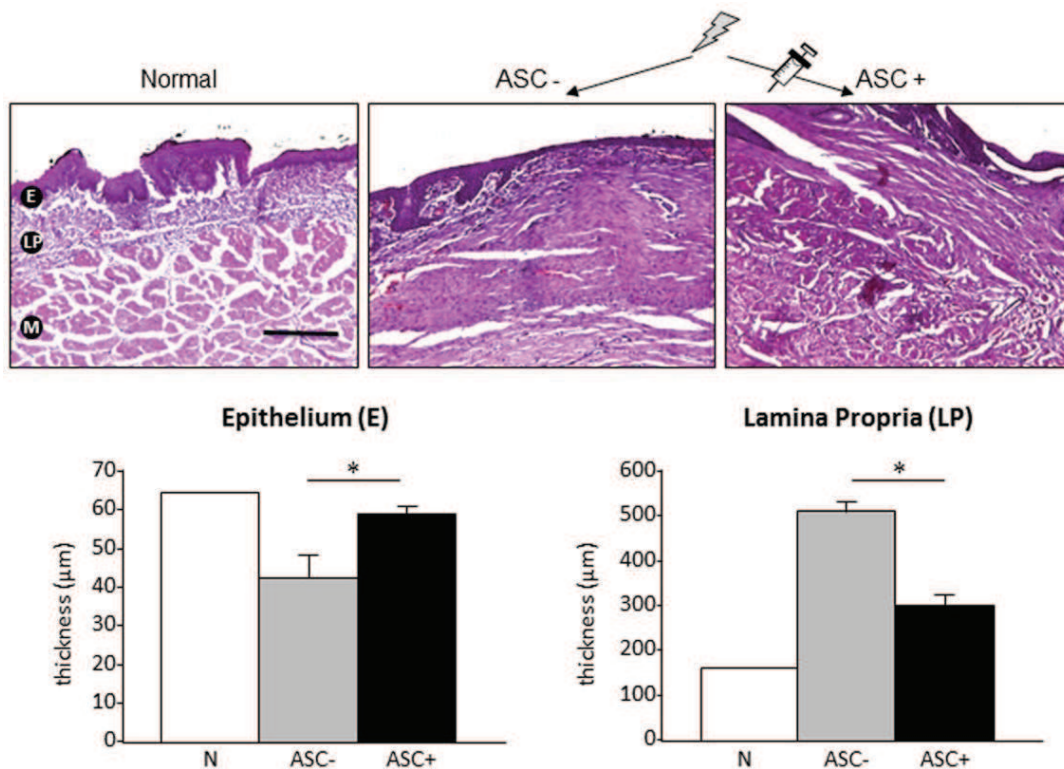


Fig. 5. Thickness of the lamina propria and epithelium. ASC limited lamina propria hypertrophy and epithelium atrophy 6 weeks after scarring. ASC = adipose-derived stromal cells; E = epithelium; LP = lamina propria.

μm ; $P < 0.001$). The extent of inflammation was higher in the scarred untreated group than the ASC-treated scarred group. The ASCs-treated scarred vocal folds had 0.8 (0–2) inflammatory foci/ mm^3 in contrast to the 3.5 foci (1–4) inflammatory foci/ mm^3 on saline-injected scarred vocal folds ($P < 0.005$).

Immunohistochemistry

In normal vocal folds, collagen type I was essentially confined to the upper region of the lamina propria

(Fig. 6). After scarring, the protein content decreased in this region but increased in the lower region in a disorganized manner. In the ASCs-injected group, collagen 1A levels decreased in the upper region of the lamina propria but did not accumulate in the lower region. The fibronectin labeling showed that the level of this protein was increased after scarring within the lamina propria. Adipose-derived stromal cells seemed to have no significant effect on this modification. Neither the density nor the organization of fibronectin varied between ASCs-injected and noninjected groups.

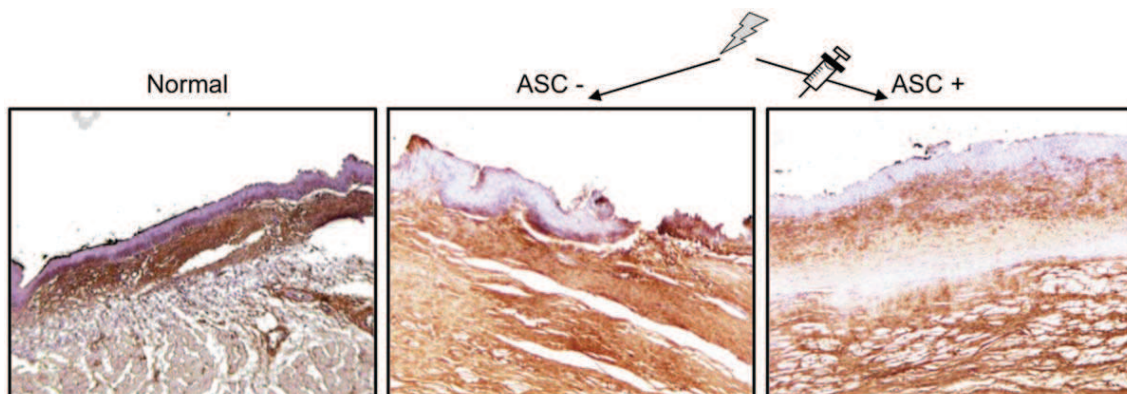


Fig. 6. Anti-collagen 1 immunohistochemistry magnification 100 \times : nonscarred (left), ASC noninjected (middle), and ASC-injected scarred (right) vocal fold. ASC = adipose-derived stromal cells.

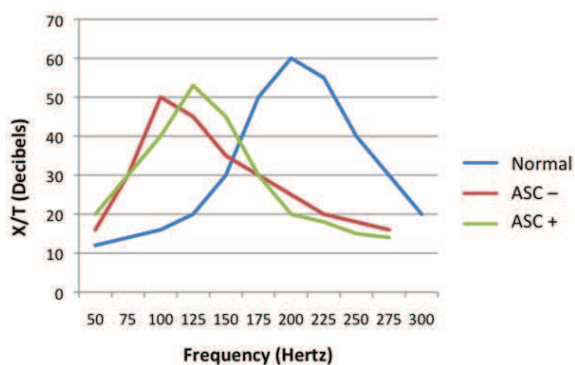


Fig. 7. The first natural frequency decreased 6 weeks after scarring. ASCs tended to normalize biomechanical properties. ASC = adipose-derived stromal cells.

Persistence of Transplanted Adipose-Derived Stromal Cells

After 21 days, most samples were negative for GFP-expressing cells, suggesting that ASCs were only transiently present (data not shown). Unspecific GFP labeling was observed in some epithelial (and adjacent endothelial) cells. No muscle or mesenchymal cells were found GFP-positive, showing that ASCs did not transdifferentiate into such cell types.

Biomechanical Data

Six weeks after scarring, the biomechanical properties of the vocal folds were measured. The first natural frequency and the X/F ratio decreased in noninjected scarred compared to control vocal folds ($P = 0.03$). Adipose-derived stromal cells mitigated the reduction of the first natural frequency in scarred vocal fold compared to noninjected scarred vocal fold ($P = 0.08$) (Fig. 7). The mean of the first natural frequency of the normal vocal folds was 212 Hz (194–236 Hz) but was 120 Hz (110–125 Hz) in ASCs-injected vocal folds and 100 Hz (98–111 Hz) in scarred noninjected vocal folds, suggesting that ASCs might limit biomechanical changes of the vocal fold after scarring.

DISCUSSION

Over the last decade, it has become clear that stem cell therapy was probably the most promising treatment for severe vocal disturbance that develops after vocal fold scarring. Various stem cells (mesenchymal stem cells [MSCs], bone marrow-derived stem cells [bMSCs], and human embryonic stem cells [hESCs]) have been used in different preclinical models. Most models were performed using allogenic transplantation of cells accompanied by immunosuppression. Kanemaru et al.^{1,2} showed that bMSCs assisted regeneration of scarred vocal folds in a nude rat model 8 weeks after injection. More recently, the same group showed that dogs injected with autologous bMSCs enjoyed faster functional recovery than animals treated with autologous induced-muscle progenitor cells. Hertegård et al.³ applied human

mesenchymal stem cells (hMSCs) to a rabbit model, demonstrating that the cells seemed to improve vocal fold wound healing. More recently, Svensson et al.²² found a significant reduction in lamina propria thickness after injection of hMSCs. Cedervall et al.⁴ used hESCs in a rabbit model and reported that the cells improved the biomechanical properties of the vocal fold. However, from the viewpoint of the ENT surgeon, the clinical use of hESCs requires additional robust safety data and is limited by ethical concerns.

Adipose tissue was long considered inert and unattractive. However, over the past 20 years, it has become recognized that mesenchymal cells of this tissue exhibit beneficial trophic effect and the ability to support tissue regeneration and functional recovery after an initial lesion.²³ In addition, this tissue is an abundant source of MSCs, which can be easily removed under local anesthesia, dispersed, and percutaneously injected into a scarred vocal fold. Only few studies have already explored the use of ASCs to manage acute or chronic vocal fold scarring,^{12–14} mainly with nonautologous cells. We sought to develop a preclinical model of ASCs therapy to treat acute vocal fold scarring without the need for immunosuppression.

We found that ASCs improved vocal fold wound healing. Our data are in accordance with Hertegård³ and Rousseau,^{16–24} who showed that vocal fold scarring increased lamina propria thickness, which is principally caused by increased fibrosis. We obtained that ASCs injected immediately after scarring reduced hypertrophy and fibrosis. Similar results have recently appeared.^{9,25–27} We evaluated all of the 16 injected animals and revealed that in two treated rabbits, the lamina propria thickness was near-normal (157 μm vs. 130 μm). Similar results have recently been reported.^{9,12} The antifibrotic properties of ASCs have also been demonstrated in vitro. Kumai et al.^{12,13} sought to modulate the activities of fibroblasts within vocal fold scars and found that ASCs changed the secretion profile of the resident fibroblasts. They showed that in the presence of ASCs collagen secretion fell, the fibroblasts proliferated and synthesis of hepatocyte growth factor (HGF) and hyaluronic acid increased. Fibroblasts regulate synthesis of the extracellular matrix compounds in response to paracrine or mechanical stimuli.^{17,18} Thus, ASCs may exert a paracrine-like effect on resident fibroblasts, probably by mediating the synthesis of HGF, fibroblast growth factor 2, TGF- β , or MMP9–1. Indeed Hiwatashi et al.¹⁴ demonstrated that the synthesis of HGF; FGF2; and hyaluronan synthase 1, 2, and 3 was upregulated in the ASCs group.

Residual inflammation is one of the most common causes of surgical failure; all of the surgical procedures are aggressive and trigger local inflammation. Mesenchymal stem cells exhibited immunomodulatory effects and injection of such cells can control graft-versus-host disease¹⁰; MSCs also inhibited immune cell proliferation in vitro.¹¹ In the present study, we found it difficult to measure residual vocal fold inflammation after 6 weeks. We performed blinded semiquantitative histological assessment and suggested that ASCs significantly

limited inflammation. Further studies on the role of ASCs in proinflammatory cytokine production—including IL-1, IL-6, and TNF α —are still required. However, the decrease in inflammatory cell numbers in ASCs-injected scarred vocal folds is encouraging.

Scarring and stiffness of vocal folds have previously been attributed to an increase in the collagen content of the lamina propria.^{16,24} Preliminary studies showed that MSCs injection significantly reduced the level of collagen type I,³ but more recently Cedervall et al.⁴ found otherwise. We confirmed that collagen type I was located in the upper part of the lamina propria,¹⁶ and that scarring increased the level thereof and rendered the collagen structure disorganized, especially in the lower part of the lamina propria. Adipose-derived stromal cells injection appeared to limit such collagen fibers remodeling, as well as changes in the numbers of elastin fibers. In contrast, we confirmed that scarring increased the fibronectin content, which was unaffected by ASCs injection.

We measured laryngeal function in an original manner, eschewing parallel plate rheometry. An electrodynamic shaker better evaluates vibratory tissue such as the vocal fold. The procedure has undergone preliminary validation²¹ and seems to be reliable and reproducible. We found that vocal fold scarring decreased the first resonant frequency and the stiffness (according to the formula $k = \omega_1^2 \times \text{weight}$). Adipose-derived stromal cells injection immediately after acute scarring limited these decrease. After scarring, ω_1 decreased and lead to k decrease as well. A reduction in stiffness caused by scarring is the most common cause of vocal disturbance,^{28,29} probably due to the limitation of oscillations during phonation. The stiffness decrease in soft tissues correlates with a similar decrease in resistance to trauma such as elastic deforming capacity. The histomorphometric analyses performed, especially highlighting the decrease in elastin fibres into lamina propria, helped us to understand the mechanisms explaining biomechanical alterations. Elastin fibers are the most important protein involved in vocal fold vibration and resistance to trauma. The observed decrease in elastin fibers might then have affected vibration and probably modified the first natural frequency. Because the biomechanical shaker was tested on bone structures, and the rate of change in the first natural frequency for the ADSC treated samples was not significant as compared to the nontreated scarred samples, this functional analysis does not allow at this moment clear conclusions. Further experimentations with a highest number of vocal folds could allow us to definitively conclude.

The persistence of transplanted cells is controversial. After 3 weeks, no GFP-positive ASCs were identified, and no GFP signal was detected from mesenchymal or muscle cells. Our results differ from those of Kanemaru et al.,^{1,2} Hertegård et al.,³ and Cedervall et al.⁴; all reported that a transdifferentiation potential was evident *in vivo*. More recently, Svensson et al.²² and Hiwataishi et al.¹⁴ failed to find any surviving injected cells 10 weeks and 1 month after transplantation, respectively, and concluded that the observed improvements in vocal fold healing was not solely attributable to any transdif-

ferentiation potential. It is possible that ASCs may differentiate into different cell lineages, but ASCs may also exert a predominantly paracrine-like effect. Various approaches including fluorescence *in situ* hybridization, the use of specifically labeled anti-human ASCs probes, reverse transcription polymerase chain reaction, fluorescence *in situ* hybridization analysis, and the use of GFP transgenic mice were used in the cited studies. In addition, the animals were sacrificed at different times (14–70 days), and animal numbers were limited. The question of ASCs persistence remains controversial and thus additional studies are needed. Nevertheless, ASCs injection caused no observable side effects in our rabbit model and appeared to be safe. All of the tissue samples were histopathologically normal, and we found no sign of dysplasia or anaplasia. Thus, ASCs injection may be safe. However, malignancy would not arise within 6 weeks; therefore, long-term studies are required to properly explore this risk with ASCs injection. Most severe vocal disturbances are attributable to chronic lesions and scarring, but studies on the effects of ASCs in chronic scarring models are not currently available. The improvements observed in scarred ASCs-injected vocal folds compared to saline-injected folds seemed rather limited and may be not sufficient to improve human vocal function. Combinations of cell therapy with biomaterials or growth factors may be necessary.^{30–33} Indeed, according to Lianq et al.³³ 4 weeks after injury, no scar formed in vocal folds treated with ASCs-micronized acellular matrix (MADM) (dermal matrix) or ASCs. Eight weeks after injury, vocal folds treated with MADM and control vocal folds became atrophic and showed scarring, and there were no obvious differences between them, whereas vocal folds treated with ASCs- MADM or ASCs were not atrophic and had a smoother surface.

CONCLUSION

Cell therapy using MSCs or (especially) ASCs appears to be an effective method for treating vocal fold scarring associated with severe vocal disturbance. We found that injection of autologous ASCs improved vocal fold wound healing, especially with regard to fibrosis, inflammation, elasticity, and stiffness. Encouraging but modest changes were noted in our model that limited direct extrapolation to human for vocal fold function recovery. Transplantation of ASCs offers promises but still requires further investigation to achieve stronger conclusion to further consider clinical applications.

Acknowledgments

The authors thank Mrs Daussion for her support in animal experiments at the Department of Experimental Surgery, Toulouse University, Toulouse, France.

Each author's role/participation: Guillaume de Bonnecaze, MD: study concept and design, article preparation, article review, data acquisition; Benoit Chaput, MD: article preparation, article review, statistical analysis; Virginie Woisard, MD: study original concept, data acquisition, surgical procedure; Emmanuelle Uro-Coste, MD: single blind histomorphometric analysis; Pascal Swider, PhD:

viscoelastic analysis; Sebastien Vergez, MD, PhD: study design, article review; Elie Serrano, MD: article review; Valerie Planat-Benard, PhD: study design, ASC preparation, article review; and Louis Casteilla, PhD: head director of the laboratory.

BIBLIOGRAPHY

1. Kanemaru S-I, Nakamura T, Yamashita M, et al. Destiny of autologous bone marrow-derived stromal cells implanted in the vocal fold. *Ann Otol Rhinol Laryngol* 2005;114:907-912.
2. Kanemaru S-I, Nakamura T, Omori K, et al. Regeneration of the vocal fold using autologous mesenchymal stem cells. *Ann Otol Rhinol Laryngol* 2003;112:915-920.
3. Hertegard S, Cedervall J, Svensson B, et al. Viscoelastic and histologic properties in scarred rabbit vocal folds after mesenchymal stem cell injection. *Laryngoscope* 2006;116:1248-1254.
4. Cedervall J, Ahrlund-Richter L, Svensson B, et al. Injection of embryonic stem cells into scarred rabbit vocal folds enhances healing and improves viscoelasticity: short-term results. *Laryngoscope* 2007;117:2075-2081.
5. Zuk PA, Zhu M, Mizuno H, et al. Multilineage cells from human adipose tissue: implications for cell-based therapies. *Tissue Eng* 2001;7:211-228.
6. Gimble JM, Guilak F. Differentiation potential of adipose derived adult stem (ADAS) cells. *Curr Top Dev Biol* 2003;58:137-160.
7. Ebrahimi TG, Pouzoulet F, Squiban C, et al. Cell therapy based on adipose tissue-derived stromal cells promotes physiological and pathological wound healing. *Arterioscler Thromb Vasc Biol* 2009;29:503-510.
8. Planat-Benard V, Silvestre J-S, Cousin B, et al. Plasticity of human adipose lineage cells toward endothelial cells: physiological and therapeutic perspectives. *Circulation* 2004;109:656-663.
9. Mazo M, Planat-Benard V, Abizanda G, et al. Transplantation of adipose derived stromal cells is associated with functional improvement in a rat model of chronic myocardial infarction. *Eur J Heart Fail* 2008;10:454-462.
10. Yanez R, Lamana ML, Garcia-Castro J, Colmenero I, Ramirez M, Bueren JA. Adipose tissue-derived mesenchymal stem cells have in vivo immunosuppressive properties applicable for the control of the graft-versus-host disease. *Stem Cells* 2006;24:2582-2591.
11. Puissant B, Barreau C, Bourin P, et al. Immunomodulatory effect of human adipose tissue-derived adult stem cells: comparison with bone marrow mesenchymal stem cells. *Br J Haematol* 2005;129:118-129.
12. Kumai Y, Kobler JB, Park H, et al. Crosstalk between adipose-derived stem/stromal cells and vocal fold fibroblasts in vitro. *Laryngoscope* 2009;119:799-805.
13. Kumai Y, Kobler JB, Park H, Galindo M, Herrera VLM, Zeitels SM. Modulation of vocal fold scar fibroblasts by adipose-derived stem/stromal cells. *Laryngoscope* 2010;120:330-337.
14. Hiwatashi N, Hirano S, Mizuta M, et al. Adipose-derived stem cells versus bone marrow-derived stem cells for vocal fold regeneration. *Laryngoscope* 2014;124:461-469.
15. Chisholm DM, Mason DK. Labial salivary gland biopsy in Sjogren's disease. *J Clin Pathol* 1968;21:656-660.
16. Rousseau B, Hirano S, Chan RW, et al. Characterization of chronic vocal fold scarring in a rabbit model. *J Voice* 2004;18:116-124.
17. Pawlak AS, Hammond T, Hammond E, Gray SD. Immunocytochemical study of proteoglycans in vocal folds. *Ann Otol Rhinol Laryngol* 1996;105:6-11.
18. Catten M, Gray SD, Hammond TH, Zhou R, Hammond E. Analysis of cellular location and concentration in vocal fold lamina propria. *Otolaryngol Head Neck Surg* 1998;118:663-667.
19. Dikkers FG, Nikkels PG. Lamina propria of the mucosa of benign lesions of the vocal folds. *Laryngoscope* 1999;109:1684-1689.
20. Daugaard H, Elmengaard B, Bechtold JE, Soballe K. Bone growth enhancement in vivo on press-fit titanium alloy implants with acid etched microtexture. *J Biomed Mater Res A* 2008;87:434-440.
21. Swider P, Guerin G, Baas J, Soballe K, Bechtold JE. Characterization of bone-implant fixation using modal analysis: application to a press-fit implant model. *J Biomech* 2009;42:1643-1649.
22. Svensson B, Nagubothu SR, Cedervall J, et al. Injection of human mesenchymal stem cells improves healing of vocal folds after scar excision—a xenograft analysis. *Laryngoscope* 2011;121:2185-2190.
23. Cousin B, Caspar-Bauguil S, Planat-Benard V, Laharrague P, Penicaud L, Casteilla L. Adipose tissue: a subtle and complex cell system. *J Soc Biol* 2006;200:51-57.
24. Rousseau B, Hirano S, Scheidt TD, et al. Characterization of vocal fold scarring in a canine model. *Laryngoscope* 2003;113:620-627.
25. Kamada Y, Yoshida Y, Saji Y, et al. Transplantation of basic fibroblast growth factor-pretreated adipose tissue-derived stromal cells enhances regression of liver fibrosis in mice. *Am J Physiol Gastrointest Liver Physiol* 2009;296:157-167.
26. Suga H, Eto H, Shigeura T, et al. IFATS collection: fibroblast growth factor-2-induced hepatocyte growth factor secretion by adipose-derived stromal cells inhibits postinjury fibrogenesis through a c-Jun N-terminal kinase-dependent mechanism. *Stem Cells* 2009;27:238-249.
27. Kumai Y, Kobler JB, Herrera VLM, Zeitels SM. Perspectives on adipose-derived stem/stromal cells as potential treatment for scarred vocal folds: opportunity and challenges. *Curr Stem Cell Res Ther* 2010;5:175-181.
28. Dailey SH, Tateya I, Montequin D, Welham NV, Goodyer E. Viscoelastic measurements of vocal folds using the linear skin rheometer. *J Voice* 2009;23:143-150.
29. Thibeault SL, Bless DM, Gray SD. Interstitial protein alterations in rabbit vocal fold with scar. *J Voice* 2003;17:377-383.
30. Duflo S, Thibeault SL, Li W, Shu XZ, Prestwich GD. Vocal fold tissue repair in vivo using a synthetic extracellular matrix. *Tissue Eng* 2006;12:2171-2180.
31. Xu W, Hu R, Fan E, Han D. Adipose-derived mesenchymal stem cells in collagen-hyaluronic acid gel composite scaffolds for vocal fold regeneration. *Ann Otol Rhinol Laryngol* 2011;120:123-130.
32. Choi JW, Park JK, Chang JW, et al. Small intestine submucosa and mesenchymal stem cells composite gel for scarless vocal fold regeneration. *Biomaterials* 2014;35:4911-4918.
33. Liang Q, Liu S, Han P, et al. Micronized acellular dermal matrix as an efficient expansion substrate and delivery vehicle of adipose-derived stem cells for vocal fold regeneration. *Laryngoscope* 2012;122:1815-1825.