



HAL
open science

Enhancing Eye Fundus Images for Diabetic Retinopathy Screening

Guillaume Noyel, Michel Jourlin, Michel Smans, Rebecca Thomas, Simon Iles, Gavin Bhakta, Andrew Crowder, David Owens, Peter Boyle

► **To cite this version:**

Guillaume Noyel, Michel Jourlin, Michel Smans, Rebecca Thomas, Simon Iles, et al.. Enhancing Eye Fundus Images for Diabetic Retinopathy Screening. American Diabetes Association 77th Scientific Sessions - ADA2017, Jun 2017, San Diego, CA, United States. , 608-P / 608, 2017. hal-01539980

HAL Id: hal-01539980

<https://hal.science/hal-01539980v1>

Submitted on 15 Jun 2017

HAL is a multi-disciplinary open access archive for the deposit and dissemination of scientific research documents, whether they are published or not. The documents may come from teaching and research institutions in France or abroad, or from public or private research centers.

L'archive ouverte pluridisciplinaire **HAL**, est destinée au dépôt et à la diffusion de documents scientifiques de niveau recherche, publiés ou non, émanant des établissements d'enseignement et de recherche français ou étrangers, des laboratoires publics ou privés.

Copyright

Enhancing Eye Fundus Images for Diabetic Retinopathy Screening

608-P

Guillaume Noyel¹, Michel Jourlin², Michel Smans¹, Rebecca Thomas³, Simon Iles⁴, Gavin Bhakta⁴, Andrew Crowder⁴, David Owens³, Peter Boyle^{1,5}

1. International Prevention Research Institute, Lyon, France | 2. Laboratoire Hubert Curien, UMR CNRS 5516, Saint-Etienne, France | 3. Diabetes Research Group, Institute of Life Sciences, College of Medicine, Swansea University, Wales, UK | 4. Diabetic Eye Screening Wales, Wales, UK | 5. Strathclyde Institute of Global Public Health, University of Strathclyde, Glasgow, UK | Correspondence: guillaume.noyel@i-pri.org

ABSTRACT

Many eye fundus images present strong variations of contrast which can be a limitation to the diagnosis of the retinopathy. Either some lesions are not taken into account or only a limited part of the domain of the image can be read. Graders have to manually adjust the contrast, which is tedious and not easily reproducible.

We have developed an automatic system, which standardises the colour contrast across the whole domain of the image. The method is consistent with the physical principles of image formation and ensures that the colour aspect of lesions such as micro-aneurysms or anatomical structures such as veins are similar. It is more powerful than the existing grey level methods.

We have tested our approach on several thousand images acquired in good or in harsher conditions. Some were bright while others were dark. Expert graders have checked the enhanced images. Diagnosis becomes more obvious and the grading more comfortable.

Another limitation for the diagnosis is that images of the same patient acquired for different examinations cannot be directly superimposed. Indeed, the eye of the patient is never in the exact same position, the image is a projection of a 3D scene into the plane of the sensor, the optics of the camera creates a radial deformation and the colour of the image may have changed.

We have developed an automatic method to superimpose eye fundus images acquired in the same position (nasal or macular). It is based on contrast standardisation, matching of salient points and a deformation model taking into account two radial distortions.

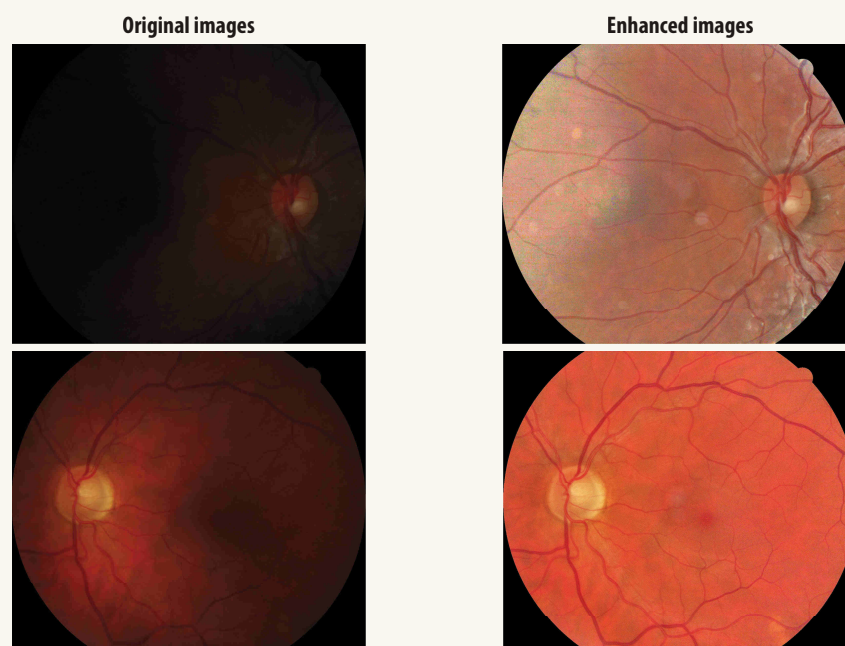
We have performed tests for 69 patients with pairs of retinal examinations acquired in good conditions at an interval of one year with and without the same camera. A similar test has been performed on 5 patients with 20 pairs acquired in harsher conditions. A minimum of 96% of pairs were correctly superimposed. This is an important step towards the longitudinal analysis of large public health databases.

CONTRAST ENHANCEMENT

Figure 1 illustrates the improvement brought by our method of standardizing the colour contrast across the entire image.

The enhanced colour images allow a more comfortable grading and a more obvious diagnostic.

Figure 1. Contrast enhancement by our colour method



Retinal exam of the same patient with a year of interval acquired in harsh conditions (strong variation of contrast in the original images)

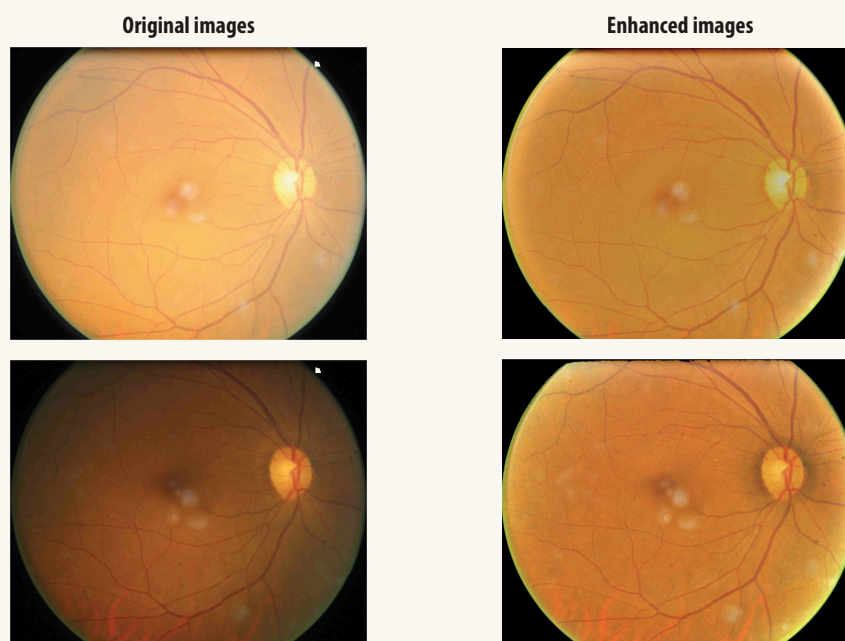


IMAGE SUPERIMPOSITION

Figure 2 details (with false colours) the two corrections needed for a proper superimposition (position and distortion).

Figure 2. Naive and correct superimposition of pairs of eye fundus images

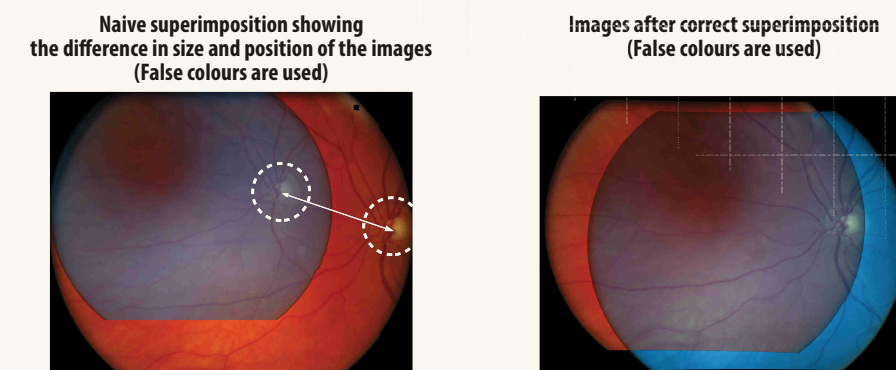
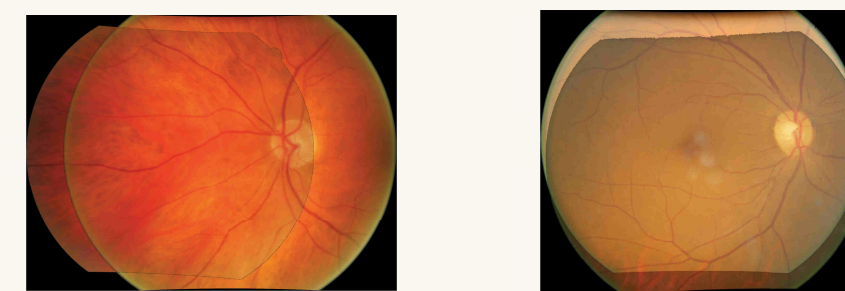


Figure 3 illustrates the result of the method.

Figure 3. Correct superimpositions of pairs of eye fundus images



RESULTS AND CONCLUSIONS

Our automatic method will allow an easier follow-up of patients with diabetic retinopathy.