



HAL
open science

Early Detection of Progressive Adolescent Idiopathic Scoliosis: A Severity Index

Wafa Skalli, Claudio Vergari, Eric Ebermeyer, Isabelle Courtois, Xavier Drevelle,
Kariman Abelin-Genevois, Remi Kohler, Jean Dubousset

► **To cite this version:**

Wafa Skalli, Claudio Vergari, Eric Ebermeyer, Isabelle Courtois, Xavier Drevelle, et al.. Early Detection of Progressive Adolescent Idiopathic Scoliosis: A Severity Index. *Spine*, 2016, <10.1097/BRS.0000000000001961>. <hal-01532147>

HAL Id: hal-01532147

<https://hal.science/hal-01532147v1>

Submitted on 20 Jun 2017

HAL is a multi-disciplinary open access archive for the deposit and dissemination of scientific research documents, whether they are published or not. The documents may come from teaching and research institutions in France or abroad, or from public or private research centers.

L'archive ouverte pluridisciplinaire **HAL**, est destinée au dépôt et à la diffusion de documents scientifiques de niveau recherche, publiés ou non, émanant des établissements d'enseignement et de recherche français ou étrangers, des laboratoires publics ou privés.



HAL Authorization

Early detection of progressive adolescent idiopathic scoliosis: a severity index

Wafa Skalli PhD^{1*}, Claudio Vergari PhD^{1,2}, Eric Ebermeyer MD³, Isabelle Courtois MD³,
Xavier Drevelle PhD¹, Kariman Abelin-Genevois MD⁴, Remi Kohler MD⁴, Jean Dubousset MD¹

Abstract

Study Design. Early detection of progressive adolescent idiopathic scoliosis (AIS) was assessed based on 3D quantification of the deformity.

Objective. Based on 3D quantitative description of scoliosis curves, the aim is to assess a specific deformation pattern that could be an early detectable severity index for progressive AIS.

Summary of Background Data. Early detection of progressive scoliosis is important for adapted treatment to limit progression. However, progression risk assessment is mainly based on the follow up, waiting for signs of rapid progression that generally occur during the growth peak.

Methods. 65 mild scoliosis (16 boys, 49 girls, Cobb Angle between 10 and 20°) with a Risser between 0 and 2 were followed from their first exam until a decision was made by the clinician, either considering the spine as stable at the end of growth (26 patients) or planning to brace because of progression (39 patients). Calibrated bi-planar X-rays were performed and 3D reconstructions of the spine allowed to calculate six local parameters related to main curve deformity. For progressive curve 3D phenotype assessment, data were compared to those previously assessed for 30 severe scoliosis (Cobb Angle > 35°), 17 scoliosis before brace (Cobb Angle > 29°) and 53 spines of non-scoliosis subjects. A predictive discriminant analysis was performed to assess similarity of mild scoliosis curves either to those of scoliosis or non-scoliosis spines, yielding a severity index (S-index). S-index value at first exam was compared to clinical outcome.

Results. At the first exam, 53 out of 65 predictions (82%) were in agreement with actual clinical outcome. 89 % of the curves that were predicted as progressive proved accurate

Conclusion. Although still requiring large scale validation, results are promising for early detection of progressive curves.

Keywords: scoliosis; progression, 3D quantification, severity index, prognosis.

Key Points

- A specific 3D phenotype of severe scoliosis was defined.
- This 3D phenotype appears in some mild scoliosis curve at the first exam.
- A severity index was developed to discriminate progressive from non-progressive mild scoliosis
- This S-index achieved an overall accuracy of 82%

* Corresponding author: wafa.skalli@ensam.eu

¹ Arts & Metiers ParisTech, LBM, 151 bd de l'Hopital 75013 Paris – France

² School of Physics and Astronomy, University of Exeter, Exeter, UK

³ Unite Rachis, CHU - Hopital Bellevue, 25 boulevard Pasteur 42100 Saint-Etienne, France

⁴ Department of Paediatric Orthopaedics, Hospices Civils de Lyon, Claude Bernard Lyon 1 University, Lyon, France

Introduction

Adolescent Idiopathic Scoliosis (AIS) is a complex pathology with local and spinal three dimensional (3D) deformities [1, 2]. Early detection of progression risk is essential to establish the treatment strategy [3, 4], but it remains challenging. Numerous studies in genetics, biology, neurosciences and biomechanics have investigated the initiation and progression of AIS [5, 6]. Progression risk assessment is mainly based on the follow-up, particularly during the growth peak, when a rapid progression can occur [3, 4]. Predictive factors include gender, skeletal maturity, potential of remaining skeletal growth, curve location and magnitude, apical axial rotation [7-9]. However, no definite criteria exist for reliable prediction of curve progression risk at an early stage [10-14]. Mechanisms of progression were investigated using numerical simulation on subject specific models, and scoliosis-like progression could be reproduced for several mild scoliosis spines when combining gravity effects with abnormal anterior growth and disc laxity [15]. However such scoliosis-like progression was never obtained for non-scoliotic spines, suggesting that an initial deformity could be of paramount importance in the biomechanical mechanism yielding curve progression.

Accurate 3D reconstruction methods from routine low dose biplanar X-Rays allow quantitative 3D analysis [16, 17], and a specific 3D deformation phenotype has been described for severe scoliosis curves [18-20].

The aim of this study is to propose a severity index based on a 3D deformation phenotype for early estimation of progression risk, with a preliminary evaluation based on follow-up of AIS patients.

Material and methods

Data collection

Data were collected prospectively or retrospectively from two hospitals within routine clinical investigation after approval by the ethical committee and formal patient and parents' consent. Inclusion criteria were: diagnosis of AIS with decision of follow up; Cobb angle range: 10-20°; age \geq 10 years; Risser between 0 or 2.

Sixty-five patients (16 boys, 49 girls) were considered, with mean age 12 years (range 7 - 15) and mean Cobb angle 14.8° (range 10° - 20°). Patients were followed until considered as stable, with Risser \geq 3 and Cobb lower than 25° (26 patients), or until a brace decision was taken (39 patients).

Biplanar X-Rays and 3D deformation phenotype

Frontal and lateral X-rays of each patient were acquired using either the EOS™ system (n = 33) or a stereo radiographic device (n = 32) [17, 21], which was first used in one of the clinical centers before the EOS™ system availability.

Acquisitions were performed in a free standing position following the SRS recommendation as described by Faro *et al.* [22], or modified to place the fingers on the zygomatic arch. All 3D reconstruction of the subject's spine was obtained using the method described by Humbert & al. [23] (Figure 1), using a research version of the STEREOS software. Semi automatic reconstruction process involves manual detection of few anatomic landmarks, yielding an initial 3D model which was retroprojected on the X-rays, then manual adjustments so that the retroprojected contours fit the vertebral contours on the X-Rays.

From this 3D reconstruction, the process was fully automatic: global and local coordinate systems (CS) were defined [24], to compute vertebral rotations in the global CS, and inter-vertebral rotations (i.e. rotation of each vertebra regarding the lower adjacent one) in the local CS of the lower adjacent vertebra. Six specific parameters were computed to describe the main curve deformation phenotype (Figure 2):

1. 2D Cobb angle, measured on the frontal X-Ray [25].
2. Vertebral Axial Rotation (VAR) at the apical level [20]
- 3-4. Intervertebral Axial Rotation at the upper and lower junction (upper IAR and lower IAR) [20].
5. Torsion index [26], computed as the mean of the sum of intervertebral axial rotations from lower junction to apex and from apex to upper junction.
6. Hypokyphosis index: this parameter is based on the observation of hypokyphosis in severe scoliosis curves, in their local sagittal plane [1]. It was defined as the difference between the local kyphosis (or lordosis) of the given subject at the apex and the mean value at the equivalent level for

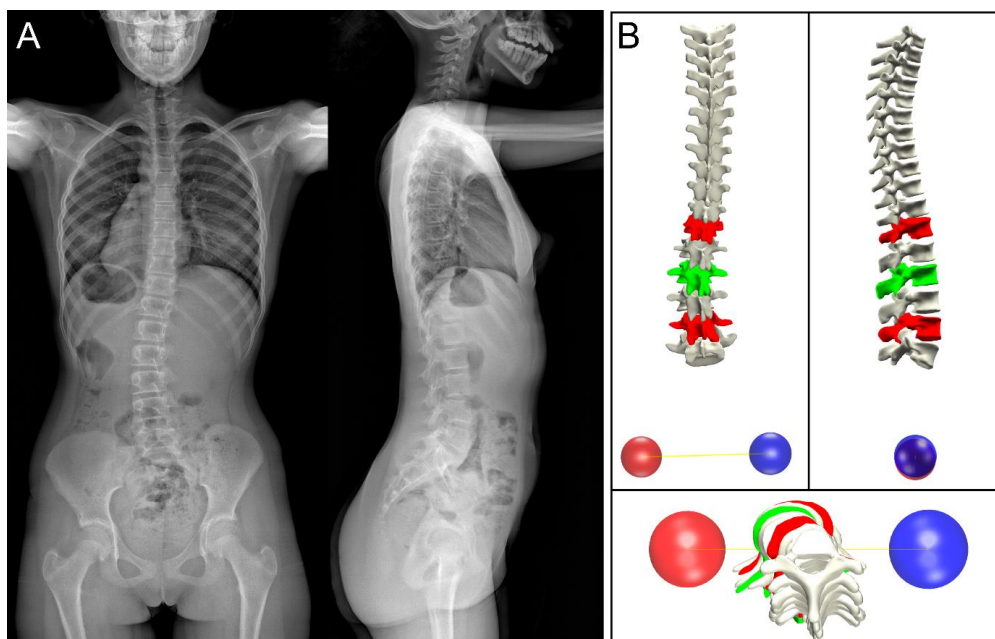


Fig. 1. A: Bi-planar X-rays; B: patient-specific 3D reconstruction (apex is in green while junctional areas are in red; posterior, lateral and top views).

the non-scoliosis subjects.

Data analysis and severity index assessment

The 3D deformation phenotype of each mild AIS patient was automatically compared to those of patients from comparative groups, whose biplanar X-Rays were collected in previous studies:

- 53 non-scoliotic subjects with no antecedents or radiological abnormality of spine or pelvis (20 female, 33 male, mean age: 21 years, range 9-36).
- 45 scoliotic patients with progressive curves:
 - 17 collected just before brace treatment (16 females, 1 male; mean age: 12 years, mean Cobb angle 28° , range $21^\circ - 37^\circ$).
 - 30 collected during their routine preoperative examination (22 females, 8 males, mean age : 16 years, mean Cobb 57° , range $36^\circ - 85^\circ$).

Four groups were considered for statistical analysis: NS (non-scoliotic), B (brace), P (preoperative), and M (mild) group, which was split in two sub-groups, M1 (stable) and M2 (progressive), based on patient's final outcome. Differences were studied with Mann-Whitney tests ($\alpha = 0.05$).

A score was defined from a predictive discriminant analysis [27-29], a classification approach used for predictive modelling in machine learning, which is summarized hereafter.

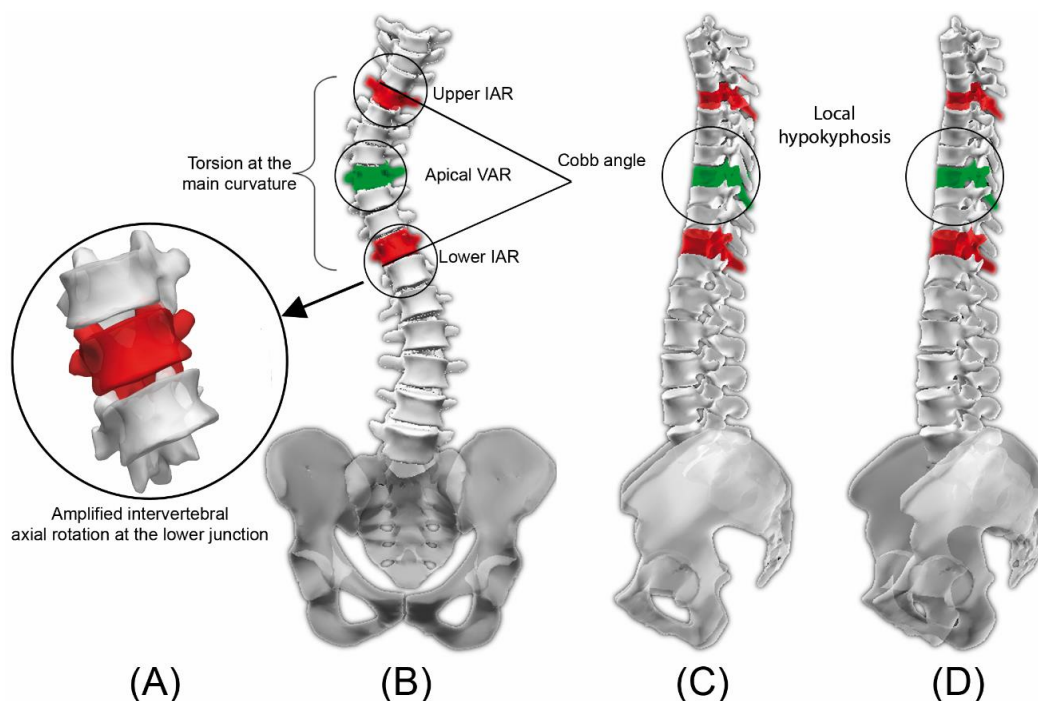


Fig. 2. Deformation phenotype for a severe scoliosis. Amplified axial rotation (A). frontal view (B), sagittal view (C). The local sagittal plane of main curvature, i.e. election plane (D), highlights the local hypokyphosis. Apex is in green while junctional vertebrae are in red. VAR: Vertebral Axial Rotation; IAR: Intervertebral Axial Rotation.

Table 1. Descriptive parameters of the five subject groups: mild scoliosis (M), which was split in stable (M1) and progressive curves (M2), non-scoliotic subjects (NS), brace (B) and pre-operative (P). (IAR: intervertebral axial rotation at junctional levels. VAR: Vertebral axial rotation at apical level. Values are given as average (standard deviation).

Group	Hypokyphosis Index (°)	Torsion (°)	Lower IAR (°)	Upper IAR (°)	Apical VAR (°)	Cobb Angle (°)
M (mild scoliosis)	-1 (-7 ; 8) [SD: 3]	5 (0 ; 11) [SD: 3]	2 (-4 ; 8) [SD: 3]	-3 (-11 ; 6) [SD: 3]	6 (0 ; 19) [SD: 4]	15 (9 ; 20) [SD: 3]
M1 (stable curves)	0 (-5 ; 8) [SD: 3]	4 (0 ; 10) [SD: 2]	1 (-4 ; 6) [SD: 2]	-1 (-10 ; 6) [SD: 3]	5 (0 ; 13) [SD: 4]	14 (9 ; 19) [SD: 3]
M2 (progressive curves)	-2 (-7 ; 3) [SD: 3]	6 (1 ; 11) [SD: 3]	3 (-3 ; 8) [SD: 3]	-4 (-11 ; 1) [SD: 2]	7 (2 ; 19) [SD: 4]	16 (10 ; 20) [SD: 3]
NS (non-scoliotic)	-1 (-13 ; 10) [SD: 4]	0	0 (-7 ; 6) [SD: 3]	1 (-9 ; 8) [SD: 4]	0 (-11 ; 8) [SD: 4]	3 (0 ; 7) [SD: 2]
B (brace)	-3 (-8 ; -1) [SD: 2]	8 (4 ; 16) [SD: 3]	3 (0 ; 9) [SD: 2]	-6 (-15 ; -1) [SD: 3]	9 (1 ; 17) [SD: 5]	28 (20 ; 37) [SD: 5]
P (preoperative scoliosis)	-3 (-14 ; 5) [SD: 4]	15 (7 ; 26) [SD: 5]	6 (2 ; 13) [SD: 3]	-8 (-17 ; -3) [SD: 3]	16 (7 ; 30) [SD: 7]	57 (36 ; 85) [SD: 13]

Each control individual belonging to NS, B or P class is defined via its 6 parameters phenotype. The method first represents the individuals using two descriptors which are linear combinations that minimize intra-class variance and maximize inter-class variance of the 6 original parameters. Then, the same linear combination is applied to the individuals from the M Group and the probability of their belonging to each of the control classes is computed, based on similarity criteria. This probability is used to define a score between 0 and 1, named severity index (S-index). S-index means similarity to progressive curves if ≥ 0.6 , to normal subjects if ≤ 0.4 , and is considered as non-conclusive between 0.4 and 0.6.

Evaluation of the S-Index

For each patient at the first exam, S-index was automatically calculated from 3D reconstruction, by an independent observer that did not pertain to the medical teams and did not know the patients evolution. The associated early prediction (negative for S-index ≤ 0.4 or positive for S-index ≥ 0.6) was kept blind to clinicians until they assessed the outcome after complete follow-up, either negative (i.e. stable at the end of growth) or positive (i.e. brace decision). The confusion matrix was built with the number of true negatives, false negatives, true positives and false negatives. Sensitivity is the rate of true positive versus total number of positive outcomes, i.e. the percentage of progressive that were identified as such. Specificity is the rate of true negative versus total number of negative outcomes, i.e.

percentage of stable that were correctly identified as such [30]. The overall accuracy was defined as the ratio of true predictions/global number of M subjects.

Results

Table 1 shows the values of the descriptive parameters for the whole population and for mild AIS subgroups, M1 (stable, n = 26, mean age: 12 years at first exam, range 7-15) and M2: (progressive, n = 39, mean age: 12 years at first exam, range 8-14). When comparing M1 (stable) to M2 (progressive) groups, all parameters but hypokyphosis index and VAR presented significant differences ($p < 0.05$), albeit relatively small.

A specific 3D deformation phenotype was observed for Brace and Preoperative groups, as illustrated for the patient in Figure 3 (double curvature, Cobb angle 49° in main thoracic curve). Maximum VAR is at the apex (T7) and maximum IARs are at the upper and lower junctions. Torsion index is 16° , and local lordosis at the apex is 2° instead of a mean 5° kyphosis at the same level for non-scoliosis patients.

As for classification based on 3D phenotype of the Mild group, S-index calculated at first exam was found in agreement with the clinical outcome for 53 patients out of 65 (82% overall accuracy). 21

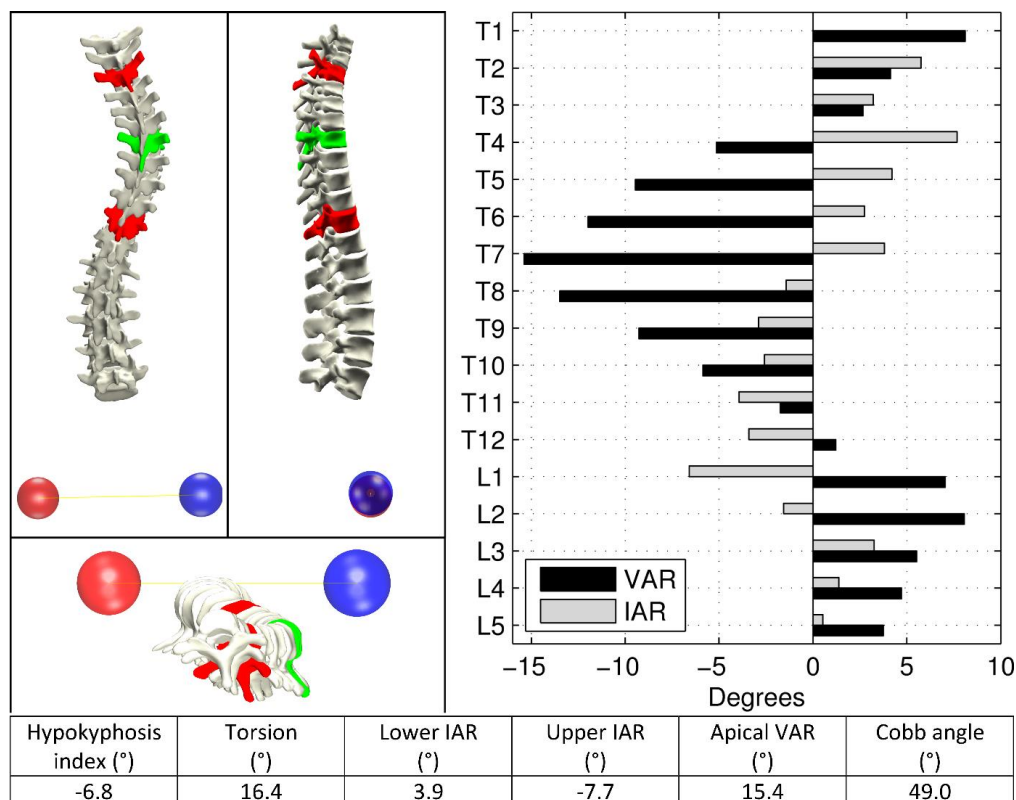


Fig. 3. 3D reconstruction of a typical severe scoliosis (T3 - T7 - T11, apex is in green while junctional vertebrae in red; posterior, lateral and top views) and graphs of corresponding vertebral axial rotation (VAR) and intervertebral axial rotation (IAR). Axial rotation is maximal at the apex while intervertebral rotations are maximal near the junctions.

patients out of 26 from M1 group (non-progressive) had an initial S-index ≤ 0.4 while 32 patients out of 39 of the M2 group (progressive) had an initial S-index ≥ 0.6 . Four patients (one from M1 and three from M2 groups) had a non-conclusive S-index, between 0.4 and 0.6. Confusion matrix (Table 2) indicates a sensitivity of 89 % and a specificity of 84%. In other words 89 % of the curves that were predicted as progressive at the first exam proved accurate.

Discussion

Early detection of progressive AIS patients would allow early management which could improve patient's outcome [3]. A previous numerical study suggested that a specific deformity could appear very early for progressive curves [18]. The current study investigated whether quantitative phenotype description could yield a predictive biomarker called Severity index.

While Cobb angle is widely used for diagnosis and decision making, its limitations have been widely described, particularly in relation with the projection bias on the frontal plane, due to the three dimensional nature of scoliosis deformity. Horizontal plane parameters, such as vertebral axial rotation at the apex (VAR), torsion or intervertebral axial rotation have been shown as other important parameters [31, 32]. 3D reconstruction from routine biplanar X-Rays allowing for automatic quantitative phenotyping of severe scoliosis was a first essential step that revealed characteristic 3D features of the main curve, consistently with qualitative clinical observations. As described by Perdriolle [20], a specific Intervertebral Axial Rotation (IAR) was found at the upper junction, and also at the lower junction. High torsion index confirmed that there is a continuous intervertebral rotation within in the curve from the junctions to the apical vertebra [18]. Also hypokyphosis at the apical level [1], was found consistent with the hypothesis of a posteroanterior asymmetric growth in scoliosis [33]. Indeed, in addition to Cobb angle, other 3D features characterize the scoliosis deformity. However, even if there is a significant difference between non progressive (M1) and progressive (M2) curves as regards most of the parameters, none of them alone is sufficient for reliable discrimination between progressive and non-progressive curves, while the combination of all yielded a more discriminant deformity pattern. The associated hypokyphosis phenomena was slight at the early stage, but it contributed to increase the overall accuracy of the S index.

Patient presented in Figure 4 had a typical progressive phenotype: at the first exam, Cobb angle was

Table 2. Confusion matrix of the severity index (S-index) prediction

	Severity index < 0.4	0.4 < Severity index < 0.6	Severity index > 0.6
Stable scoliosis (N=26)	21 (81 %)	1 (4 %)	4 (15 %)
Progressive scoliosis (N=39)	4 (10 %)	3 (8 %)	32 (82 %)

only 13°, but apical rotation, torsion index, lower and upper IAR were respectively 10°, 9°, 3° and -6°, resulting in a S-index of 0.9, which was found consistent with the real clinical outcome 20 months later.

In progressive curves, horizontal plane parameters show two phenomena: a continuous torsion within the curve and a discontinuity at the junctions. Torsion and IAR at junctions may be related to alteration of the connective soft tissues, particularly the intervertebral disc. Yu *et al.* [34] reported that the annulus of normal discs consists of an abundant and highly organized fibre network while in discs of patients undergoing surgery for scoliosis, elastic fibers were sparse, and the collagen and elastic fiber networks were disorganized with loss of lamellar structure. Therefore mechanical cascade of curve progression could be the result of early disc disease, which origin remains to find, that would yield intervertebral axial rotation resulting in local instability and vicious circle of deformity increase. Recent progress related to in vivo characterization of intervertebral discs [35, 36], could help in future quantitative disc analysis to progress towards understanding its possible alteration.

This preliminary study has several limitations: the first one lies in objective definition of progressive spine. Brace decision was considered, since the clinical teams were fully familiar with scoliosis:

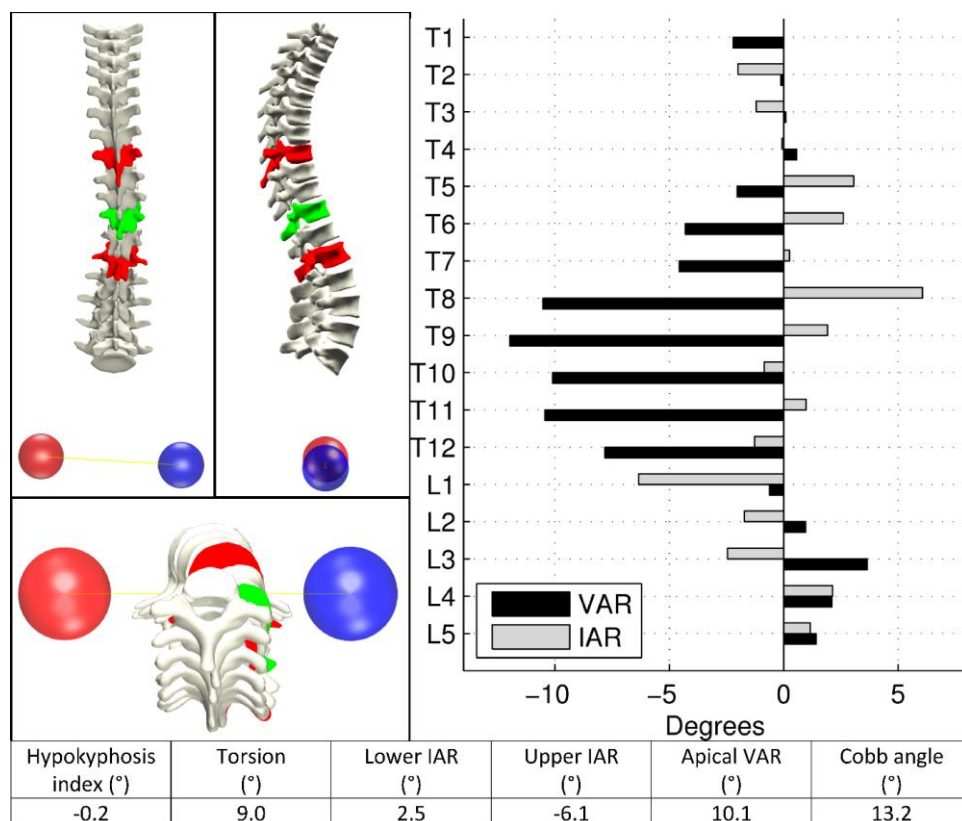


Fig. 4. 3D reconstruction of a typical progressive (T8 – T11 – L1, Cobb angle 13°, apex is in green while junctional vertebrae in red; posterior, lateral and top views) and graphs of corresponding vertebral axial rotation (VAR) and intervertebral axial rotation (IAR). Axial rotation is maximal near the apex while intervertebral rotations are maximal near the junctions.

decision was based on 6 months progression of one or several criteria such as + 5° Cobb angle and/or + 5° VAR, together with worsening of the sagittal profile, with a reduction of the thoracic kyphosis, or clinical observation of an imbalance . As the brace decision still has some subjective non formalized issues, an expert surgeon (last author) blindly validated the brace decision for each patient to consider the curve as progressive.

Another limitation is the requirement of strict acquisition patient positioning. As this index is very sensitive to rotations, any position in which the trunk is artificially twisted, resulting for example from asymmetric positioning of the arms may have a strong effect on the S-Index. Also, two fully trained operators performed all the 3D reconstructions, in order to avoid potential effect of 3D reconstruction errors since the focus of the current study is on the validity of this index; both were blinded to the patients' outcome. Work is in progress to determine intra and interobserver reproducibility assessment to check the robustness of the S index, together with improvement of the reconstruction method to reduce manual operation.

Another limitation is related to the limited number of patients, due to the long follow-up time while biplanar X-Ray technology is quite recent in routine clinical environment. Moreover as some patients were lost this is not a consecutive serie. Because of the limited number of patients, various AIS topologies were considered, since a previous study did not show evidence of the topology effect on patients clustering regarding the horizontal plane parameters [31]. Further large scale studies could

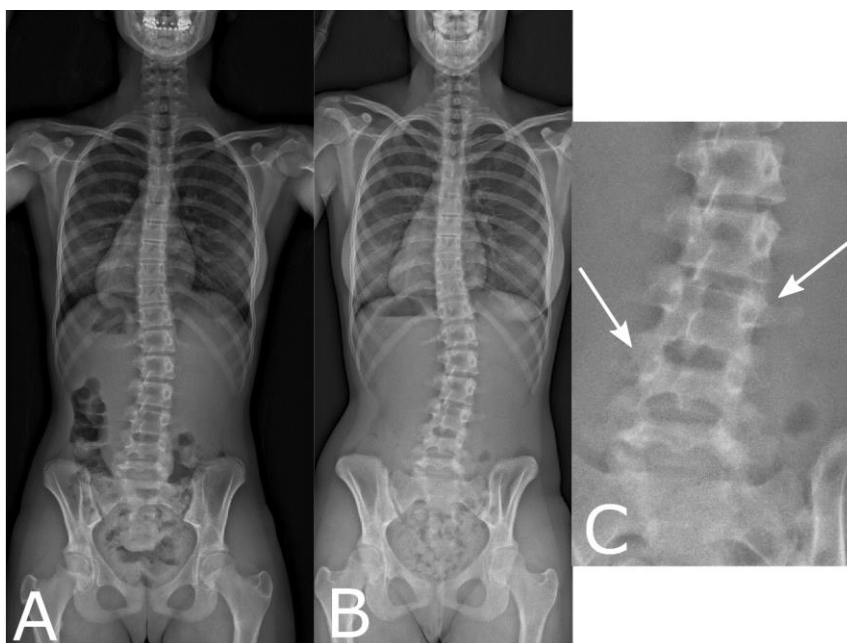


Fig. 5. This patient showed a Cobb angle of 17° at her first exam (A). When she reached Risser 4 (B) without a brace decision, her Cobb angle was only 23°. However, her waist crease and frontal imbalance increased. Moreover, the L3 vertebra (C) shows a lateral asymmetry of the upper and lower intervertebral vertebral space, which could be the initiation of future rotatory dislocation

Table 3. Clinical parameters of misclassified patients.

Hypokyphosis Index (°)	Torsion (°)	Lower IAR (°)	Upper IAR (°)	Apical VAR (°)	Cobb Angle (°)	Clinical Outcome
-5.1	8.8	4.2	2.3	12.6	17.4	Stable (false positives)
-0.6	4.0	3.7	-3.9	10.9	15.5	
-0.9	9.8	6.4	-9.7	11.3	17.4	
-2.2	6.0	3.6	-3.4	10.3	13.7	
0.2	1.4	0.5	-0.6	7.5	11.7	Progressive (false negatives)
1.5	2.7	-1.5	-1.2	6.2	10.2	
0.2	2.3	-0.9	1.1	4.5	10.9	
0.0	1.6	-2.9	1.0	7.2	11.0	

include adjustment of the S-index calculation according to the spine topology, would such adjustment appear relevant.

Despite these limitations, we found that 53 out of 65 patients were accurately classified using this S-index and, what is even more important, that 89% of the patients that were predicted as progressive indeed progressed. Therefore, this S-Index appears promising and constitutes a rationale for a larger scale prospective validation study.

Out of the four patients that presented an inconclusive S-index (between 0.4 and 0.6), three were progressive; this might indicate that it is safer to continue monitoring such patients. Eight patients out of 65 (12.5%) were misclassified: the four false negative cases (Table 3) had small Cobb angles (10-12°) and low IARS and torsions. It is possible that the classification would have been correct at their second visit, when their curves had slightly increased. Four false positive cases presented high apical axial rotation (between 10 and 13°, Table 3), torsion indices (4 - 10°) and IARs (2.3 - 10° in absolute values) at their first visit, which explains why they were classified as similar to progressive scoliosis although they were stable. Two of them will be detailed: one was 14 years old female, with a Risser 1, curvature T4-T8-T11, Cobb angle 17.5, AVR 12.6, torsion 9°, yielding a severity index of 0,91. However, this patient represent a very specific case where the side of torsion was not in the sign of concavity, which may be different from the classically described structural scoliosis. A greater number of patients in the database could help taking into account such very specific deformities and improve the severity index.

The second had a Cobb angle of 17° at the first exam (Figure 5A). S-index was 0.91 while the patient reached Risser 4 without a brace decision, with a Cobb angle of 23°. However, Figure 5B shows that both waist crease and frontal imbalance increased. Moreover, the zoom on the L3 vertebra shows lateral asymmetry of the upper and lower intervertebral space, which could be the initiation of future rotatory dislocation. Even if the Cobb angle is moderate, the longitudinal follow up of this patient could be useful to clarify the criteria defining progressive vs non progressive scoliosis.

Indeed treatment decision criteria are still to improve, either for bracing or not. Weinstein et al. [37] found that in a population of patients which were assigned brace treatment and refused it, 48% did not progress to surgery. This suggests possible unnecessary bracing for some patients, and the S-index, once fully validated, could support treatment decision with more objective data.

Conclusion

The main finding of the study is that in progressive AIS, a specific 3D deformity phenotype appears at early stage, scored using an S-index as a predictor. For 65 mild AIS at the first exam, 82% of predictions were consistent with clinical outcome, and 89% of the patients that were predicted progressive at the first exam progressed and required bracing. Even if the limited number of patients does not allow drawing definite conclusions, it seems that an S-index greater than 0.6 indicates a strong presumption of progressivity. Once confirmed on a larger population, the severity index could be a relevant biomarker to improve diagnosis and decision making at an early stage.

Acknowledgments

The “Fondation Yves Cotrel pour la recherche en pathologie rachidienne” and the other partners of the ParisTech BiomecAM chair program on subject-specific musculoskeletal modelling (ParisTech Foundation, Société Générale, Proteor and Covea) funds were received in support of this work.

References

1. Dickson RA, Lawton JO, Archer IA, Butt WP (1984) The pathogenesis of idiopathic scoliosis. Biplanar spinal asymmetry. *J Bone Joint Surg Br* 66:8-15
2. Poncet P, Dansereau J, Labelle H (2001) Geometric torsion in idiopathic scoliosis: three-dimensional analysis and proposal for a new classification. *Spine* 26:2235-2243
3. Duval-Beaupere G (1982) [Surveillance, course, and prognosis of scoliosis]. *Rev Prat* 32:3261-3264, 3269-3271
4. Duval-Beaupere G (1996) Threshold values for supine and standing Cobb angles and rib hump measurements: prognostic factors for scoliosis. *Eur Spine J* 5:79-84
5. Kouwenhoven JW, Castelein RM (2008) The pathogenesis of adolescent idiopathic scoliosis: review of the literature. *Spine* 33:2898-2908. doi: 10.1097/BRS.0b013e3181891751
6. Veldhuizen AG, Wever DJ, Webb PJ (2000) The aetiology of idiopathic scoliosis: biomechanical and neuromuscular factors. *Eur Spine J* 9:178-184
7. Duval-Beaupere G (1970) [Maturation indices in the surveillance of scoliosis]. *Rev Chir Orthop Reparatrice Appar Mot* 56:59-76
8. Bunnell WP (1986) The Natural History of Idiopathic Scoliosis Before Skeletal Maturity. *Spine* 11:773-776
9. Perdriolle R, Vidal J (1985) Thoracic idiopathic scoliosis curve evolution and prognosis. *Spine* 10:785-791

10. Kohashi Y, Oga M, Sugioka Y (1996) A New Method Using Top Views of the Spine to Predict the Progression of Curves in Idiopathic Scoliosis During Growth. *Spine* 21:212-217
11. Lonstein JE, Carlson JM (1984) The prediction of curve progression in untreated idiopathic scoliosis during growth. *J Bone Joint Surg Am* 66:1061-1071
12. Peterson LE, Nachemson AL (1995) Prediction of progression of the curve in girls who have adolescent idiopathic scoliosis of moderate severity. Logistic regression analysis based on data from The Brace Study of the Scoliosis Research Society. *J Bone Joint Surg Am* 77:823-827
13. Sapkas G, Papagelopoulos PJ, Kateros K, Koundis GL, Boscainos PJ, Koukou UI, Katonis P (2003) Prediction of Cobb angle in idiopathic adolescent scoliosis. *Clin Orthop Relat Res*:32-39. doi: 10.1097/01.blo.0000068360.47147.30
14. Yamauchi Y, Yamaguchi T, Asaka Y (1988) Prediction of curve progression in idiopathic scoliosis based on initial roentgenograms. A proposal of an equation. *Spine* 13:1258-1261
15. Drevelle X, Lafon Y, Ebermeyer E, Courtois I, Dubousset J, Skalli W (2010) Analysis of Idiopathic Scoliosis Progression by Using Numerical Simulation. *Spine* 35:E407-E412
16. Dubousset J, Charpak G, Dorion I, Skalli W, Lavaste F, Deguise J, Kalifa G, Ferey S (2005) [A new 2D and 3D imaging approach to musculoskeletal physiology and pathology with low-dose radiation and the standing position: the EOS system]. *Bulletin de l'Academie nationale de medecine* 189:287-297; discussion 297-300
17. Dubousset J, Charpak G, Skalli W, de Guise J, Kalifa G, Wicart P (2008) [Skeletal and spinal imaging with EOS system]. *Archives de pediatrie : organe officiel de la Societe francaise de pediatrie* 15:665-666. doi: 10.1016/S0929-693X(08)71868-2
18. Dubousset J (1994) Three-dimensional Analysis of the Scoliotic Deformity. In: Weinstein SL (ed) *The Pediatric Spine: Principles and Practice*. Raven Press Ltd, New York.
19. Dubousset J (1999) [Idiopathic scoliosis. Definition--pathology--classification--etiology]. *Bulletin de l'Academie nationale de medecine* 183:699-704
20. Perdriolle R, Vidal J (1981) [A study of scoliotic curve. The importance of extension and vertebral rotation (author's transl)]. *Rev Chir Orthop Reparatrice Appar Mot* 67:25-34
21. Dumas R, Mitton D, Laporte S, Dubousset J, Steib JP, Lavaste F, Skalli W (2003) Explicit calibration method and specific device designed for stereoradiography. *J Biomech* 36:827-834
22. Faro FD, Marks MC, Pawelek J, Newton PO (2004) Evaluation of a functional position for lateral radiograph acquisition in adolescent idiopathic scoliosis. *Spine* 29:2284-2289
23. Humbert L, De Guise JA, Aubert B, Godbout B, Skalli W (2009) 3D reconstruction of the spine from biplanar X-rays using parametric models based on transversal and longitudinal inferences. *Med Eng Phys* 31:681-687. doi: 10.1016/j.medengphy.2009.01.003
24. Stokes IA (1994) Three-dimensional terminology of spinal deformity. A report presented to the Scoliosis Research Society by the Scoliosis Research Society Working Group on 3-D terminology of spinal deformity. *Spine* 19:236-248
25. Cobb JR (1960) The Problem of the Primary Curve. *J Bone Joint Surg Am* 42:1413-1425
26. Steib JP, Dumas R, Mitton D, Skalli W (2004) Surgical correction of scoliosis by in situ contouring: a detorsion analysis. *Spine* 29:193-199. doi: 10.1097/01.BRS.0000107233.99835.A4
27. Fisher RA (1936) The use of multiple measurements in taxonomic problems. *Annals of Eugenics* 7:179-188. doi: 10.1111/j.1469-1809.1936.tb02137.x

28. Mahalanobis PC (1936) On the generalised distance in statistics. In: Proceedings of the National Institute of Sciences of India. pp. 49-55.
29. Venables WN, Ripley BD (2002) Modern Applied Statistics with S. Springer
30. Altman DG, Bland JM (1994) Diagnostic tests. 1: Sensitivity and specificity. *BMJ* 308:1552
31. Courvoisier A, Drevelle X, Dubousset J, Skalli W (2013) Transverse plane 3D analysis of mild scoliosis. *Eur Spine J* 22:2427-2432. doi: 10.1007/s00586-013-2862-x
32. Nault M-L, Mac-Thiong J-M, Roy-Beaudry M, deGuise J, Labelle H, Parent S (2013) Three-dimensional Spine Parameters Can Differentiate Between Progressive and Nonprogressive Patients With AIS at the Initial Visit: A Retrospective Analysis. *Journal of Pediatric Orthopaedics* 33:618-623. doi: 10.1097/BPO.0b013e318292462a
33. Cheng JC, Castelein RM, Chu WC, Danielsson AJ, Dobbs MB, Grivas TB, Gurnett CA, Luk KD, Moreau A, Newton PO, Stokes IA, Weinstein SL, Burwell RG (2015) Adolescent idiopathic scoliosis. *Nature Reviews Disease Primers* 1:15068. doi: 10.1038/nrdp.2015.68
34. Yu J, Fairbank JC, Roberts S, Urban JP (2005) The elastic fiber network of the annulus fibrosus of the normal and scoliotic human intervertebral disc. *Spine* 30:1815-1820
35. Vergari C, Dubois G, Vialle R, Gennisson JL, Tanter M, Dubousset J, Rouch P, Skalli W (2016) Lumbar annulus fibrosus biomechanical characterization in healthy children by ultrasound shear wave elastography. *Eur Radiol* 26:1213-1217. doi: 10.1007/s00330-015-3911-0
36. Zhang Z, Chan Q, Anthony M-P, Samartzis D, Cheung KMC, Khong P-L, Kim M (2012) Age-related diffusion patterns in human lumbar intervertebral discs: a pilot study in asymptomatic subjects. *Magnetic Resonance Imaging* 30:181-188. doi: <http://dx.doi.org/10.1016/j.mri.2011.09.021>
37. Weinstein SL, Dolan LA, Wright JG, Dobbs MB (2013) Effects of Bracing in Adolescents with Idiopathic Scoliosis. *New Engl J Med* 369:1512-1521. doi: doi:10.1056/NEJMoa1307337