



HAL
open science

Preliminary clinical study to evaluate an interactive system to segment organs at risk in thoracic oncology on CT

Jose Dolz, H A Kirisli, T Fechter, S Karnitzki, U Nestle, M Vermandel, L Massoptier

► To cite this version:

Jose Dolz, H A Kirisli, T Fechter, S Karnitzki, U Nestle, et al.. Preliminary clinical study to evaluate an interactive system to segment organs at risk in thoracic oncology on CT. Radiotherapy and Oncology, Apr 2016, Turin, Italy. pp.S451-S452. hal-01462044

HAL Id: hal-01462044

<https://hal.science/hal-01462044>

Submitted on 8 Feb 2017

HAL is a multi-disciplinary open access archive for the deposit and dissemination of scientific research documents, whether they are published or not. The documents may come from teaching and research institutions in France or abroad, or from public or private research centers.

L'archive ouverte pluridisciplinaire **HAL**, est destinée au dépôt et à la diffusion de documents scientifiques de niveau recherche, publiés ou non, émanant des établissements d'enseignement et de recherche français ou étrangers, des laboratoires publics ou privés.

Preliminary clinical study to evaluate an interactive system to segment organs at risk in thoracic oncology on CT.

J. Dolz*

AQUILAB, Loos-les-Lille, France. and

5 *Univ. Lille, Inserm, CHU Lille, U1189 - ONCO-THAI - Image Assisted Laser Therapy for Oncology, F-59000 Lille, France*

H.A. Kirişli

AQUILAB, Loos-les-Lille, France.

T. Fechter, S. Karnitzki, and U. Nestle

Department of Radiation Oncology, University Medical Center, Freiburg, Germany.

M. Vermandel

10 *Univ. Lille, Inserm, CHU Lille, U1189 - ONCO-THAI - Image Assisted Laser Therapy for Oncology, F-59000 Lille, France.*

L. Massoptier

AQUILAB, Loos-les-Lille, France

15 **Purpose:** Radiotherapy aims at delivering the highest possible dose to the tumor while minimizing the irradiation of surrounding healthy tissue, and especially to the organs at risk (OARs). Therefore, accurate delineation of OARs is required for radiation treatment planning (RTP). In thoracic oncology, delineation of some OARs remains manual, making the task time consuming and prone to inter observer variability. Various (semi-) automatic approaches have been proposed to segment OARs on CT but the task still remains challenging. Here, a system to interactively segment OARs in thoracic oncology on CT images is presented and its clinical acceptability
20 evaluated.

25 **Methods:** The proposed framework has been implemented using MITK platform. User interaction lies in the easy definition of few manual seeds for the OARs and background using a 'paintbrush' tool, which can be interactively added in any view (axial, sagittal or coronal), and is subsequently propagated within the whole volume. Once the user is content with the seeds placement, the system automatically performs the segmentation. If the outcome is not satisfying, the user can modify the seeds, which involves adding and/or removing existing seeds, and perform again the automatic segmentation. Number of tries has been limited to five in the current study. If after the five modifications the segmentation result is not sufficient to be usable in the RTP, the user shall reject it; otherwise, he shall accept it. A hybrid approach based on our previous work [1, 2] which combines watershed transformation and graph cuts [3] is used for the segmentation task.

30 **Results:** The system was evaluated on multivendor CT datasets of 10 patients presenting from early stage to locally advanced NSCLC or pulmonary metastases. OARs taken into consideration in this study were: heart, lungs, oesophagus, proximal bronchus tree, spinal canal and trachea. Interactive contours were generated by a physician using the proposed system. Delineation of the OARs obtained with the presented system was approved to be usable for RTP in more than 90% of the cases, excluding the oesophagus, which segmentation was never
35 approved (Fig 1). On the accepted reported cases, more than 90% of the interactive contours reached a Dice Similarity Coefficient higher than 0.7 with respect to manual segmentations (Fig 2). Therefore, our interactive delineation approach allows users to generate contours of sufficient quality to be used in RTP up to three times faster than manually.

40 **Conclusions:** An interactive, accurate and easy-to-use computer-assisted system for OARs segmentation in thoracic oncology was presented and clinically evaluated. The introduction of the proposed approach in clinical routine might offer a valuable new option to radiation therapists (RTTs) in performing OARs delineation task. Consequently, further experiments have been conducted on larger databases and with the participation of additional RTTs to investigate its potential use in daily clinical practice [4].

* jose.dolz.upv@gmail.com

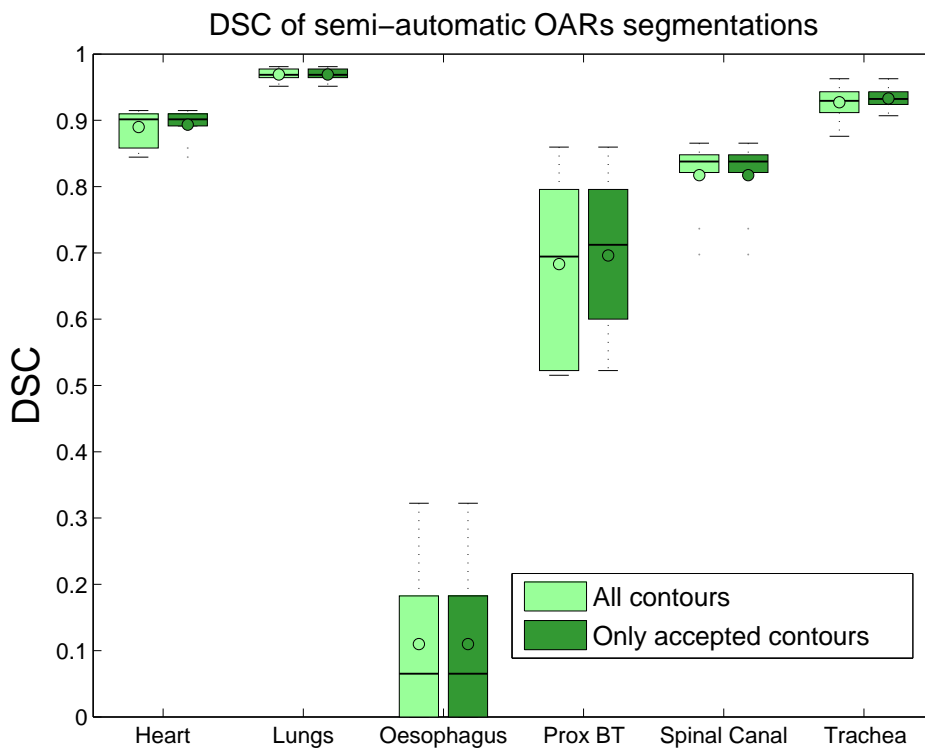


Figure. 1. Dice Similarity Coefficients (DSC) of semi-automatic OARs segmentation.

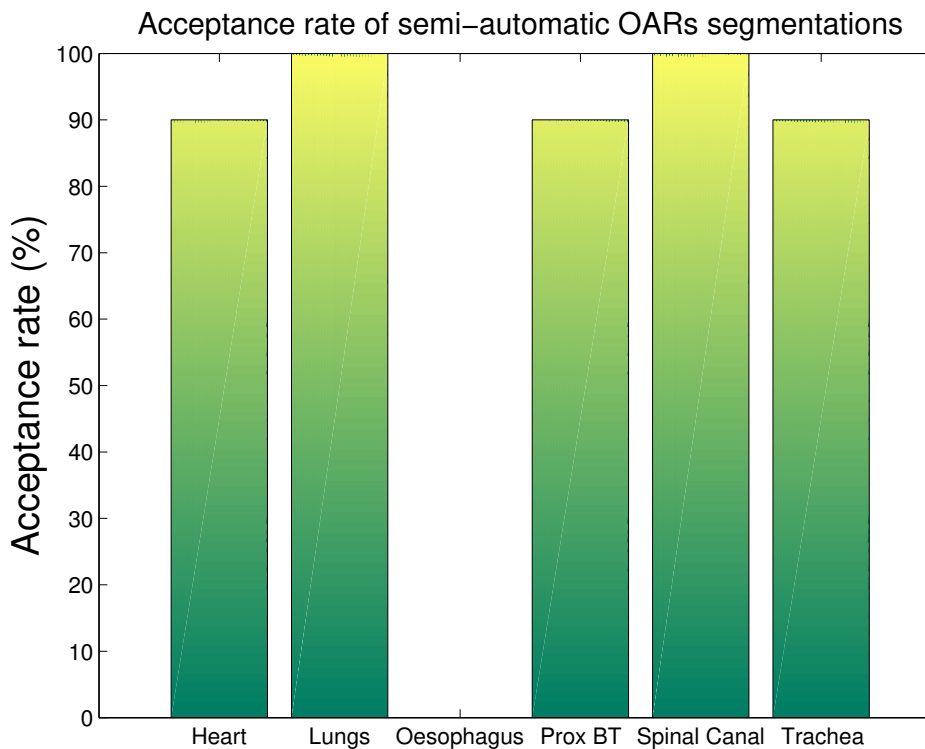


Figure. 2. Acceptance rate for the semi-automatic segmentations

REFERENCES

-
- 45 [1] Jose Dolz, Hortense A Kirişli, Romain Viard, and Laurent Massoptier. Combining watershed and graph cuts methods to segment organs at risk in radiotherapy. In *SPIE Medical Imaging*, pages 90343Z–90343Z. International Society for Optics and Photonics, 2014.
- [2] Jose Dolz, Hortense A Kirişli, Romain Viard, and Laurent Massoptier. Interactive approach to segment organs at risk in radiotherapy treatment planning. In *SPIE Medical Imaging*, pages 90343S–90343S. International Society for Optics and Photonics, 2014.
- 50 [3] Yuri Y Boykov and M-P Jolly. Interactive graph cuts for optimal boundary & region segmentation of objects in nd images. In *Computer Vision, 2001. ICCV 2001. Proceedings. Eighth IEEE International Conference on*, volume 1, pages 105–112. IEEE, 2001.
- [4] Jose Dolz, HA Kirişli, T Fechter, S Karnitzki, O Oehlke, U Nestle, Maximilien Vermandel, and L Massoptier. Interactive contour delineation of organs at risk in radiotherapy: Clinical evaluation on nsclc patients. *Medical physics*, 43(5):2569–2580, 2016.
- 55