



HAL
open science

A three-dimensional deformable brain atlas of the domestic pig

Paul Meurice, Stephan Saikali, Charles-Henri Malbert

► **To cite this version:**

Paul Meurice, Stephan Saikali, Charles-Henri Malbert. A three-dimensional deformable brain atlas of the domestic pig. Farm Animal Imaging Congress, Jun 2010, Rennes, France. hal-01409423

HAL Id: hal-01409423

<https://hal.science/hal-01409423>

Submitted on 4 Jun 2020

HAL is a multi-disciplinary open access archive for the deposit and dissemination of scientific research documents, whether they are published or not. The documents may come from teaching and research institutions in France or abroad, or from public or private research centers.

L'archive ouverte pluridisciplinaire **HAL**, est destinée au dépôt et à la diffusion de documents scientifiques de niveau recherche, publiés ou non, émanant des établissements d'enseignement et de recherche français ou étrangers, des laboratoires publics ou privés.

A three-dimensional deformable brain atlas of the domestic pig

Meurice P., Saikali S., Malbert C.H.

INRA, UMR1079 SENAH, F-35590 St Gilles, France

Context: The domestic pig is used in numerous medical research fields and in particular for human digestive and nutritional physiology (Douglas, 1972; Dodds, 1982; Tumbleson, 1986). The pig's brain is gyrencephalic and has more similarities with the human brain in terms of anatomy and development than the rodent's brain (Lind, 2007).

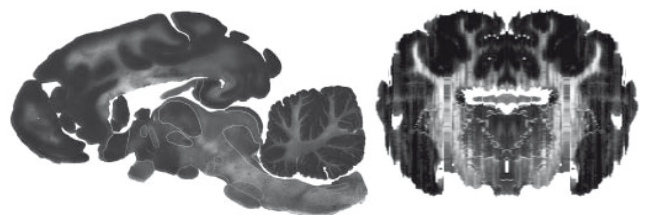
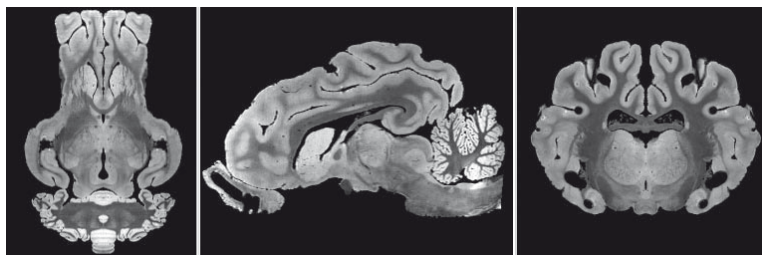
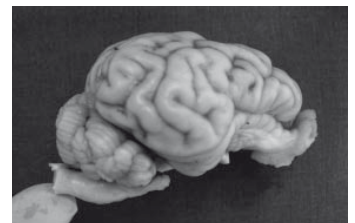Its size facilitates surgical interventions and electrodes insertion, which makes pig an interesting animal model for deep brain stimulation (Sauleau, 2009).

Aim: To build a 3D brain atlas, using histological analysis, high magnetic field MRI and the existing literature.

Material and Methods

A stereotaxic frame ("Ghost") was built from an ex vivo high resolution image of a pig brain acquired with high field (4.7T) MRI facility.

Thirty deep brain structures were identified from sagittal histological slices. The cytoarchitectonic brain mapping was achieved from sagittal and coronal slices. Sagittal sections were coregistered to each other before being aligned with the ghost.



Results

Number of identified structures :

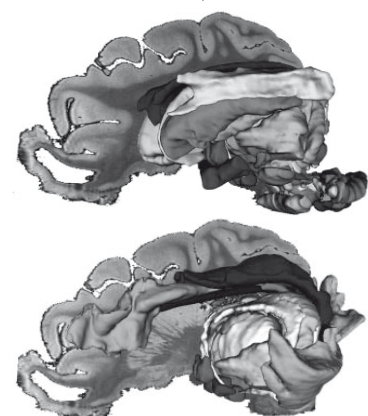
Central structures

Thalamus	9
Striate system	6
Limbic system	4
Subthalamus	2
Epithalamus	2
Hypothalamus	3
Mesencephalon	6
Pons	3
Medulla oblongata	4
Cranial nerves	8
Other (AC,PC,CC,CO)	4

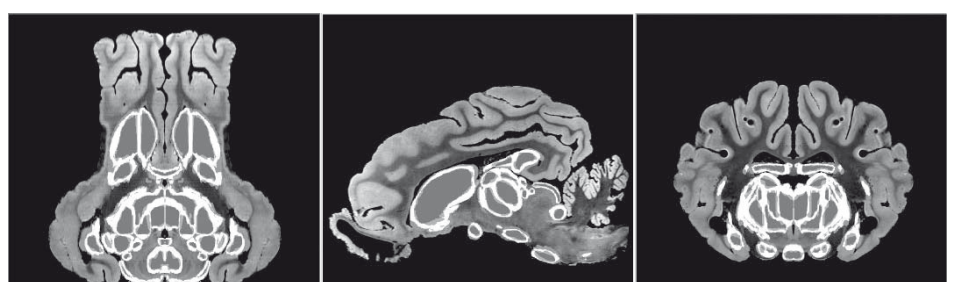
Ventricular system	4
Deep Cerebellar structures	6
Cerebellar lobules	12
Brodmann's area	28

24 of the 101 identified structures were medial.

3D views of the central structures (a) and limbic system (b)



In parallel, a probabilistic atlas of the deep brain structures was developed upon six pig brain hemispheres to estimate the spatial variability of these areas.



Conclusion

Thanks to high resolution MR images and histological slices, we developed a detailed digital, three-dimensional atlas of the domestic pig. This atlas can be used as a standard stereotaxic frame such as the Talairach frame in the human. It can facilitate anatomical identification and automatic segmentation in future brain imaging and surgery studies.