



HAL
open science

Anterior cervical interbody fusion using polyetheretherketone cage filled with synthetic bone graft in acute cervical spine injury

L. Hattou, X. Morandi, J. Lefebvre, P.-J. Le Reste, L. Riffaud, P.-L. Hénaux

► **To cite this version:**

L. Hattou, X. Morandi, J. Lefebvre, P.-J. Le Reste, L. Riffaud, et al.. Anterior cervical interbody fusion using polyetheretherketone cage filled with synthetic bone graft in acute cervical spine injury. *Orthopaedics & Traumatology: Surgery & Research*, 2017, 103 (1), pp.61-66. 10.1016/j.otsr.2016.09.004 . hal-01386881

HAL Id: hal-01386881

<https://hal.science/hal-01386881>

Submitted on 6 Dec 2016

HAL is a multi-disciplinary open access archive for the deposit and dissemination of scientific research documents, whether they are published or not. The documents may come from teaching and research institutions in France or abroad, or from public or private research centers.

L'archive ouverte pluridisciplinaire **HAL**, est destinée au dépôt et à la diffusion de documents scientifiques de niveau recherche, publiés ou non, émanant des établissements d'enseignement et de recherche français ou étrangers, des laboratoires publics ou privés.

Anterior cervical interbody fusion using polyetheretherketone cage filled with synthetic bone graft in acute cervical spine injury

Lotfi Hattou, Xavier Morandi, Jean Lefebvre, Pierre-Jean Le Reste, Laurent Riffaud, Pierre-Louis Hénaux
Department of Neurosurgery, Rennes University Hospital, CHU Pontchaillou, 2 rue Henri Le Guilloux,
35033, Rennes Cedex 9, France.

Corresponding author: Pierre-Louis Hénaux

Department of Neurosurgery, Rennes University Hospital, CHU Pontchaillou,
2, rue Henri le Guilloux
35033 Rennes Cedex 9, France

E-mail : pierrelouis.henaux@chu-rennes.fr

Phone : 33 2 99 28 42 77

Fax : 33 2 99 28 41 80

Abstract

Purpose The aim of this study was to assess the interbody fusion rate for patients treated by anterior cervical interbody fusion (ACIF) using polyetheretherketone (PEEK) cages filled with synthetic bone graft in acute cervical spine injury.

Materials and Methods Twenty-nine patients (mean age: 49 years) with monosegmental instability due to cervical spine injury were followed. We assessed the rate of and time to interbody fusion at one-year follow-up. In case of secondary displacement, we analysed its causes and surgical management.

Results The rate of fusion was 86.2%. The mean time to fusion was 7.2 months. Interbody fusion was observed at 3 months in 4 patients, at 6 months in 14 and at 1 year in 7. Four patients had secondary displacement within 3 months.

Conclusion ACIF with a PEEK cage filled with synthetic bone graft seems to be an alternative to iliac crest bone graft with no morbidity related to the harvest site.

Keywords Cervical Spine, Trauma, Polyetheretherketone, Bone fusion, anterior cervical discectomy and fusion

Introduction

Acute spine injuries are frequent with an incidence of 19.4 cases per million inhabitants in France. It is estimated that there are more than 900 new cases per year (1). In Europe, cervical spine injuries represent 45% of spinal cord injuries (2). The most common causes are road accidents, falls and sports injuries. Subaxial cervical spine injuries affect mostly young patients. In contrast, elderly people have more upper cervical spine injuries (3). Subaxial spinal injuries may cause mechanical instability with bone fractures or disco-ligamentous disruption and can lead to nerve root injury or spinal cord compression (4, 5). The goal of treatment of unstable lesions is restoration of a normal spinal canal and decompression of the spinal cord (6). In case of a fracture with dislocation or translation, reduction is recommended first (7). Treatment is based on external immobilisation, anterior surgery with fusion (8) or posterior arthrodesis (9).

Introduced at the end of the fifties by Cloward, Smith and Robinson (10, 11), anterior cervical interbody fusion (ACIF) using a tricortical bone graft harvested from the iliac crest is often performed with a high rate of interbody fusion (8, 12, 13) in injuries. However, this method leads to harvest-site morbidity such as unsightly scars, infections, haematomas, prolonged pain, nerve injury, higher intraoperative blood loss, and fracture and could impair recovery (14, 15). Fusion with a cage filled with synthetic bone is the most used technique in cervical spondylosis (16, 17, 18, 19). In these cases, polyetheretherketone (PEEK) cages are the most common choice (20, 19, 17). In acute cervical spine injuries, interbody fusion with cages has rarely been reported (15, 21, 22). In these rare reports, cages are filled with autologous bone graft. To our knowledge, no study has reported the use of PEEK cages filled by synthetic bone graft.

The aim of this study was to assess the interbody fusion rate for patients with acute cervical spine injury treated by ACIF using PEEK cages filled with synthetic bone graft.

Materials

Materials

Thirty-four patients suffering from acute cervical spine injury with monosegmental instability were enrolled retrospectively between January 2009 and April 2014 in our study. Mean age at presentation was 52 years (range 19–88 years) with a sex ratio of 1:0.26. We analysed the patients' preoperative neurological status, the type of fracture and the integrity of the disco-ligamentous soft tissue complex on cervical CT scan or/and MRI according to the Subaxial Injury Classification (SLIC) (Table 1) (4). This classification has been validated and is recommended (level I of evidence) for management of cervical spine injury (5). The SLIC system separates fractures according to their morphology in compression, distraction, rotation or translation. We added disc herniation and isolated facet fracture, which were not described specifically in this classification. The mean SLIC score was 5.5 (range 2–10). A score greater or equal to 5 is considered as severe and surgical treatment is recommended in these cases (4). The mean neurological score was 1.4 (range 0–4). Twenty-six patients had a neurological deficit and eight had no deficit. The mean Disco-Ligamentous Complex (DLC) score was 1.8 (range 0–2). The mean morphology score was 2.3 (range 0–4). Fifteen patients had a translation injury (eight biarticular and seven uniarticular) (Fig. 1); eight had an isolated facet fracture; eight had a distraction; four had a disc herniation and one had a vertebral body compression injury. C5-C6 level was the most frequently involved level (n=10), then C6-C7 (n=9), C3-C4 (n=5), C4-C5 (n=5), C7-T1 (n=4) and C2-C3 (n=1). In cases of dislocation, closed reduction was performed first under radioscopic control by pulling gently on the cervical spine with a slight extension. All patients included were treated by an ACIF using a modular PEEK cage filled with synthetic bone graft composed exclusively of hydroxyapatite (LDR medical MC+®) (Fig. 2) combined with an anchoring clip placed into the lower vertebrae for almost of them (Fig. 3). We added an anterior locking plate to strengthen stabilization for all patients. Patients did not have postoperative immobilisation by cervical collar. Patients requiring an open reduction were excluded and had a posterior osteosynthesis. Cases with fracture or deformation of the vertebral body were also excluded because of technical constraints (insufficient height of the cage). The mean duration of surgery was 83 min (range 60–143 min). Concerning the height of PEEK cages, we used 4.5 mm for one patient, 5 mm for seven, 6 mm for 15, 7 mm for 10 and 7.5 mm for the last one. The mean

hospital stay was 10 days (range 4–46 days). Twentytwo patients were discharged home and seven were discharged to a rehabilitation centre. Patients who were discharged home stayed on average 7 days (range 4–13 days), whereas patients discharged to a rehabilitation centre stayed 19 days (range 9–46 days) (Table 2). Five patients died during hospitalisation due to respiratory failure or bedsore complications.

Method

The primary endpoint was defined as the rate of interbody fusion at one year. Interbody fusion was defined by visualisation of trabecular bone bridging across the bone-graft interface and absence of radiolucent gaps between the endplate and graft on anterior and lateral cervical X-rays for all patients and confirmed on a CT scan with a slice thickness of 1 or 1.25 mm for 8 of them. The secondary endpoint was the time to interbody fusion. The rate of interbody fusion was analysed independently by two senior neurosurgeons. Agreement between observers was evaluated using kappa statistics.

In case of default of fusion with secondary displacement, the causes and surgical management were analysed and described.

Results

Results are summarised in [Table 2](#).

Interobserver agreement was determined as excellent ($\kappa=0.88$). After reaching a consensus, the rate of interbody fusion was 86.2% (25 patients among the 29 followed). The mean time to interbody fusion was 7.2 months (range 3–12 months). Interbody fusion was observed at 3 months in 4 patients, at 6 months in 14 and at 1 year in 7 ([Figs. 4 and 5](#)).

Four patients had no interbody fusion and had secondary displacement within 3 months. Case 5 (C6-C7) had an anterior displacement of the cage and the anterior plate at 1.5 month on the X-ray control. He had an isolated neck pain. We decided to perform a complementary surgery by posterior arthrodesis with laminar hooks from C4 to T1 ([Fig. 6](#)). Case 17 (C6-C7) had an antelsthesis of C6 over C7 with a right unilateral dislocation three months after surgery. The patient was asymptomatic. We first applied a closed reduction with 4 kg traction for three days. Then, we performed a posterior arthrodesis with transarticular screws from C5 to C7. Case 20 (C7-T1) had anterior displacement of the cage and the anterior locking plate, leading to bilateral dislocation 3 months after surgery. This patient had a motor deficit being improved. We performed a reduction by 6 kg traction followed by a posterior arthrodesis with transarticular screws from C6 to T1. Case 33 (C4-C5) had a poor reduction with C4-C5 bilateral dislocation. The patient was tetraplegic. An additional posterior arthrodesis was performed one month after surgery with transarticular screws from C3 to C5.

Discussion

ACIF with PEEK cages filled by synthetic bone graft and osteosynthesis with an anterior locking plate seems to be an interesting alternative to autologous bone graft. Fusion rate at one year for monosegmental cervical spine injury is satisfactory. Furthermore this technique makes it possible to avoid iliac crest harvest and its associated complications. Surgical treatment of cervical spine injuries includes anterior, posterior or combined approaches. Currently, this surgical management is a subject of controversy (6). Neither the anterior or the posterior approach has proved superior to the other and both are effective in acute cervical spine injuries (6). In Europe, the anterior approach seems to be the most commonly used (13). We focused on the anterior approach because it allows ventral decompression of the spinal cord under direct visualization and it offers preservation of soft tissue trophicity better than the posterior approach (6, 23). On the other hand, if open reduction of the facet dislocation is required, posterior arthrodesis remains the only alternative (6).

In 1958, Cloward introduced the anterior approach for the management of cervical spine injuries (10). The first studies evaluating this method showed poor outcomes that could be explained by the lack of stability without additional osteosynthesis by anterior plate (11, 24). Nowadays, reported fusion rates are high in cervical spine injuries. Laus et al. treated 20 patients with anterior decompression and interbody fusion with iliac bone grafts and reported a fusion rate of 100% with a mean time of 4.5 months (12). They used additional immobilisation with a Philadelphia cervical collar for 2.5 months after surgery. We did not add cervical immobilisation for our patients because we find it is uncomfortable, especially for elderly people. Kasimatis et al. studied 74 patients: 65 of them had an iliac bone graft and nine had a titanium cage filled with autologous bone graft. They reported a fusion rate of 90.5% (8). Woodworth et al. studied 17 cases treated by a single surgeon with autologous bone graft with a rate of fusion of 88.2% (23). In our study, all the neurosurgical team members performed this surgery in emergency situations. Our rate of fusion was 86.2% and is slightly lower than the rates reported in the literature. The use of an interbody cage in cervical spondylosis is a validated process with a high fusion rate (16, 17, 25). Using a cage decreases the rate of complications, as it does not require iliac harvesting (16). PEEK cages have the following advantages, such as their anatomical shape and their potential gain of height increasing foraminal height space to allow nerve root decompression (25); they are also

radiolucent and facilitate postoperative control to follow fusion (18); they are non-resorbable and have a modulus of elasticity similar to the bone (19).

In cervical spine injuries, Kandziora et al. compared the use of a titanium cage filled with autologous bone graft and additional osteosynthesis with anterior plate to the use of autologous tricortical iliac crest bone grafts (15). They reported no statistically significant difference in terms of clinical and radiological outcomes between these two techniques. However, among the 53 patients, there were complications for 14 of the 53 patients related to iliac crest harvesting. They reported a fusion rate of 76.9% at oneyear follow-up in the cage group. Nevertheless, the time to fusion seemed to be shorter for the iliac crest bone graft group (15). Delepine et al. used a PEEK cage filled with cancellous bone harvested percutaneously from the iliac bone associated with an anterior titanium plate, followed by immobilisation using a cervical collar for 2 to 3 months. They reported a good fusion rate for 26 out of 30 patients (86.7%) (21). Song et al. reported a good fusion rate within 3 months for 54 out of 58 cases (93.1%) treated by anterior fusion with a PEEK cage filled with cancellous bone. They also used postoperative immobilisation with a cervical collar for 6 weeks (22). No study evaluated the use of a cage filled with a synthetic bone graft of hydroxyapatite in the treatment of cervical spine injuries. We did not use any immobilisation after surgery, in contrast to most of the other teams (8, 12, 15, 21, 22). This element of postoperative management should be further studied as it might impact bone fusion.

For the few patients who did not fuse, secondary displacement occurred early, within three months following surgery. In the majority of cases, this complication was related to incomplete reduction prior to arthrodesis. Case 5 (C6-C7) had an anterior displacement of the cage and the anterior locking plate, probably due to a low height cage of 5 mm which could lead to unwanted motion. It might be more appropriate, as far as practicable, to use a higher cage of at least 6 mm. Some authors used heights of 7 or 8 mm (23). For case 17, the primary reduction was also incomplete and despite fusion there was secondary displacement with recurrent translation injury. Case 20 was technically difficult to treat because of a short neck and a diffuse idiopathic skeletal hyperostosis (Forestier Disease). He had secondary displacement with joint attachment without neurological complications. External and open reduction was impossible and he was treated by posterior arthrodesis with transarticular screws. Case 33 had a displacement related to incomplete reduction and an incompletely impacted cage. Also, it appeared that patients with displacement had a higher mean age than the rest of the population of patients in this study. In light of these data, it appears that the fusion failures are related to a default in surgical technique rather than to the use of synthetic

bone grafts: It is therefore important (1) to be certain that complete reduction has occurred before proposing an anterior approach; (2) to perform a good removal of endplates to increase surface fusion; (3) to use a high cage (6–7 mm) centered in the interbody space; (4) to also use an anchoring clip to increase the primary stability of the cage; (5) to add an anterior locking plate; (6) to insert screws in the vertebral body pointing towards the top and bottom. In one case, the anchoring clip was not used (case 23) and yet the fusion was obtained at one year. Even if spinal fusion is probably enhanced by anchoring clip, we think that anterior plate increase mainly the fusion. If there is any doubt in particular about the reduction of the facet joints, the posterior approach should be favoured. Even if quality of fusion is related to severity of the initial lesion, our policy for the most part is to begin with an anterior approach whenever it is possible. Rarely in severe cases, we add a contention by a cervical collar with a further close imaging follow up to detect early displacement. In case of secondary displacement, we perform a complementary posterior approach. Another benefit of anterior arthrodesis with a cage is economic. Indeed, the duration of surgery is reduced. In the end, the financial cost of a cage seems to be less expensive than the cost associated with donor site complications, which generally increase hospital stay (15, 21).

The limitations of our study were its small sample size, its single neurological centre setting and its retrospective nature. The heterogeneity of the surgeons' experience levels skews the outcome. There was also a bias related to the different vertebral levels injured. Indeed, it seems more difficult to operate a patient on C2-C3 segment because of the mandible obstructing approach, or a less accessible C7-T1 segment. Finally, our population was not homogeneous in terms of age, type of injury, neurological status and comorbidities.

Another limitation of our study is the method to assess spinal fusion. There is no widely-used classification for the cervical interbody fusion in the literature. Spinal fusion and diagnosis of pseudarthrosis require an association of clinical arguments and various imaging modalities. In this way, evaluate fusion rate using static x-rays is debatable. Dynamic x-rays, even if not systematically performed in routine, could be useful to evaluate fusion. It may help surgeons to diagnose a pseudarthrosis when excessive movement is observed. Nonetheless, lack of movement in a fused segment does not confirm fusion. Indeed, the instrumentation decreases motion and may overestimate spinal fusion. We can also use Thin slice CT scan which is more sensitive than x-rays and which remains the best non invasive modality of spinal fusion assessment (26).

Conclusion

ACIF with PEEK cages filled with synthetic bone seems to be an alternative to iliac crest bone grafts in acute cervical spine injury. This technique has the advantage of simplifying the surgery with a shorter duration of the procedure and of avoiding postoperative morbidity related to iliac harvesting. However, it is a preliminary study and it is necessary to conduct a prospective comparative study on a larger scale to confirm the interest of the PEEK cage and synthetic bone in cervical traumatic surgery.

References

1. Lee BB, Cripps RA, Fitzharris M, Wing PC The global map for traumatic spinal cord injury epidemiology: update 2011, global incidence rate. *Spinal Cord* 2014 ; 52:110–116.
2. Hasler RM, Exadaktylos AK, Bouamra O, Benneker LM, Clancy M, Sieber R et al. Epidemiology and predictors of spinal injury in adult major trauma patients: European cohort study. *Eur Spine J* 2011; 20:2174-2180.
3. Lieberman IH, Webb JK. Cervical spine injuries in the elderly. *J Bone Joint Surg Br* 1994; 76:877-881.
4. Vaccaro AR, Hulbert RJ, Patel AA, Fisher C, Dvorak M, Lehman RA et al. The subaxial cervical spine injury classification system: a novel approach to recognize the importance of morphology, neurology, and integrity of the disco-ligamentous complex. *Spine* 2007; 32:2365-2374.
5. Aarabi B, Walters BC, Dhali SS, Gelb DE, Hurlbert RJ, Rozelle CJ et al. Subaxial cervical spine injury classification systems. *Neurosurgery* 2013; 3:170-185.
6. Gelb DE, Aarabi B, Dhali SS, Hurlbert RJ, Rozelle CJ, Ryken TC et al. Treatment of subaxial cervical spinal injuries. *Neurosurgery* 2013 ; 3:187-192.
7. Hadley MN, Walters BC. Introduction to the guidelines for the management of acute cervical spine and spinal cord injuries. *Neurosurgery* 2013; 3:5-16.
8. Kasimatis GB, Panagiotopoulos E, Gliatis J, Tyllianakis M, Zouboulis P, Lambiris E. Complications of anterior surgery in cervical spine trauma : an overview. *Clin Neurol Neurosurg* 2009; 111:18-27.
9. Yukawa Y, Kato F, Ito K et al. Placement and complications of cervical pedicle screws in 144 cervical trauma patients using pedicle axis view techniques by fluoroscope. *Eur Spine J* 2009; 18:1293-1299.
10. Cloward RB. The anterior approach for removal of ruptured cervical disc. *J Neurosurg* 1958; 15:602-617.
11. Smith GW, Robinson RA. The treatment of certain cervical-spine disorders by anterior removal of the intervertebral disc and interbody fusion. *J Bone Joint Surg Am* 1958; 40:607-24.
12. Laus M, Pignatti G, Tigani D, Alfonso C, Giunti A. Anterior decompression and plate fixation in fracture dislocations of the lower cervical spine. *Eur Spine J* 1993 ; 2:82-88.
13. Lee SH, Sung JK. Unilateral lateral mass-facet fractures with rotational instability: new classification and a review of 39 cases treated conservatively and with single segment anterior fusion. *J Trauma* 2009; 66:758-767.
14. Dimitriou R, Mataliotakis GI, Angoules AG, Kanakaris NK, Giannoudis PV. Complications following autologous bone graft harvesting from the iliac crest and using the RIA: a systematic review. *Injury* 2011; 42:S3-15.
15. Kandziora F, Pflugmacher R, Scholz M, Schnake K, Putzier M, Khodadadyan-Klostermann C, et al. Treatment of traumatic cervical spine instability with

- interbody fusion cages: a prospective controlled study with a 2-year follow-up. *Injury* 2005; 36 Suppl 2:B27-35.
16. Jacobs W, Willems PC, Kruyt M, van Limbeek J, Anderson PG, Pavlov P et al. Systematic review of anterior interbody fusion techniques for single- and double level cervical degenerative disc disease. *Spine* 2011; 36:E950-960.
 17. Cho DY, Lee WY, Sheu PC, Chen CC. Cage containing a biphasic calcium phosphate ceramic (Triosite) for the treatment of cervical spondylosis. *Surg Neurol* 2005; 63:497-503.
 18. Cho DY, Liao WR, Lee WY, Liu JT, Chiu CL, Sheu PC. Preliminary experience using a polyetheretherketone (PEEK) cage in the treatment of cervical disc disease. *Neurosurgery* 2002; 51:1343-1349.
 19. Boakye M, Mummaneni PV, Garrett M, Rodts G, Haid R. Anterior cervical discectomy and fusion involving a polyetheretherketone spacer and bone morphogenetic protein. *J Neurosurg Spine* 2005; 2:521-525.
 20. Hee HT, Kundnani V. Rationale for use of polyetheretherketone polymer interbody cage device in cervical spine surgery. *Spine J* 2010; 10:66-69.
 21. Delepine F, Jund S, Schlatterer B, de Peretti F. Experience with Poly Ether Ether Ketone (PEEK) cages and locking plate for anterior cervical fusion in the treatment of spine trauma without cord injury. *Rev Chir Orthop Reparatrice Appar Mot* 2007; 93:789-797.
 22. Song KJ, Choi BW, Kim GH, Song JH. Usefulness of polyetheretherketone (PEEK) cage with plate augmentation for anterior arthrodesis in traumatic cervical spine injury. *Spine J* 2010; 10: 50-57.
 23. Woodworth RS, Molinari WJ, Brandenstein D, Gruhn W, Molinari RW. Anterior cervical discectomy and fusion with structural allograft and plates for the treatment of unstable posterior cervical spine injuries. *J Neurosurg Spine* 2009; 10: 93-101.
 24. Cloward RB. Treatment of acute fractures and fracture-dislocations of the cervical spine by vertebral-body fusion. A report of eleven cases. *J Neurosurg* 1961; 18: 201-209.
 25. Celik SE, Kara A, Celik S. A comparison of changes over time in cervical foraminal height after tricortical iliac graft or polyetheretherketone cage placement following anterior discectomy. *J Neurosurg Spine* 2007; 6:10-16.
 26. Gruskay JA, Webb ML, Grauer JN. Methods of evaluating lumbar and cervical fusion. *Spine J* 2014 ; 14 : 531- 539.

Conflict of interest

None.

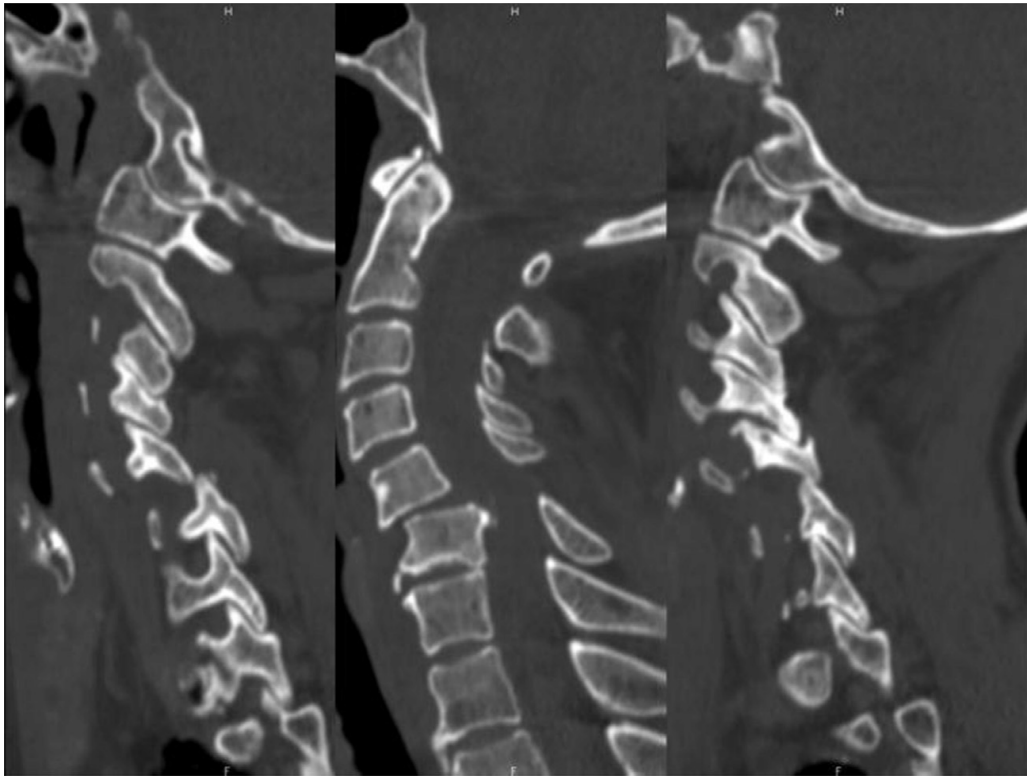


Figure 1

CT scan (sagittal view) showing a right unilateral translation of C5-C6 with antelisthesis of C5 over C6 (case 2).



Figure 2

PolyEtherEtherKetone cage filled with synthetic bone graft (LDR medical MC+®).

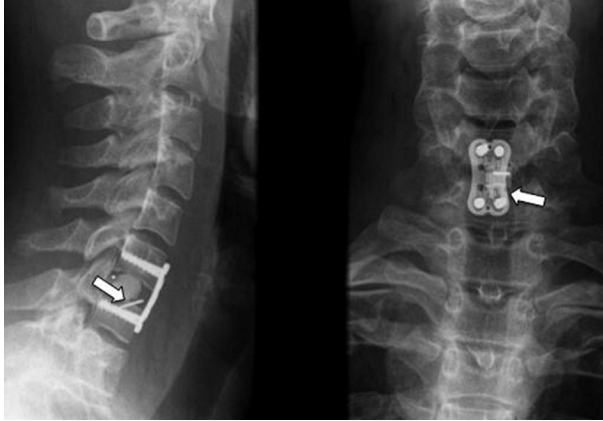


Figure 3

Lateral (a) and anterior (b) X-rays showing anterior cervical fusion by a PEEK cage filled with synthetic bone graft combined with an anchoring clip (arrows) and an anterior locking plate (Case 16).

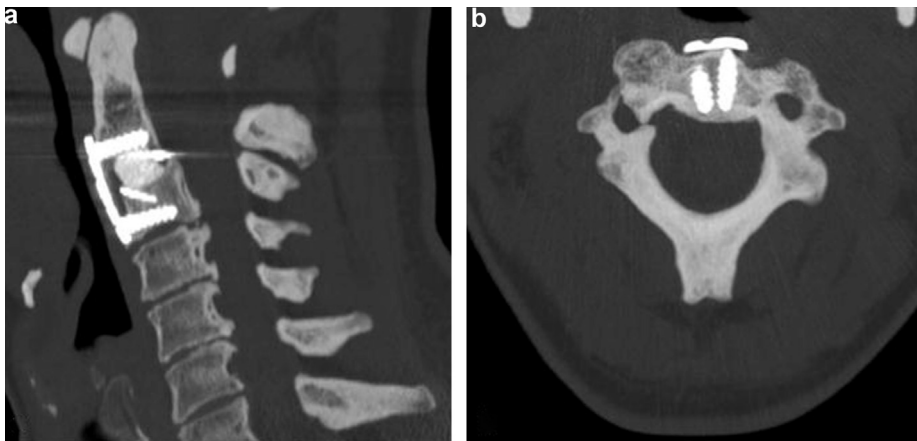


Figure 4

a Sagittal CT scan showing fusion with PEEK cage and synthetic bone graft with an anterior locking plate for a bilateral isthmic fracture of C2 (Case 10).

b Axial CT scan showing bone fusion at one year.

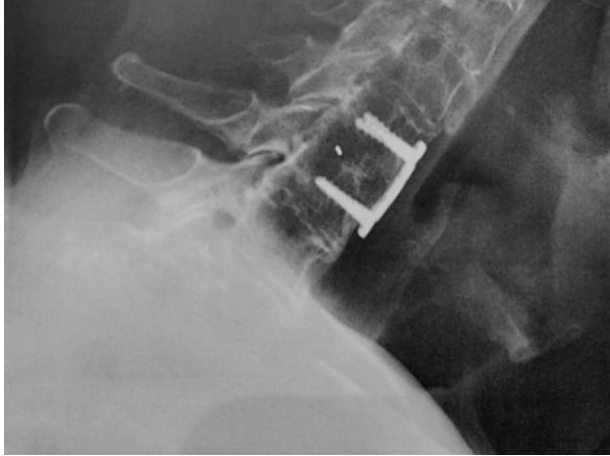


Figure 5

Lateral X-ray showing interbody fusion at one year with a PEEK cage filled with synthetic bone graft without an anchoring clip (case 23).

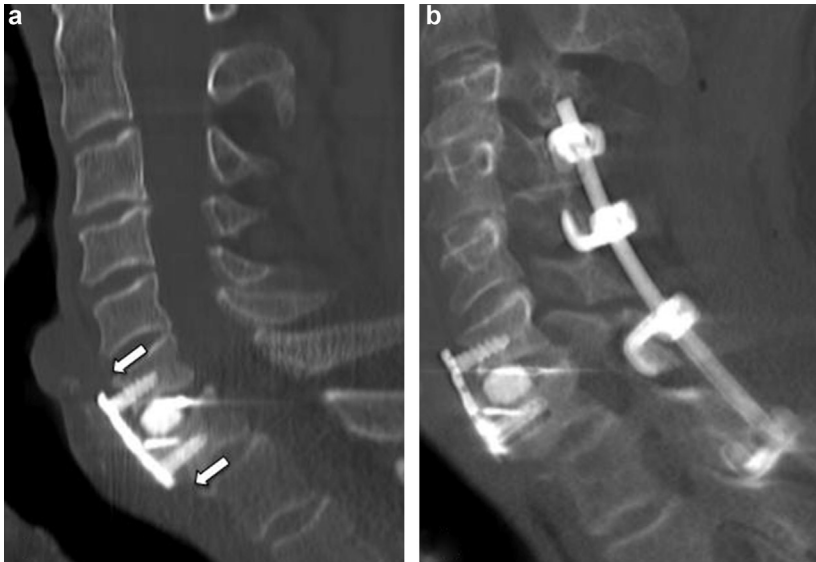


Figure 6

CT scan (sagittal view)

a showing anterior displacement of the cage and the anterior locking plate (arrows).

b after complementary surgery with posterior arthrodesis by laminar hooks (case 5).

Table 1 Sub-axial Cervical Spine Injury Classification system (SLIC) (According to Vaccaro et al. 2000)

Morphology	
- No Abnormality	0
- Compression	1
- Burst	+1=2
- Distraction (e.f., facet perch, hyperextension)	3
- Rotation/ translation (e.g., facet dislocation, unstable teardrop or advanced staged flexion compression injury)	4
Disco-ligamentous complex	
- intact	0
- Indeterminate (e.g., isolated interspinous widening, MRI signal change only)	1
- Disrupted (e.g., widening of disc space, facet perch or dislocation)	2
Neurological status	
- Intact	0
- Root injury	1
- Complete cord injury	2
- Incomplete cord injury	3
- Continuous cord compression in setting of neurological deficit	+1

Table 2 Summary of clinicals and radiologicals findings

Cases	Age (y)	Gender	Level	Description	SLIC	TS (min)	C height (mm)	TH (d)	Home	Rehab	CT	Fusion (mo)	DP	Displ
1	70	M	C6-C7	Translation	6	86	5	5	+			6		
2	56	M	C6-C7	Facet fracture	2	95	6	4	+			3		
3	54	F	C5-C6	Facet fracture	2	60	7	4	+			3		
4	40	M	C3-C4	Distraction	6	80	6	4	+			6		
5	73	M	C6-C7	Facet fracture	2	72	5	5	+					+
6	51	M	C6-C7	Translation	10	89	7						†	
7	31	F	C5-C6	Distraction	6	74	5	5	+			6		
8	31	M	C5-C6	Disc herniation	3	80	4.5	4	+			12		
9	19	M	C4-C5	Facet fracture	2	65	6	4	+			3		
10	47	M	C2-C3	Facet fracture	2	143	7	8	+		+	6		
11	28	M	C7-T1	Distraction	6	125	5	16		+		6		
12	72	F	C5-C6	Translation	9	98	6	10	+			12		
13	19	M	C4-C5	Translation	9	85	6	12		+		6		
14	21	M	C6-C7	Distraction	5	93	6	5	+			6		
15	81	M	C5-C6	Translation	8	68	6						†	
16	20	F	C5-C6	Translation	7	62	6	6	+		+	6		
17	81	F	C6-C7	Facet fracture	2	86	6	11	+					+
18	45	M	C4-C5	Translation	9	90	5	9		+		12		
19	73	M	C7-T1	Disc herniation	4	61	6						†	
20	61	M	C7-T1	Distraction	4	78	6	25		+				+
21	33	M	C6-C7	Translation	6	85	6	6	+		+	6		
22	57	M	C4-C5	Translation	10	71	7						†	
23	83	M	C5-C6	Facet fracture	2	98	6	46		+		12		
24	30	M	C6-C7	Translation	7	72	6	9	+		+	3		
25	46	M	C6-C7	Compression	3	77	5	5	+			6		
26	63	F	C3-C4	Distraction	6	86	7	10	+			6		
27	80	M	C3-C4	Translation	10	65	7						†	
28	88	M	C5-C6	Distraction	7	95	7	10		+		12		
29	73	M	C5-C6	Translation	8	70	7	13	+			12		
30	36	F	C5-C6	Facet fracture	1	68	6	4	+		+	12		
31	58	M	C7-T1	Disc herniation	2	84	7	16	+		+	6		
32	37	M	C3-C4	Distraction	5	63	5	6	+		+	6		
33	47	M	C4-C5	Disc herniation	10	83	7.5	13		+				+
34	49	M	C3-C4	Translation	3	102	7	9	+		+	6		
Mean	52				5,4	82,6		9,8						
Total	34								22	7	8	25	5	4

M Male **F** female **SLIC** Subaxial Injury Classification **TS** Time of Surgery **C height** Cage height **TH** Time of Hospitalization **Home** Patients discharged to home
Rehab Patients referred to rehabilitation **CT** Fusion evaluation by CT scan **DP** deceased patient (†) **Displ** Displacement