



**HAL**  
open science

## Pitfalls in the diagnosis of new-onset frontal lobe seizures

Stéphanie Bourion-Bédès, Coraline Hingray, Héloïse Faust, Jean-Pierre Vignal, Hervé Vespignani, Raymund Schwan, Jacques Jonas, Louis Maillard

► **To cite this version:**

Stéphanie Bourion-Bédès, Coraline Hingray, Héloïse Faust, Jean-Pierre Vignal, Hervé Vespignani, et al.. Pitfalls in the diagnosis of new-onset frontal lobe seizures. *Epilepsy & Behavior Case Reports*, 2014, 2, pp.1-3. 10.1016/j.ebcr.2013.10.002 . hal-01331994

**HAL Id: hal-01331994**

**<https://hal.science/hal-01331994>**

Submitted on 25 Oct 2023

**HAL** is a multi-disciplinary open access archive for the deposit and dissemination of scientific research documents, whether they are published or not. The documents may come from teaching and research institutions in France or abroad, or from public or private research centers.

L'archive ouverte pluridisciplinaire **HAL**, est destinée au dépôt et à la diffusion de documents scientifiques de niveau recherche, publiés ou non, émanant des établissements d'enseignement et de recherche français ou étrangers, des laboratoires publics ou privés.



Distributed under a Creative Commons Attribution - NonCommercial - NoDerivatives 4.0 International License



## Case Report

Pitfalls in the diagnosis of new-onset frontal lobe seizures<sup>☆</sup>

S. Bourion-Bédès<sup>a,\*</sup>, C. Hingray<sup>b,c</sup>, H. Faust<sup>c</sup>, J.P. Vignal<sup>b</sup>, H. Vespignani<sup>b,d,e</sup>, R. Schwan<sup>c,e</sup>,  
J. Jonas<sup>b</sup>, L. Maillard<sup>b,d,e</sup>

<sup>a</sup> Service médico-psychologique régional, Metz, France

<sup>b</sup> Central Hospital of Nancy, Department of Neurology, Nancy Cedex, France

<sup>c</sup> University Hospital of Psychiatrie and Psychothérapie, Laxou, France

<sup>d</sup> CRAN, UMR 7039, CNRS, France

<sup>e</sup> Faculty of Medicine, University of Lorraine, Nancy, France

## ARTICLE INFO

## Article history:

Received 13 October 2013

Accepted 15 October 2013

Available online 28 November 2013

## Keywords:

Frontal lobe epilepsy

Psychogenic nonepileptic seizure

Misdiagnosis

## ABSTRACT

We reported the case of a young woman who received an antiepileptic drug after a first possible generalized tonic-clonic seizure with no clear inter-ictal epileptic paroxysms in the routine electroencephalogram. Her stereotypical movements decreased but did not disappear with treatment. Then a diagnosis of PNES was considered by neurologist after witnessing a stereotypical motor episode. While AED treatment was decreased and stopped, epileptic seizure frequency and severity increased with secondary generalized tonic-clonic seizures. Then she presented postictal psychotic features that combined with video-EEG findings led to the final diagnosis of new onset pre-frontal lobe epilepsy.

© 2013 . Published by Elsevier B.V. This is an open access article under the CC BY-NC-ND license (<http://creativecommons.org/licenses/by-nc-nd/3.0/>).

## 1. Introduction

A constellation of motor and behavioral manifestations can be described in frontal lobe epilepsy which may masquerade as psychiatric disorders and may be difficult to identify as frontal lobe seizure manifestations [1].

We report the case of a young woman with paroxysmal stereotypical motor behaviors initially treated as epileptic seizures then misdiagnosed as psychogenic nonepileptic seizures (PNES). After antiepileptic drug reduction, seizure frequency and severity gradually increased, and she presented postictal psychotic features that, combined with video-EEG findings, led to the final diagnosis of new-onset prefrontal lobe epilepsy.

## 2. Case report

A 22-year-old right-handed woman was referred to the emergency room of the regional hospital for paroxysmal motor behaviors occurring several times a week and a possible generalized tonic-clonic seizure. Paroxysmal motor behaviors consisted of several stereotypical episodes of right arm tonic elevation and abduction sometimes followed by right

leg movements. Birth history, developmental history, and past medical history were unremarkable. There was no family history of epilepsy. Her neurological examination was normal. Workups including a brain magnetic resonance imaging (MRI) and an interictal EEG, both of which were interpreted as normal. Nevertheless, the suspicion of an initial unprovoked generalized tonic-clonic seizure led to a first antiepileptic treatment with oxcarbazepine. Her stereotypical movements decreased but did not disappear with treatment. She decided to ask the opinion of a neurologist who diagnosed psychogenic nonepileptic attacks after witnessing a stereotypical motor episode and decided to progressively stop antiepileptic treatment. Soon after cessation of treatment, she presented once again a cluster of paroxysmal motor manifestations followed by probable generalized tonic-clonic seizures. She was then referred to our department. Her initial neurological examination was normal. She was awake and alert. A long-term video-EEG monitoring was performed to clarify the epileptic or psychogenic nature of her symptoms. During her first video-EEG monitoring session, the patient experienced a psychotic episode with delusions of grandeur, paranoid delusions, auditory hallucinations, and intensive feelings of strangeness with derealization after 4 recorded paroxysmal motor behaviors without any clear concomitant EEG rhythmic discharge. Video-EEG monitoring had to be stopped, and she was transferred to an inpatient psychiatry unit. Psychomotor agitation required a low dose of cyamemazine. The psychotic symptoms disappeared within 24 h. The quick disappearance of psychotic features and the careful analysis of ictal video-EEG findings finally led to the diagnosis of a postictal psychosis complicating a cluster of new-onset prefrontal seizures. Clinically, seizures comprised the following stereotyped sequence: tonic flexion of the head and trunk with intense

<sup>☆</sup> This is an open-access article distributed under the terms of the Creative Commons Attribution-NonCommercial-ShareAlike License, which permits non-commercial use, distribution, and reproduction in any medium, provided the original author and source are credited.

\* Corresponding author at: Service médico-psychologique régional, 1 rue Seulhotte, 57 073 Metz, France. Fax: + 33 3 87 38 51 09.

E-mail addresses: [steph\\_bedes@yahoo.fr](mailto:steph_bedes@yahoo.fr) (S. Bourion-Bédès), [raymund.schwan@univ-lorraine.fr](mailto:raymund.schwan@univ-lorraine.fr) (R. Schwan), [lmaillard@univ-lorraine.fr](mailto:lmaillard@univ-lorraine.fr) (L. Maillard).

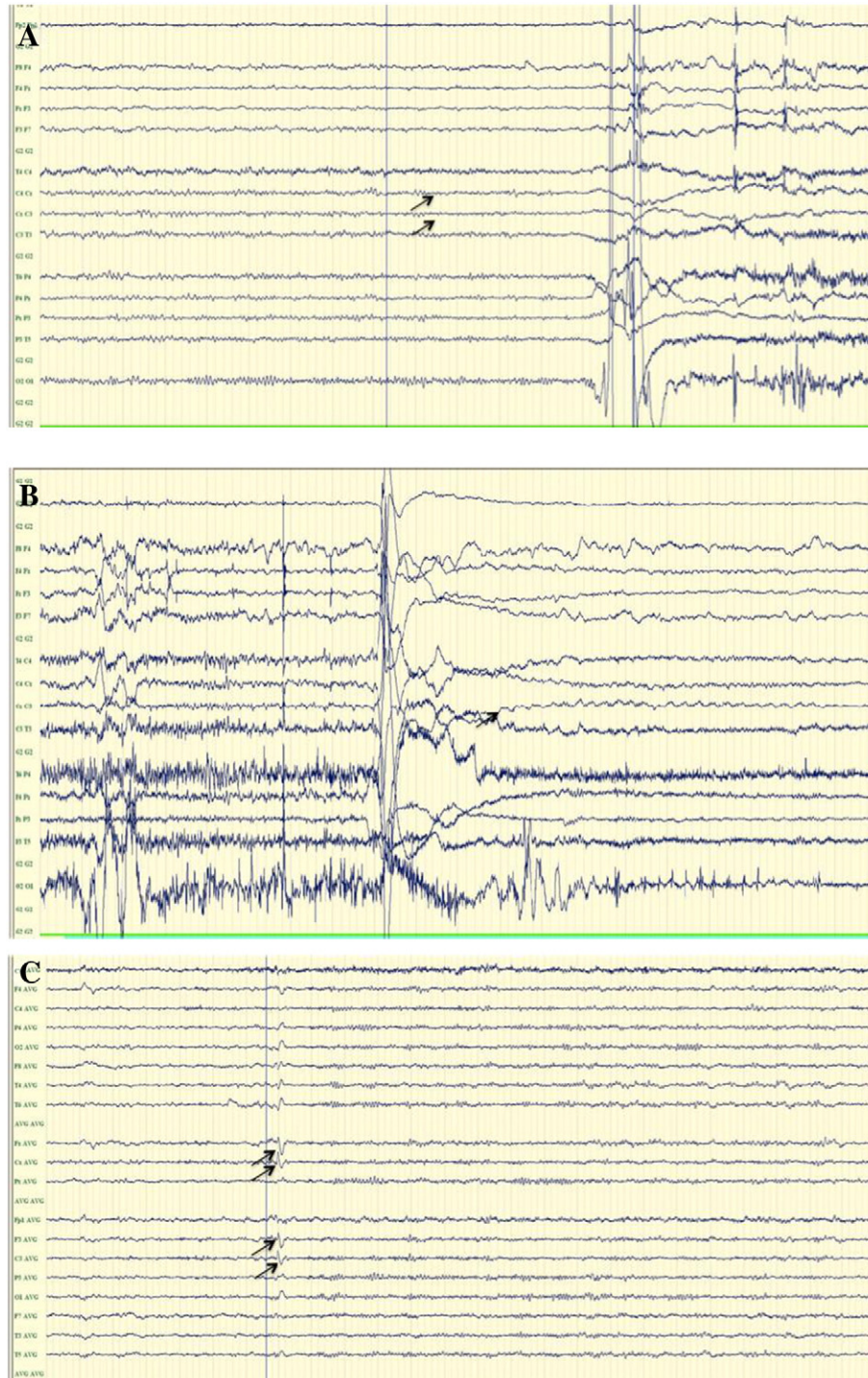
grasping of the bed rails followed by a tonic abduction and flexion of her right upper limb and then by automatisms of flexion and extension of the legs with a right rotation of the pelvis. The full episodes lasted about 20 s and occurred several times a day.

Ictal EEG revealed very discrete abnormalities in all seizures visible 1 to 3 s before the clinical onset and characterized by a generalized flattening, sometimes predominating in the midline frontocentral electrodes (Fz, Cz) followed by a focal theta (4 c/s) rhythmic activity lasting several seconds in the same electrodes (Figs. 1A and B). Interictal spikes were rarely observed in the left and midline frontal electrodes (F3, Fz) (Fig. 1C).

Carbamazepine was started. She has been seizure-free since then, with a follow-up of 30 months, and she had no recurrence of psychotic symptoms.

### 3. Discussion

The present case raises several interesting issues for discussion. The differential diagnosis between epileptic seizures and PNES is known to be sometimes difficult, especially for frontal lobe seizures [2]. This diagnosis has improved over the last 30 years, especially in conjunction with more widespread utilization of video-EEG recordings [3]. The



**Fig. 1.** A: EEG showing a focal flattening in bilateral central electrodes. B: Delayed ictal focal theta (4 c/s) rhythmic activity in bilateral central electrodes. C: EEG showing interictal spikes in the left and midline frontocentral electrodes.

usefulness of video-EEG, even in initially negative EEG cases, is clearly illustrated here.

Before video-EEG monitoring, the patient initially received an antiepileptic drug (AED) after a first possible generalized tonic–clonic seizure with no clear interictal epileptic paroxysms in the routine electroencephalogram. Then, a diagnosis of PNES was considered in the presence of paroxysmal disruptive behavioral and emotional changes without any video-EEG monitoring. While AED treatment was decreased and stopped, epileptic seizure frequency and severity increased with secondarily generalized tonic–clonic seizures. The present case is reported to increase awareness in physicians that the epileptic nature of paroxysmal motor behaviors with normal interictal EEG may be underrecognized and misdiagnosed as PNES in the absence of video-EEG monitoring. Moreover, this case illustrates that it is much safer to rely on video-EEG monitoring before decreasing or stopping antiepileptic drugs if a diagnosis of PNES is suspected in a patient with an initial diagnosis of possible epilepsy.

In our case, video-EEG monitoring established the epileptic nature of the paroxysmal motor behavior based on discrete electroencephalographic ictal correlates. The occurrence of a psychotic episode and its quick resolution were suggestive of a postictal psychosis and indirectly supported the diagnosis of an underlying epilepsy. Both epilepsy and PNES present high comorbidity with psychiatric disorders. A high prevalence of depression, anxiety, PTSD, and personality disorders is associated with PNES. However, to the best of our knowledge, postictal acute and fast-resolving psychotic features have, indeed, never been reported as a complication of PNES [4]. The pathogenesis of postictal psychosis is not fully understood. It is more often present after a cluster of generalized tonic–clonic seizures or in focal epilepsy, especially temporal lobe epilepsy [5]. In frontal lobe epilepsy, ictal hallucinations as well as interictal and postictal psychosis have also been described [1,6]. Even though our patient presented postictal psychotic features earlier in the course of her epilepsy than usually described [7], a postictal psychosis was diagnosed based on the following convergent arguments: prevailing positive symptoms consisting of auditory hallucinations, paranoid delusions, agitation, and disorganized thought [7,8] occurring after a cluster of complex partial and secondarily generalized seizures [9,10] and the short duration of symptoms, which quickly resolved after neuroleptic medication.

In conclusion, this case illustrates that motor and behavioral manifestations with normal interictal EEG encountered in frontal lobe epilepsy may be misdiagnosed as psychogenic nonepileptic seizures. It emphasizes the need for early video-EEG monitoring in ambiguous cases before starting or stopping AED treatment.

### Conflict of interest

The authors have no conflict of interest.

### Acknowledgments

We confirm that we have read the Journal's position on issues involved in ethical publication and affirm that this report is consistent with those guidelines.

### References

- [1] Luat A, Asano E, Rothermel R, Sood S, Chugani H. Psychosis as a manifestation of frontal lobe epilepsy. *Epilepsy Behav* 2008;12:200–4.
- [2] Hubsch C, Baumann C, Hingray C, Gospodaru N, Vignal JP, Vespignani H, et al. Clinical classification of psychogenic non-epileptic seizures based on video-EEG analysis and automatic clustering. *J Neurol Neurosurg Psychiatry* 2011;82(9):955–60.
- [3] Bodde N, Brooks J, Baker G, Boon P, Hendriksen G, Mulder O, et al. Psychogenic non-epileptic seizures—definition, etiology, treatment and prognostic issues: a critical review. *Seizure* 2009;18:543–53.
- [4] Scévola L, Teitelbaum J, Oddo S, Centurión E, Loidl CF, Kochen S, et al. Psychiatric disorders in patients with psychogenic nonepileptic seizures and drug-resistant epilepsy: a study of an Argentine population. *Epilepsy Behav* 2013;29:155–60.
- [5] Kuba R, Brazdil M, Rektor I. Postictal psychosis and its electrophysiological correlates in invasive EEG: a case report study and literature review. *Epilepsy Behav* 2012;23:426–30.
- [6] Adachi N, Onuma T, Nishiwaki S, Murauchi S, Akanuma N, Ishida S, et al. Inter-ictal and post-ictal psychoses in frontal lobe epilepsy: a retrospective comparison with psychosis in temporal lobe epilepsy. *Seizure* 2000;9:328–35.
- [7] Elliott B, Joyce E, Shorvon S. Delusions, illusions and hallucinations in epilepsy: 2. Complex phenomena and psychosis. *Epilepsy Res* 2009;85:172–86.
- [8] Kanemoto K, Kawasaki J, Kawai I. Postictal psychosis: a comparison with acute interictal and chronic psychoses. *Epilepsia* 1996;37:551–6.
- [9] Trimble M. *The psychoses of epilepsy*. New York: Raven Press; 1991.
- [10] Schulze-Bonhage A, Tebartz van Elst L. Postictal psychosis: evidence for extrafocal functional precursors. *Epilepsy Behav* 2010;18:308–12.