



HAL
open science

Nasal Bone Fractures In Children And Adolescents. Patient Demographics, Etiology of The Fracture and Evaluation of Plain Film Radiography as a Diagnostic Method in Children's Clinical University Hospital

Marks Ronis, Linda Veidere, Daiga Marnauza, Lana Micko, Lasma Bidina, Janis Sokolovs

► To cite this version:

Marks Ronis, Linda Veidere, Daiga Marnauza, Lana Micko, Lasma Bidina, et al.. Nasal Bone Fractures In Children And Adolescents. Patient Demographics, Etiology of The Fracture and Evaluation of Plain Film Radiography as a Diagnostic Method in Children's Clinical University Hospital. *Mechanics, Materials Science & Engineering Journal*, 2016, <10.13140/RG.2.1.4639.4001>. <hal-01301822>

HAL Id: hal-01301822

<https://hal.science/hal-01301822v1>

Submitted on 13 Apr 2016

HAL is a multi-disciplinary open access archive for the deposit and dissemination of scientific research documents, whether they are published or not. The documents may come from teaching and research institutions in France or abroad, or from public or private research centers.

L'archive ouverte pluridisciplinaire HAL, est destinée au dépôt et à la diffusion de documents scientifiques de niveau recherche, publiés ou non, émanant des établissements d'enseignement et de recherche français ou étrangers, des laboratoires publics ou privés.



Distributed under a Creative Commons CC BY 4.0 - Attribution - International License

Nasal Bone Fractures In Children And Adolescents. Patient Demographics, Etiology of The Fracture and Evaluation of Plain Film Radiography as a Diagnostic Method in Children's Clinical University Hospital

Marks Ronis¹, Linda Veidere¹, Daiga Marnauza¹, Lana Micko¹, Lasma Bidina¹, Janis Sokolovs²

1 – Riga Stradins University, Faculty of Medicine, Latvia

2 – Children's Clinical University Hospital, Department of Otorhinolaryngology, Latvia



DOI 10.13140/RG.2.1.4639.4001

Keywords: otorhinolaryngology, nasal, trauma, pediatrics, x-ray

ABSTRACT. Nasal bones are the second most common site of fractures in the craniofacial area in pediatric population. Nasal fractures are less common in very young children mostly due to underdeveloped nasal bones and other factors. Nasal bone fractures can be diagnosed clinically. Plain film radiographs are not indicated if an uncomplicated fracture is suspected. They may be difficult to interpret and have low specificity and sensitivity.

Aim. To retrospectively collect data of patients admitted to the Children's Clinical University Hospital, Otorhinolaryngology department with the diagnosis „Fracture of nasal bones” S02.2 (ICD-10) from 01.01.2012 to 31.12.2014. To obtain descriptive statistics concerning pediatric patients. Also, to evaluate if the plain film x-ray is a necessity when diagnosing nasal bone fractures and its impact on the decision for surgical reduction of the fracture.

Results. During the time period of three years given above there were 153 patients admitted to the ENT department with diagnosis S02.2. Among those 120 (78,4%) were male and 33 (21,6%) were female. Most patients, 103, were 13 to 17 years old. The etiology of trauma was obtained from 89 (58,2%) patients' histories. Convincingly the most common cause was sports trauma in 43. Statistical analysis showed no statistically significant connection ($p=0,296$) between the positive findings of nasal bone fractures and the decision to perform a reduction of the fracture. However, it showed a statistically significant association ($p<0,05$) between deformity of the nose and the decision to perform the reduction.

Conclusions. Based on the descriptive statistics a risk group of nasal bone fracture patients in pediatric population can be outlined – boys who do contact sports in their early teenage years. As to plain film radiography it is safe to conclude that it is unreliable for the evaluation of nasal fractures in children. Furthermore, this study showed, that the decision for the surgical reduction of the fracture can be based on the results of a thorough patient examination and the fact that the patient presents with a visual deformity of the nose.

Introduction. Nasal bones are the second most common site of fractures in the maxillofacial area in pediatric population [1, 2]. Still the incidence is much lower than in adults. In adolescence, a nasal bone fracture pattern more closely resembles that of adults [3]. In very young children, however, nasal fractures are less common mostly due to underdeveloped nasal bones and less prominent nasal pyramid [4]. Therefore prevalence of pediatric nasal bone fractures increases progressively with increasing age. Two peaks have been observed in the frequency of such fractures: The first, at the age of 6–7 years, is associated with the beginning of school attendance [9]. The second, at 12–14 years, is related to increased physical activity and participation in sports during puberty and adolescence [9,12]. In pediatric patients sports and falls are the major causes of isolated nasal bone fractures. There is a marked preponderance of boys in the worldwide pediatric population affected by facial fractures, with the male-to-female ratio ranging from 1,1:1 to 8,5:1, depending on the study [9,10,12]. The predominance of boys is attributed mainly to the fact that their physical activity is more intense and more hazardous than that of girls.

To properly treat nasal bone fracture it is important to evaluate and diagnose it by physical or radiologic examination. In general, these fractures can be diagnosed by clinically identifying crepitus and tenderness [5]. If an uncomplicated nasal fracture is suspected, plain film radiography is rarely indicated [6]. Previous studies show that plain radiography yields negative results in 25% of patients

who required surgical intervention [7]. A study by de Lacey found that plain films had a 66% false-positive reading as a result of the misinterpretation of normal suture lines, vascular indentation lines, or developmental thinning of the nasal bones (8). Plain radiographs of the nose in pediatric patients are especially difficult to interpret because of possible growth plate fractures and cartilaginous injuries [9, 10]. Due to low sensitivity of plain x-ray imaging, its' efficiency in clinical decision making has become controversial [11] (Figure 1). Over the course of 3 years, at least 136 nasal bone radiographs in multiple projections have been ordered in Children's Clinical University Hospital mostly due to possible legal matters but also because of patients' parents' concerns about the required reduction of the fracture without what they believe to be a critical step in diagnosing – nasal bone x-ray.

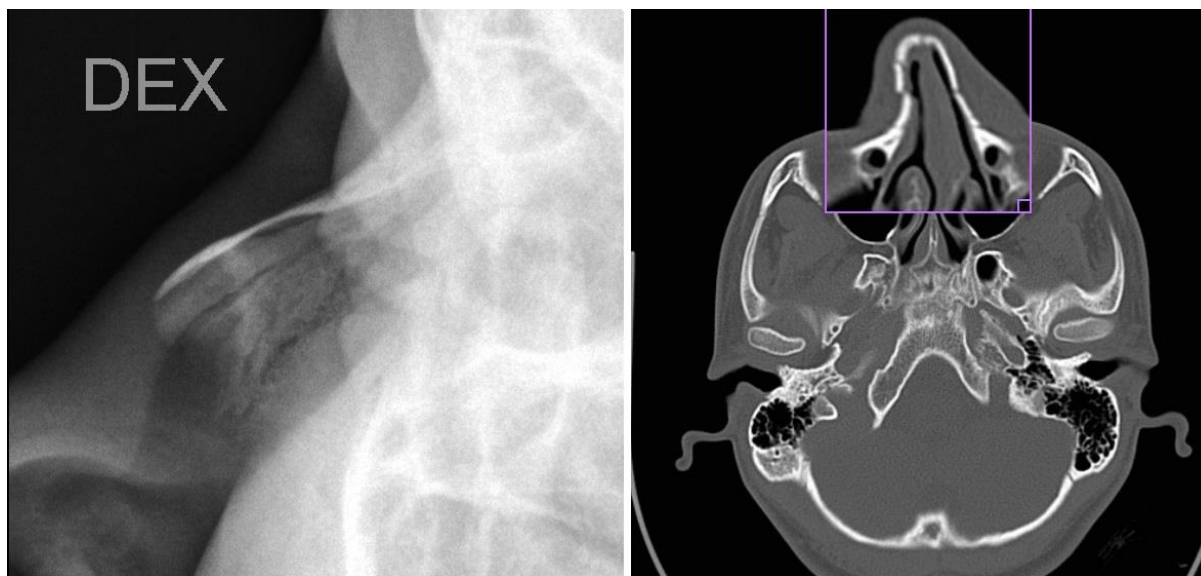


Fig. 1. On the left: a plain film radiograph of the right nasal bone of a patient from this study. Note the seemingly normal appearance of the nasal bone. On the right: a head CT scan of the same patient, performed on the same day as the radiograph. Note the fracture of the right nasal bone with a slight dislocation (white arrow)

Aim. The aim of this study was to identify the characteristics in the demographics of pediatric patients with nasal bone fractures and find the most common causes of the trauma to further establish possible risk groups.

The second objective was to evaluate whether plain film radiography is a crucial diagnostic procedure, which further determines the necessity of a reduction of the fracture in children presenting with nasal trauma in Children's Clinical University Hospital.

Materials and Methods. Using a retrospective study design records of 153 patients admitted to the Children's Clinical University Hospital (Riga, Latvia) department of otolaryngology with the diagnosis „Fracture of nasal bones” S02.2 (ICD-10) from 01.01.2012 to 31.12.2014 were studied. Data was gathered using patient data from Children's Clinical University Hospital's information system “Andromeda”. Statistical analyses were performed using IBM SPSS Statistics ver. 22 software. $p < 0,05$ was considered statistically significant.

Descriptive statistics concerning patients' age, gender, month in which the trauma occurred, etiology of the trauma were obtained. Patients were sorted into three age groups: preschool children (less than 7 years old), primary school children (7 to 12 years old) and teenagers (13 years and older). Depending on the etiology of the trauma, patients were categorized into five groups: traffic accident, sports trauma, domestic trauma (including accidental falls), fight without criminal character between

peers and fight with criminal character (including domestic abuse, beating by a group of people, assault on the street by a stranger). χ^2 test was applied to determine if there was a statistically significant difference between the etiology of the nasal bone fracture in different age groups.

Cross tabulation with χ^2 test was used to determine if there was any connection between positive radiologic findings and treated patient rate as well as between visual deformity of the nose on initial physical exam and treated patient rate.

Results. A total of 153 patients' records were selected for further analysis. Patients were from 2 to 17 years old with the mean age at the moment of nasal bone fracture of 13,21 years ($\pm 3,45$). 120 (78,4%) patients were male and 33 (21,6%) were female. Most frequently, the trauma occurred in April and March (20 and 19 cases respectively). The mean duration of hospital stay was 3,42 days ($\pm 1,98$).

The precise etiology of trauma was obtained from 89 (58,2%) patients' histories (Figure 2) due to lack of specific information about the trauma in some cases. The most common cause was sports injury in 43 cases. Comparing the cause of trauma in two separate age groups: teenagers in which the majority of the traumas occurred (103 cases) and primary school children revealed that the most common type of trauma in both groups was sports trauma followed by fights among peers without criminal character for teenagers and household trauma for primary school children (Figure 3). Pearson's χ^2 test revealed that there is statistically significant difference in nasal bone fracture causes between these groups. There were only 7 patients in the preschool group of which only one record specified the cause of trauma therefore this group was excluded from statistical analysis. It is worth pointing out that while the male/female ratio stayed similar in both the preschool and primary school children 1,9:1, in teenage group the number of males tripled while the number of female patients stayed the same resulting in a male/female ratio of 5,9:1.

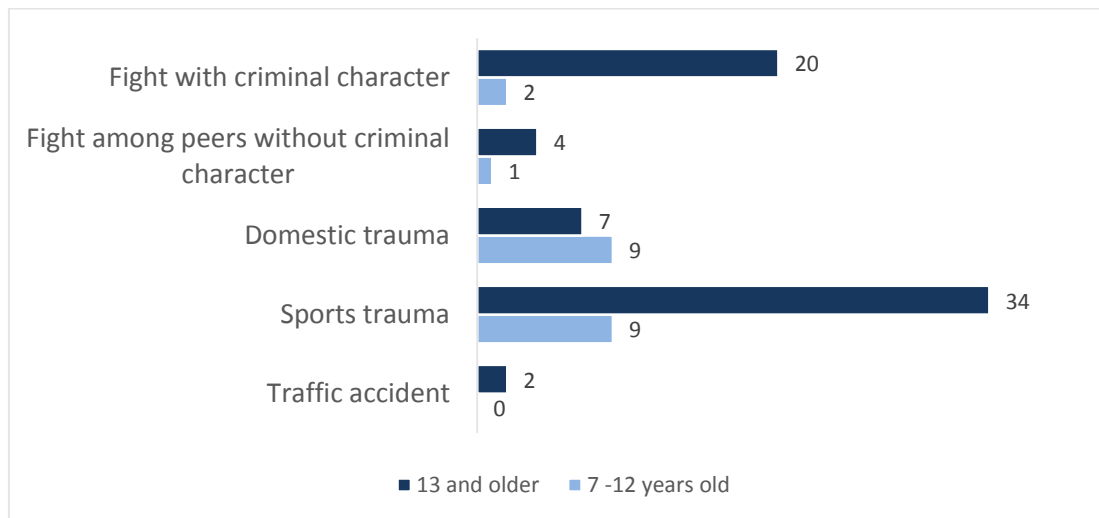


Fig. 2. The causes of nasal bone fractures in teenage and primary school age groups

136 (88,9%) patients underwent plain film radiography of nasal bones in at least 2 projections. 6 of these patients had diagnostic imaging done outside Children's Clinical University Hospital and there was no official radiologist's conclusion in the records. Due to this fact only the rest 130 patients were selected for further analysis of which 92 had a confirmed nasal bone fracture on plain film radiographs, while the rest 38 had no confirmation of fracture using this imaging modality.

Out of all patients 114 had a mention of visual deformity of the nose on the initial clinical examination by an otorhinolaryngologist at Children's Clinical University Hospital while 9 patients did not present with a visual deformity and 30 patients had no data concerning the visual appearance of the nose.

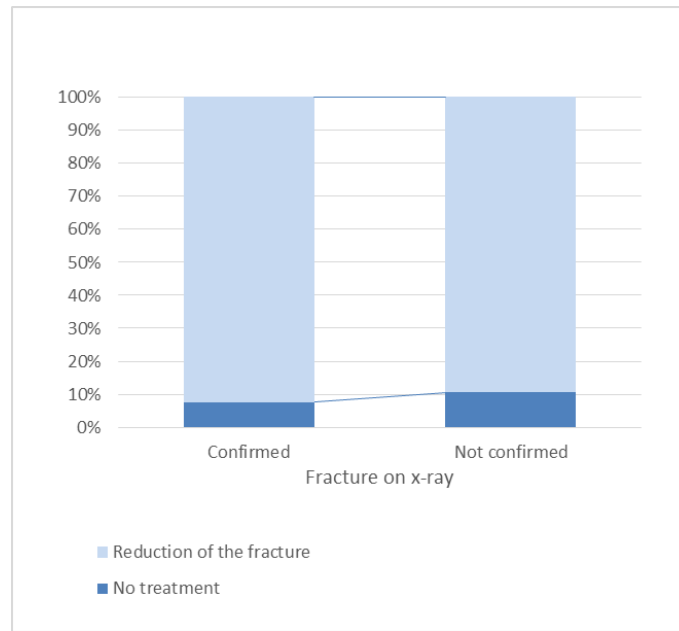


Fig. 3. Even on graphical presentation of the data there is only a slightly noticeable difference between the patients who had a confirmed fracture on the x-ray and those who did not

The statistical analysis of Pearson’s χ^2 showed that there is no statistically significant connection ($p=0,296$) between the positive findings of nasal bone fractures and the decision to perform a reduction of the fracture (Figure 4). However, it showed a statistically significant association ($p<0,05$) between deformity of the nose and the decision to perform the reduction (Figure 5).

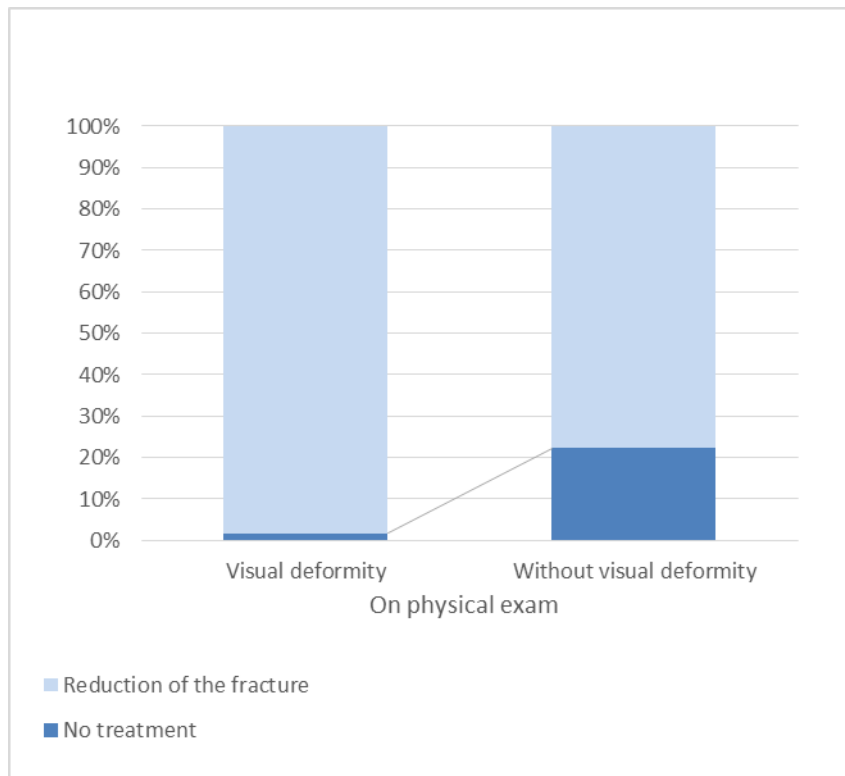


Fig. 4. The difference, unlike in Fig. 3, is visible when comparing those with visual deformity of the nose after trauma with those who had no deformity

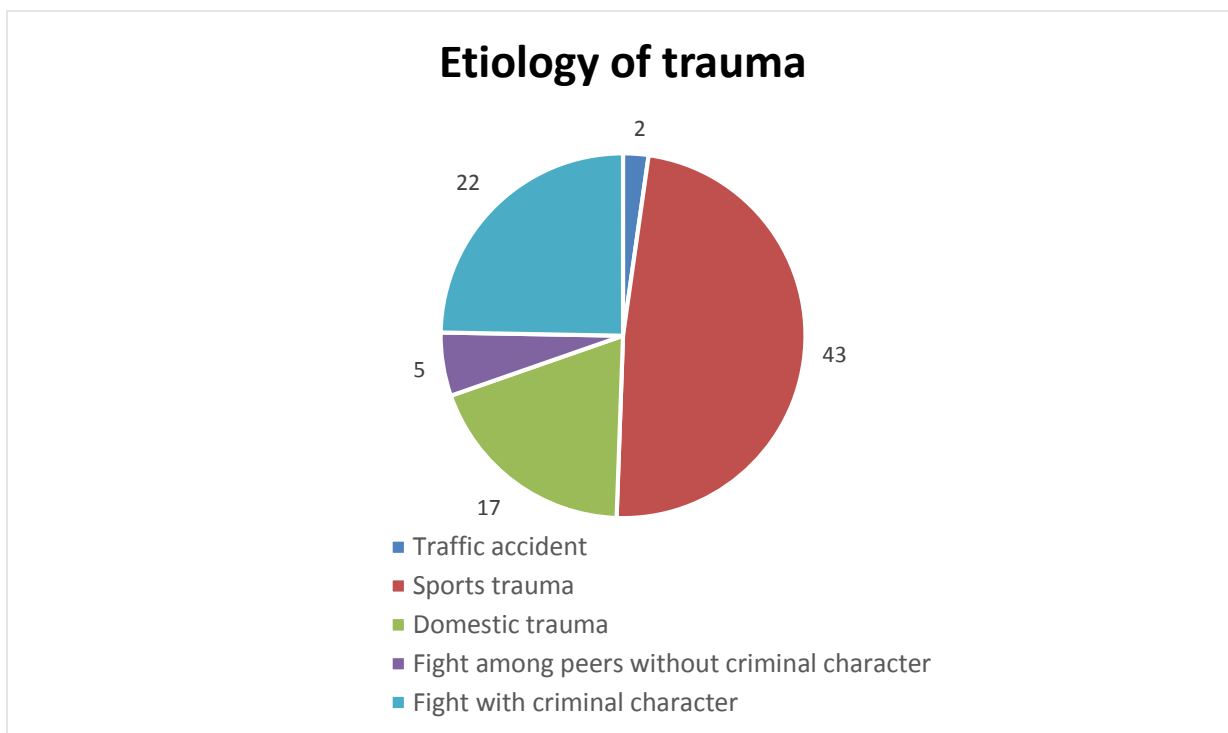


Fig. 5. Etiology of trauma

Discussion. Male patients are at higher risk of nasal bone fractures, especially in their teenage years. In puberty fights among peers with resulting nasal trauma are common among males, however trauma acquired during sports activities such as football, basketball and martial arts, all of which can be described as contact sports, remains the number one cause of nasal bone fractures in the teenage portion of the pediatric population. The high number of male patients is what brings this age group to have the most cases. The number of female patients does not change much with age and the relative increase in the primary school group could be explained with the fact that they start school and are left without the attention of adults more frequently. This could also be true in accordance to males in the primary school group as this is the age at which most parents decide that their children should also do after school activities of which sport is the most popular. Nasal bone fractures in preschool children were rare. There are some limitations to this study in case of etiology because only 89 records contained precise description of how the trauma occurred, especially in younger children. Also, this study showed very small number of patients in the traffic accident etiology group, this may be due to the fact that these patients have polytrauma and are treated in other departments of the hospital with an otorhinolaryngologist as a consult. To sum up, demographic data (predominance of male patients and patient number increase with age) and trauma etiology (sports trauma as the most common) corresponds with the tendencies given in existing literature and studies [9, 10, 12] – the small incidence peak at the start of school attendance and the bigger peak in teenage years during puberty (Figure 6).

This study shows that plain film radiography has little or no role in clinician's decision to perform reduction of the nasal bone fracture. Several patients with positive findings on x-ray examination have been left untreated, while some of those who had no signs of fracture on the x-ray images still underwent the reduction of the fracture. The diagnosis "fracture of nasal bones" remains mostly dependent on the findings on the initial examination by an otorhinolaryngologist. The most significant finding being the visual deformity of the nose, which in many cases indicates the necessity to perform a reduction of the fracture. Over the course of 3 years at least 136 nasal bone radiographs have been done in Children's Clinical University Hospital. The government's funding for this procedure is 4 euro and 15 euro-cents per projection. That makes at least 564,40 euro in total for a method that is reported to be only 72% sensitive and 73% specific [13].

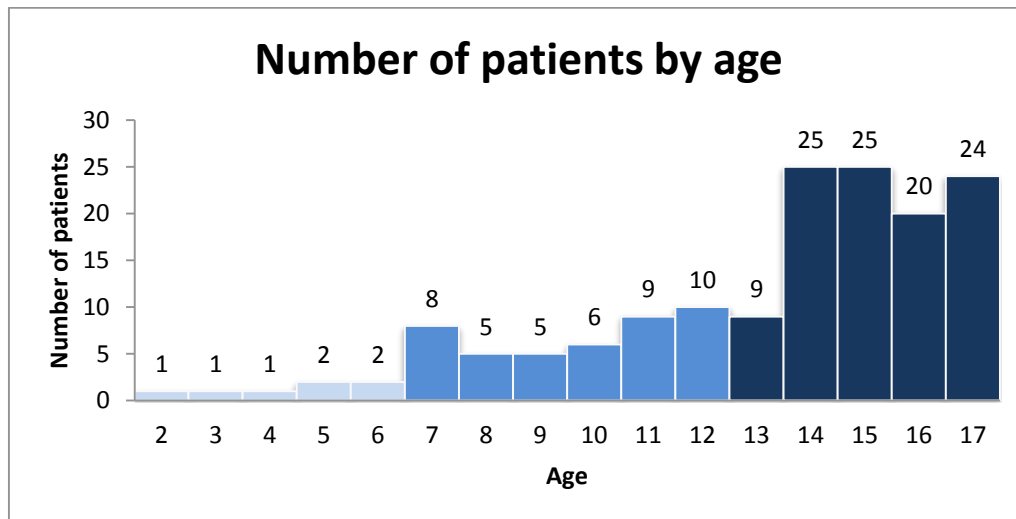


Fig. 6. Incidence of nasal bone fractures by age. Notice the small peak of incidence at 7 years and the big peak at the onset of puberty at 14 years

However, due to legal matters it is still important to confirm nasal bone fractures using diagnostic imaging. Computer tomography (CT) is a great alternative for detecting nasal bone fractures with sensitivity and specificity near 100% [13, 14]. Yet, ordering a CT scan for younger children often requires sedation or general anesthesia. Additionally there are risks of radiation-induced leukemia and brain cancer with CT head scans [15]. In this study 12 patients underwent a CT head scan ordered by a neurologist on account of neurologic symptoms such as severe headache or short loss of consciousness after the trauma. Unfortunately, the sample size of these patients was too small to yield any statistically correct results concerning the accuracy of CT in the diagnosis of nasal bone fractures. The CT scan confirmed nasal bone fractures in 9 patients.

In the past decade, the use of high-resolution ultrasonography (HRUS) in detecting nasal bone fractures has emerged. There have been numerous publications comparing HRUS to plain film radiography and CT in all of which the specificity and sensitivity of HRUS was near 100%. Another advantage of HRUS is that it is radiation free and doesn't require the patient to be completely still during examination [13, 16, 17]. Taking into account the poor performance of plain x-ray imaging shown in this study and the radiation hazards and complexity of performing CT head scans in younger children, authors suggest that a new study should be conducted using HRUS as a diagnostic procedure in nasal bone fractures alongside plain film radiography. This would help to bring a safer and more precise imaging modality into everyday practice.

Summary. A risk group of nasal bone fracture patients in pediatric population can be outlined; they are predominantly males 7 to 17 years of age with a peak of incidence at the time of puberty. Children, including females, who do contact sports, are at higher risk of nasal bone fracture. These fractures are very rare in children less than 7 years of age.

It is safe to conclude that plain film radiography is unreliable for the evaluation of nasal fractures in children. Furthermore, this study showed, that the decision for the reduction of the fracture can be based on a thorough otorhinolaryngologist's examination and the fact that the patient presents with a visual deformity of the nose.

References

[1] Muñante-Cárdenas J.L., Olate S., Asprino L., et al: Pattern and treatment of facial trauma in pediatric and adolescent patients. *J. Craniofac. Surg.* 2011; 22: pp. 1251-1255.

- [2] Imahara S.D., Hopper R.A., Wang J., et al: Patterns and outcomes of pediatric facial fractures in the United States: a survey of the National Trauma Data Bank. *J. Am. Coll. Surg.* 2008; 207: pp. 710-716.
- [3] Lee D.H., Jang Y.H. Pediatric nasal bone fractures: Does delayed treatment really lead to adverse outcomes? *Int. J. Pediatr. Otorhinolaryngol.* 2013; 77: pp. 726-731.
- [4] Desrosiers A.E., and Thaller S.R.: Pediatric nasal fractures: evaluation and management. *J. Craniofac. Surg.* 2011; 22: pp. 1327-1329.
- [5] Han D.S., Han Y.S., Park J.H. A new approach to the treatment of nasal bone fracture: radiologic classification of nasal bone fractures and its clinical application. *J. Oral Maxillofac. Surg.* 2011; 69: pp. 2841-2847.
- [6] Kucik C.J., Clenney T., Phelan J. Management of acute nasal fractures. *Am. Fam. Physician.* 2004; 70: pp. 1315-1320.
- [7] Damman F. Imaging of paranasal sinuses today. *Radiologe* 2007; 7: pp. 576, 578-583.
- [8] de Lacey G.J., Wignall B.K., Hussain S., Reidy J.R. The radiology of nasal injuries: problems of interpretation and clinical relevance. *Br J Radiol.* 1977; 50:412-4.
- [9] Zimmermann C.E., Troulis M.J., Kaban L.B. Pediatric facial fractures: recent advances in prevention, diagnosis and management. *Int. J Oral Maxillofac Surg* 2006;35(1):2–13
- [10] Holland A.J., Broome C., Steinberg A., Cass D.T. Facial fractures in children. *Pediatr Emerg Care.* 2001;17(3):157–160.
- [11] Gurkov R., Clevert D., Krause E. Sonography versus plain X-rays in diagnosis of nasal fracture. *Am. J. Rhinol.* 2008;22: 613-616.
- [12] Ferreira P.C., Amarante J.M., Silva P.N., et al. Retrospective study of 1251 maxillofacial fractures in children and adolescents. *Plast. Reconstr. Surg.* 2005; 115: 1500–1508.
- [13] Mohammadi A, Ghasemi-Rad M. Nasal bone fracture--ultrasonography or computed tomography? *Med. Ultrason.* 2011;13: 292-295.
- [14] Hwang K., You S.H., Kim S.G., Lee S.I. Analysis of nasal bone fractures; a six-year study of 503 patients. *J Craniofac Surg.* 2006;17(2):261–4.
- [15] Miglioretti D.L., Johnson E, Williams A. The Use of Computed Tomography in Pediatrics and the Associated Radiation Exposure and Estimated Cancer Risk. *JAMA Pediatrics.* 2013; 167: 700-707.
- [16] Lee M.H., Cha J.G., Hong H.S., Lee J.S., Park S.J., Paik S.H., Lee H.K. Comparison of high-resolution ultrasonography and computed tomography in the diagnosis of nasal fractures. *J. Ultrasound. Med.* 2009; 28:717-23.
- [17] Adeyemo W.L., Akadir O.A. A systematic review of the diagnostic role of ultrasonography in maxillofacial fractures. *Int. J Oral Maxillofac Surg.* 2011; 40:655-661.