



HAL
open science

Is ventricular deformation affine?

Martin Genet, Constantin von Deuster, Christian T. Stoeck, Sebastian
Kozerke

► **To cite this version:**

Martin Genet, Constantin von Deuster, Christian T. Stoeck, Sebastian Kozerke. Is ventricular deformation affine?. 2nd International Workshop on Latest Advances in Cardiac Modeling (LACM 2015), Mar 2015, Munich, Germany. hal-01274902

HAL Id: hal-01274902

<https://hal.science/hal-01274902>

Submitted on 17 Feb 2016

HAL is a multi-disciplinary open access archive for the deposit and dissemination of scientific research documents, whether they are published or not. The documents may come from teaching and research institutions in France or abroad, or from public or private research centers.

L'archive ouverte pluridisciplinaire **HAL**, est destinée au dépôt et à la diffusion de documents scientifiques de niveau recherche, publiés ou non, émanant des établissements d'enseignement et de recherche français ou étrangers, des laboratoires publics ou privés.

Is ventricular deformation affine?

MARTIN GENET^{*†}, CONSTANTIN VON DEUSTER^{†‡}, CHRISTIAN T. STOECK^{†‡} AND
SEBASTIAN KOZERKE^{†‡}

*Marie Curie International Outgoing Fellow

†Institute for Biomedical Engineering, ETH Zurich, Switzerland

‡Division of Imaging Sciences and Biomedical Engineering, King’s College London, United Kingdom

Abstract

Introduction. Recent advances in cardiac diffusion tensor imaging (DTI) have enabled robust imaging of the *in vivo* heart [1]. This allows to non-invasively assess myofiber and myosheet orientations, which has been a long-standing bottleneck of patient-specific cardiac modeling [2]. Thanks to efficient sequence design, *in vivo* DTI has even been performed in patients [3] and at multiple cardiac phases [4]. In this study, we analyze dual phase cardiac DTI data of normal humans to investigate the affinity of ventricular deformation. The angulation data is compared to predictions based on myofiber transportation by macroscopic deformation, to quantify the potential relative sliding between myofibers.

Methods. *In vivo* DTI data was obtained on a healthy human volunteer, using a slice interleaved dual heart phase stimulated echo acquisition mode (STEAM) imaging method [4]. Ten short-axis slices were acquired with diffusion weighting along ten directions [4]. In addition, three dimensional tagged magnetic resonance images were acquired using a complementary spatial modulation of magnetization (3D CSPAMM) method, and post-processed using the SinMod algorithm to obtain the displacement field throughout the ventricle during the cardiac cycle [5]. They were used (*i*) to account for myocardial strain during diffusion tensor reconstruction [4]; and (*ii*) to map the tensor points acquired at end-diastole and end-systole (see next paragraph).

The analysis consists in comparing the angulation of the myocardial microstructure from end-diastole to end-systole (or *vice versa*), (*i*) measured using *in vivo* DTI; and (*ii*) associated to the macroscopic deformation measured using 3D CSPAMM. First of all, the end-systolic position of the end-diastolic tensor points was computed, and the closest end-systolic tensor point of each transported end-diastolic tensor point was found. Then, to compute the former, *i.e.*, the measured rotation between end-diastole and end-systole, the angles between the myofiber vectors of each couple of tensors was assessed. Finally, to compute the later, *i.e.*, the rotation induced by the macroscopic deformation, the rotation part of the deformation gradient was extracted.

Results. Figure 1(a-b) shows the tensor points at end-diastole & end-systole, while Figure 1(c-d) compares the transmural variation of measured & transported helix & transverse angle change. The data suggests that there is an average additional rotation of 10° of the myofibers from end-diastole to end-systole, in addition the rotation induced by the macroscopic transformation. Measured & transported transverse angles are more similar.

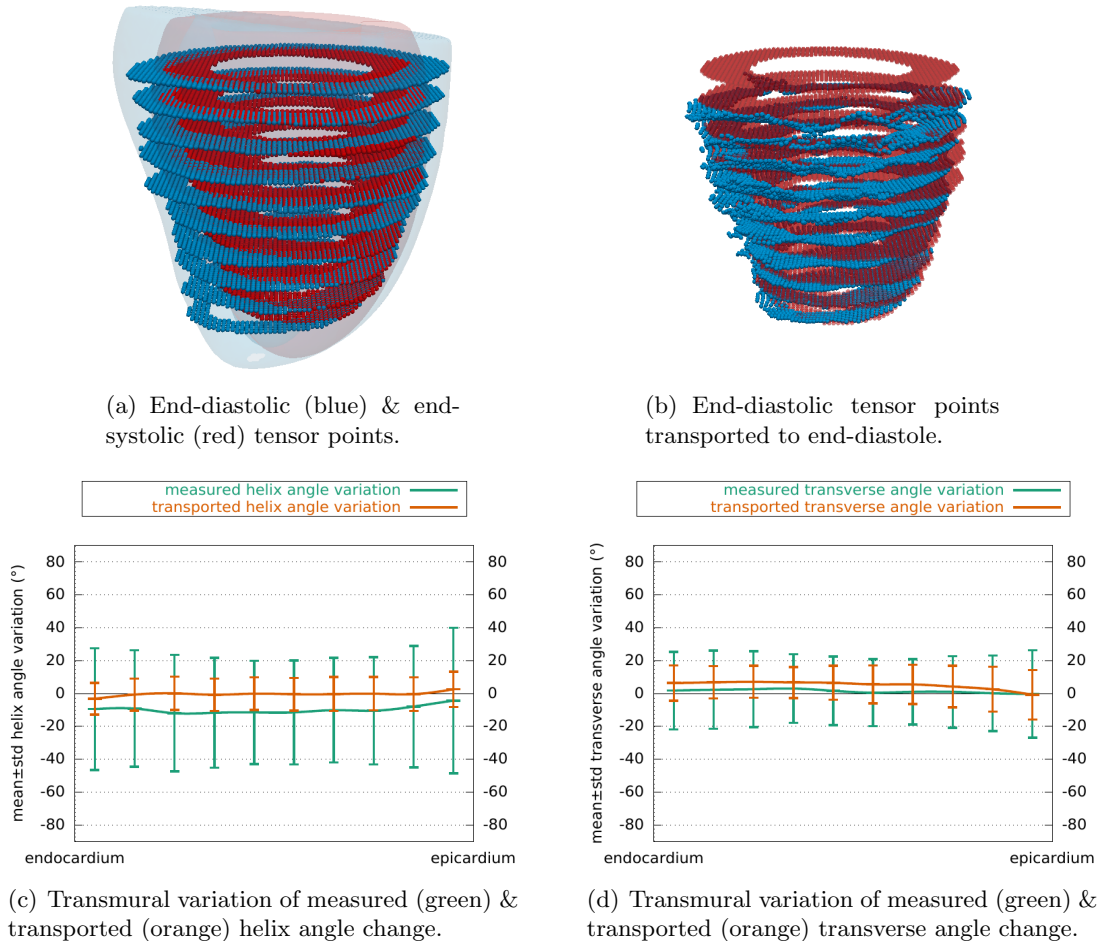


Figure 1: Analysis of a high-resolution *in vivo* DTI & tagged MRI dataset.

Discussion. The present analysis provides an element of response to the long-standing question of the affinity of the ventricular deformation; our findings are however limited by the use of a single *in vivo* dataset. We are now working toward performing the analysis on a dataset of ten human volunteers, in order to confirm the finding. The non-affinity foreseen here could have a significant impact in cardiac modeling, where mostly first order continuum models are currently used, as well as in cardiology, where it could help to better explain the complex cardiac deformation and potentially represent a valuable biomarker for diagnosis.

References

- [1] S. Nelles-Vallespin, *et al.*. In vivo diffusion tensor MRI of the human heart: Reproducibility of breath-hold and navigator-based approaches. *Magnetic Resonance in Medicine*, **70**, 454–465, 2013.
- [2] L. C. Lee, *et al.*. Applications of computational modeling in cardiac surgery. *Journal of Cardiac Surgery*, **29**(3), 293–302, 2014.
- [3] J. Harmer, *et al.*. In vivo myofibre architecture in the systemic right ventricle. *European Heart Journal*, **34**(47), 3640, 2013.
- [4] C. T. Stoeck, *et al.*. Dual-phase cardiac diffusion tensor imaging with strain correction. *PloS One*, **9**(9), 2014.
- [5] H. Wang, *et al.*. Analysis of 3D cardiac deformations with 3D SinMod. Conf. Proc. IEEE Eng. Med. Biol. Soc, 2013.