



**HAL**  
open science

## Contrast enhancement of eye fundus images

Guillaume Noyel, Michel Jourlin, Rebecca Thomas, Gavin Bhakta, Andrew Crowder, David Owens, Peter Boyle

► **To cite this version:**

Guillaume Noyel, Michel Jourlin, Rebecca Thomas, Gavin Bhakta, Andrew Crowder, et al.. Contrast enhancement of eye fundus images. International Diabetes Federation. IDF2015 - World Diabetes Congress, Nov 2015, Vancouver, Canada. , IDF2015 - World Diabetes Congress 2015, 1110-P, 2015, 10.13140/RG.2.1.3180.9367 . hal-01243876

**HAL Id: hal-01243876**

**<https://hal.science/hal-01243876>**

Submitted on 16 Dec 2015

**HAL** is a multi-disciplinary open access archive for the deposit and dissemination of scientific research documents, whether they are published or not. The documents may come from teaching and research institutions in France or abroad, or from public or private research centers.

L'archive ouverte pluridisciplinaire **HAL**, est destinée au dépôt et à la diffusion de documents scientifiques de niveau recherche, publiés ou non, émanant des établissements d'enseignement et de recherche français ou étrangers, des laboratoires publics ou privés.

Copyright



# Contrast enhancement of eye fundus images

1110-P

Guillaume Noyel<sup>1</sup>, Michel Jourlin<sup>2</sup>, Rebecca Thomas<sup>3</sup>, Gavin Bhakta<sup>4</sup>, Andrew Crowder<sup>4</sup>, David Owens<sup>3</sup>, Peter Boyle<sup>1,5</sup>

1. International Prevention Research Institute - iPRI, Lyon, France | 2. Laboratoire Hubert Curien, UMR CNRS 5516, Saint-Etienne, France | 3. Diabetes Research Group, Institute of Life Sciences, College of Medicine, Swansea University, Wales, United Kingdom  
4. Diabetic Retinopathy Screening Service for Wales, Wales, UK | 5. University of Strathclyde Institute of Global Public Health at iPRI, Lyon, France | Correspondence: guillaume.noyel@i-pri.org

## BACKGROUND

A significant number of digital eye fundus images have strong contrast variations which can be a limiting factor for the diagnosis of the diabetic retinopathy lesions.

Current solution: manual contrast made by graders.

Limitations:

- This is not easily reproducible.
- Images may still be considered un-gradable because they are too bright or too dark.

Causes: Cataract, motion of the patient, acquisition conditions and differences in absorptions of the light in the eye.

## Aim

We have developed a fully automatic method, which achieves contrast uniformity across the entire image.

## METHOD

It is based on a colour model consistent with the physical principles of image formation.

The contrast of the dark or the bright elements are adjusted in a way that provides a similar colour aspect to lesions such as micro-aneurysms or to anatomical structures such as veins.

It is much more powerful than the previous existing grey level methods using polynomial adjustment (1), mathematical morphology (2) or histogram equalisations (3).

## RESULTS

It has been tested on more than 2000 images acquired from different screening services ranging from a high resource country with quality controlled process while others were obtained from low resource countries under harsher conditions.

Some images were bright while others were dark making diagnosis difficult.

For all images, the lighting variations have been corrected and the contrast has been enhanced for lesions such as micro-aneurysms and the vascular structures.

=> Easier detection by graders.

## DISCUSSION

This new colour contrast method is very promising tool to assist graders in diagnosing the presence of diabetic retinopathy and other lesions present in digital eye fundus images since the lesions appear to be much more evident in comparison of the original image.

Importantly our method is fully automatic and can be easily integrated in a screening system.

Figure 1. Contrast enhancement by our colour method using images from a high-resource country.

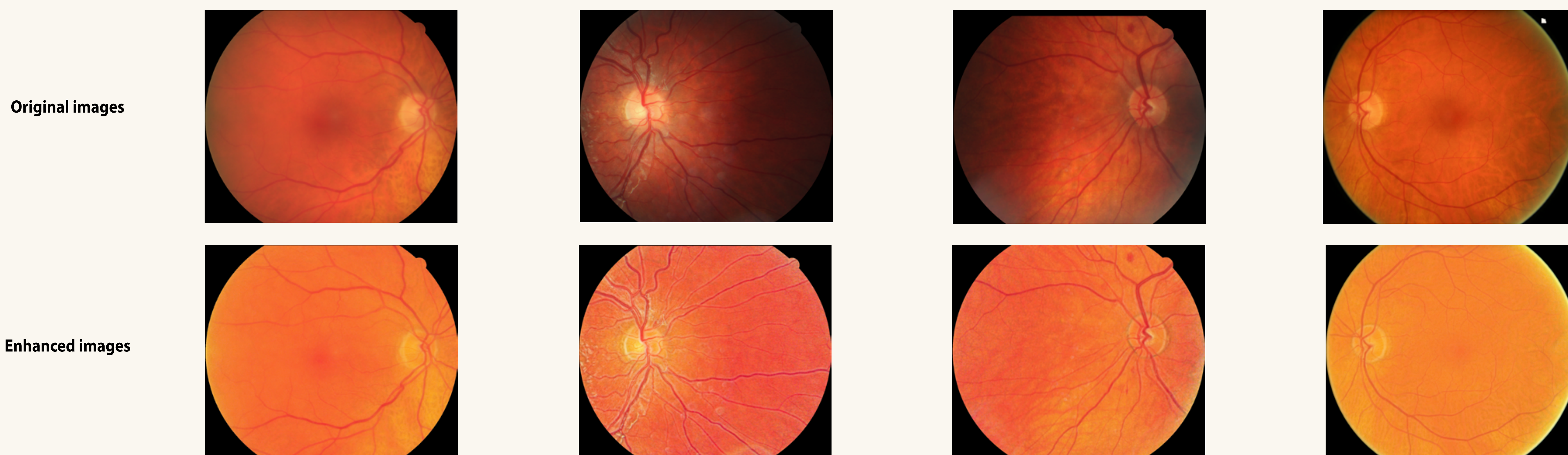
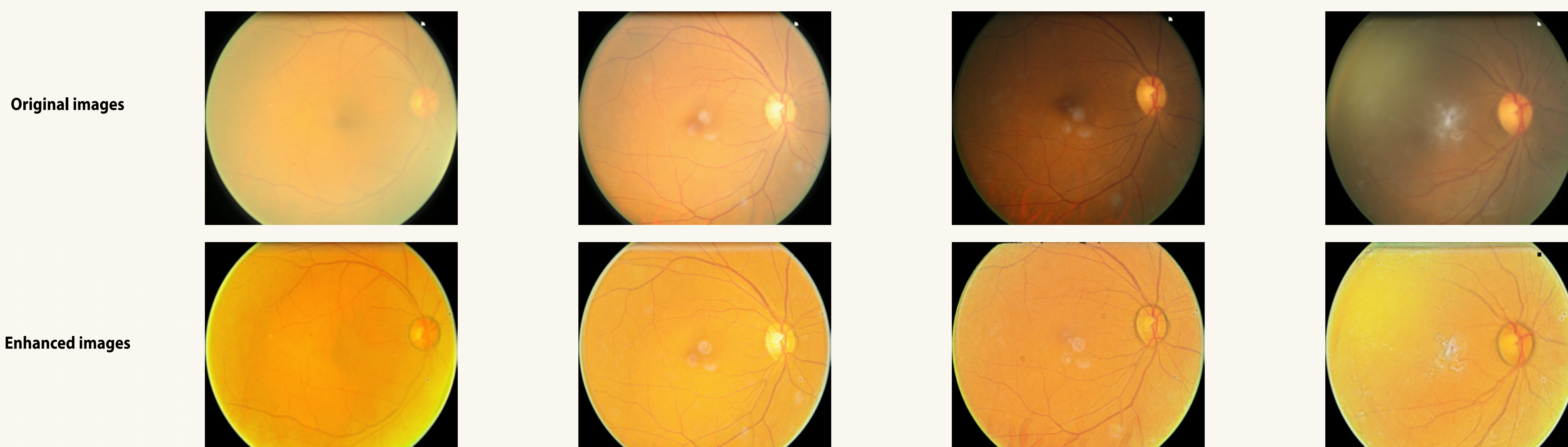


Figure 2. Contrast enhancement by our colour method using images from a low-resource country.



**Conflict of interest disclosure:**

This poster does not contain any trade names. This poster does not cover any unapproved uses of specific drugs, other products or devices.

**References:**

1. Walter T, Massin P, Erginay A, et al. Automatic detection of microaneurysms in color fundus images. Med Image Anal 11: 555-566, 2007.
2. Zhang X, Thibault G, Decenciere E, et al. Exudate detection in color retinal images for mass screening of diabetic retinopathy. Med Image Anal 18: 1026-1043, 2014.
3. Zuiderveld K. Contrast limited adaptive histogram equalization. In: Graphics gems IV, edited by Heckbert PS. San Diego, CA, USA: Academic Press Professional, Inc., 1994.