



HAL
open science

Echocardiographic characteristics and outcome of straddling mitral valve

Alain Fraisse, Pedro J. del Nido, Jean Gaudart, Tal Geva

► **To cite this version:**

Alain Fraisse, Pedro J. del Nido, Jean Gaudart, Tal Geva. Echocardiographic characteristics and outcome of straddling mitral valve. *Journal of the American College of Cardiology*, 2001, 38 (3), pp.819-826. 10.1016/S0735-1097(01)01441-3 . hal-01211578

HAL Id: hal-01211578

<https://hal.science/hal-01211578v1>

Submitted on 26 Apr 2016

HAL is a multi-disciplinary open access archive for the deposit and dissemination of scientific research documents, whether they are published or not. The documents may come from teaching and research institutions in France or abroad, or from public or private research centers.

L'archive ouverte pluridisciplinaire **HAL**, est destinée au dépôt et à la diffusion de documents scientifiques de niveau recherche, publiés ou non, émanant des établissements d'enseignement et de recherche français ou étrangers, des laboratoires publics ou privés.

Echocardiographic Characteristics and Outcome of Straddling Mitral Valve

Alain Fraisse, MD,* Pedro J. del Nido, MD, PhD,† Jean Gaudart, MD,‡ Tal Geva, MD, FACC*
Boston, Massachusetts and Marseille, France

OBJECTIVES	This study sought to characterize the echocardiographic features of straddling mitral valve (SMV) and to determine its surgical implications and midterm outcome in a large clinical cohort.
BACKGROUND	Despite a relatively large body of literature on the postmortem anatomy of SMV, there is a paucity of information regarding its echocardiographic features, surgical implications and preoperative predictors of outcome.
METHODS	A retrospective review identified 46 patients with SMV between 1982 and 1999 who underwent echocardiography and surgery and had follow-up data. A detailed review of the echocardiograms, surgical reports and all pertinent records was undertaken.
RESULTS	Review of the echocardiograms revealed a widely varying anatomy among the study patients. However, four distinct groups with relatively uniform morphologic features could be distinguished on the basis of segmental analysis. Cardiac malposition associated with right ventricular hypoplasia, superior-inferior ventricles and criss-cross atrioventricular relations were common among patients with {S,D,L} (S = viscerotrial situs solitus, D = D-ventricular loop, L = L-malposition of the great arteries) (n = 6) and {S,L,D} (n = 5) segmental combinations but were rare among patients with {S,D,D} (n = 26) and {S,L,L} (n = 9) combinations. Surgical management consisted of a functional single-ventricle palliation in 38 patients (83%) and biventricular repair in 8 patients (17%). Overall mortality was 22%, but none of the seven patients who were operated on during the cohort's last five years (1994 to 1999) has died. By multivariate analysis, noncommitted ventricular septal defect was the strongest independent predictor of death (relative risk = 10.2), followed by multiple ventricular septal defects (relative risk = 4.7).
CONCLUSIONS	This study demonstrates that echocardiography provides detailed noninvasive imaging of the complex anatomic features of SMV and its associated anomalies. Anatomic classification based on segmental analysis allows the distinction of four groups with more uniform morphologic features. Although a biventricular approach is feasible in selected patients, a functional univentricular palliation is indicated in those with major straddling and markedly hypoplastic ventricles. (J Am Coll Cardiol 2001;38:819-26) © 2001 by the American College of Cardiology

Straddling mitral valve (SMV) is a rare congenital cardiac malformation that is invariably associated with a ventricular septal defect (VSD) and almost always with conotruncal anomalies (1-3). The etiology and morphogenesis of SMV remain incompletely understood, but its anatomic features have been well described on the basis of autopsy material (1-8). These reports indicate that the mitral valve (MV) straddles the anterior aspect of the septum through a malalignment conoventricular-type VSD, that the most common associated conotruncal anomaly is double-outlet right ventricle (DORV) followed by transposition of the great arteries (TGA) and that left and right ventricular size varies considerably (2-6). However, because of its rare occurrence, most published reports on SMV are based on a

relatively small number of cases, and no consistent anatomic classification has been proposed. The morphologic and functional features of SMV in living patients have not been described in detail, and few reports have addressed the echocardiographic features of SMV (9-12). Moreover, information on midterm outcome and preoperative echocardiographic features predictive of mortality is scarce. Only a few surgical reports have included patients with SMV (13-16); the largest published clinical experience included only 11 patients (14). Thus, the spectrum of echocardiographic findings and the optimal surgical management of patients with SMV remain unclear. The goals of this study, therefore, are to propose a classification of SMV based on echocardiographic findings in 46 patients, to report their midterm clinical outcome and to identify preoperative variables predictive of mortality.

MATERIALS AND METHODS

Patients. The computerized database of the Department of Cardiology at Children's Hospital (Boston, Massachusetts)

From the Departments of *Cardiology and †Cardiac Surgery, Children's Hospital, and the Departments of Pediatrics and Surgery, Harvard Medical School, Boston, Massachusetts; and the ‡Laboratoire de Biomathématiques, Université de la Méditerranée, Marseille, France. Dr. Fraisse was supported by the Federation Francaise de Cardiologie.

Manuscript received January 22, 2001; revised manuscript received May 10, 2001, accepted May 23, 2001.

Abbreviations and Acronyms

AV	=	atrioventricular
DORV	=	double-outlet right ventricle
LV	=	left ventricle
MV	=	mitral valve
RV	=	right ventricle
SMV	=	straddling mitral valve
TGA	=	transposition of the great arteries
TV	=	tricuspid valve
VSD	=	ventricular septal defect

was searched for all patients with the coded diagnosis of SMV from 1982 through February 1999. Patients were included in this study if they had: 1) a preoperative echocardiogram performed in our laboratory with documentation of SMV; 2) surgical management at Children's Hospital; and 3) follow-up data regarding outcome. The Committee on Clinical Investigations at Children's Hospital approved the study protocol.

Clinical and echocardiographic data. The clinical records, echocardiograms, surgical reports and, when applicable, autopsy reports were reviewed. The following data were recorded for each patient, based on clinical records: demographic information, age at diagnosis, age at first surgery, age at last surgery and type of surgical procedures. The following anatomical details were documented based on review of the echocardiograms: segmental anatomy (17), atrioventricular (AV) relationship, ventricular size and function, mitral valve morphology and attachments (including number and location of the papillary muscles), tricuspid valve (TV) morphology and function, type of conus, semilunar valve morphology and function, outflow tract obstruction (defined as peak Doppler gradient ≥ 20 mm Hg) and the morphology of the great arteries. All associated malformations were recorded. Ventricular size was graded as normal or hypoplastic (defined as ventricular sinus apex reaching $\leq 2/3$ of the cardiac apex). Ventricular function was qualitatively graded as normal or mildly, moderately or severely depressed. The type of VSD and its relationship to the semilunar valves were classified as subaortic, subpulmonary, doubly committed or uncommitted according to published criteria (18). Straddling mitral valve was defined as attachments of MV chordae tendineae on both sides of the ventricular septum (1-4). Patients with chordal attachments on the left ventricular septal surface were not considered to have SMV and were not included in this study. Major degree of SMV was defined as more than half of the MV related to the infundibulum on the basis of qualitative assessment from a short-axis view (either subxiphoid or parasternal) and from the apical four-chamber view during diastole. The anatomical definitions of right ventricle (RV) sinus, infundibulum and the nomenclature of segmental anatomy were previously published (17-20).

Statistical analysis. The frequency of anatomic findings was compared between groups using Fisher exact test. The

demographic and anatomic findings of patients who were alive at the time of the most recent follow-up evaluation were compared with those of nonsurvivors. The Kaplan-Meier method was used to evaluate the probability of survival over time. Univariate analysis of predictors of death was performed using the Breslow test for qualitative variables and the Cox proportional hazards model for continuous variables. To identify independent predictors of mortality, variables that reached a p value < 0.2 by univariate analysis were entered into a multivariate Cox proportional hazards model with a backward elimination algorithm. A p value < 0.05 was considered statistically significant.

RESULTS

Patients. Forty-six patients fulfilled inclusion criteria for this study. Two of the patients included in this series were previously reported (6). Of the 46 patients included, 27 were males and 19 were females (male/female ratio = 1.4). Their median age at echocardiography was 1.1 years (range 0 to 13). Their mean (\pm standard deviation) follow-up was 3.9 ± 4.8 years (range 3 days to 17 years).

Anatomic findings. All patients had viscerotransposition of the great arteries (S, D-ventricular loop and the remaining 30% had L-ventricular loop). Based on review of the echocardiograms, patients with viscerotransposition of the great arteries (S), D-ventricular loop (D) and L-malposition of the great arteries (L), or {S,D,L} segmental anatomy, differed from those with {S,D,D} pattern in that the prevalence of dextrocardia, superior-inferior ventricles, criss-cross AV relations and RV sinus hypoplasia was significantly higher in the former group. Similarly, levocardia, superior-inferior ventricles, criss-cross AV relations and RV sinus hypoplasia were more common in patients with {S,L,D} than in those with {S,L,L} anatomy. Consequently, patients were grouped according to the following four segmental anatomic patterns: {S,D,D} in 26 cases, {S,D,L} in 6 cases, {S,L,D} in 5 cases and {S,L,L} in 9 cases. Table 1 summarizes the anatomic characteristics of the four anatomic groups and Figures 1 to 4 show their echocardiographic features.

Several anatomic features were common to all patients. The MV was good-sized and straddled into the RV infundibulum over the anterior aspect of the ventricular septum through a conoventricular-type VSD. Malalignment between the conal septum superiorly and the muscular interventricular septum inferiorly was also present in all patients. In 12 patients (26%) the VSD extended posteriorly into the AV canal septum (inlet septum), in 2 patients (4%) the VSD was restricted by the straddling MV leaflets and in 4 patients (9%) there were additional muscular VSDs. The most common location of the VSD was subpulmonary (61%), followed by subaortic in 22%, noncommitted in 11% and doubly committed VSD in 6%. All patients had an abnormal conotruncus, with DORV being the most common anomaly (83%) followed by TGA (17%). However, the

Table 1. Anatomic Characteristics of 46 Patients with Straddling Mitral Valve

Segmental Anatomy	Group I {S,D,D} (n = 26)	Group II {S,D,L} (n = 6)	Group III {S,L,D} (n = 5)	Group IV {S,L,L} (n = 9)	All Patients (n = 46)
Dextrocardia	0	2*	0	4	6
SI ventricles	2	5	5	0	12
Crisscross AV relations	0	2	2	0	4
VA alignment					
DORV	22	6	4	6	38
TGA	4	0	1	3	8
Ventricular size					
No hypoplasia	20	1	1	7	29
Hypoplastic RV sinus	1	4	3	2	10
Hypoplastic LV	5	1	1	0	7
Type of conus					
Subaortic	15	5	4	7	31
Bilateral	10	1	1	2	14
Subpulmonary	1	0	0	0	1
VSD					
Subpulmonary	19	4	4	1	28
Subaortic	5	1	0	4	10
Noncommitted	1	0	1	3	5
Doubly committed	1	1	0	1	3
Extension of VSD into AV canal	8	0	1	3	12
Restrictive VSD	1	1	0	0	2
Additional VSDs	4	0	0	0	4
Outflow obstruction					
Pulmonary	16	6	3	8	33
Aorta	6	0	1	0	7
Neither	4	0	1	1	6
TV straddling	2	0	0	1	3
Major straddling	6	2	1	2	11

*In one patient the heart was predominantly in the left hemithorax on chest x-ray but with a rightward-pointing apex.

AV = atrioventricular; LV = left ventricle; RV = right ventricle; SI = superior-inferior; TV = tricuspid valve; VA = ventriculo-arterial; VSD = ventricular septal defect.

prevalence of TGA in patients with L-ventricular loop was slightly higher (29%) than in those with D-ventricular loop (12%). The most common type of conus was subaortic (67%), followed by bilateral (30%). One patient with {S,D,D} DORV segmental anatomy had a subpulmonary conus.

The morphology of the MV leaflets, the extent of straddling and the anatomy of the chordae tendineae and papillary muscles varied considerably among patients. In 87% of cases, the anterior leaflet of the MV was large and a portion of it straddled through an anteriorly positioned conoventricular VSD into the RV infundibulum. Less frequently (13%), both anterior and posterior MV leaflets straddled into the infundibulum (Fig. 3). Based on the defined criteria, the degree of SMV was judged to be major in 11 patients (24%) and minor in the other 35 patients (76%). In 29 patients (63%), the SMV attached to a single papillary muscle or to a group of small papillary muscles within the infundibulum. In the remaining 17 patients, most of whom had minor straddling, the SMV had direct chordal attachments within the infundibulum. The site of infundibular attachment(s) included septal band (35 patients), conal septum (12 patients), and the infundibular free wall (23 patients). In the LV, the MV attached to two distinct papillary muscles in 17 patients (37%), to two fused papillary muscles in 12 patients (26%) and to a single

posteromedial papillary muscle in 17 patients (37%). The anterior leaflet of the MV was frequently divided by an additional commissure, resulting in a trileaflet MV. The chordae tendineae from both sides of the commissure converged into one or more closely spaced papillary muscles within the infundibulum, thus creating a functional commissure. By Doppler, there was mild mitral regurgitation in nine patients (20%) and mild tricuspid regurgitation in eight patients (17%). None of the patients had more than mild AV valve regurgitation.

Both ventricles were well developed in 29 patients (63%), the RV was hypoplastic in 10 patients (22%) and the left ventricle (LV) was hypoplastic in 7 patients (15%). The MV was well developed in all patients whereas the TV was hypoplastic in seven patients (15%). In the three patients with hypoplasia of the RV sinus and a well-developed TV, the TV straddled through the posterior aspect of the VSD (AV canal-type VSD)—i.e., bilateral straddling.

Obstruction of the pulmonary outflow tract was common in this series (33 patients, 72%). Subvalvar and valvar pulmonary stenosis was present in 24 patients and pulmonary atresia in 9 patients. The mechanism of obstruction was judged to be secondary to conal septal malalignment in all patients. In two of these patients, the SMV was felt to further contribute to the pulmonary outflow obstruction. Aortic outflow was obstructed in seven patients (15%), with

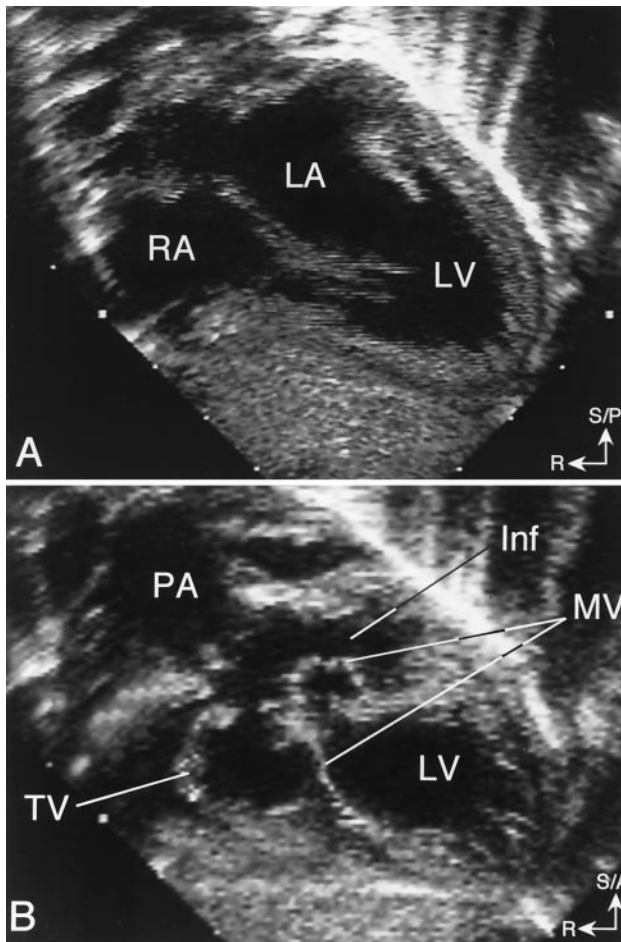


Figure 1. Straddling mitral valve in a patient with double outlet right ventricle and {S,D,D} segmental anatomy. (A) Subxiphoid long-axis view showing levocardia, situs solitus of the atria with a right-sided right atrium (RA), left-sided left atrium (LA), and D-ventricular loop. The mitral valve is seen entering the left ventricle (LV). (B) Cranial angulation of the transducer demonstrates straddling of the MV into the infundibulum (Inf). PA = pulmonary artery; S/A = superior/anterior; S/P = superior/posterior; R = right; TV = tricuspid valve.

anterior malalignment of the conal septum in all patients and MV tissue interposition in one patient. In six patients there was no outflow obstruction. Associated anomalies included coarctation (5 patients), type A interrupted aortic arch (1 patient), secundum atrial septal defect (16 patients), left superior vena cava to coronary sinus (2 patients), additional muscular VSDs (4 patients), coronary artery anomaly (3 patients), patent ductus arteriosus (6 patients) and severe dilation of the main pulmonary artery (1 patient). **Clinical profile and outcome.** The clinical presentation was predominantly influenced by the relative distribution of pulmonary and systemic blood flow. Cyanosis associated with decreased pulmonary blood flow led to an early placement of a systemic-to-pulmonary artery shunt in 25 patients (54%). Increased pulmonary blood flow dominated the clinical picture in 11 patients (24%). Pulmonary artery banding was performed in seven patients, coarctation repair in one patient and stage I Norwood procedure in an additional three patients who had severe LV and aortic

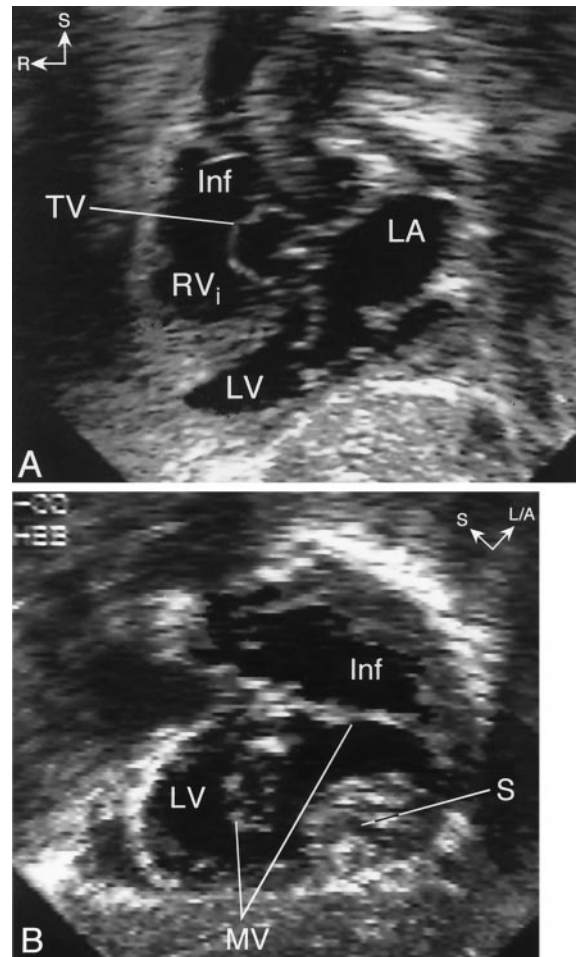


Figure 2. Echocardiogram in a patient with straddling mitral valve (MV) and {S,D,L} segmental anatomy. (A) Subxiphoid long-axis view showing dextrocardia, left-sided left atrium (LA) with an MV that enters an inferior left ventricle (LV). The right ventricle inflow (RV_i) is superior to the LV and the ventricular septum is horizontal (superior-inferior ventricles). Notice that the tricuspid valve (TV) is seen in a "short-axis" orientation whereas the MV is seen in a "long-axis" orientation. This indicates that the axes of the MV and TV are angled relative to each other, typical for criss-cross atrioventricular relations. (B) Clockwise rotation of the transducer from the long-axis plane demonstrates major straddling of the MV into a large left-sided infundibulum (Inf). L/A = left/anterior; R = right; S = superior.

hypoplasia. Four patients (9%) presented with well-balanced pulmonary-to-systemic flow ratio and underwent a modified Fontan operation as their first operation. Five patients (11%) underwent a biventricular repair as their first operation: LV-to-aortic valve intracardiac baffle and a conduit from the RV to the pulmonary arteries (Rastelli procedure) in two patients, arterial switch operation with VSD closure in two patients and an atrial switch with VSD closure in one patient. Three additional patients underwent a biventricular repair after an initial palliative procedure at another institution. The most recent operation was a biventricular procedure in eight patients (17%), whereas 38 patients (83%) underwent a functional single-ventricle palliation. Among the 38 patients who had a functional single-ventricle palliation, 11 (29%) had major MV straddling, seven had LV

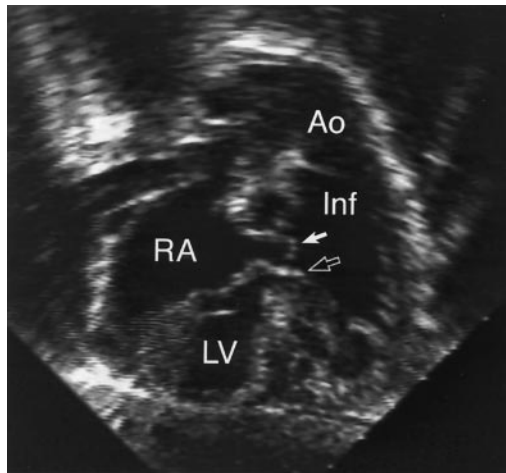


Figure 3. Straddling mitral valve in a patient with double-outlet right ventricle {S,L,L} segmental anatomy and straddling of both anterior (white arrow) and posterior (black arrow) mitral leaflets. Ao = aorta; Inf = infundibulum; LV = left ventricle; RA = right atrium.

hypoplasia and nine had RV sinus hypoplasia. All patients who underwent a biventricular repair had minor SMV and two well-developed ventricles, except for one patient with a mildly hypoplastic RV who successfully underwent an arterial switch operation and VSD closure. None of the patients with {S,L,D} segmental anatomy and only two patients with {S,D,L} segmental combination underwent biventricular repair. Overall, the patients underwent an average of 2.2 operations each (range 1 to 5). The median age at last surgery was 2.3 years (range 0 to 13) and the mean duration of follow-up was 3.9 ± 4.8 years.

Ten patients died during the study period, yielding a mortality rate of 22%. The clinical characteristics of the patients who died are summarized in Table 2. The mortality rate did not change significantly from 1982 to 1988 (4/17, 24%) to 1989 to 1993 (6/22, 27%). However, all seven patients who were operated on from 1994 through February 1999 survived. There were 7 deaths (18%) among the 38 patients who underwent single-ventricle palliation and 3 deaths (38%) in the 8 patients who underwent a biventricular repair ($p = 0.25$). Kaplan-Meier analysis of the proba-

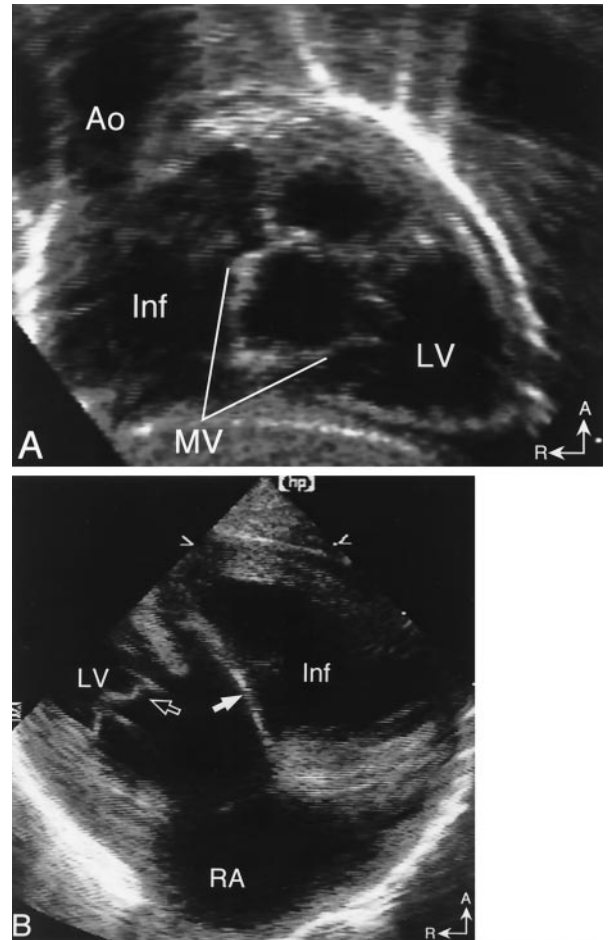


Figure 4. Straddling mitral valve (MV) associated with double-outlet right ventricle and {S,L,D} segmental anatomy. (A) Cranial angulation of the transducer in the subxiphoid long-axis plane shows straddling of the MV into a right-sided infundibulum (Inf). Notice the rightward position of the aorta (Ao). (B) Parasternal long-axis view showing the posterior MV leaflet entering the left ventricle (LV) (open arrow) and the anterior MV leaflet inserting into the infundibulum (Inf) (white arrow). A = anterior; R = right.

bility of survival for the entire cohort demonstrated that the likelihood of survival was 87% at 1 year, 79% at 8 years and 74% at 20 years (Fig. 5). When the same analysis was

Table 2. Clinical Characteristics of the Patients Who Died

Patient	Type of Last or Major Surgery	Number of Operations	Age at Death (yr)	Time of Death After Surgery (days)	Cause of Death
1	Stage I Norwood	1	0	11	cardiac arrest*
2	Bidirectional Glenn	2	0.5	2	arrhythmia
3	Stage I Norwood	1	0.1	0	hypoxemia
4	Modified Fontan	4	8	2	low cardiac output
5	Central shunt	2	0.4	2	low cardiac output
6	VSD baffle to PA	2	0.4	2	low cardiac output
7	Modified Rastelli operation	1	4.5	0	low cardiac output
8	ASO with VSD closure	1	0.1	17	low cardiac output
9	RBTS	2	1.2	424	aspiration†
10	RBTS	1	0.6	150	arrhythmia

*During tracheal suctioning on the 11th postoperative day. †During sedation with oral chloral hydrate.
 ASO = arterial switch operation; PA = pulmonary artery; RBTS = right Blalock-Taussig shunt; VSD = ventricular septal defect.

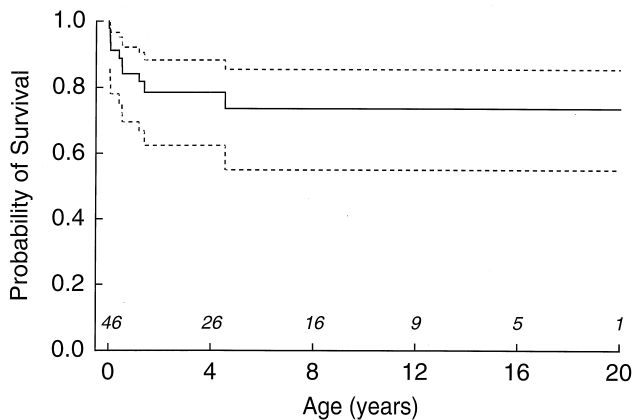


Figure 5. Kaplan-Meier curve (with 90% confidence intervals) showing the probability of survival of 46 patients with straddling mitral valve.

applied separately for patients who underwent a single versus biventricular repair, the probability of survival for the functional single-ventricle palliation group was 77% at 16 and 20 years compared with 50% at 16 years for the biventricular group. However, the difference between groups was not statistically significant ($p = 0.34$).

Table 3 summarizes the results of univariate and multivariate analyses of potential demographic, anatomic and functional predictors of mortality. Patients with a noncommitted VSD had the highest risk of death (relative risk 10.2, $p = 0.005$), followed by multiple VSDs (relative risk 4.7, $p = 0.06$). All five patients with noncommitted VSD underwent a functional single-ventricle palliation, with three deaths. Of the four patients with multiple VSDs, three underwent a functional single-ventricle palliation, with two deaths. In the remaining patient who underwent a biventricular repair and subsequently died, the additional VSDs were not detected preoperatively. Overall, 8 patients with multiple or noncommitted VSDs had a functional single-ventricle palliation, with 5 deaths (62.5%), compared with only 2 deaths among the 30 patients who had other types of a single VSD and had a functional single-ventricle palliation (6.7%) ($p = 0.02$).

DISCUSSION

This largest clinical cohort of patients with SMV studied to date demonstrates five key findings: 1) despite the wide morphological spectrum that characterizes this lesion, it is possible to identify four distinct groups with more uniform anatomy; 2) biventricular repair is feasible in selected patients with SMV; 3) patients with {S,D,L} and {S,L,D} segmental combinations had a higher incidence of cardiac malposition and hypoplastic TV and RV and were less likely to undergo a biventricular repair; 4) the presence of a noncommitted VSD was the strongest independent risk factor for death in the multivariate model followed by multiple VSDs; and 5) mortality rate decreased from 24% to 27% before 1994 to 0% during the cohort's most recent five years (1994 to 1999).

Morphologic considerations. This echocardiographic study confirms several anatomic observations that were previously made in postmortem series (1-8). The MV straddled over the anterior aspect of the interventricular septum through a malalignment-type conoventricular septal defect into the RV infundibulum in all patients. Another uniform finding was an abnormal conotruncus with either DORV or TGA. However, the relatively small number of cases included in most previous studies did not permit classification of anatomic subgroups. We have previously recognized a distinct anatomic pattern in patients with SMV who had hypoplasia of the RV sinus and TV, superior-inferior ventricles and criss-cross AV relations (6). These patients differed from the more common group with two well-developed ventricles in that the degree of ventricular malposition (measured as the angle between the atrial and ventricular septa) was much larger (6). In the present study, patients were easily categorized into one of the following four anatomic groups based on segmental situs: {S,D,D}, {S,D,L}, {S,L,D} or {S,L,L}. On further analysis, patients with {S,D,L} and {S,L,D} segmental anatomy had a significantly higher incidence of cardiac malposition (dextrocardia in patients with D-ventricular loop and levocardia in patients with L-ventricular loop), RV sinus and TV hypoplasia, superior-inferior ventricles and criss-cross AV relations. In general, the anatomy in these patients was less likely to be amenable to a biventricular repair, as opposed to the patients with {S,D,D} or {S,L,L} segmental anatomy.

Echocardiographic considerations. This study demonstrates that echocardiography is ideally suited for noninvasive evaluation of SMV. This conclusion is in agreement with previous reports (9-12) and clinical practice (21). Review of the echocardiograms from the 46 study patients indicates that the MV and its support apparatus must be systematically imaged from multiple views to fully characterize the anomaly. In young patients, the subxiphoid window offers excellent views of the MV, chordae tendineae and papillary muscles, as well as simultaneous cross-sectional images of the LV, RV sinus and infundibulum. Off-axis images are often necessary to obtain simultaneous views of all the anatomical elements involved in SMV. For example, counterclockwise rotation of the transducer from the standard subxiphoid short-axis (parasagittal) plane produces an oblique coronal image that displays both ventricles and infundibulum. Any straddling MV leaflets and chordae can be seen from this view, as well as the potential for construction of a surgical pathway from the LV to the semilunar valves. The apical and parasternal windows are also informative. The apical four-chamber view is especially useful to determine the extent of SMV (minor vs. major straddling). The parasternal short-axis view is particularly helpful in visualizing the MV attachments within the infundibulum, including the presence and location of any accessory papillary muscles. The experience from this study suggests that the importance of systematic echocardiographic examination from multiple acoustic windows and

Table 3. Predictors of Death in 46 Patients With SMV

Variables	Relative Risk (95% confidence limits)	p Value
Univariate analysis		
Male gender	1.8 (0.5–7)	0.25
Age at initial surgery <0.1 year old	0.8 (0.5–1.2)	0.28
Weight at last surgery <2 SD	1 (0.5–1.8)	0.98
Biventricular repair	2.3 (0.6–8.9)	0.25
Dextrocardia	0.04 (1.3 × 10 ⁻⁵ –125.6)	0.24
Superior-inferior ventricles	1.1 (0.3–4.2)	0.85
Crisscross AV valves	1.3 (0.2–10)	0.78
Ventriculo-arterial alignment (DORV)	1.9 (0.2–14.6)	0.39
Hypoplastic RV	0.3 (0.04–2.7)	0.33
Hypoplastic LV	0.6 (0.1–4.8)	0.81
Bilateral conus	0.5 (0.1–2.5)	0.31
Noncommitted VSD	4.9 (1.2–18.9)	0.006
Extension of VSD into AV canal	1.2 (0.3–4.7)	0.65
Multiple VSDs	5.6 (1.4–22)	0.002
Major straddling	0.8 (1.2–3.8)	0.95
Mitral regurgitation	0.5 (0.1–4.1)	0.52
Nonrestrictive pulmonary blood flow	0.3 (0.1–1.1)	0.04
Oxygen saturation before last surgery	0.9 (0.2–4.8)	0.98
Multivariate analysis		
Noncommitted VSD	10.2 (2–51.8)	0.005
Multiple VSDs	4.7 (0.9–23.8)	0.06
Nonrestrictive pulmonary blood flow	0.3 (0.05–1.2)	0.08

AV = atrioventricular valves; DORV = double-outlet right ventricle; LV = left ventricle; RV = right ventricle; SD = standard deviation; SMV = straddling mitral valve; VSD = ventricular septal defect.

views cannot be overemphasized. Flow mapping with color Doppler is useful for assessment of MV function but does not aid in the diagnosis of SMV or with surgical planning. The potential benefit of three-dimensional echocardiography in the preoperative evaluation of SMV deserves further study.

Surgical considerations. The nearly universal association of SMV with a malalignment conoventricular septal defect and with conotruncal anomalies (DORV or TGA), and the recognition of four distinct segmental anatomic patterns, has important surgical implications. Another important observation is that a significant proportion of these children (29 of 46) had two ventricles of normal or nearly normal size. Therefore, discussion as to whether a biventricular repair is feasible in these patients will revolve around the ability of the surgeon to baffle the LV outflow through the VSD to the closest semilunar valve—pulmonary or aortic—without distorting the chordal apparatus of the mitral valve and without obstructing LV outflow (22).

Techniques have been described for repair of these defects in children when the degree of straddling is relatively minor (14,23). Frequently, enlargement of the VSD is necessary to avoid subaortic obstruction from the chordal apparatus crossing the VSD. In patients with DORV, the VSD patch is usually placed around the chordal insertion site (achieved in seven patients in this study). In TGA with SMV, the chordae can be retracted flush with the edge of the VSD and they are then fixed in that position by suturing of the VSD patch onto the crest of the septum (performed in one patient in this series). Despite this apparent distur-

tion, mitral regurgitation is an uncommon complication of biventricular repair.

Recognition of the segmental anatomy is also important for determination of the likely position of the conduction tissue before VSD closure or baffling. The conduction axis in patients with SMV, unlike straddling TV, follows the usual pattern for the segmental situs. Specifically, in patients with solitus atria and D-ventricular loop the conduction axis is expected to run along the posterior-inferior rim of the VSD. In those with L-ventricular loop the conduction axis is expected to run along the superior-anterior rim of the VSD. Therefore, injury to conduction tissue, even when VSD enlargement is necessary, should be avoidable (22).

For the subgroup of children with SMV and hypoplasia of one ventricle, the usual management for functional single ventricle with total cavopulmonary connections—avoiding complex intracardiac procedures—is a good alternative with excellent early and midterm results (24). The only exception is the small subgroup (2 of 46) with DORV where the MV leaflet attaches to the crest of the septum, creating a restrictive VSD. In this group, VSD enlargement is likely to be required to prevent LV outflow obstruction.

Study limitations. The retrospective nature of the analysis imposes inherent limitations. The surgical management of the patients was decided on a case-by-case basis, and selection of single versus biventricular approach was not based on predefined criteria. Hence, it is not possible to know whether some of the patients who underwent a functional single-ventricle palliation could have survived a biventricular repair. Similarly, it is not possible to determine

whether patients who did not survive a biventricular approach would have survived a functional single-ventricle palliation.

Acknowledgments

We thank Emily Flynn McIntosh for the artwork and Bill McIntosh for the photography.

Reprint requests and correspondence: Dr. Tal Geva, Department of Cardiology, Children's Hospital, 300 Longwood Avenue, Boston, Massachusetts 02115. E-mail: geva_t@a1.tch.harvard.edu.

REFERENCES

1. Kitamura N, Takao A, Ando M, Imai Y, Konno S. Taussig-Bing heart with mitral valve straddling: case reports and postmortem study. *Circulation* 1974;49:761-7.
2. Freedom RM, Bini R, Dische R, Rowe RD. The straddling mitral valve: morphological observations and clinical implications. *Eur J Cardiol* 1978;8:27-50.
3. Bharati S, McAllister HA, Lev M. Straddling and displaced atrioventricular orifices and valves. *Circulation* 1979;3:673-84.
4. Milo SM, Ho SY, Macartney FJ, et al. Straddling and overriding atrioventricular valves: morphology and classification. *Am J Cardiol* 1979;44:1122-34.
5. Wenink ACG, Gittenberger-de Groot AC. Straddling mitral and tricuspid valves: morphologic differences and developmental background. *Am J Cardiol* 1982;49:1959-71.
6. Geva T, Van Praagh S, Sanders SP, Mayer JE, Van Praagh R. Straddling mitral valve with hypoplastic right ventricle, crisscross atrioventricular relations, double outlet right ventricle and dextrocardia: morphologic, diagnostic and surgical considerations. *J Am Coll Cardiol* 1991;17:1603-12.
7. Muster AJ, Bharati S, Aziz KU, et al. Taussig-Bing anomaly with straddling mitral valve. *J Thorac Cardiovasc Surg* 1979;77:832-42.
8. Wenink ACG, Gittenberger-de Groot AC, Brom AG. Developmental considerations of mitral valve anomalies. *Int J Cardiol* 1986;11:85-98.
9. Rice MJ, Seward JB, Edwards WD, et al. Straddling atrioventricular valve: two-dimensional echocardiographic diagnosis, classification and surgical implications. *Am J Cardiol* 1985;55:505-13.
10. Marino B, Sanders SP, Pasquini L, Giannico S, Parness IA, Colan SD. Two-dimensional echocardiographic anatomy in criss-cross heart. *Am J Cardiol* 1986;58:325-33.
11. Smallhorn JF, Tommasini G, Macartney FJ. Detection and assessment of straddling and overriding atrioventricular valves by two-dimensional echocardiography. *Br Heart J* 1981;46:254-62.
12. Vargas Barron J, Sahn DJ, Valdes-Cruz LM. Two-dimensional echocardiographic evaluation of overriding and straddling atrioventricular valves associated with complex congenital heart disease. *Am Heart J* 1984;107:1006-14.
13. Danielson GK, Tabry IF, Riter DG, Fulton RE. Surgical repair of criss-cross heart with straddling atrioventricular valve. *J Thorac Cardiovasc Surg* 1979;77:847-51.
14. Serraf A, Nakamura T, Lacour-Gayet F, et al. Surgical approaches for double-outlet right ventricle or transposition of the great arteries associated with straddling atrioventricular valves. *J Thorac Cardiovasc Surg* 1996;111:527-35.
15. Belli E, Serraf A, Lacour-Gayet F, et al. Biventricular repair for double outlet right ventricle. Results and long-term follow-up. *Circulation* 1998;98:II360-7.
16. Aoki M, Forbess JM, Jonas RA, Mayer JE, Castaneda AR. Result of biventricular repair for double-outlet right ventricle. *J Thorac Cardiovasc Surg* 1994;107:338-50.
17. Van Praagh R. Terminology of congenital heart disease. Glossary and commentary. *Circulation* 1977;56:139-43.
18. Van Praagh S, Davidoff A, Chin A, Shiel FS, Reynolds J, Van Praagh R. Double-outlet right ventricle: anatomic type and developmental implications based on a study of 101 autopsied cases. *Arch Mal Coeur* 1982;13:389-440.
19. Kumar K, Lock JE, Geva T. Apical muscular ventricular septal defects between the left ventricle and the right ventricular infundibulum: diagnostic and interventional considerations. *Circulation* 1997;95:1207-13.
20. Van Praagh R, Geva T, Kreuzer J. Ventricular septal defects: how shall we describe, name and classify them? *J Am Coll Cardiol* 1989;14:1298-9.
21. Geva T. Echocardiography and Doppler ultrasound. In: Garson A, Jr., Bricker JT, Fisher DJ, Neish SR, editors. *The Science and Practice of Pediatric Cardiology*. Baltimore, MD: Williams & Wilkins, 1997: 789-843.
22. Anderson RH, Ho SY. Which hearts are unsuitable for biventricular repair? *Ann Thorac Surg* 1998;66:621-6.
23. Pacifico AD, Soto B, Barger LMJ. Surgical treatment of straddling tricuspid valves. *Circulation* 1979;60:655-64.
24. Stamm C, Friehs I, Mayer JE, Jr., et al. Long-term results of the lateral tunnel Fontan operation. *J Thorac Cardiovasc Surg* 2001;121:28-41.