



HAL
open science

Systemic embolism: a serious complication after cardiac transplantation avoidable by bicaval technique

Alberto Riberi, Pierre Ambrosi, Gilbert Habib, Bernard Kreitmann, John Yao, Jean Gaudart, Olivier Ghez, Dominique Metras

► To cite this version:

Alberto Riberi, Pierre Ambrosi, Gilbert Habib, Bernard Kreitmann, John Yao, et al.. Systemic embolism: a serious complication after cardiac transplantation avoidable by bicaval technique. *European Journal of Cardio-Thoracic Surgery*, 2001, 19, pp.307-312. 10.1016/S1010-7940(00)00653-9 . hal-01211574

HAL Id: hal-01211574

<https://hal.science/hal-01211574v1>

Submitted on 26 Apr 2016

HAL is a multi-disciplinary open access archive for the deposit and dissemination of scientific research documents, whether they are published or not. The documents may come from teaching and research institutions in France or abroad, or from public or private research centers.

L'archive ouverte pluridisciplinaire **HAL**, est destinée au dépôt et à la diffusion de documents scientifiques de niveau recherche, publiés ou non, émanant des établissements d'enseignement et de recherche français ou étrangers, des laboratoires publics ou privés.



Distributed under a Creative Commons Attribution - NonCommercial - NoDerivatives 4.0 International License



ELSEVIER

European Journal of Cardio-thoracic Surgery 19 (2001) 307–312

EUROPEAN JOURNAL OF
CARDIO-THORACIC
SURGERY

www.elsevier.com/locate/ejcts

Systemic embolism: a serious complication after cardiac transplantation avoidable by bicaval technique[☆]

Alberto Riberi^{a,*}, Pierre Ambrosi^b, Gilbert Habib^b, Bernard Kreitmann^a, John G. Yao^a,
Jean Gaudart^c, Olivier Ghez^a, Dominique Metras^a

^aDepartment of Cardiovascular Surgery, Children's Hospital la Timone, Rue de l'Armée d'Afrique, 13385 Marseille, Cedex 5, France

^bDepartment of Cardiology, La Timone Hospital, Rue de l'Armée d'Afrique, 13385 Marseille, Cedex 5, France

^cDepartment of Medical Information, La Timone Hospital, Rue de l'Armée d'Afrique, 13385 Marseille, Cedex 5, France

Received 8 September 1999; received in revised form 14 November 2000; accepted 11 December 2000

Abstract

Objective: Systemic embolism is a serious complication after classical orthotopic transplantation, presumably originating from enlarged left atrium. We specifically studied this problem after classical and modified bicaval transplantation. **Methods:** Between December 1985 and March 1999 we consecutively performed 72 classical and 106 modified heart transplantation. Modification included bicaval anastomosis and recipient left atrium maximal reduction. Mean age was 47 years. All the patients received an antiplatelet therapy and were routinely followed. When clinical signs of systemic embolism were present, a neurological evaluation and transesophageal echocardiography were done. Sixty matched patients (30 of each group) had comparative transesophageal echocardiography study, at least 6 months after transplantation. **Results:** Perioperative mortality was 17.4%. Mean follow-up was 6.8 2 + /47 years. All patients were in sinus rhythm. Among 147 survivors, 11 patients who underwent classical transplantation had a systemic embolism, 1 month to 12 years after transplantation, 15.3%, (11/72). Two limb ischemia and one mesenteric ischemia (needing surgery), seven strokes (one death, two permanent neurological deficit). There was no systemic embolism in the modified technique group ($P = 0.013$). Left atrial comparative transesophageal echocardiography study showed a larger left atrial surface in classical transplantation. $33 \pm 4 \text{ cm}^2$ versus $20 \pm 3 \text{ cm}^2$ in a modified technique, $P = 0.01$. Spontaneous echo contrast was present in 56% of classical technique group associated with atrial thrombosis in nine patients, there were no atrial thrombosis in modified technique group and spontaneous echocontrast was present in 0.5% ($P = <0.001$). **Conclusion:** The occurrence of systemic embolism, left atrial spontaneous echocontrast and thrombosis when using classical technique, and the absence of these complications with the bicaval technique justified the use of this method. Our experience with atrial thrombosis and spontaneous echocontrast rises the question of anticoagulation in classical transplantation. © 2001 Elsevier Science B.V. All rights reserved.

Keywords: Cardiac transplantation; Atrial; Thrombosis; Systemic embolism

1. Introduction

Systemic embolism is a serious complication of classical orthotopic heart transplantation. The frequency of intracardiac thrombi after cardiac transplantation is probably underestimated. The incidence of reported cardiac embolism after cardiac transplantation varies between 2 and 15% [1]. It is accepted that most patients with intracardiac thrombi are symptom free. However, several cases of systemic embolism in patients undergoing a classical heart transplantation (CHT) have been reported [2–6]. The reasons for formation of intracardiac thrombi after classical heart transplantation

are presumably the enlarged left atria, (resulting for addition of donor and recipient atria), the non-contractile portion of recipient atrium and the asynchrony between the donor and the recipient atria which encourages stasis [5,6].

The purpose of this study is to report our experience with systemic embolism and to analyze the risk factors for atrial thrombosis and systemic embolism after classical and modified bicaval heart transplantation (BCHT).

2. Materials and Method

2.1. Patients

Between December 1985 and April 1999 we consecutively performed 72 classical heart transplantation (CHT) and subsequently 106 modified BCHT. Mean age was

[☆] Presented at the 13th Annual Meeting of the European Association for Cardio-thoracic Surgery, Glasgow, Scotland, UK, September 5–8, 1999.

* Corresponding author. Tel.: +33-491-386676; fax: +33-491-386704.

E-mail address: alberi@free.fr (A. Riberi).

46.6 ± 19 years (0.8–71). The three staff members of the surgical team carried out all the operations and have used the same technique either in CHT or in BCHT. Indication for transplantation was in 47 ischemic cardiomyopathy, 123 dilated cardiomyopathy, nine congenital cardiomyopathy, and four valvular cardiomyopathy. Three patients had an history of ischemic stroke 1 month, 1 and 10 years before the cardiac transplantation.

All patients had before inscription in the waiting list a complete check-up looking for contraindication, in particular peripheral vascular status, which was assessed by echodoppler and angiography when necessary.

When transplanted patients presented symptoms and signs of systemic embolism, a transesophageal echocardiography (TEE), a vascular echodoppler and a brain computed tomography (CT) scan were systematically done. Preoperative data are detailed in Table 1.

2.2. Surgical technique in recipients

Modifications of the classical heart transplantation technique have consisted in: total right atria resection, reduction of the left atria to a minimal cuff containing the four pulmonary veins and everting suture between the recipient pulmonary veins and the donor left atrium

2.3. Surgical technique in donors

Modifications of cardiac harvesting consisted in dissection and division of the superior vena cava just below the Pyrogoff confluent.

When lungs were also harvested the heart was separated from the lungs by division of the pulmonary artery 1 cm below the bifurcation and reduction of the left atrium, in order to keep a cuff of atrial tissue around the right and left pulmonary veins.

2.4. Follow-up

All survivors (147 patients) were followed-up in our institution. A double immunosuppression including Cya and ster-

oid was administrated in the first two years following the transplantation, and then steroids were stopped and substituted by Azathioprine.

All patients received an antiplatelet treatment (aspirin), which was stopped if poorly tolerated. In patients who had peripheral embolism an oral anticoagulant treatment was administrated. Surveillance consisted in routine physical examination, chest X-rays, surface EKG, yearly left and right cardiac catheterization with coronary angiography and myocardial biopsy. Transthoracic echocardiography was usually utilized for evaluate cardiac function and detect rejection. Transesophageal echocardiography was done in 60 matched patients (30 CHT and 30 BCHT) 6 months after transplantation, and a comparative study was undertaken. Subsequently TEE was performed routinely in all patients.

2.5. Statistical methods

Univariate analysis (Chi-square or Student *t*-test) and multivariate analysis (Cox test) were used.

To calculate the risk of event and the survival rate the Kaplan–Meier method was utilized. A *P* value equal or less than 0.05 was considered statistically significant (Software S.P.S.S.).

3. Results

Since the beginning of our experience in December 1985, 178 patients underwent a cardiac transplantation in our institution.

Seventy-two had a classical heart transplantation (group I) and 106 a modified total bicaval transplantation (group II). There was no significantly difference between the two groups concerning sex ratio, pre-operative diagnosis, functional NYHA class, and pulmonary vascular resistance. Mean age was slightly greater in group II (48 years versus 44 years), and there were more patients over 60 years of age in group II, 40.2 versus 19.8% in group I (*P* = 0.02), due to wider acceptance of older patients.

There was no complication due to the surgical technique. The aortic cross-clamping time in the recipient (cardiac excision and donor heart implantation) was longer in group II (87.2 ± 12 versus 65.4 ± 15, *P* = 0.001). The donor ischemic time was also longer in group II (87.2 ± 53 versus 210 ± 67 MN *P* = 0.01). The increased ischemic time was partially due to the surgical technique, but also to harvesting carried out far from our center which were more frequent in group II, 50 versus 24% in group I (*P* = 0.003). Perioperative mortality (30 days) was 17.4% (32/178) in the whole group, without significantly difference between the two groups, 15.7% in group I and 18.4% in group II (*P* = 0.1).

The follow-up period was longer in group I, than in group II 8.70 years (±4.50) versus 5.90 years (±3.28) *P* = 0.001. The actuarial survival rate was 76.9, 70.59 and 66.19% at 3, 6

Table 1
Pre-operative data (*n* = 178)

Age	46.6 ± 19 years (7 month–71 years)
Sex	
Male	145
Female	33
Pre-operative diagnosis	
Dilated	123
Ischemic	47
Congenital	9
Valvular	4
Atherosclerosis of the carotid arteries	28
Atrial fibrillation	5
Pre-operative stroke ^a	3

^a One permanent neurological deficit.

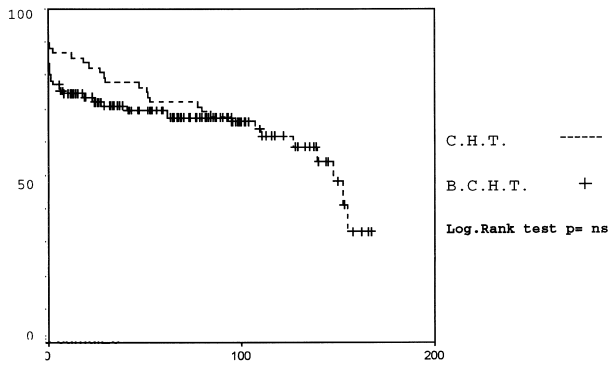


Fig. 1. Actuarial survival curve after CHT and BCHT Kaplan–Meier method.

and 9 years for the classical technique and 71.01, 69.47 and 67.43% for bicaval, without difference between the two groups ($P = n.s.$) (Fig. 1).

Among 82.5% perioperative (1 month) survivors 11 patients of group I (15.2%) had a systemic embolism 21 days to 12 years after operation. There were one mesenteric ischemia, two lower limb ischemia, and eight strokes. Three patients needed a surgical treatment: one a bowel resection and two a surgical embolectomy of the lower limb. One patient die due to a stroke, two had permanent neurological deficit (one hemiplegia, one monoplegia) and another had a cerebral hemorrhage due to the anticoagulant treatment given after a stroke. Left atrial thrombosis was shown at TEE in 81.8% of these patients (9/11) The atrial thrombi were located in four cases in the left atrial appendage, in two cases on the atrio-atrial suture line and in the others three in the recipient left atrial wall, close to the suture line. None of the patient who underwent a BCHT had arterial embolism or atrial thrombosis at TEE ($P = 0.013$) (Fig. 2).

The vascular echo-doppler showed that 28 patients had vascular lesions of the supraaortics trunks before the operation. Among these, 26 had diffuse atherosclerosis lesions without evidence of stenosis and did not need any medical

or surgical treatment. Two patients had a stenotic lesion of the carotid artery one of them needed a percutaneous dilatation of the lesion with stenting. The other presented a mild carotid stenosis and an antiplatelet treatment was administered. Eight patients who had diffuse atherosclerosis lesions of supraortics trunks underwent a classical cardiac transplantation and 3 of them had an episode of systemic embolism (istroke two limb ischemia).

Among the three patients who had a stroke before the transplantation, two underwent a cardiac transplantation with the modified technique and the other with the classical technique. None of these patients presented any evidence of systemic embolism along their follow-up. None of the patients transplanted (group I and group II) presented a right sided (right atrium, ventricle or pulmonary artery) thrombosis or embolism.

Patient’s characteristics are detailed in Table 2. All transplanted patients were in long term sinus rhythm, the post operative surface EKG showed no major difference between the two groups except a double atrial activity in patients who had a CHT (14 versus 0) $P = 0.003$.

The occurrence of acute rejection episodes was no significantly different in patients who had a peripheral embolism than in patients free from embolism (1.8 ± 2 versus 2.1 ± 3) $P = 0.1$. Chronic rejection defined by coronary vascular lesions at yearly coronary angiograms were presents in 19 patients. None of these patients had any evidence of systemic embolism.

Sixty matched patients (30 of each group) had a comparative transthoracic and transeophageal echocardiography study, at least 6 months after surgery, which showed a major incidence of mild mitral incompetence in group, I 66 versus 33% in group II, ($P = 0.03$), a major incidence of left atria thrombosis, 12.5% (9/72) group I versus 0 in group II, ($P = 0.02$). Moreover a larger surface of the left atria in CHT than in BCHT ($33 \pm 4 \text{ cm}^2$ versus $20 \pm 3 \text{ cm}^2$) $P = 0.01$, and an increased incidence of spontaneous echo-contrast in group I than in group II ($56 \pm 0.5\%$) $P = 0.001$ were founded. Nine patients had a concomitant lung harvesting in donors, four of group I and five of group II. The measurement of the left atrium surface revealed also in these cases significantly larger atria in patients operated with CHT $29 \pm 5 \text{ cm}^2$ versus $21 \pm 21 \text{ cm}^2$ in the BCHT ($P = 0.03$).

The univariate and multivariate analysis of risk factors: age peripheral vascular status, the absence of antiplatelet treatment, the impaired left diastolic function, (defined as an end diastolic left ventricular pressure greater than 17 mmHg at cardiac catheterization), the decreased left systolic function, (defined as an ejection fraction inferior to 50% at echocardiography and or at cardiac angiocardiogram), atrial fibrillation or sinus rhythm before surgery, and surgical technique, recognized the surgical technique as the only factor favoring peripheral embolism. In contrast the altered diastolic function and the absence of antiplatelet treatment were risk factor for death (Table 3).

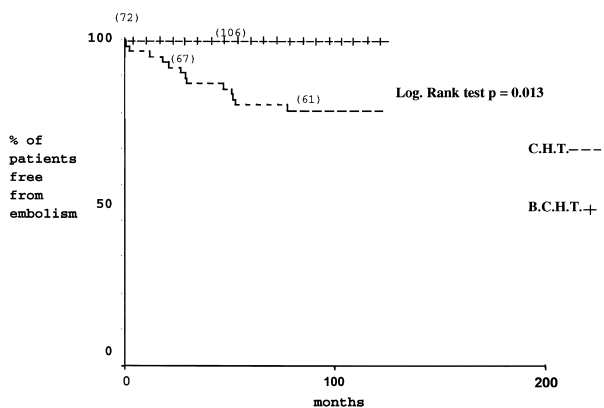


Fig. 2. Univariate analysis (Kaplan–Meier). Actuarial risk of systemic embolism after cardiac transplantation with CHT and BCHT.

Table 2
Patients having a systemic embolism, after cardiac transplantation ($n = 11$)

Patients No.	Age (years)	Clinical signs	Time to embolism	Surgical technique ^a	Evolution
1	30	Limb ischemia	21 days	CHT	Surgical embolectomy
2	48.5	Stroke	28 days	CHT	No sequel
3	51.8	Stroke	3 months	CHT	Permanent hemiplegia
4	38.9	Mesenteric ischemia	3 years	CHT	Surgical bowel resection
5	60.08	Stroke	5 years	CHT	No sequel
6	41.5	Stroke	6 years	CHT	Cerebral hemorrhage ^b
7	42.0	Stroke	7 years	CHT	Monoplegia
8	55.8	Stroke	8 years	CHT	Death
9	69.3	Stroke	9 years	CHT	No sequel
10	54.2	Limb ischemia	10 years	CHT	Surgical embolectomy
11	56	Stroke	12 years	CHT	No sequel

^a None of patients undergoing BCHT had a systemic embolism.

^b Cerebral haematoma due to the anticoagulant treatment.

4. Discussion

Systemic embolism is a serious complication after classical cardiac transplantation. The incidence of left atrial thrombi in patients who underwent a CHT is unknown since the majority of these patients are asymptomatic [3,4] and intracardiac thrombi are only detected by TEE or thoracic CT scan [1–3,6–8].

The physiopathology of intracardiac thrombi formation in patients undergoing CHT is not completely understood, although several factors may be involved:

- Alteration in hemostatic mechanism has been shown to exist. An increase in platelet aggregation has been observed which is due to the inhibited endothelial prostacycline synthesis mediated by cyclosporine. This abnormality in platelet aggregation is resistant to conventional antiplatelet treatment [9]. In our series of patients, there was no difference in the incidence of atrial thrombosis and peripheral embolism between patients with or without antiplatelet treatment. On the other hand rejection deplete the endothelial thrombomodulin and the antithrombin III which results in an increased thrombogenic incidence [10]. In our experience there were no

difference in rejection incidence between the group of patients having peripheral embolism and the free of systemic embolism group.

- The resulting enlarged left atrium after CHT favors blood stasis and thrombi formation. The presence of spontaneous echocontrast has been observed in a high percentage of patients undergoing a CHT [1,2,5–8,11,12].
- In our series all patients who had an episode of peripheral embolism had underwent a classical cardiac transplantation, and in this group of patients an enlarged left atrium and an increased incidence of spontaneous echocontrast (SEC) were observed by TEE when compared to BCHT group. Others technical factors were found to predispose a patient to forming thrombi, because the TEE showed thrombotic formation along the atrial suture line [2,11]. This was also reported after lung transplantation on the cuff of left atrium [12,13]. In all patients undergoing a CHT the suture line was visualized and in two of them an intracardiac thrombus was observed at TEE. None of patients who underwent a BCHT had an apparent suture line at TEE. This is probably due to the everting suture technique used in the anastomosis between the recipients pulmonary veins and the donor left atrium. The impaired diastolic and systolic function may be linked to the formation of intracardiac thrombi [3,7,14]. In our series two patients among the 11 having a systemic embolism had an impaired diastolic function. The systolic function was normal in all patients of this group.
- The asynchronous contraction of the recipient and donor atrial components as well as the presence of arrhythmia induce blood stasis and may result in an increasing thrombogenic propensity [3,7,11,15,16]. Three patients who had a stroke in our series presented a double atrial activity and this was observed in 46.6% of patients undergoing a CHT. Atrial fibrillation in the recipient atrial component has been reported as favoring atrial thrombosis [1,15]. None of the patients having an atrial thrombosis and/or a systemic embolism had a fibrillation of the recipient component of the atria in our experience.

Table 3
Multivariate analysis (Cox test)

Variant	Free of embolism	Embolism	P^a
Age (years)	46.3 ± 17	48.4 ± 11	1
Carotid disease	25	3	0.9
No anti platelets treatment	35	2	0.3
Impaired left diastolic function	32	2	1
Decreased left systolic function	12	0	1
Atrial fibrillation before surgery	5	0	1
Surgical technique			
CHT	61	11	0.04
BCHT	106	0	

^a $P = <0.05$ was significant.

Moreover we don't have observed arrhythmia among our cohort of patients.

- The peripheral vascular status of patients undergoing heart transplantation may also predispose to arterial thrombosis or embolism. In our cohort of patients eight among the CHT group presented a diffuse atherosclerosis of the supraortic trunks, three of them had an episode of arterial embolism and demonstration of a left atrial thrombi, which suggest that the arterial embolism was probably due to the left atrial thrombus. In the CHT group only two patients among eleven presenting an arterial embolism were free of left atrial thrombosis at TEE study and did not presented any evidence of peripheral vascular disease at the echodoppler study. Another possible important factor in thrombo-embolic events is the duration of the follow-up period. Incidence of thrombo-embolic complications increases with time [17]. In our series 54.5% (6/11) of episodes of arterial embolism occurred in the early or mid term follow up and 45.5% (5/11) in the late follow-up period, and this represents a limitation in our study since the two compared series are consecutive and the mean follow-up for the bicaval group is shorter than in classical technique group 5.90 years versus 8.70 years, respectively.

5. Conclusion

Atrial thrombosis and systemic embolism after heart transplantation are probably underestimated, and more studies are necessary to shed light on its actual incidence. All the conditions favoring blood stasis and left atrial thrombosis are found after CHT, in contrast BCHT seems to decrease considerably this problem, without increasing the perioperative mortality and morbidity and this only fact justifies the use of this technique. Our experience of left atrial thrombosis, and frequent left atrial echocontrast rises the question of the anticoagulation in patients who had undergone a CHT.

References

- [1] Derumeaux G, Habib G, Mouton Schleifer D. Standard orthotopic heart transplantation versus total orthotopic heart transplantation. A transesophageal echocardiography study of the incidence of left atrial thrombosis. *Circulation* 1995;9:196–201.
- [2] Derumeaux G, Mouton Schleifer D, Redonnet M. Fréquence des thrombus intra-auriculaires détectés par l'échocardiographie transoesophagienne chez les transplantés cardiaques. *Arch Mal Coeur* 1994;87:1459–1465.
- [3] Fernandez-Gonzalez A, Llorens R, Herreros J. Intracardiac thrombi after orthotopic heart transplantation: clinical significance and etiologic factors. *J Heart Lung Transplant* 1994;13:236–240.
- [4] Rahman A, Deiraniya A, Campbell C. Thrombotic complications after heart transplantation. *J Heart Lung Transplant* 1994;13:1146–1147.
- [5] Bouchart F, Derumeaux G, Mouton-Schleifer D. Conventional and

- total orthotopic cardiac transplantation: a comparative clinical and echocardiography study. *Eur J Cardio-thorac Surg* 1997;12:555–559.
- [6] Metras D, Kreitmann B, Riberi A. Etude comparative de la transplantation cardiaque orthotopique standard et totale. *Arc Mal Coeur* 1997;90:27–34.
- [7] Polanco G, Jafri SM, Alam M. Transesophageal echocardiographic findings in patients with orthotopic heart transplantation. *Chest* 1992;101:599–602.
- [8] Ishizuka N, Nakaura K, Fujita Y. Transesophageal echocardiography findings in patients after heart transplantation. *J Cardiol* 1997;29:163–170.
- [9] De Lorgeril M, Dureau G, Boissonnat P. Increased platelet aggregation after heart transplantation: influence of Aspirin. *J Heart Lung Transplant* 1991;10:600–603.
- [10] Labarrere C, Pitts D, Halbhook H. Natural anticoagulant pathway in normal and transplanted human hearts. *J Heart Lung Transplant* 1992;11:342–347.
- [11] Angermann C, Spes C, Tammen A. Anatomic characteristics and valvular function of the transplanted heart: transthoracic versus transesophageal echocardiographic findings. *J Heart Transplant* 1990;9:331–338.
- [12] Schmid C, Gulba DC, Heublein B. Systemic recombinant tissue plasminogen activator lysis for left atrial thrombus formation after single lung retransplantation. *Ann Thorac Surg* 1992;53:338–340.
- [13] Stang MR, Hinderliter AL, Gott KK. Atrial anastomotic thrombus causes neurologic deficits in a lung transplant recipient. *Transplantation* 1996;62:693–695.
- [14] Clark VL, Levine TB. Thrombus causing fatal left ventricular outflow tract obstruction in a heart transplant patient. *Cathet Cardiovasc Diagn* 1992;25:132–134.
- [15] Torrecilla EG, Garcia-Fernandez MA, San Roman D. Left atrial spontaneous echocardiographic contrast after heart transplantation. *Am J Cardiol* 1992;69:817–818.
- [16] Adair JC, Call GK, O'Connell JB. Cerebrovascular syndromes following cardiac transplantation. *Neurology* 1992;42:819–823.
- [17] Forrat R, Ferrera R, Boissonnat P, Adeleine P, Dureau G, Ninet J, Lorgeril M. High prevalence of thromboembolic complications in heart transplantation. *Transplantation* 1996(61):757–762.

Appendix A. Conference discussion

Dr P. Totaro (Brescia, Italy): I did a similar study when I was working in Northern General Hospital in Sheffield. We found a similar incidence of atrial thrombosis in patients without any sign of peripheral embolism. We treated them with oral anticoagulation and they recovered very well and their thrombosis disappeared.

So my question is, does your incidence regard overall population or only the patients with clinical signs of peripheral embolism?

And the second one is, how did you treat the patient with the left atrial thrombosis?

Dr Riberi: For all patients with left arterial thrombosis with an anticoagulant treatment by an oral – this is your question?

Dr Totaro: Yes. Did you give just oral anticoagulant, or did you give intravenous heparin for some time?

Dr Riberi: In the beginning we induced the treatment with heparin in vein and then we go on oral anticoagulant treatment with it.

I'm sorry, I didn't understand the first question.

Dr Totaro: Does your incidence of left atrial thrombosis regard all the patients with a heart transplant or only the patients with clinical signs of peripheral embolism?

Dr Riberi: Forty percent of patients with classical heart transplantation in our population have a left atrial thrombosis.

Dr Totaro: I mean we found 14% of incidence of left atrial thrombosis just as a routine surveillance of echocardiographic in asymptomatic patients.

Dr Riberi: Yes.

Dr Totaro: Is yours the same?

Dr Riberi: Yes.

Dr C. Yankah (Berlin, Germany): You may have a peripheral thrombosis or thromboembolic episodes without having atrial thrombosis. These patients sometimes have preoperatively heparin therapy. And we have some experience in some certain patients who developed heparin-induced thrombocytopenia and also caused some peripheral thromboembolic episodes, even as well as also the cerebral. Have you observed or diagnosed heparin-induced thrombocytopenia (HIT type II). Perhaps these two patients were HIT patients.

Dr Riberi: No, we have never found these kinds of complications with heparin.

Dr A. Haverich (Hannover, Germany): The bicaval technique in and by

itself does not influence thromboembolism from the left atrium. Therefore the title of the presentation is somewhat misleading.

On the other hand, if you also change the technique of suturing the left atrium, making it much smaller, that has definitely an influence. Our cardiologists always tell us to occlude the left atrial appendage on the donor heart. Did you change that as well when changing your technique between the first and the second group of your study?

Dr Riberi: We sutured the left appendage – this is your question?

Dr Haverich: Yes. And did you occlude the left atrial appendage?

Dr Riberi: Yes, always.

Dr Haverich: With both techniques?

Dr Riberi: No. We began with the bicaval techniques to do it.